

## Clinical and Radiological Five Year Follow-Up of the First 57 Birmingham Hip Resurfacing Procedures of a Single Surgeon

Stefan GM Weenders<sup>1\*</sup>, Robert JLL van de Kimmenade<sup>1</sup>, Hester J van der Zaag-Loonen<sup>2</sup>, Pieter HJ Bullens<sup>1</sup> and Eric Breemans<sup>1</sup>

<sup>1</sup>Department of Orthopaedics, Gelre Hospital Apeldoorn, The Netherlands

<sup>2</sup>Department of Epidemiology, Gelre Hospital Apeldoorn, The Netherlands

\*Corresponding Author: Stefan GM Weenders, Department of Orthopaedics, Gelre Hospital Apeldoorn, The Netherlands.

Received: September 21, 2018; Published: October 24, 2018

### Abstract

**Background:** There is limited independent data to verify the mid to long-term success of the Birmingham Hip Resurfacing (BHR) prosthesis. The aim of this study was to evaluate the clinical results of the first BHR procedures of a single surgeon with a minimum of five years follow-up.

**Material and Methods:** All patients who underwent hip resurfacing arthroplasty between 2005 and 2007 with the BHR system by one surgeon were included. We measured blood cobalt levels and assessed survival. If a patient became a contralateral BHR hip after the inclusion period, only the first procedure was used for radiological evaluation.

**Results:** During the inclusion period 57 first BHR procedures were performed in 57 patients; 36 were male (63%), median age was 53 years (range 34 - 62 years). Median follow-up was 6.9 years (range 5.1 - 10.4). One patient was lost to follow-up. Five patients needed a revision during follow-up (survival 91.1%). Radiological evaluation revealed a median inclination of 54.4° (range 34.0° to 69.4°) and a median anteversion of 26.0° (range 0.2° to 64.0°). CT and ultrasound analysis revealed one patient with an abnormality suspected for an adverse reaction to metal debris (ARMD). The median cobalt level in the unilateral group was 28.8 nmol/L (range 12.0 - 230.8) and 47.5 nmol/L (range 17.0 - 2579.4) in the bilateral group ( $p = 0.004$ ).

**Conclusions:** This study shows a survival of 91.1% after a median follow-up of 6.9 years. The long-term effects of elevated metal ion levels in the blood remain uncertain. CT analysis is an important tool to investigate possible long term complications such as loosening and ARMD formation.

**Keyword:** Arthroplasty; Hip Replacement; Hip Resurfacing; Outcome; Learning Curve

### Introduction

The BHR prosthesis was developed in the 1990s to overcome the problem of early failure of conventional total hip replacements (THR) in young active males with end-stage osteoarthritis of the hip [1-4]. Concern has emerged about an increasing number of revisions for unexplained pain and adverse reactions to metal debris (ARMD) and possible systemic effects [2,5]. Although closely monitored there is a lack of published outcome concerning the mid to long-term success of the BHR [3].

### Aim of the Study

The aim of this study was to evaluate the outcome of the first BHR procedures of one orthopedic surgeon including his learning curve after a minimum of five years follow-up and to identify risk factors for failure and ARMD.

## Materials and Methods

During the inclusion period 57 first BHR procedures were performed in 57 patients. The first patient receiving a BHR (Smith and Nephew, Warwick, United Kingdom) was operated in January 2005. Data from all consecutive patients operated on were retrospectively included in our study. The last patient of this cohort was operated in December 2006. All procedures were done by one single orthopaedic surgeon (EB), taking its learning curve into account. Only the first implanted BHR of every patient was analyzed.

Indications for this implant in our clinic were relatively young patients with end-stage osteoarthritis of the hip. Patients with osteoporosis, determined on a dual x-ray absorptiometry scan, were excluded. The posterior approach was used for all hips. In the 6 - 12 weeks following the procedure, patients were allowed full weight-bearing activities with crutches while being supervised by a physiotherapist. Clinical follow-up was performed at six weeks, three months, one year and every year thereafter. Institutional Review Board (IRB) approval was received and the study was carried out in the context of national guidelines on the follow-up of metal-on-metal hip arthroplasty patients as part of clinical care evaluation. The study was performed according to the ethical standards of Gelre hospital and the Helsinki Declaration.

## Radiological analysis

Patients were investigated with an anteroposterior (AP) pelvic radiograph at every clinical visit. Radiographs were taken with the patient supine and the legs slightly abducted and internally rotated so the feet made a right angle with the toes touching. The beam source to detector distance was 100 cm and at 90° to the table; the beam centered at the pubic symphysis. All images were digitally acquired and sent to PACS (Picture Archiving and Communication System, Sectra, Linköping, Sweden). After five years patients were also investigated by hip ultrasound to assess the presence of a cystic or solid mass in the peri-prosthetic tissue due to an eventual ARMD defined by Langton, *et al* [6-8]. A CT scan was performed to analyze the position of the component and to identify the presence of osteolysis at five years follow-up [2]. CT scans were acquired on a Siemens AS 64 CT scanner (Siemens, Erlangen, Germany). The protocol used a collimation of 64 x 0,675 mm, 120 kV, 250 mAs and metal artifact reduction bone algorithm. Axial and coronal images parallel to the table surface with a slice thickness of 4 mm and a reconstruction interval of 3 mm, were calculated from the raw data set. Based on the images the acetabular cup inclination and version angles were measured on the optimal slice determined by scrolling through the stack of images, using optimal window width and level as determined by the radiologist.

The femoral component was considered to have radiological evidence of loosening if there was dislocation and/or a radiolucent line > 2 mm in any one of the three zones described by Amstutz, *et al* [4,9]. Acetabular loosening was recorded if there was a radiolucent line > 2 mm in two or more zones described by DeLee and Charnley and/or signs of dislocation [10,11]. Any osteolysis around the femoral or acetabular component was recorded. Thinning of the femoral neck was considered to be present if there was a greater than 10% reduction in the minimum width of the femoral neck adjacent to the margin of the femoral component on the x-ray when compared with the same dimension on the initial post-operative radiograph [11]. All images (CT, ultrasound and x rays) were interpreted by an experienced musculoskeletal radiologist. The radiologist was blinded to patient history and symptoms.

## Metal analysis

Whole blood samples were taken after five years to measure cobalt levels. Blood was collected in metal free tubes via Venflon (Becton Dickinson, Helsingborg, Sweden), discarding the first 5 mL. All samples were frozen and sent to an external specialized laboratory (Humicon B.V., Maastricht, the Netherlands) for blinded analysis of whole blood and serum cobalt (Co) levels using inductively coupled plasma mass spectroscopy (ICPMS) analysis [3]. A serum cobalt level of 85 nmol/L or greater was used as a cut-off level for a potential ARMD or failure [5,12-15].

### Statistical analysis

Statistical analysis was performed with SPSS Statistics v17.0 (SPSS Inc., Chicago, Illinois). Descriptive statistics were calculated, including median, frequency, and proportions. The primary endpoint of this study was a revision of either the femoral or acetabular component, or both, independent of its reason, but according to the guidelines of the Dutch Orthopaedic Association (NOV) [12]. Differences in cobalt levels between patients with an unilateral and a bilateral BHR were tested with the Mann Whitney U test. A p-value < 0.05 was considered to be statistically significant.

### Results

Patient demographics of the whole group are shown in table 1. During follow-up three patients died from unrelated causes without revision.

Number of patients n (hips)	57 (57 hips)	
Male n (%)	36 (63.2)	
Median age (yrs) (range)	53 (33.7 - 61.8)	
Median weight (kg) (range)	85 (45 - 133)	
Osteoarthritis of the hip n (%)	49 (86)	
Other diagnoses		
Avascular necrosis n (%)	4 (7)	
Dysplasia n (%)	4 (7)	
Median follow-up time yrs (range)	6.9 (5.1 - 10.4)	
Number of BHR revisions n (%)	5/56 (8.9)	1 lost to follow-up

**Table 1:** Patient demographics (whole group).

BHR: Birmingham Hip Resurfacing.

The cobalt levels of 52 patients (34 patients with unilateral BHR and 18 patients with bilateral BHR) were evaluated. In five patients cobalt analysis was not possible because of four patients did not reach the minimally five years of follow-up (one patient died, three patients due to revision) and one patient could not be traced and was lost to follow-up.

Six patients had no CT analysis because of lost to follow-up (one patient), not reaching the five years of follow up (four patients) and one patient had moved away and due to logistical reasons a CT was not possible.

At the time of the last follow-up, five patients (8.9%) underwent a revision of the BHR prosthesis. Two patients underwent a revision, respectively, four and seven weeks after the BHR procedure, both as a consequence of a femoral neck fracture. One female patient, with bilateral BHR, underwent a revision 3.7 years after the index operation because of femoral-loosening seen on pelvic x rays. During the revision operation of this patient, no signs of ARMD were seen. Another female patient needed a revision after 4.9 years because of pain and squeaking. The hip of one male patient, with a bilateral BHR, was revised 7.1 years after the index operation because of complaints of squeaking, high cobalt levels (2579 nmol/L) and abnormal findings on ultrasound and CT (synovial thickening). On revision, the hip showed no infection or ARMD but there was a large cup hole defect. The survival of the BHR hip for the entire cohort with any revision as the endpoint was 91.1%.

### Bilateral BHR

During follow-up time, 18 (31.5%) patients received a BHR prosthesis on the contra-lateral hip. Patient demographics are shown in table 2. Of these 18 bilateral BHR patients, two patients underwent a revision of the first BHR hip. One patient received a revision of the contra-lateral hip during follow-up.

Number of patients n	18
Male n (%)	11 (61.1)
Median age (yrs) (range)	51 (41.3 - 61.8)
Median weight (kg) (range)	93 (45 - 113)
Osteoarthritis of the hip n (%)	17 (94.4)
Other diagnoses	
Dysplasia n (%)	1 (5.6)
Median follow-up time yrs (range)	7.1 (3.7 - 9.4)
Number of BHR revisions n (%)	3/18 (16.7)

**Table 2:** Patient demographics (patients with bilateral BHR in whole group).  
BHR: Birmingham Hip Resurfacing.

**General complications**

One patient got an adjusted rehabilitation program of six weeks non-weight bearing, because of a fissure seen during the operation resulting in full recovery after six weeks. At follow-up one patient developed a myocardial infarction three days after the surgical procedure and fully recovered. There were no nerve injuries, infections, dislocations, or other general major medical complications. The occasionally reported symptoms on our outpatient clinic during follow-up were groin pain, complaints due to a bursitis, squeaking, stiffness, pain around buttocks, pain after walking, radicular pain and complaints of instability. These symptoms were mild and were most of the time self-limiting. When necessary, a conservative treatment with pain medication and/or physiotherapy was successful.

**Blood cobalt levels**

Table 3 shows the measured whole blood cobalt levels. The median cobalt level in the unilateral group was 28.8 nmol/L (12.0 - 230.8 nmol/L) and 47.5 nmol/L (17.0 - 2579.4 nmol/L) in the bilateral group (p = 0.004). There was one patient with an extreme high cobalt level (2579.4 nmol/L). This patient had a bilateral BHR device and complained of pain at one hip during follow-up and underwent a revision procedure with total hip arthroplasty with multihole cup, meshgraft and stem. During his last visit cobalt level was 60 nmol/L. There were no patients with abnormal ultrasound or CT scan findings with cobalt levels < 85 nmol/L.

Patient group	Elevated cobalt level (> 85 nmol/L)	No elevated cobalt level (< 85 nmol/L)
Number of patients	8	44
Bilateral	4	14
Men n (%)	4 (50%)	29 (65.9%)
Median cup diameter mm (range)	56 (50 - 60)	59 (48 - 64)
Median femoral diameter mm (range)	50 (42 - 54)	53 (42 - 58)
Median inclination	55° (47 - 69)	55° (34 - 68)
Median anteversion	28° (9 - 42)	26° (0.2 - 64)
Median cobalt level nmol/L (range)	182.3 (95.0 - 2579.4)	31.6 (12.0 - 73.0)
Number of patients with ARMD*	1 (12.5%)	0 (0%)
Number of symptomatic patients	3 (37.5%)	8 (18.2%)
Median age years (range)	57 (41 - 60)	52 (38 - 62)

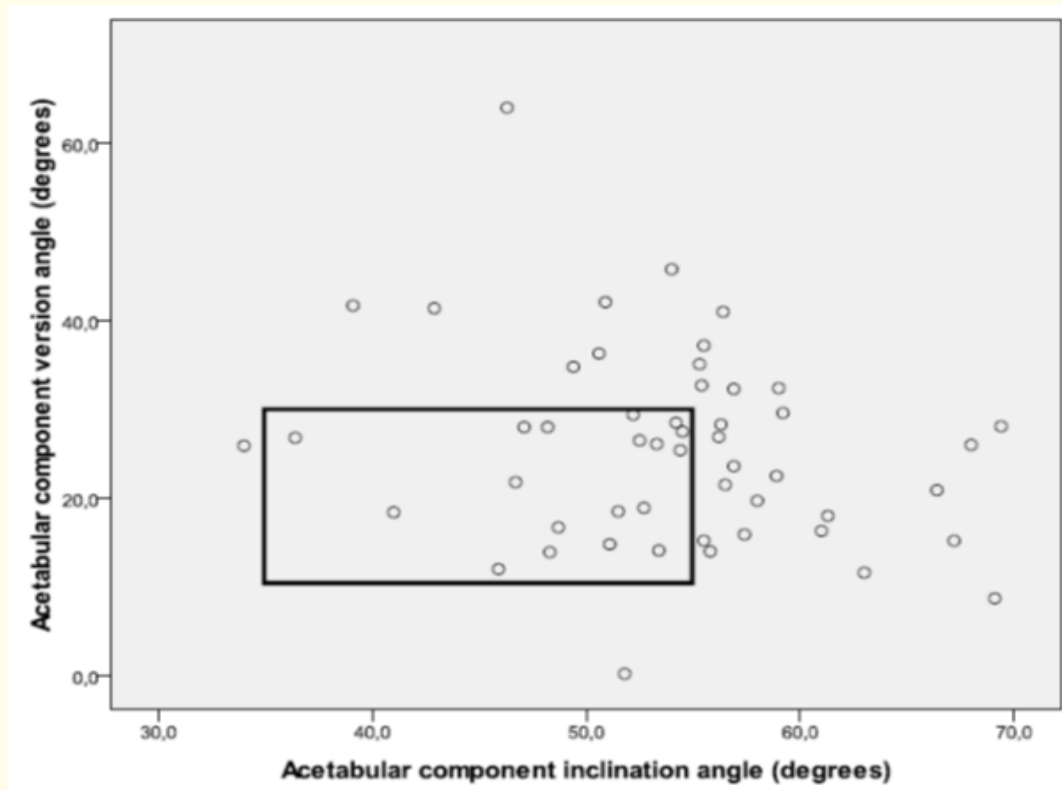
**Table 3:** Patients with elevated whole blood cobalt levels versus patients with no elevated cobalt levels 5 years after the first BHR procedure.  
\*ARMD: Adverse Reactions to Metal Debris Suspected on CT/Ultrasound.

**Radiological results**

Radiological evaluation of the orientation of the acetabular components in the whole group and symptomatic patients is shown in table 4. The position of the acetabular component was in the recommended safe-zone in 18 BHRs (35%) (Figure 1). Two patients had a femoral neck fracture, four and seven weeks after the first BHR implantation. Another patient showed femoral component loosening 3.7 years after BHR implantation. There were no patients with radiological evidence of thinning of the femoral neck or acetabular loosening. In two patients abnormalities were detected with ultrasound and CT. One of these patients showed synovial thickening and one patient showed on CT an abnormality suspected for ARMD. The patient suspected for synovial thickening underwent a revision because of pain and elevated cobalt levels. Furthermore it was this patient with the highest inclination angle (69.4°). The patient suspected for ARMD is asymptomatic and does not want a revision operation at the last follow-up and is under regular review.

	All	Symptomatic
Number of patients (hips)	51 (51)	11 (11)
Median inclination (range)	54.4° (34.0 - 69.4)	55.8° (48.2 - 66.4)
Median anteversion (range)	26.0° (0.2 - 64.0)	18.5° (11.6 - 45.8)

**Table 4:** Radiological evaluation acetabular component with CT analysis 5 years after first BHR procedure.



**Figure 1:** Visualization of number of Birmingham Hip Resurfacing hips in the safe zone (acetabular component inclination vs. anteversion measured with CT) with optimal zone (rectangle) for positioning as defined by Grammatopoulos, et al [24].

## Discussion

Hip resurfacing is considered by many to be an alternative to conventional total hip arthroplasty. There are advantages and drawbacks to any procedure, and there is a learning curve associated with the introduction of any new technology. This study showed a survival rate of 91.1% with BHR hips during the early experience of a high volume hip surgeon with a median follow-up of 6.9 years. This is in accordance with literature showing survival rates ranging from 73.9% to 92.5% in women and 87.1% to 100% in men with a mean follow-up ranging from 0.6 to 14 years [2,11,16]. Studies differ from each other through experience from the surgeon, used surgical approach and used hip resurfacing device. Unfortunately in our study not all patients have reached a follow-up time of ten years yet, so only midterm outcomes are presented.

Despite acceptable results there is still a debate going on if hip resurfacing should be used especially in the light of potentially risks. In literature short and long term complications are described. In our study the number of short term complications (dislocations, neck fractures and infections) is low. Long term complications such as ARMD and loosening are rare. As mentioned an important advantage of the BHR device is the lack of dislocations. Fracture of the femoral neck is unique to hip resurfacing arthroplasty and a common complication. This occurs in approximately 1% - 2% cases and most of the time within one year after the index procedure [7]. In our study two patients had a femoral neck fracture. Bone density measurements were normal and these patients were of normal weight (BMI between 18.5 - 25 kg/m<sup>2</sup>). Risk factors reported in literature are a reduced proximal femoral bone quality and the femoral component in varus position with notching of the superior part of femoral neck [7]. In our study notching of the femoral neck was the cause of fracture in the two cases.

This report used conventional x-ray, CT and ultrasound as radiologic analysis modalities. A Metal Artefact Reduction Sequence (MARS) MRI is an alternative option and we are aware that a CT scanning has the drawback of a high radiation exposure to the patient. However we have chosen for the combination CT and ultrasound to assess the presence of a cystic or solid mass in the peri-prosthetic tissue due to an eventual ARMD with ultrasound and to analyze the position of the component and to identify the presence of osteolysis with CT [2]. Bisschop, et al. found that MRI has no higher sensitivity than CT [2]. MARS MRI is good in detecting ARMD formation but is less capable to detect acetabular osteolysis and implant position [17].

Accurately measuring inclination of the acetabular component in hip resurfacing is important because a high inclination angle of the acetabular component in hip resurfacing is related to wear. However, how larger the head, the more forgiving is a high abduction angle. Wear is due to edge-loading and can result in high serum metal ion levels and ARMD [18-22]. Recent studies suggested that excessive anteversion of the cup may be an equally important factor but these findings are not consistently reproduced in studies [18,19,22-25]. Incorrect anteversion can also cause iliopsoas irritation, impingement, reducing range of motion, increased risk of fracture, dislocation and loosening [25-28]. Malpositioning of the femoral component may result in impingement and femoral neck fracture [29]. In order to minimize these risks it is recommend that surgeons implant the acetabular component at an inclination of 45 degrees (+/- 10) and anteversion of 20 degrees (+/- 10) on post-operative radiographs, the so called safe-zone [24]. The position of the acetabular component was in the recommended safe-zone in 35% of BHRs, with other studies reporting up to 88% of BHR acetabular components were implanted in this safe-zone [11]. Reasons for variety in these results are the early learning curve and experience of the surgeon.

Today we know that small heads, too much abduction of the acetabular component as well as too much anteversion, notching of the femoral neck and primary or secondary osteoporosis are a reason for failure. The best results are obtained with males with big heads with primary arthritis of the hip [30,31].

The last couple of years more and more concerns arise about local tissue reactions. These periprosthetic soft tissue lesions have been described variously as metallosis, aseptic lymphocytic vasculitis-associated lesions (ALVAL), adverse reaction to metal debris (ARMD) or adverse local tissue reaction (ALTR). In some cases, the local tissue reaction can be particularly aggressive and periprosthetic soft tissue masses relating to the joint, so called pseudotumors, can be found in patients with MoM hip resurfacing [2]. During follow-up there were two patients suspected of local soft tissue reactions according to ultrasound and CT images. In our study ARMD formation is until now not confirmed. One patient underwent a surgical revision and a large cup hole defect was seen. Other studies describe numbers ranging from 0.1% to 28% [2]. One of the known causes that promote ARMD is the malposition of the acetabular component, in particular with inclination angles greater than 55 degrees, which is also correlated with high serum cobalt ion levels [7,11,23]. Although one patient with a cup inclination angle of 69.4° showed a large cup hole defect and high cobalt levels, our study group is too small and the incidence of ARMD too low for confirmation of this relation by our study results. Another limitation of our study was that we used no histology confirmation at patients with a revision procedure and a suspected ARMD on CT and/or ultrasound. Only macroscopic observations were described but no clear ARMD was seen.

Fifty-two patients gave blood samples to measure cobalt ion levels, but a clear effect on outcome remains unclear. It is known that increased serum levels of cobalt and chromium are markers of wear rates of bearing surfaces [2,14]. Levels of 118.7 nmol/L or greater have been identified as having the potential for soft tissue reaction [14]. Hart, et al. suggested 4.94 ppb (= 84.3 nmol/L) cobalt and chromium levels as a useful diagnostic test for discrimination of poor from well-functioning metal-on-metal hip replacements [15]. The Dutch Orthopaedic Association (NOV) uses 85 nmol/L as an elevated value with elevated risk for ARMD [12]. In a recent multicenter validation study, Metharu, et al. confirmed that patients with a blood metal ion level below an implant-specific threshold have a low risk of ARMD after MoM hip arthroplasty [30]. Using these implant specific thresholds fewer patients with ARMD were missed. Implant-specific blood metal ions thresholds are therefore recommended [32]. High metal levels alone are not necessarily an indication for revision, although cardiac and neurological toxicity of cobalt has been described [2].

Patients in our study with very high serum ion levels, however, were at risk of having abnormalities on ultrasound and/or CT scan and had abnormal implant positioning (cup inclination > 55°, anteversion < 10° or > 20°). Our findings support results from Langton, et al. who also described this relationship, but our study group is too small to describe a clear relationship [6,11]. Like other authors we think that cobalt levels can be used as screening instrument and not necessary implying a revision. Further diagnostic measurements to rule out ARMD or abnormal positioning of the prosthesis are recommended in these cases [2]. Furthermore limitations of this study are the retrospective character and a relatively small number of patients. Another limitation is the lack of functional outcome measurements, for example the Harris Hip Score (HHS). For this reason we could not make reliable conclusions for functional outcome after a follow-up of at least five years. This is important because only using "revision of the BHR hip for any reason" as an endpoint is debatable.

### Conclusion

This study revealed a survival of 91.1% at a median follow-up of 6.9 years in a consecutive series of 57 patients (57 hips) who underwent hip resurfacing arthroplasty with the BHR system by one orthopaedic surgeon during his learning curve. Although the clinical outcome is favorable the patients are being kept under regular review as the long-term effects of elevated metal ion levels in the blood remain uncertain. Radiological analysis is the most important tool to investigate possible long term complications such as loosening and ARMD. Longer follow-up is necessary to analyze survivorship of the BHR.

### Conflict of Interest

SGM Weenders, RJLL van de Kimmenade, HJ van der Zaag-Loonen, PHJ Bullens and E Breemans declare that they have no conflict of interest.



## Bibliography

1. Van Der Straeten C., *et al.* "Metal ion levels from well-functioning Birmingham Hip Resurfacings line significantly at ten years". *Bone and Joint Journal* 95B.10 (2013): 1332-1338.
2. Bisschop R., *et al.* "High prevalence of pseudotumors in patients with a Birmingham Hip Resurfacing prosthesis: a prospective cohort study of one hundred and twenty-nine patients". *Journal of Bone and Joint Surgery-American Volume* 495.17 (2013): 1554-1560.
3. Holland JP., *et al.* "Ten-year clinical, radiological and metal ion analysis of the Birmingham Hip Resurfacing: from a single, non-designer surgeon". *Journal of Bone and Joint Surgery-British Volume* 94.4 (2012): 471-476.
4. Treacy RB., *et al.* "Birmingham hip resurfacing: a minimum follow-up of ten years". *Journal of Bone and Joint Surgery-British Volume* 93.1 (2011): 27-33.
5. Van Der Straeten C., *et al.* "The 2012 Otto Aufranc Award: The interpretation of metal ion levels in unilateral and bilateral hip resurfacing". *Clinical Orthopaedics and Related Research* 471.2 (2013): 377-385.
6. Langton DJ., *et al.* "Early failure of metal-on-metal bearings in hip resurfacing and large-diameter total hip replacement: A consequence of excess wear". *Journal of Bone and Joint Surgery-British Volume* 92.1 (2010): 38-46.
7. Scaglione M., *et al.* "Metal-on-metal hip resurfacing: correlation between clinical and radiological in assessment, metal ions and ultrasound findings". *Musculoskeletal Surgery* 99.1 (2015): 45-53.
8. Mont MA and Schmalzried TP. "Modern metal-on-metal hip resurfacing: important observations from the first ten years". *Journal of Bone and Joint Surgery-American Volume* 90A.3 (2008): 3-11.
9. Amstutz HC., *et al.* "Metal on metal hybrid surface arthroplasty: two to six year follow up study". *Journal of Bone and Joint Surgery-American Volume* 86A (2004): 28-39.
10. DeLee JG and Charnley J. "Radiological demarcation of cemented sockets in total hip replacement". *Clinical Orthopaedics and Related Research* 121 (1976): 20-32.
11. Mehra A., *et al.* "Birmingham Hip Resurfacing: A Single Surgeon Series Reported at a Minimum of 10 Years Follow-Up". *Journal of Arthroplasty* 30.7 (2015): 1160-1166.
12. Dutch Orthopaedic Association 2015, 1 ust. Advies Metaal-op-Metaal Heupprothesen per 1 ustus (2015).
13. Langton DJ., *et al.* "The clinical implications of elevated blood metal ion concentrations in asymptomatic patients with MoM hip resurfacings: a cohort study". *BMJ Open* 3.3 (2013): e001541.
14. Tai SM., *et al.* "Two-year serum metal ion levels in minimally invasive total conservative hip resurfacing: preliminary results of a prospective study". *ANZ Journal of Surgery* 85.3 (2015): 164-168.
15. Hart AJ., *et al.* "Sensitivity and specificity of blood cobalt and chromium metal ions for predicting failure of metal-on-metal hip replacement". *Journal of Bone and Joint Surgery-British Volume* 93.10 (2011): 1308-1313.
16. Azam MQ., *et al.* "Survivorship and clinical outcome of Birmingham hip resurfacing: a minimum ten years' follow-up". *International Orthopaedics* 40.1 (2016): 1-7.
17. Waldstein W., *et al.* "MRI does not detect acetabular osteolysis 350 around metal-on-metal Birmingham THA". *Archives of Orthopaedic and Trauma Surgery* 134.7 (2014): 1009-1015.



18. Westacott DJ, *et al.* "Assessment of cup orientation in hip resurfacing: a comparison of TraumaCad and computed tomography". *Journal of Orthopaedic Surgery and Research* 8 (2013): 8.
19. Hart AJ, *et al.* "Cup inclination angle of greater than 50 degrees increases whole blood concentrations of cobalt and chromium ions after metal-on-metal hip resurfacing". *HIP International* 18.3 (2008): 212-219.
20. Hart AJ, *et al.* "The relationship between the angle of version and rate of wear of retrieved metal-on-metal resurfacings: a prospective, CT-based study". *Journal of Bone and Joint Surgery-British Volume* 93.3 (2011): 315-320.
21. Kwon YM, *et al.* "Analysis of wear of retrieved metal-on-metal hip resurfacing implants revised due to pseudotumours". *Journal of Bone and Joint Surgery-British Volume* 92.3 (2010): 356-361.
22. Langton DJ, *et al.* "The effect of component size and orientation on the concentrations of metal ions after resurfacing arthroplasty of the hip". *Journal of Bone and Joint Surgery-British Volume* 90.9 (2008): 1143-1151.
23. De Haan R, *et al.* "Revision of metal-on-metal resurfacing arthroplasty of the hip: the influence of malpositioning of the components". *Journal of Bone and Joint Surgery-British Volume* 90.9 (2008): 1158-1163.
24. Grammatopoulos G, *et al.* "Optimal acetabular orientation for hip resurfacing". *Journal of Bone and Joint Surgery-British Volume* 92.8 (2010): 1072-1078.
25. Desy NM, *et al.* "Surgical variables influence metal ion levels after hip resurfacing". *Clinical Orthopaedics and Related Research* 469.6 (2011): 1635-1641.
26. Cyteval C, *et al.* "Iliopsoas impingement on the acetabular component: radiologic and computed tomography findings of a rare hip prosthesis complication in eight cases". *Journal of Computer Assisted Tomography* 27.2 (2003): 183-188.
27. Kluess D, *et al.* "Limited range of motion of hip resurfacing arthroplasty due to unfavorable ratio of prosthetic head size and femoral neck diameter". *Acta Orthopaedica* 79.6 (2008): 748-754.
28. Malik A, *et al.* "Impingement with total hip replacement". *Journal of Bone and Joint Surgery-American Volume* 89.8 (2007): 1832-1842.
29. Kitada M, *et al.* "Validation of the femoral component placement during hip resurfacing: a comparison between the conventional jig, patient-specific template, and CT based navigation". *International Journal of Medical Robotics* 9.2 (2013): 223-229.
30. Matharu GS, *et al.* "The future role of metal-on-metal hip resurfacing". *International Orthopaedics* 39.10 (2015): 2031-2036.
31. Medicines and Healthcare products Regulatory Agency (MHRA). Medical device alert: Metal-on-metal (MoM) hip replacements - guidance on implantation and patient management (2015).
32. Matharu GS, *et al.* "Blood Metal Ion Thresholds to Identify Patients with Metal-on-Metal Hip Implants at Risk of Adverse Reactions to Metal Debris: An External Multicenter Validation Study of Birmingham Hip Resurfacing and Corail-Pinnacle Implants". *Journal of Bone and Joint Surgery-American Volume* 99.18 (2017): 1532-1539.

**Volume 9 Issue 11 November 2018**

**©All rights reserved by Stefan GM Weenders, *et al.***