

The Significance of Ultrasound in Juvenile Distal Forearm Fractures

Ekkehard Pietsch*

Consultant Orthopaedic and General Surgeon, The-Expert-Witness.de, Hamburg, Germany

***Corresponding Author:** Ekkehard Pietsch, Consultant Orthopaedic and General Surgeon, The-Expert-Witness.de, Hamburg, Germany.

Received: July 20, 2018; **Published:** September 26, 2018

Abstract

The distal forearm fracture is with a share of 30% one of the most common fracture in children [1]. Still today, X-rays are considered to be the gold standard in diagnosing the injury. Studies with focus on Ultrasound examination could prove a higher sensitivity and specificity for the diagnosis of distal forearm fractures making it a safe and reliable means of diagnosing bony injuries. We reviewed cases where the diagnosis of a fracture was supported by Ultrasound and cases that could have even been missed on standard X-rays.

Keywords: *Ultrasound; Paediatric Forearm Fractures*

Introduction

Fractures to the metaphysis of the distal forearm are common [2]. The gold standard in confirming the diagnosis are X-ray views in two planes of the wrist. However, there is a growing number of research that provides evidence that Ultrasound is a safe and reliable tool in making the diagnosis too [3-5]. It can be even used to give a good estimate of the extent of the deformity [6] or as parameter for the reduction of dislocated fractures. Fritz-Niggli [7] argued that X-rays create a 10 fold morbidity risk in children than in adult patients and concluded that the indication for the application of radiation needs to be critically reviewed in every single case [8-10]. The quality of the Ultrasound scans allows good visualisation of bony injuries, which makes it a valuable assessment tool. The objective of this article is to encourage the physician to use the potential of ultrasound examination as a safe tool in the diagnosis of suspected forearm fractures.

Material and Methods

We enclosed children into the study with an acute trauma to the distal forearm and suspicion of a fracture. All children underwent a physical examination followed by an Ultrasound examination through the same orthopaedic surgeon. The ultrasound examination used a 7.5- MHz linear array transducer in the standard 6 positions. For completion of the investigations, anteroposterior and lateral x-rays were requested. Findings were evaluated through the examining surgeon.

Results

In total, 101 patients between 4 and 16 years of age were recruited with an average age of 11 years at the time of the trauma. We found 51 fractures to the distal radius in 86 cases, 9 injuries involved the distal ulna, and 6 were combined injuries of the radius and ulna. 32 of the injuries showed as greenstick fractures. Ultrasound examination and prediction for a fracture reached a specificity and sensitivity of 99.5%.

The Cases

Case 1

An 8-year old boy played football as goal keeper. He tried to catch a ball that was shot from a short distance. His wrist was forcefully hyperextended. He complained of immediate pain and restricted movements. On examination, he presented a fusiform swelling over the

distal forearm but no gross deformity. Pain on palpation of the distal radius and a loss of function suggested a bony injury. The Ultrasound examination could show an impaction of the cortex over the posterior metaphysis. His X-ray confirmed the diagnosis. He was placed in a cast before X-ray to avoid the X-ray control after the confirmation of the diagnosis and cast manipulation.

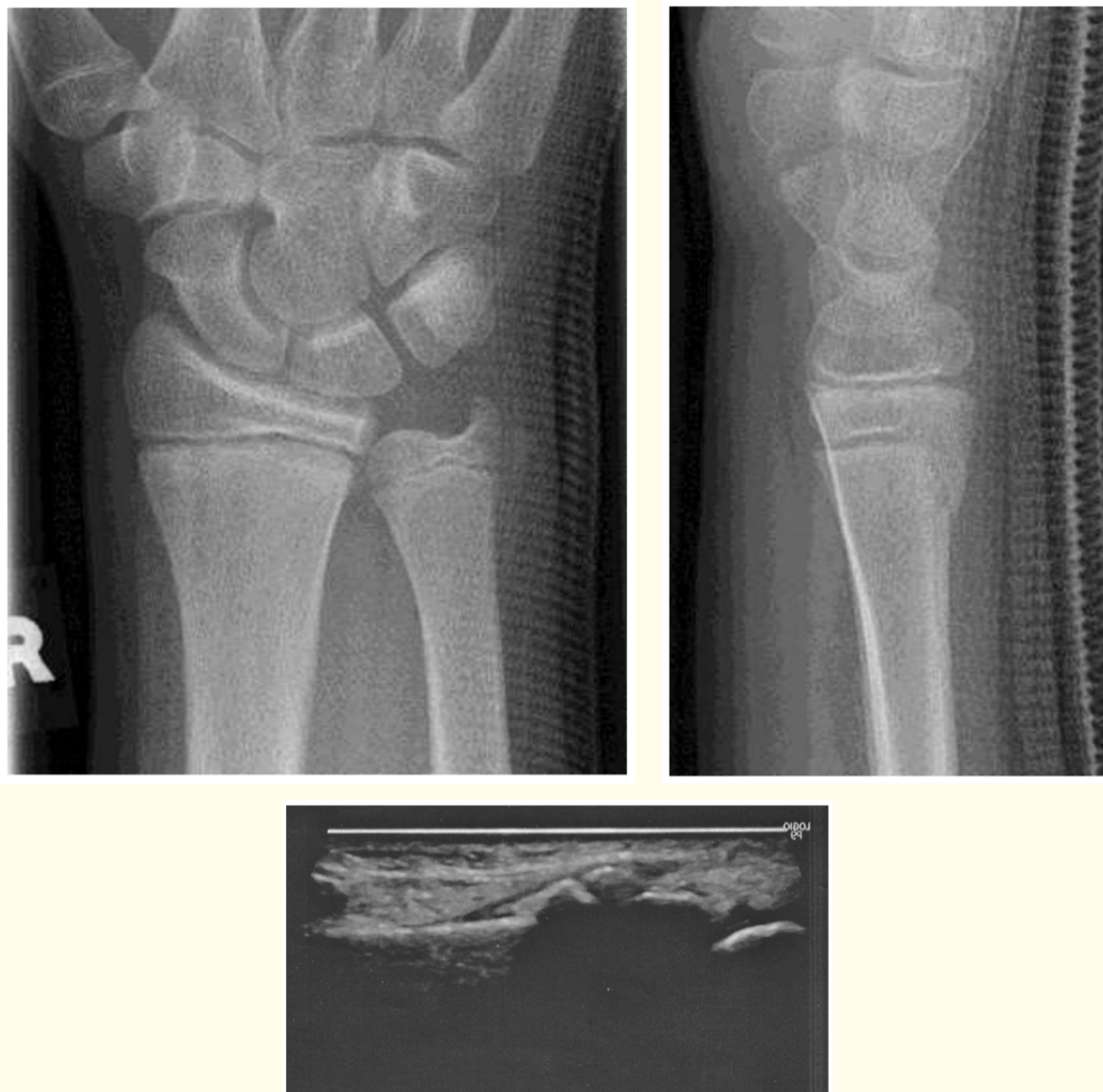
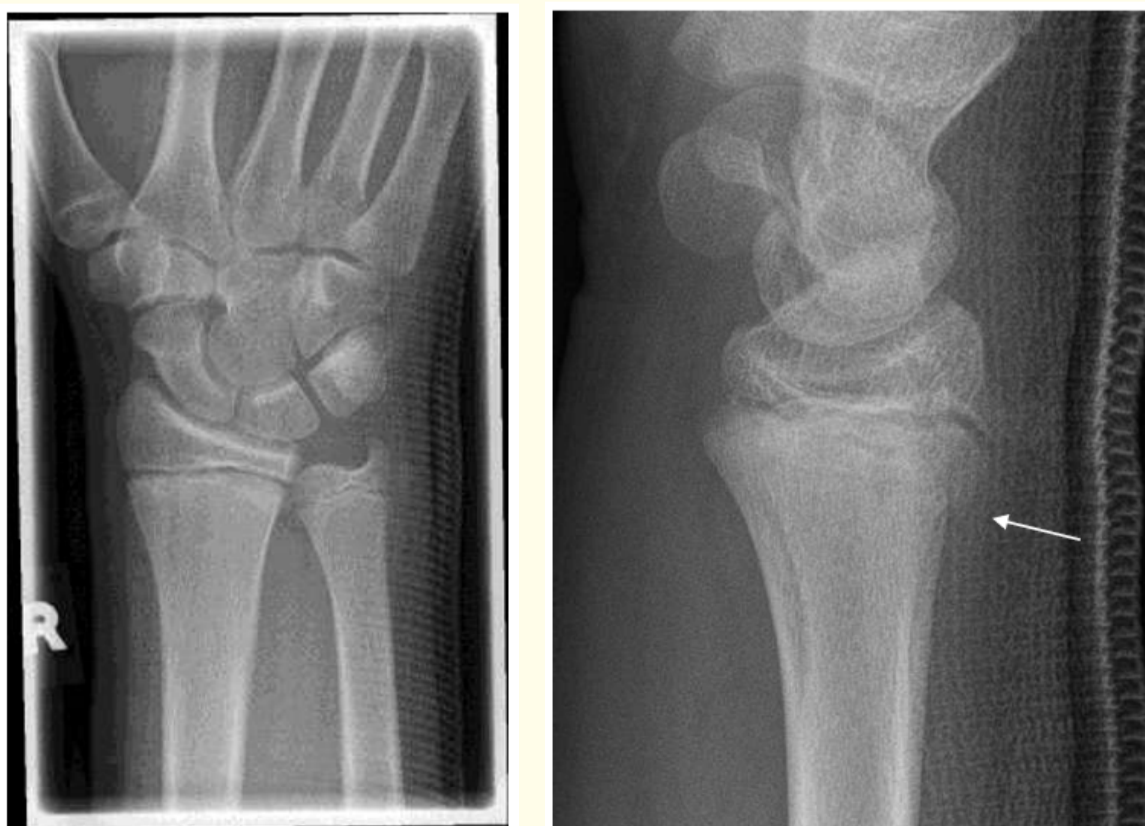
Figure 1

Case 2

An eight-year old girl fell onto her forearm whilst ice skating. She presented with mild soft tissue swelling to the distal third of the radial sided forearm. Active movements were possible but restricted at the extreme of palmar and dorsi flexion. On examination, she indicated pain on palpation of the distal radius metaphysis. There was no palpable deviation or step. Ultrasound showed a buckle in the distal third of the radius with minimal to nil deformity. X-rays confirmed the fracture as found on Ultrasound.



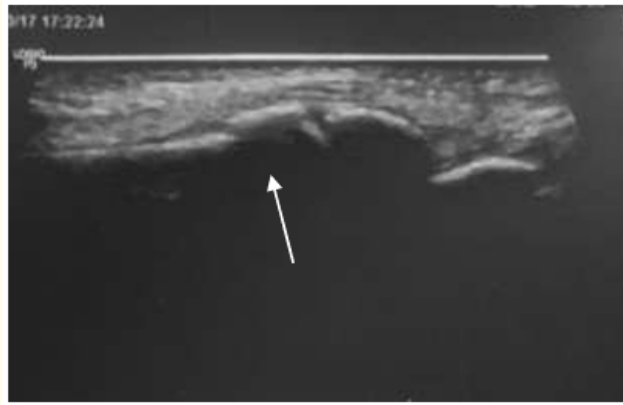


Figure 2: The Ultrasound shows a cortical fragment extending from the metaphysis.

Case 3

An 11-year old girl fell whilst inline skating onto her wrist a day ago. She developed painful restrictions but no relevant soft tissue swelling. Her mother wanted to wait and see what would happen. The examination revealed only little soft tissue swelling with an intracutaneous coloration. The wrist was painful on palpation of the distal radius but without noticeable deformity or step.

X-rays rose suspicion with a positive fat pad sign and a possible cortical angulation over the dorsal aspect of the metaphysis.

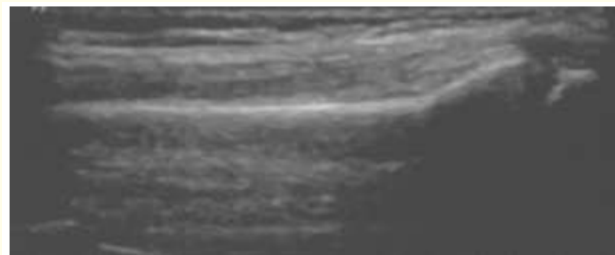
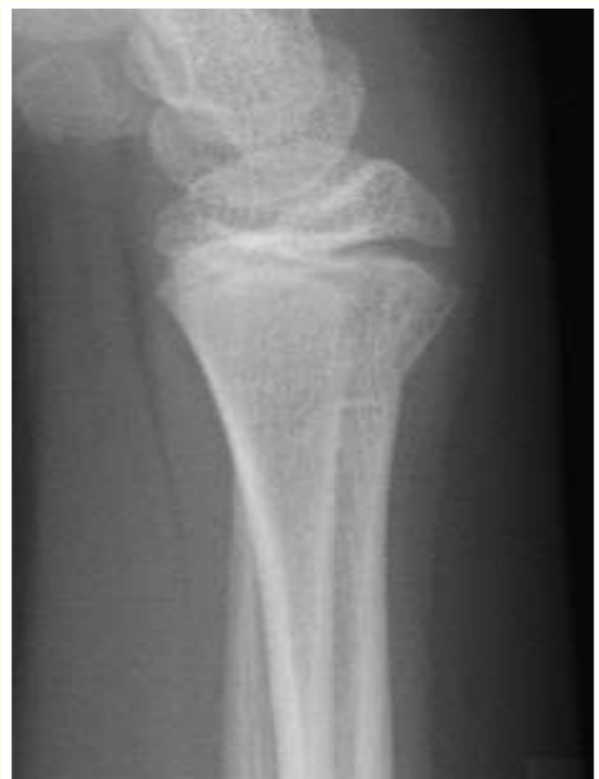
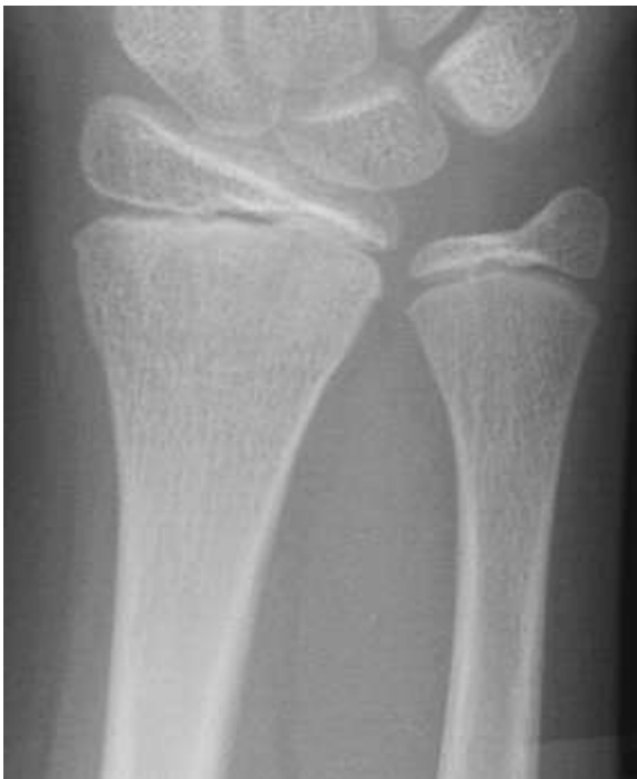
Figure 3: The Ultrasound shows a slight cortical angulation but no frank fragment.

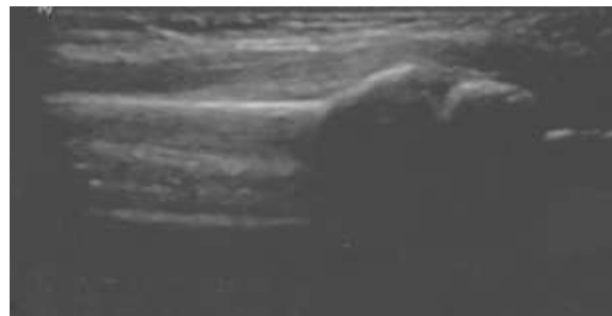


Figure 4: However, a different angle makes the angulation more noticeable.

Case 4

A 16-year-old boy fell whilst trampolining and injured his wrist. He attended casualty on the following afternoon. He complained of an increasing stiffness and pain in his wrist movements. On examination, he had a localised lentiform soft tissue swelling and tenderness over the radial aspect of his wrist with limited movements.

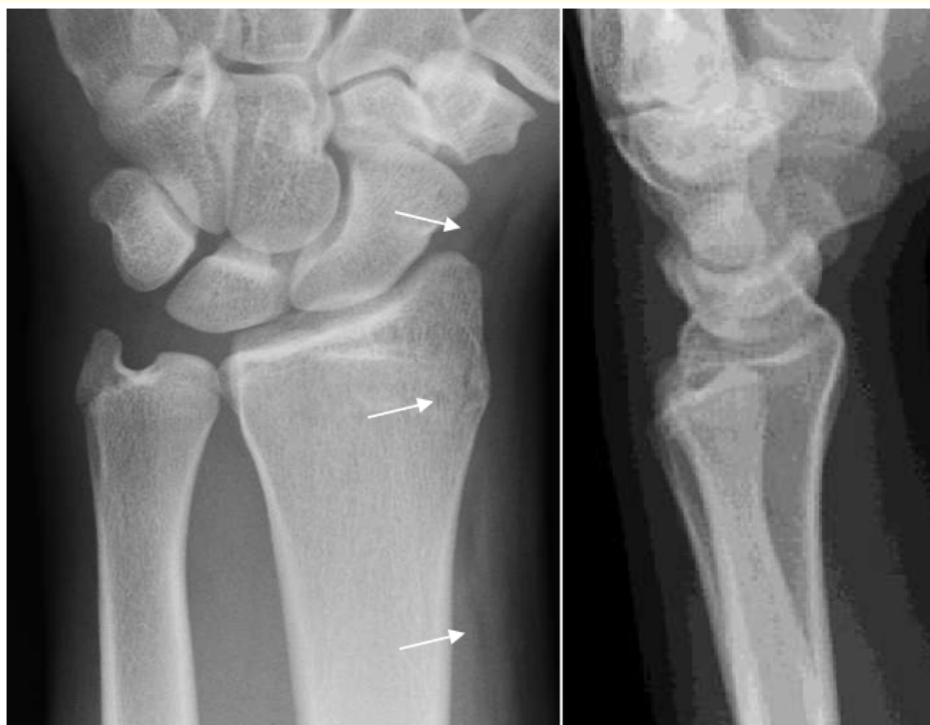

Figure 5

X-rays reveal some cortical irregularity over the radial styloid and soft tissue swelling. The Ultrasound, in contrast, highlights a complex cortical injury.

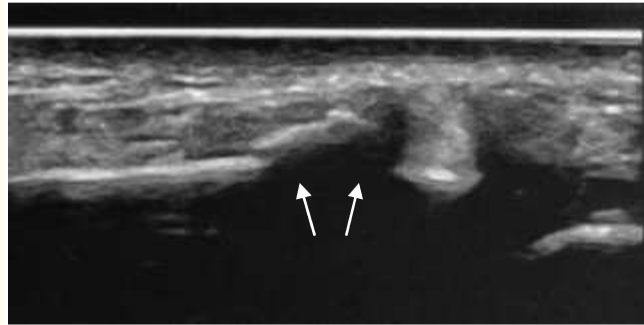

Figure 6: Ultrasound with cortical fragmentation and some displacement.

X-rays reveal some cortical irregularity over the radial styloid and soft tissue swelling. The Ultrasound, in contrast, highlights a complex cortical injury.

Case 5

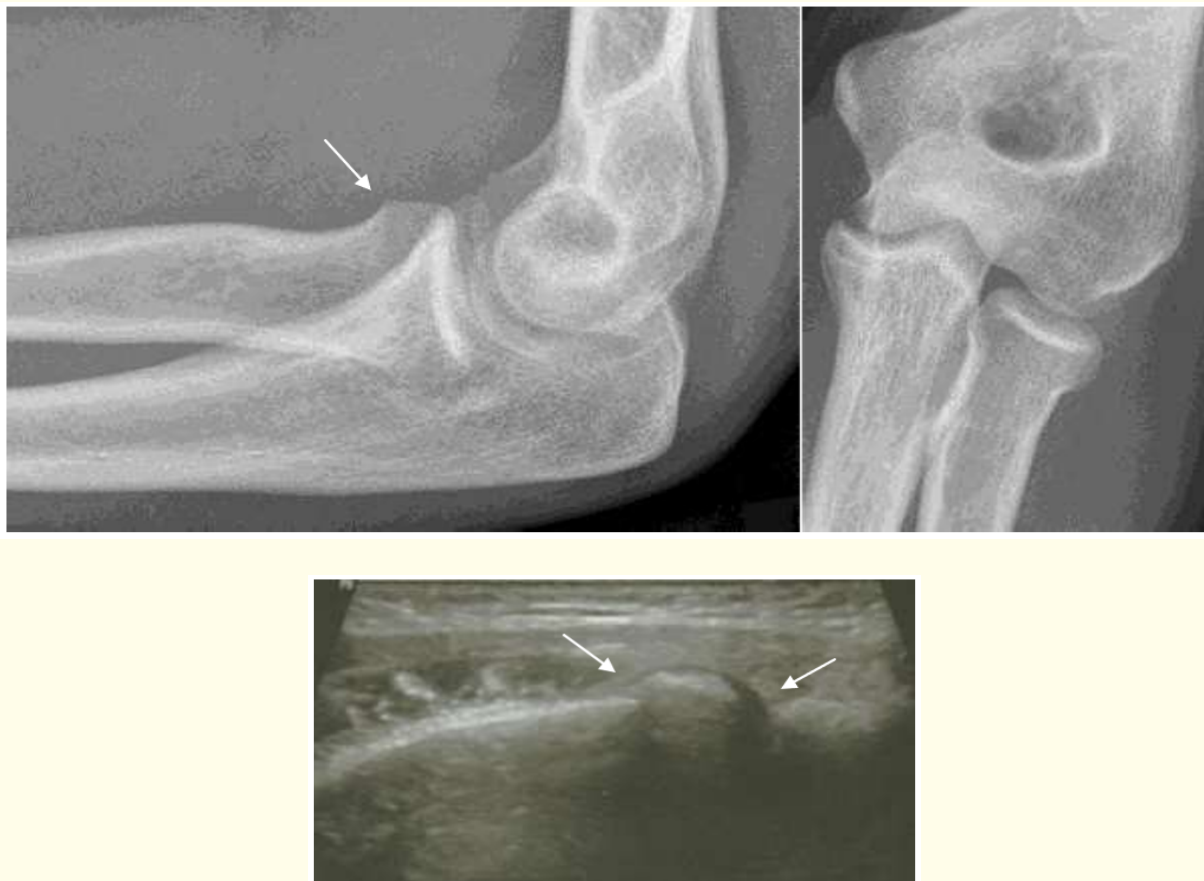

Figure 7

A 16-year-old fell from her bicycle on her outstretched wrists. She complained of symptoms in her left elbow and shoulder. Whilst the shoulder appeared to be unharmed, the elbow presented with a puffy swelling over the lateral epicondyle. She was tender to touch over the radial head on pro- and supination and painful to move into deep flexion.

X-rays require a high suspicion and show on the lateral view a cortical irregularity over the anterior aspect of the radial head. The ap view appears unremarkable.

The Ultrasound, in contrast, detects a cortical disruption in the junction of the radial neck and a small joint effusion indicating the fracture.

Discussion

Studies evaluating the diagnostic accuracy of sonography in forearm fractures have been carried out in the paediatric population. Techniques are known as FAST POCUS. It is an acronym for a “focused assessment with sonography for trauma” and was initially used for the assessment of the abdomen and heart. POCUS, in contrast, is known as “point of care ultrasound” and focuses on areas of interest, in our cases the painful forearm. It was found that the sensitivity of our US examination for distal radius fractures was 100%.

The gold standard of diagnostic tests, however, is still the X-rays examination in these studies. X-ray imaging is considered as reliable, as false negative results have not been reported. However, their sensitivity seems low [11,12]. Hedelin [13] confirmed that missed fractures on X-rays could be identified with Ultrasound. However, it appears that X-rays are more sensitive for detecting ulna fractures [5,14-19].

With a sensitivity of almost 100%, Herren [20] suggested that a negative result in ultrasound may reduce the need for further radiographs in children with distal forearm lesions. But in any doubtful situation, the need for conventional radiographs should remain.

The advantage of Ultrasound examination is the variable number of angles that can be applied whereas X-rays usually provide only two planes. Thus, pathologies in the interim junction can be visualised that would be possibly missed on films (Case 4 and 5). Even subtle changes, e.g. minor angulations become more obvious during the examination (Case 3). It can also give the correct diagnosis ahead of the X-ray imaging, which can enable the doctor to apply a cast and use the X-ray for diagnostic reason and as control post casting (Case 1 and 2). Thus, further radiation exposure can be avoided.

Sivrikay [21] found false positive results in radius fractures. The authors discussed that the Lister tubercle may be misinterpreted as cortical disruption similar to a displaced fracture of the radius on the longitudinal axis. Emergency physicians should therefore be aware of potential false positive results with their sonographic examination.

Conclusion

US examination has excellent sensitivity for the diagnosis of distal radius fractures and appears superior in detecting cortical irregularities. With the Ultrasound, emergency physicians have an excellent and non-invasive tool for detecting obscure fractures in young patients with distal forearm trauma. Ultrasound can close the gap between high clinical suspicion and a questionable or even unremarkable X-ray and reduce the number of missed fractures.

Bibliography

1. Hart ES., *et al.* “Broken bones: common pediatric fractures-part I”. *Orthopaedic Nursing* 25.4 (2006): 251-256.
2. von Laer L., *et al.* “Frakturen und Luxationen im Wachstumsalter”. Stuttgart, New York: Thieme (2007).
3. Durston W and Seartzentruber R. “Ultrasound guided reduction of pediatric forearm fractures in the ED”. *American Journal of Emergency Medicine* 18.1 (2000): 72-77.
4. Rathfelder F and Paar O. “Einsatzmöglichkeiten der Sonographie als diagnostisches Verfahren bei Frakturen im Wachstumsalter”. *Der Unfallchirurg* 98 (1995): 645-649.

5. Williamson D., *et al.* "Ultrasound imaging of forearm fractures in children: a viable alternative?" *Journal of Accident and Emergency Medicine* 17.1 (2000): 22-24.
6. Hehl G., *et al.* "Posttraumatische Beinlangendifferenzen nach konservativer und operativer Therapie kindlicher Oberschenkelfrakturen". *Der Unfallchirurg* 96 (1993): 651-655.
7. Niggli H. "Strahlengefährdung und Strahlenschutz: Ein Leitfaden für die Praxis". Bern, Stuttgart, Toronto: Huber (1988).
8. Beir (Committee on the biological effects of ionising radiation). "The effects on population of exposure to low levels of ionizing radiation". Washington DC: National Academy of Sciences National Research Council (1980).
9. Fletcher EW., *et al.* "The risk of diagnostic radiation of the newborn". *British Journal of Radiology* 59.698 (1986): 165-170.
10. Wolf K., *et al.* "Bildgebende Verfahren und Strahlenschutz in der Unfallchirurgie". *Der Unfallchirurg* 99.12 (1996): 975-985.
11. Jørgsholm P., *et al.* "The benefit of magnetic resonance imaging for patients with posttraumatic radial wrist tenderness". *Journal of Hand Surgery* 38.1 (2013): 29-30.
12. Balci A., *et al.* "Wrist fractures: sensitivity of radiography, prevalence, and patterns in MDCT". *Emergency Radiology* 22.3 (2015): 251-256.
13. Hedelin H., *et al.* "Minimal training sufficient to diagnose pediatric wrist fractures with ultrasound". *Critical Ultrasound Journal* 9.1 (2017): 11.
14. Chaar-Alvarez FM., *et al.* "Bedside ultrasound diagnosis of nonangulated distal forearm fractures in the pediatric emergency department". *Pediatric Emergency Care* 27.11 (2011): 1027-1032.
15. Eckert K., *et al.* "Sonographic diagnosis of metaphyseal forearm fractures in children: a safe and applicable alternative to standard x-rays". *Pediatric Emergency Care* 28.9 (2012): 851-854.
16. Ackermann O., *et al.* "Ultrasound diagnosis of forearm fractures in children: a prospective multicenter study". *Unfallchirurg* 112.8 (2009): 706-711.
17. Chen L., *et al.* "Diagnosis and guided reduction of forearm fractures in children using bedside ultrasound". *Pediatric Emergency Care* 23.8 (2007): 528-531.
18. Javadzadeh HR., *et al.* "Diagnostic value of bedside ultrasonography and the water bath technique in distal forearm, wrist, and handbone fractures". *Emergency Radiology* 21.1 (2014): 1-4.
19. Kozaci N., *et al.* "Evaluation of the effectiveness of bedside point-of-care ultrasound in the diagnosis and management of distal radius fractures". *American Journal of Emergency Medicine* 33.1 (2015): 67-71.
20. Herren C., *et al.* "Ultrasound-guided diagnosis of fractures of the distal forearm in children". *Orthopaedics and Traumatology: Surgery and Research* 101.4 (2015): 501-505.
21. Sivrikaya S., *et al.* "Emergency physicians performed Point-of-Care-Ultrasonography for detecting distal forearm fracture". *Turkish Journal of Emergency Medicine* 16.3 (2016): 98-101.

Volume 9 Issue 10 October 2018

©All rights reserved by Ekkehard Pietsch.