

## Platelet-Rich Plasma Therapy for Scaphoid Fracture Nonunion

**Mourad Mekaouche<sup>1\*</sup>, Mustapha Merabet<sup>2</sup> and Houari Koriche<sup>2</sup>**

<sup>1</sup>Medical Office Bio-Orhtopedic and Rehabilitation, Oran, Algeria

<sup>2</sup>Radiologist, Ennadjah Clinic, Oran, Algeria

**\*Corresponding Author:** Mourad Mekaouche, Medical Office Bio-Orhtopedic and Rehabilitation, Oran, Algeria.

**Received:** June 22, 2018; **Published:** July 26, 2018

### Abstract

Scaphoid fractures are the most common fractures of the carpus, accounting for 80% of all carpal fractures. These fractures are frequently seen in young adults. Patients with scaphoid fractures most often present with wrist pain and tenderness. The pain of scaphoid fracture may progressively decrease, even in the absence of consolidation leading to scaphoid non-union. A vascularized bone graft and fixation with a screw is recommended for scaphoid nonunion without arthritis. When significant degenerative changes are already in place, palliative surgery such as proximal row carpectomy, limited or complete wrist arthrodesis is indicated.

We report the case of scaphoid fracture nonunion in a 17 year Young teenager. The patient was treated with platelet-rich plasma injection under ultrasound guidance. The final MRI and CT showed complete healing of the scaphoid.

**Keywords:** Platelet-Rich Plasma Therapy; Scaphoid Fracture

### Introduction

Scaphoid fractures are the most common fractures of the carpus, accounting for 80% of all carpal fractures. These fractures are frequently seen in young adults. Patients with scaphoid fractures most often present with wrist pain and tenderness. Sometimes, the pain is completely absent, which explains the late diagnosis at the stage of nonunion, carried incidentally on a radiograph requested during a second trauma, long after the initial accident.

Non-treated scaphoid nonunion induces carpal misalignment, osteoarthritis and collapse of the carp.

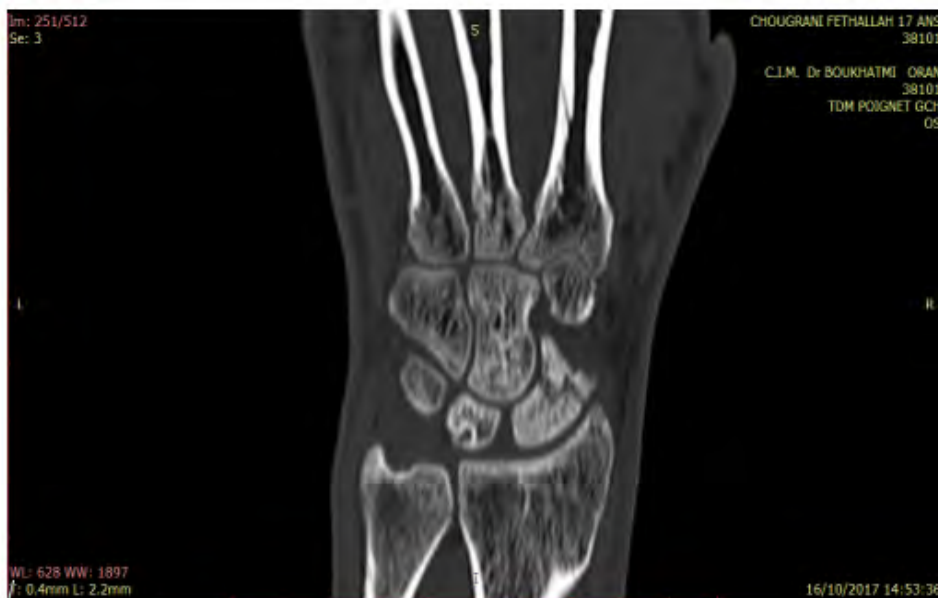PRP is a biological product defined as a portion of the plasma fraction of autologous blood with a platelet concentration above the baseline. The PRP by promoting natural healing becomes a promising alternative to surgery.

This case reports on the efficacy of PRP for the treatment of delayed unions of scaphoid bone compared with surgical bone grafting techniques. The PRP gave a complete revascularization with attachment of the 02 fragments leading to a total healing of his lesion. Confirmed by radiological follow-up (CT and MRI).

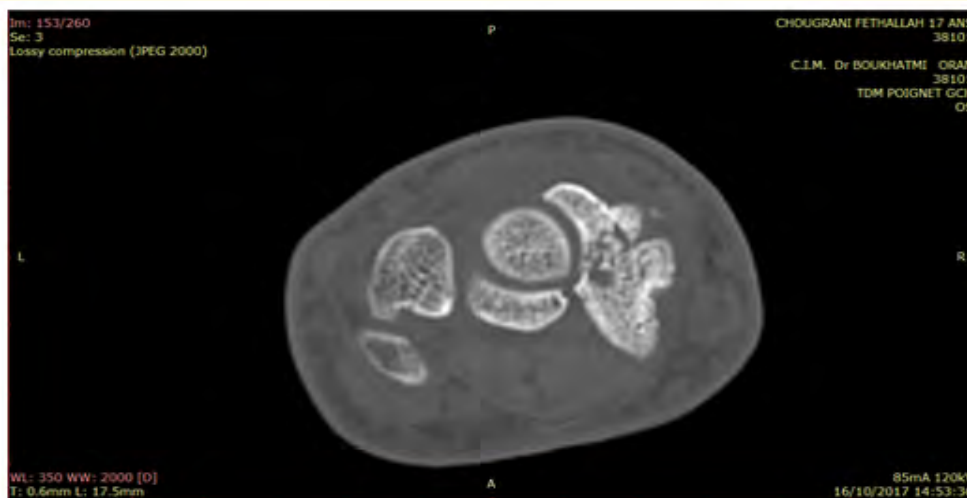
### Presentation of the Case

Young teenager aged 17, victim of a left wrist injury occurring during a motorcycle accident on 15/04/2017. The initial radiology of the painful left wrist is considered normal.

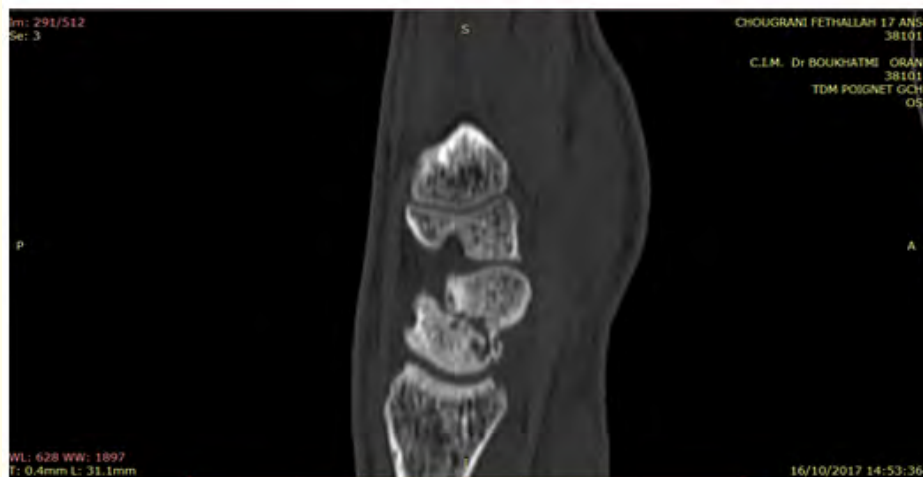After 6 months, the patient still complaining of pain decided to consult an orthopedist who requested a scan on 16/10/2017 (Figure 1). The CT scan found a Scaphoid nonunion fracture with focal necrosis of the proximal pole. The surgeon proposes surgery (internal fixation with bone graft).



Sagittal View left wrist



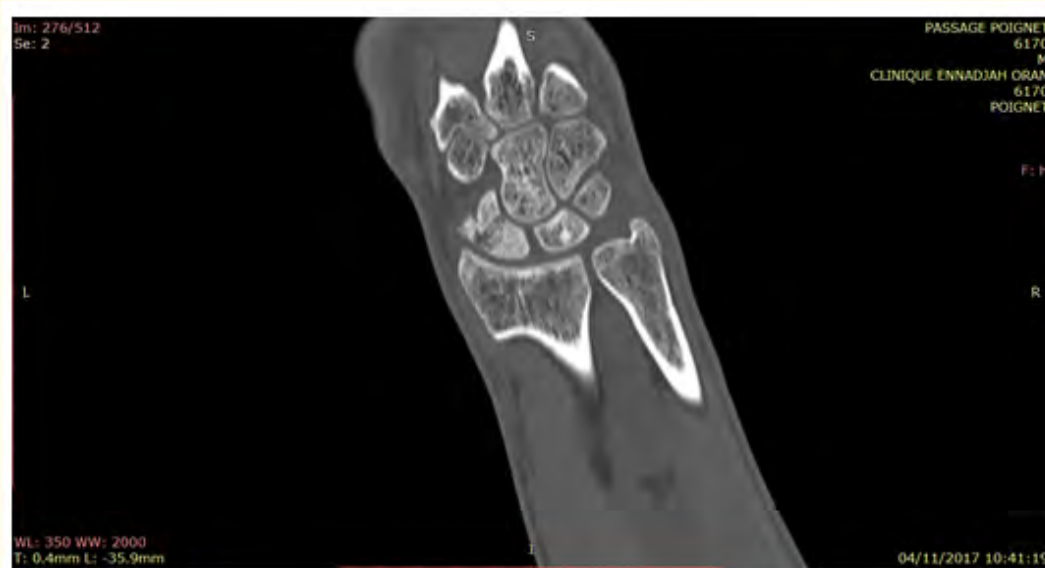Axial view left wrist



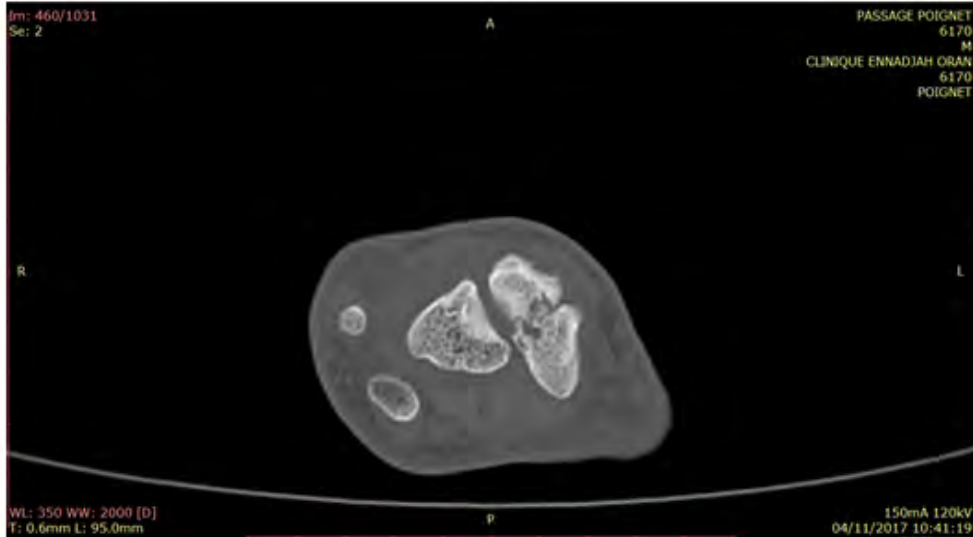
Coronal View left wrist

**Figure 1:** Scaphoid nonunion fracture type 2a (classification according to Alnot) Focal necrosis of the proximal pole.

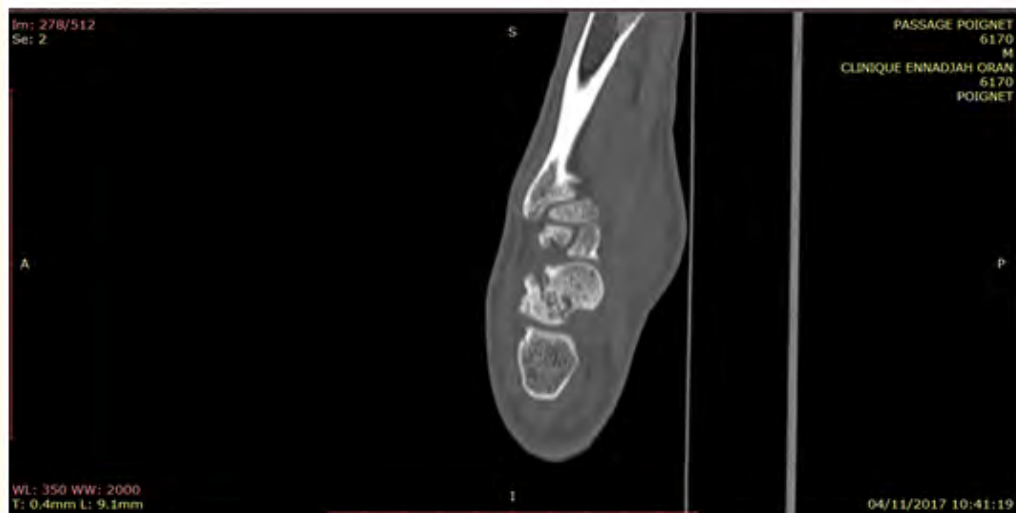The father who is of the medical body (nurse) to avoid the surgery decides to try complete immobilization. A new radiological assessment (a second CT scan and an MRI) dating from 04/11/2017 (Figure 2) finds a stationary state: Scaphoid nonunion fracture identical to the radiological assessment of 16/10/2017.



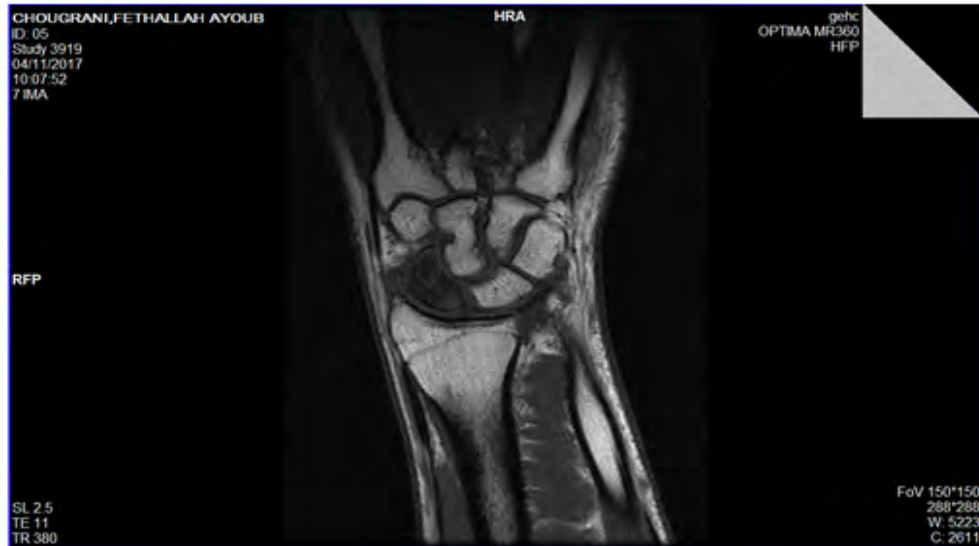Sagittal view left wrist



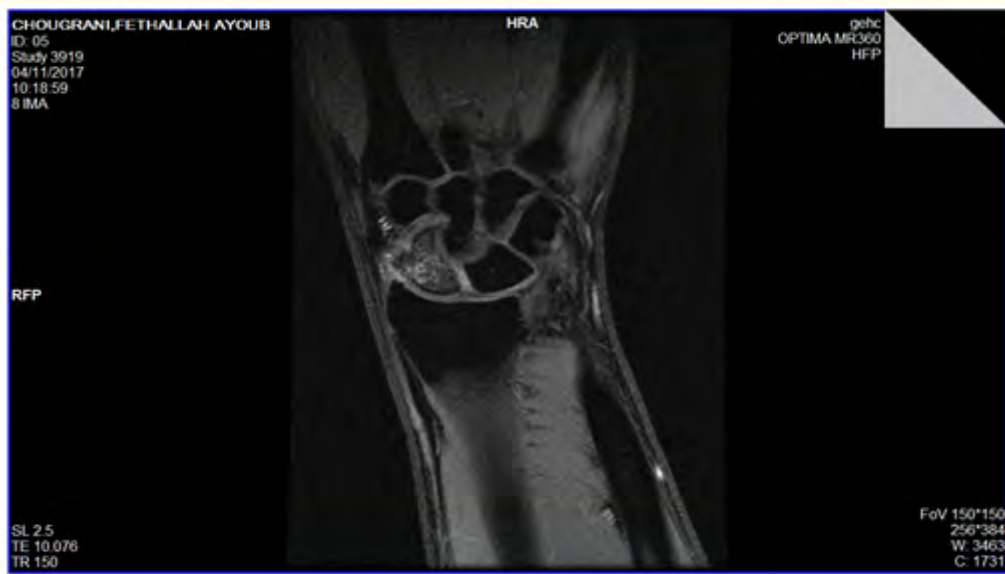*Axial view left wrist*



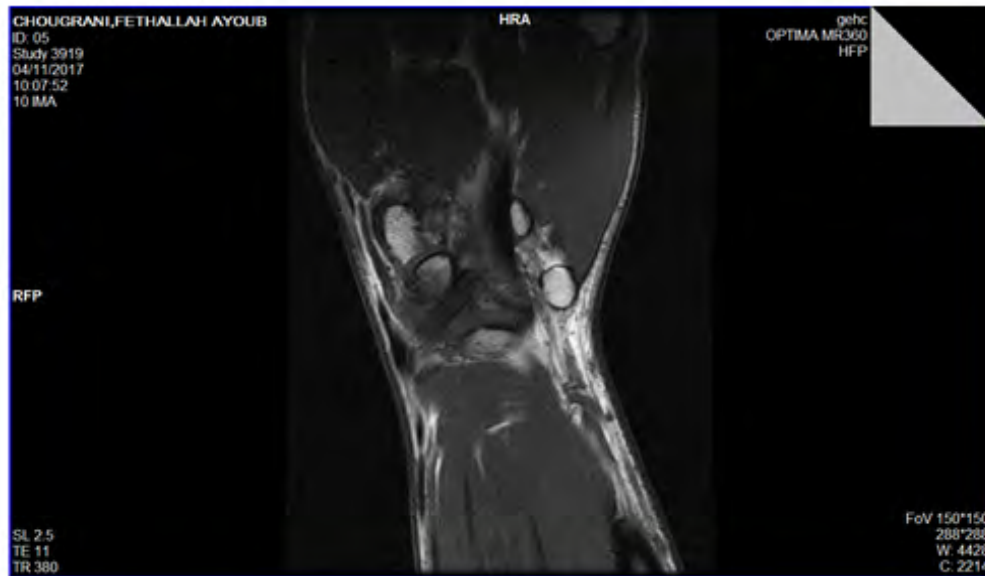
*Coronal view left wrist*



*Focal necrosis of the proximal pole*



*Poor vascularization of the proximal fragment in gadolinium sequence*



*Validity of the distal fragment*

**Figure 2:** Second CT scan and MRI demonstrated no response to immobilization treatment. Persistence of the fracture line with geodes 1-2-3.

**PRP Session 12/11/2017**

The patient received an injection of 5 ml of prolotherapy (dextrose 25%) under ultrasound guidance on the dorsal surface of the wrist at:

- The fracture
- The scapho-lunar ligament
- The articular radio-carpal space.

Thereafter, the patient was injected with 5 ml PRP (PRP was prepared after collecting 20 ml of venous blood from the patient and centrifuged at 400g for 10 minutes). The PRP was injected under ultrasound guidance to the dorsal aspect of the wrist at level:

- The fracture
- The scapho-lunar ligament
- The articular radio-carpal space.

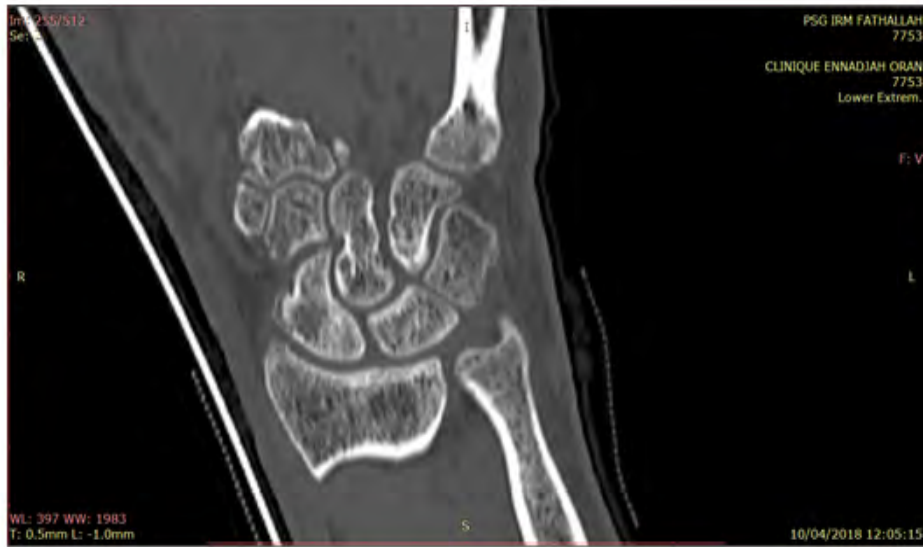After the PRP, the patient received 5 cc of ozone at 20 µg/ml, injected in the same way, as prolotherapy and PRP.

The wrist was rested in a splint for 03 months

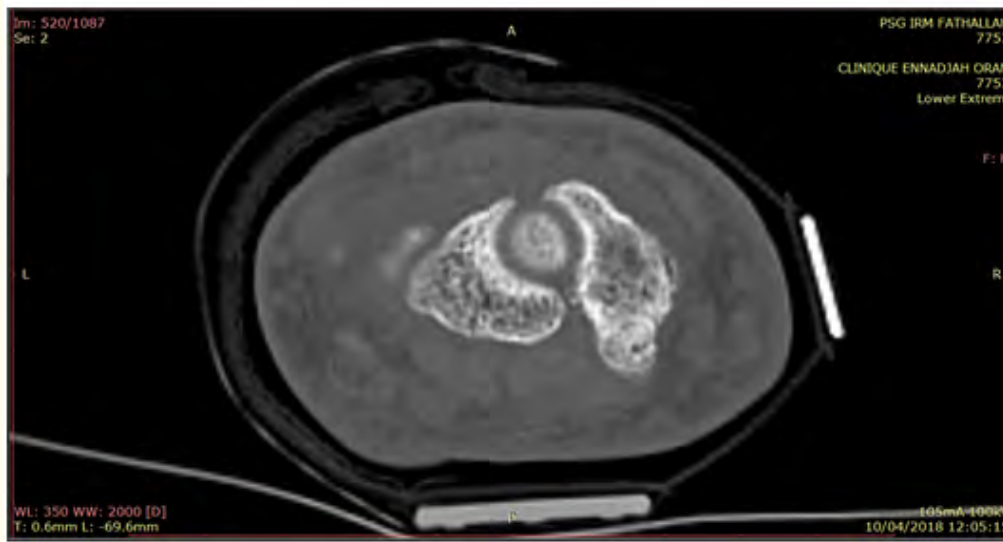
**Patient Follow-Up 10/04/2018**

The patient was reviewed with his radiological assessment.

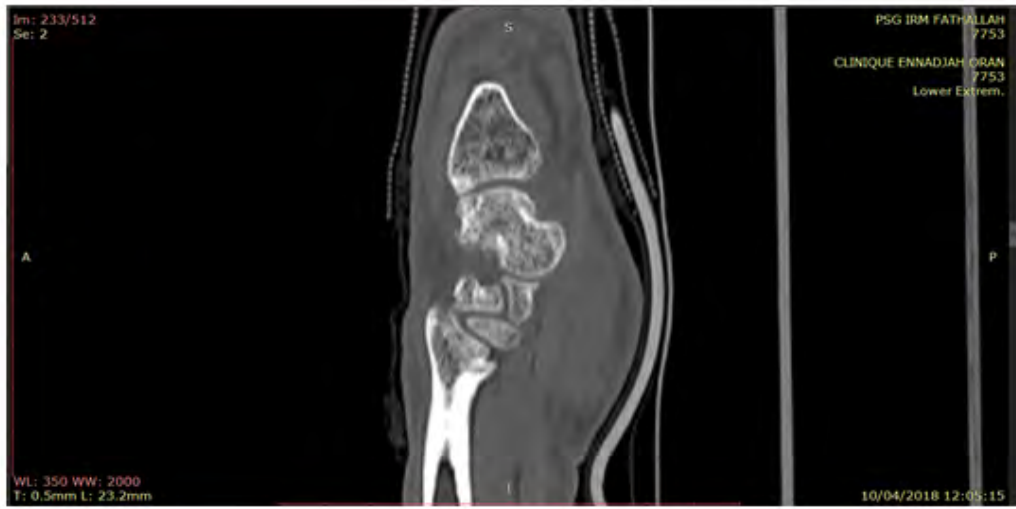
Final MRI and CT scan showed complete revascularization of the fragment and attachment of 100% with healing of the ventral scapho-lunate ligament



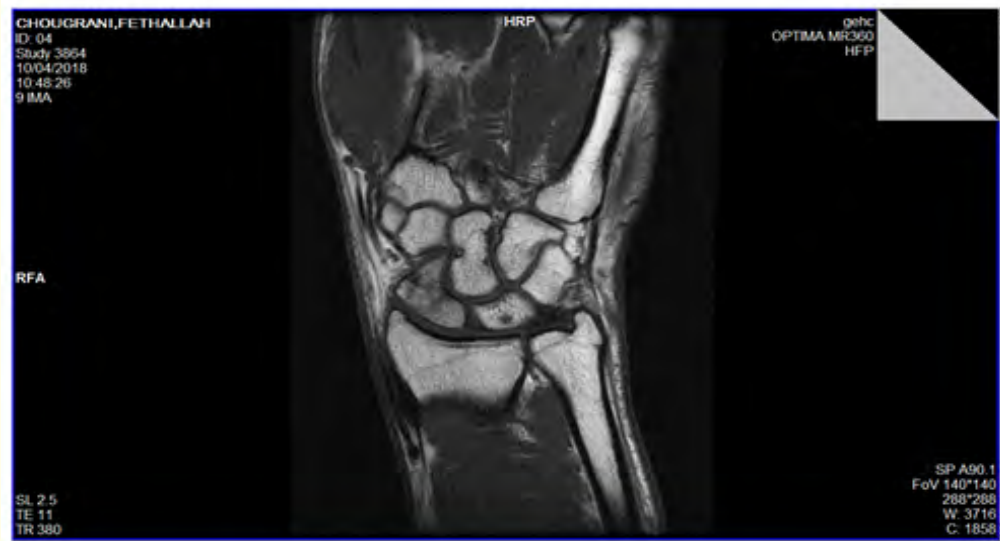Sagittal view left wrist



Axial view left wrist

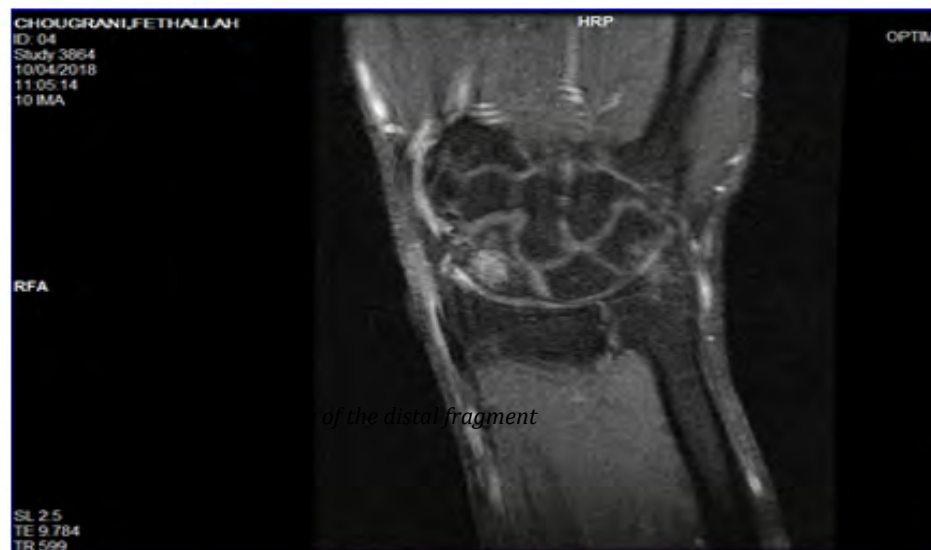

Coronal view left wrist



Restoration of the normal morphological aspect in MRI





*Complete revascularization of the proximal fragment*

**Figure 3:** Final CT scan and MRI attachment of 100%.

## Discussion

The intermediate position of the carpal scaphoid, between the first and second row, partly explains its high susceptibility to trauma. The pain of scaphoid fracture may progressively decrease, even in the absence of consolidation leading to non-union. The vascularization of the scaphoid belonging to the Gelberman I group (recurrent and terminal); It comes from two branches of the radial artery, which do not communicate with each other. The main vascularization penetrates the bone by its distal slope. This vascular arrangement explains the relative fragility of the bone and the difficulties encountered in achieving fracture consolidation, especially of the proximal pole (on the radius side) [1]. The scaphoid nonunion progressively lead to a distortion of carp in DISI, osteoarthritis and then collapse of the scaphoid (wrist SNAC). The incidence of osteonecrosis of the scaphoid reaches 30 to 40% with scaphoid nonunion.

Scaphoid nonunion is characterized by reorganization of the fracture site presenting a fibrosclerotic and necrotic tissue preventing any consolidation.

Surgery is the only recognized treatment for scaphoid nonunion fracture.

If the carp does not show signs of degenerative arthritis, a standard or vascularized bone graft can be considered, with or without internal fixation. However, if degenerative arthritis is present, a limited or complete wrist arthrodesis remains a life-saving solution for a stable and painless wrist. Alternatively, proximal denervation neurectomy of the anterior or interosseous nerve (AIN) and posterior interosseous nerve (PIN) may also be proposed [2,3].

Preoperative evaluation of the vitality of the proximal pole is a major issue. Standard radiography, CT scan bone or scintigraphy unfortunately does not allow characterizing its vascularization. It seems that only sequences with gadolinium injection are reliable for predicting failure or success of bone grafting. The T1 and T2 weighted sequences remain contradictory.

The success rate is 100% when the contrast enhancement is intense and homogeneous. It is 89% when it affects 50 to 80% of the proximal fragment and 75% when it affects only 20 to 50% of the proximal fragment. It falls to 0% in the absence of contrast enhancement. The lack of enhancement of the proximal fragment after intravenous Gadolinium injection is indicative of pedicular grafting [4-6].

In regenerative medicine, preoperative evaluation of the vitality of the proximal pole could be used as one of the prognostic elements for the therapeutic choice (Prolotherapy, plasma rich in platelets, stem cells or the combination of techniques).

Platelets Rich Plasma has been used for traumatic non-union fractures after failure of surgery with controversial results [7,8]. Autologous percutaneous bone marrow injections have been used with promising results [9].

This case is our first experience with the use of PRP as a biological treatment for a delayed union fracture without prior surgery. We used PRP in osteochondritis of the knee with a very good result [10]. To our knowledge, this is the first study of the effect of PPR as a first-line therapy for delayed union fracture. In this particular case, the patient has benefited from the addition of prolotherapy and ozonotherapy.

We believe that the success of regenerative medicine will probably come from the application not of a single element, but by the combination of several elements [11]. A treatment sequence could be envisaged in which each element involved could target a part of the regeneration process [12]. Prolotherapy consists of injecting a small volume of solution, mainly dextrose with solutions ranging from 12.5% - 25%, into several sites of painful insertions of the ligaments, tendons and adjacent articular spaces. Prolotherapy will create an inflammatory process, promoting the repair and growth of new tissue [13].

PRP is an autologous blood product with high activated platelet concentrations containing considerable amounts of platelet derived growth factor (PDGF), vascular endothelial growth factor (VEGF), epidermal growth factor (EGF), fibroblast growth factor (FGF) and transforming growth factor (TGF- $\beta$ 1, TGF- $\beta$ 2) which are responsible for repair and granulation tissue formation in human body [14]. Ozone is a highly soluble gas with great oxidizing activity. Medical ozone (O<sub>2</sub>-O<sub>3</sub> mix) appears to behave as a bioregulator when it comes into contact with a biological liquid, releasing factors from human endothelial cells and normalizing the cellular redox balance [15]. Ozone concentrations below 20  $\mu$ g/ml do not alter the properties and results of PRP when used in combination [16].

Platelet-rich plasma injection provides a very safe and easy alternative to bone grafting in the treatment of scaphoid fracture non-union. Despite the contradictory results, the reduced cost of its preparation protocol, sometimes even very simple and easy, has encouraged its therapeutic use to stimulate tissue healing and bone regeneration. But there is still a need for more research on the restorative capacity of the PRP. We are convinced that the application of PRP will improve the healing of fracture nonunion by allowing bone repair without surgery.

### Conclusion

Scaphoid surgery is a justified intervention in the event of a scaphoid nonunion fracture following an old trauma with a painful wrist. The results are often good, but complications are possible and progression to osteoarthritis cannot be ruled out. PRP promoting safe and natural healing is a promising alternative to surgery. There are few controlled trials. However, several clinical trials are underway to solve this type of problem. In the future, the PRP could change the current management.

## Bibliography

1. Gelberman RH and Menon J. "The vascularity of the scaphoid bone". *Journal of Hand Surgery* 5.5 (1980): 508-513.
2. Kawamura K and Chung KC. "Treatment of scaphoid fractures and nonunions". *Journal of Hand Surgery* 33.6 (2008): 988-997.
3. Scott P Steinmann and Julie E. Adams "Scaphoid fractures and nonunions: diagnosis and treatment". *Journal of Orthopaedic Science* 11.4 (2006): 424-431.
4. Smith M., et al. "Review of imaging of scaphoid fractures". *ANZ Journal of Surgery* 80.1-2 (2010): 82-90.
5. Fox MG., et al. "Accuracy of enhanced and unenhanced MRI in diagnosing scaphoid proximal pole avascular necrosis and predicting surgical outcome". *Skeletal Radiology* 44.11 (2015): 1671-1678.
6. A Blum., et al. "Le diagnostic des fractures récentes du scaphoïde : revue de la littérature". *Journal de Radiologie* 88.5-C2 (2007): 741-759.
7. Fariborz Ghaffarpasand., et al. "Platelet Rich Plasma for Traumatic Non-Union Fractures: A Novel but Controversial Bone Regeneration Strategy". *Bulletin of Emergency and Trauma* 1.3 (2013): 99-101.
8. Say F., et al. "Is platelet-rich plasma injection an effective choice in cases of non-union?" *Acta Chirurgiae Orthopaedicae et Traumatologiae Cechoslovaca* 81.5 (2014): 340-345.
9. Bielecki Tomasz., et al. "The application of bone marrow aspirate concentrate (BMAC) enrich in stem cells, growth factors and other active substances for the scaphoid delayed union treatment". *Journal of Orthopaedics Trauma Surgery and Related Research* 2.39 (2016): 16-21.
10. Mourad Mekaouche., et al. "Platelet-Rich Plasma Therapy for Osteochondritis Dissecans". *Journal of Prolotherapy* 9 (2017): e978-e981.
11. Molloy T., et al. "The roles of growth factors in tendon and ligament healing". *Sports Medicine* 33.5 (2003): 381-394.
12. Gracer RI and Bocci V. "Can the combination of localized "proliferative therapy" with "minor ozonated autohemotherapy" restore the natural healing process?" *Medical Hypotheses* 65.4 (2005): 752-759.
13. Vora A., et al. "Regenerative injection therapy for osteoarthritis: fundamental concepts and evidence-based review". *PM&R* 4.5 (2012): S104-S109.
14. Steven P Arnoczky., et al. "What Is Platelet-Rich Plasma?" *Operative Techniques in Sports Medicine* 19.3 (2011): 142-148.
15. E Iliakis., et al. "Is Medical Ozone Safe when Injected Intra-articularly? A Comparative Histological Study in Rat". *International Journal of Ozone Therapy* 7 (2008).
16. Anitua E., et al. "Ozone dosing alters the biological potential and therapeutic outcomes of plasma rich in growth factors". *Journal of Periodontal Research* 50.2 (2015): 240-247.

**Volume 9 Issue 8 August 2018**

**© All rights reserved by Mourad Mekaouche., et al.**