

Axilla Suspension with Local Island Skin Flap Prevents Skin Transplant Shrinkage and Recurrence of Postburn Shoulder Total Adduction Contracture: New Method

Viktor M Grishkevich*

Department of Reconstructive and Plastic Surgery, A.V. Vishnevsky Institute of Surgery of the Russian Academy of Medical Sciences, Moscow, Russia

***Corresponding Author:** Viktor M Grishkevich, Department of Reconstructive and Plastic Surgery, A.V. Vishnevsky Institute of Surgery of the Russian Academy of Medical Sciences, Moscow, Russia.

Received: March 29, 2018; **Published:** July 27, 2018

Abstract

Background: During extensive burns of the shoulder joint area, shoulder stays in an adduction position, and a small island of healthy skin can be preserved in the axillary apex. Wound scarring results in total contracture formation treatment which presents a challenge for surgeons since skin transplants shrink and contracture recurs. Elevation of a larger flap for donor wound covering leaves soft tissue defect. These factors indicate that a new, more effective technique is needed.

Methods: In 21 patients with severe shoulder adduction contractures, caused by extensive scars, a small island skin was preserved in the axillary fossa's apex. Axilla was covered with contracted scars; it descended, and its contours were smoothed. It was proposed that a complete contracture release and stable axilla suspension would prevent axilla displacement down and skin shrinkage would not cause re-contracture. For axilla suspension, the island skin was chosen in the form of a subcutaneous pedicle flap the ends of which were connected with the edges of the wound at the joint axillary axis level, and the large wound was divided into two separate wounds: shoulder and thoracic.

Results: In all 21 patients the island skin of axilla was used as a subcutaneous pedicle flap. After contracture release, the flap's ends were connected with wound edges at the level of the joint rotation axis anteriorly and posteriorly. Because of the flap's tension, the axilla edges approached, the tissues of the joint extension surface (E) were displaced on joint flexion lateral surfaces, and soft tissues were squeezed. These factors allowed stably suspend axilla and divided the large wound into two: shoulder and thoracic which were skin grafted or covered with local tissues. It was determined that the suspension of the axilla by the island skin subcutaneous pedicle flap and division of the large wound into two (shoulder and thoracic) prevented skin graft shrinkage and contracture recurrence. In all cases, contractures were released completely, and the axillary contours were restored with time. No flap loss or contracture recurrence was observed. Skin transplants shrinkage was minimal and had no effect on the flap's position. Contraction of skin grafts was compensated by neighboring soft tissues' displacement on wounds.

Conclusion: The newly developed low-traumatic effective technique was used for treatment of severe (total) shoulder adduction contracture by prevention of shrinkage of skin transplants using the axilla suspension by a subcutaneous pedicle flap prepared from the axillary island skin. Excellent functional and good cosmetic results made grounds for recommending this method for treatment of shoulder severe contractures where an island of skin was preserved in the axillary fossa apex.

Keywords: *Shoulder Scar Contracture; Axillary Contracture Treatment; Anatomy of Axillary Scar Contracture; Axillary Island Skin; Skin Graft Shrinkage Prevention*

Highlights

1. Total shoulder adduction contracture treatment presents a challenge for surgeons since skin transplants shrink and contracture recurs.
2. Donor sites for regional flaps are often scarred.
3. The article presents a new method that allows prevention of skin transplants shrinkage and contracture recurrence.

Introduction

The scar shoulder adduction contracture is the most frequent (38%) among the big joint contractures caused by burns [1]. Deep and vast burns of the shoulder joint region cause the most severe contracture or total, making up 14% of total number in which the scars cover the entire joint flexion zone (FL and FM surfaces) or tightly surround the joint circularly. Scars often cover neighboring and regional areas – shoulder, neck and chest wall. Such contracture belongs to type III or IV of numeric classifications and is most severe and challenging for surgeons [2,3]. In our anatomy-based three-grade classification, this contracture type is named total [4]. Such contractures undergo treatment with skin transplants [5] or regional pedicle fascio-cutaneous and musculocutaneous or free flaps. Skin transplants in axilla shrink and contracture often recurs. Special garment and abducted devices are insufficient to prevent complications [6]. Therefore, most often total shoulder contractures are treated with regional pedicle, island, regular and expanded flaps [7,8]. After total contracture release, a big wound or scar surface deficit (contracture cause) appears for covering of which a big flap is needed. The elevation of such flap can deform a donor site, especially in children. During burns, the shoulder accepts an adducted position, and a small island skin is preserved from injury in the fossa's apex. When operating on such patients, we tried to use the island's axillary skin in form of subcutaneous pedicle flap.

Material and Methods

Twenty-one patients with total (severe) shoulder scar contractures were personally operated, in which the island skin was preserved in axillary fossa's apex, using the new technique. Among patients, 10 were female and 11, male, ranging in age from 8 to 49 years old. All patients sustained deep-partial or full-thickness burns from 8 to 28% of TBS (total body surface). Reconstruction was performed from five months to four years after injury.

Before and after surgery, the anatomic and clinical features of contractures were explored: (scar size, location, and spreading, as well as possibilities of the use in form of subcutaneous pedicle flap). To accomplish the reconstruction: (a) contracted scar were dissected from anterior joint rotation axis to posterior; (b) axilla elevated to its normal level; (c) using subcutaneous pedicle flap (island skin), the axilla was suspended; (e) shoulder and thoracic wounds were separately skin grafted. The new technique was more successful, safe, and less traumatic in treatment of most severe total shoulder contractures. Results were observed from six months to seven years. Good results were characterized by a full range of motion and good skin transplants appearance.

Result

Anatomy of total shoulder contracture, scar surface deficit as contracture cause (Figure 1 and 2)

The shoulder joint flexion surface is divided into edge flexion (F) and extension (E) surfaces. The dividing line passes along the shoulder joint rotation axis. Joint flexion surface is divided into flexion lateral (FL) and flexion medial (FM) by a curvature formed by the edges of the axillary fossa. The distance from the edge of the fossa to the joint rotation axis is the flexion lateral surface (FL); the axillary fossa or distance between the edges of the fossa is flexion medial surface; both flexion lateral and flexion medial surfaces are total flexion surface (Figure 1). Scars, covering the joint flexion lateral surface(s), form a fold along the edge of the fossa, and the crest of the fold is the edge of scars. Therefore, the contracture caused by scars located on the joint flexion lateral (FL) surface including scars' sheet of the fold, creates the edge contracture (anterior, posterior and anterior-posterior or both sided).

Contracted scars covering axillary fossa or flexion medial (FM) surface cause the shoulder medial adduction contracture.

Contracted scars involving the entire joint flexion surface (two edge and medial surfaces) cause a total contracture [4].

This classification is substantiated by the author who had observed and surgically treated more than a thousand patients with scar contractures of different localization and severity. This three-type classification is applied to all postburn scar contractures regardless of their location and severity. Thus, shoulder total adduction contractures are characterized by scars which cover the entire joint flexion surface or the joint's three flexion surfaces, anterior and posterior flexion lateral (FL), and axillary fossa or flexion medial (FM) surface (Figure 1).

Scars spread widely on neighboring shoulder joint areas, including inner surface of the shoulder and lateral truncal surface. Island axillary skin was covered by scars from periphery, and a cavity was formed which connected with the outward space through a small round orifice of 2-3 cm in diameter (Figure 1-4). The lateral wall and the bottom of the cavity was healthy skin. The fossa's edges were smoothed, and the entire axillary region turned downward. In 1 out of 20 patients the island axillary skin was open, located deeper than the surrounding scarred skin transplants (Figure 5-7). The size and form of the island's skin differed from case to case but was nearly a half of the axillary fossa's surface. Surrounding scars and skin transplants' qualities also varied (even, rough, thin, thick, less or more mature, mildly or severely contracted).

Total shoulder contracture treatment using island skin and skin transplants

Treatment of severe shoulder adduction contracture using immured island skin and skin transplants (Figure 1)

Scars cover the joint surface, shoulder and chest wall without fold formation; therefore, severe scar surface deficit becomes a specific feature of total contractures. The axillary fossa becomes obliterated, smoothed, and descends downwards. Small orifice leading to the cavity is in the center of axillary projection. Severe scar surface deficit (large wound appeared after contracture release) of joint flexion surface excluded the possibility of total contracture reconstruction with local flaps. Thus, the treatment would consist from the following steps of reconstruction: (a) freeing axilla of scar contracture; (b) elevating and suspension of the axilla with a subcutaneous pedicle flap (island skin) to a normal level with overcorrection; (c) division of axillary big wound (scar surface deficit) into two: shoulder and thoracic; (d) wounds resurfacing with skin transplants. These anatomic and functional aspects led to the new surgical method/concept development and good outcomes yielding in treatment most severe form of scar shoulder adduction contractures.

Planning consisted of several lines drawing: around orifice and two Y-shaped lines from the orifice anteriorly and posteriorly up to the joint rotation axis level (Figure 1A and 1B).

Surgery (Figure 1): Y-shape incisions of scars from the orifice to the joint rotation axis anteriorly and posteriorly was used for separation of contracted scars from the tissues of the joint extension (E) surface. After that, the wound's scar borders are easy divergence what allow fully total contracture elimination.

After shoulder abduction, a big wound (Dt- scar surface deficit, I- island skin) appeared; the skin of the cavity stayed in situ (Figure 1C, arrow mark). Then, the scarred edges of the orifice were excised; the island skin, which formed a cavity, was mobilized from periphery and dissected from the shoulder and trunk sides leaving nearly 3 - 4 cm bridge in situ (subcutaneous pedicle). The center of the flap was displaced on axilla bottom; muscles edges, forming fossa's edges, were freed from scars and flap. Thus, the central part of the flap was located on axillary apex (Figure 1G, scheme), the cavity wall was dissected from shoulder and chest sides, and half of the cavity displaced in anterior and posterior direction. The island skin was additionally cross-cut from shoulder and trunk sides, converting the healthy skin into a narrow subcutaneous pedicle flap (FP) of nearly 3-4 cm in width (Figure 1D). The flap was displaced first on anterior flexion lateral (FL) surface and sutured with the wound border. Then, posterior FL surfaces and the flap's ends were sutured (Figure 1D, FP-flap). The flap was transposed in anterior and posterior direction with tension and, as a result, fossa's edges stretched each other up to axilla oblit-

eration. The extended flap, having steady blood circulation, steadily suspended the axilla with overcorrection and divided the large wound into two: shoulder and thoracic which are scar surface deficit (Dt) and contracture cause. Both wounds were skin grafted (Figure 1E). Due to flap tension, the adipose-cutaneous layer of joint extension surface (E) located above the shoulder joint rotation axis was displaced downward covering a part of the wound on the joint flexion lateral surfaces (FL). The flap's stretching spreads on neighboring zones and soft tissue were squeezed. As a result, the wound's length in anterior-posterior direction became shorter. These circumstances allowed a relatively short flap approach the wound's edges, steadily suspend the axilla, cover the central axillary zone, and divide the big wound into two: shoulder and thoracic. The big wounds beside the flap were skin grafted. Skin flap and hairs continued to grow after surgery; skin transplant (T-t) converted into normally functioning skin.

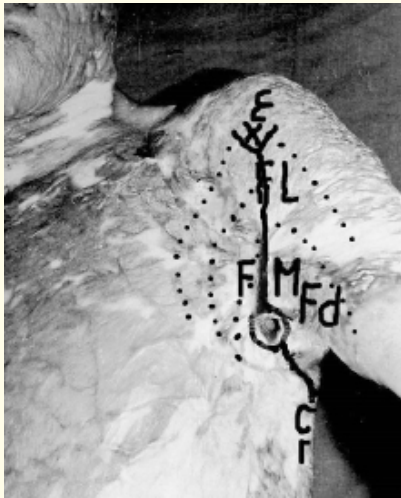


Figure 1a

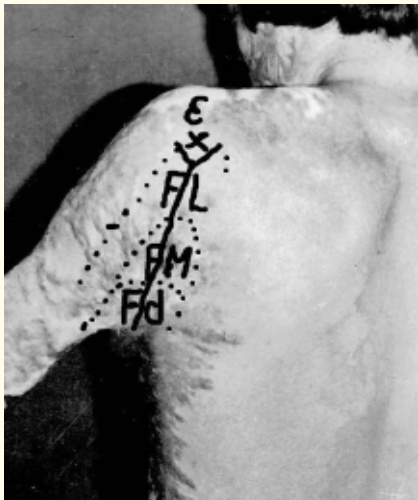


Figure 1b

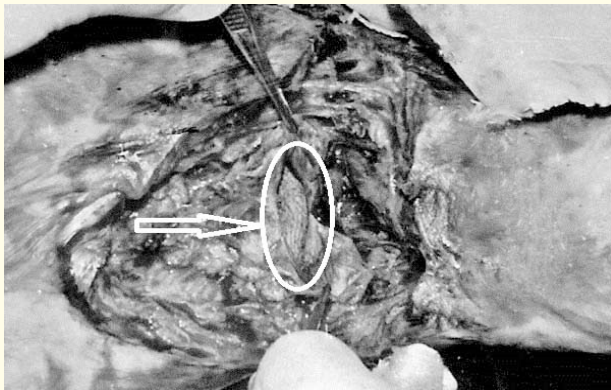


Figure 1c

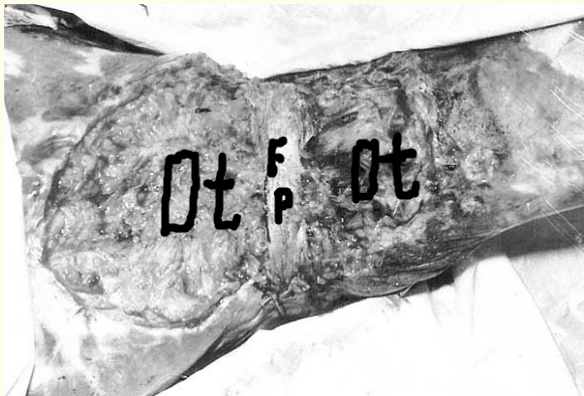


Figure 1d

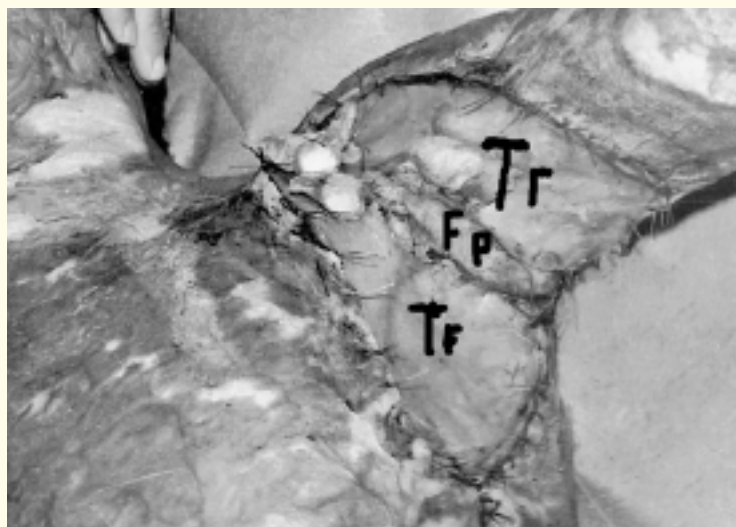


Figure 1e

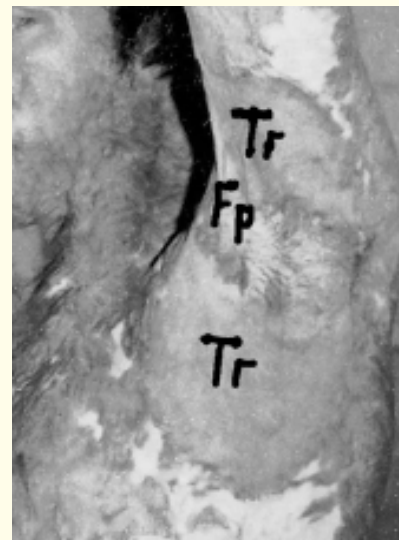


Figure 1f

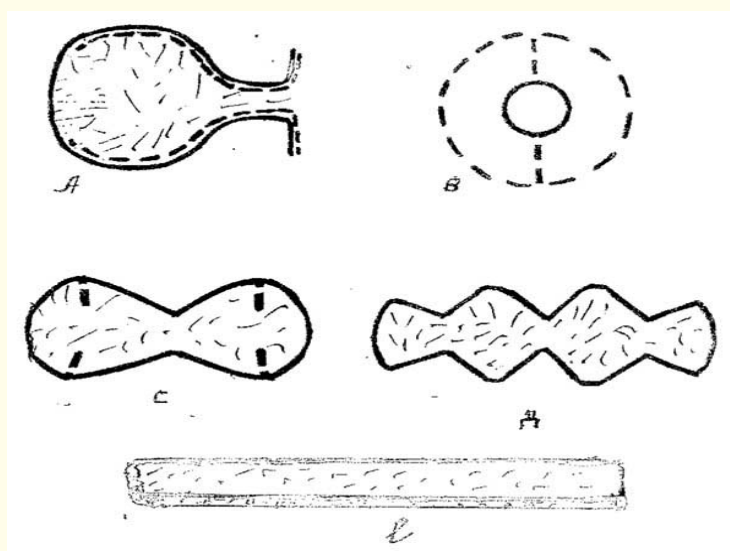


Figure 1g

Figure 1: Severe total shoulder adduction contracture treatment with immured island healthy skin of cupola and skin grafting. (a, b) Contracture anatomy: E- joint extension surface; "+"- joint rotation axis; FL- flexion lateral surface; FM- flexion medial surface. Fd- fold. Pre surgery: total severe adduction contracture, wide spreading scars, scars displaced axilla downward; small orifice leading to immured skin; planning: line around orifice and lines for contracture release by scars dissection with Y-shaped incisions from orifice to the joint rotation axis; (c) after scars' dissection and freed orifice from scars, a large wound or Dt- scar surface deficit, appeared and the healthy island skin seen in axillary center; (d) immured healthy skin mobilized from periphery and converted into a subcutaneous pedicle flap (FP), its ends connected with wound edges on anterior and posterior joint surfaces, large wound divided onto two: thoracic and shoulder, flap suspended axilla to normal level; (e) wounds aside the flap were covered with skin transplant (T-t); (f) two years after reconstruction: full shoulder abduction, flap (island healthy skin) became two times wider, hair grows, skin transplants look as normal skin; axillary fossa restored; (g) converting healthy skin in longitudinal flap (scheme).

Immured island skin treatment in case of mild-to-moderate contractures (Figure 2, 3 and 4)

In such cases, the scar's surface deficiency was less expressed. Joint functional zones: E- joint extension surfaces; FL- flexion lateral and FM- flexion medial surfaces; "+"- joint rotation axis. The planning of the contracture release: Y- lines of contracted scars incisions from orifice to the joint rotation ("+"). For elongation in anterior-posterior direction, the island skin was incised anteriorly and posteriorly, converting the immured island skin into a subcutaneous pedicle flap (Figure 3C); axilla suspension with the flap and wound division into shoulder and thoracic were the same as in the previous case (Figure 1). Due to axilla's elevation, the scar surface surplus/fold appeared on the shoulder and trunk which allowed the wounds aside the flap to be covered with local tissues, connecting the wound's edges along the shoulder and trunk (Figure 2D, 3D and 4C).

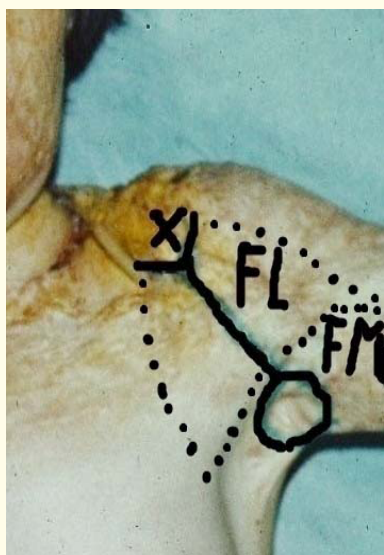


Figure 2a

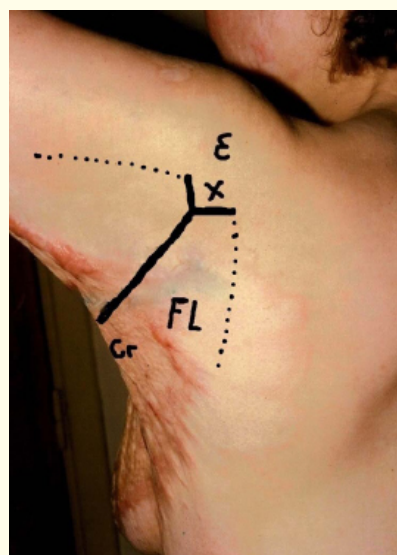


Figure 2b

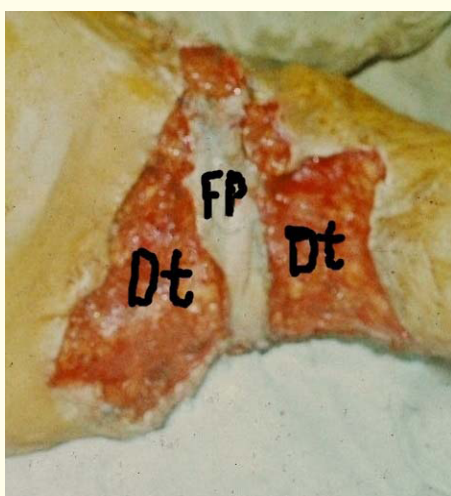


Figure 2c

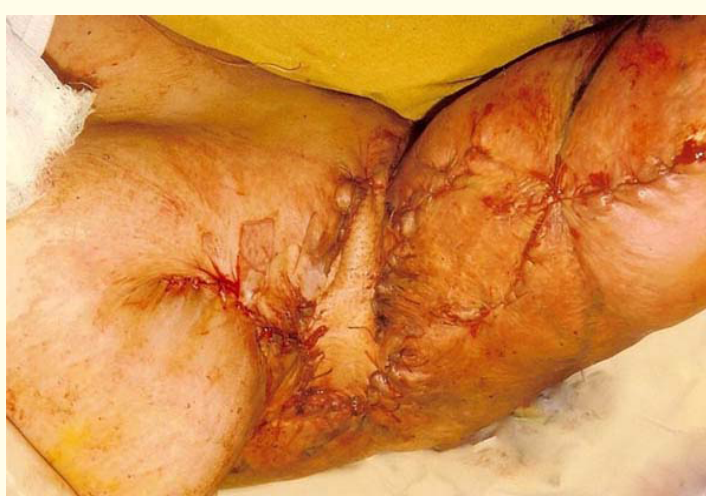

Figure 2d

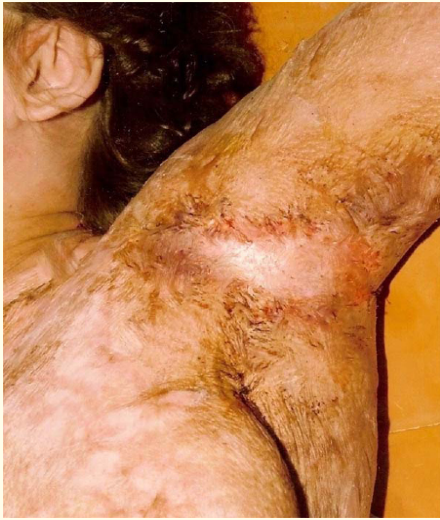

Figure 2e

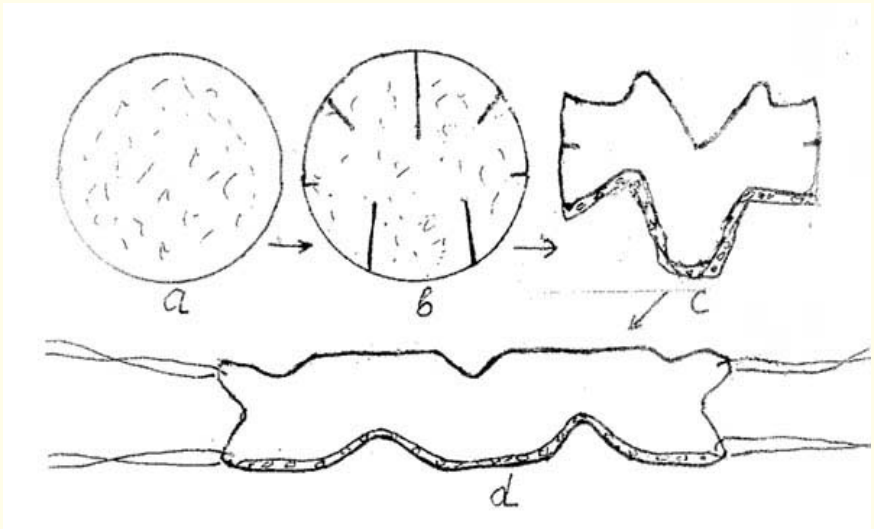


Figure 2f

Figure 2: Conversion of cupola immured healthy island skin into a long narrow flap and fixation it in central axilla. (a, b) Before operation, joint zones and contracture anatomy marked: E- joint extension surface; "+"- joint rotation axis; FL-flexion lateral surfaces converted by scars and contracture caused; FM- flexion medial surface covered by scars; planning: Y-lines of contracted scars dissection on FL surfaces anteriorly and posteriorly from the folds' crests to the joint rotation axis; (c) the skin of the cavity is converted into a FP- flap the ends of which are sutured to wound's ends anteriorly and posteriorly. The flap suspends the axilla and divides the wound into shoulder and thoracic segments, which are Dt- scar surface deficit and contracture cause; (d) end of operation, wounds (scar surface deficit) aside the flap are primarily closed, starting from flap's ends; (e) results: contracture fully released with local tissues, axillary region restored; (f) converting the cavity's healthy skin into subcutaneous pedicle flap (scheme).

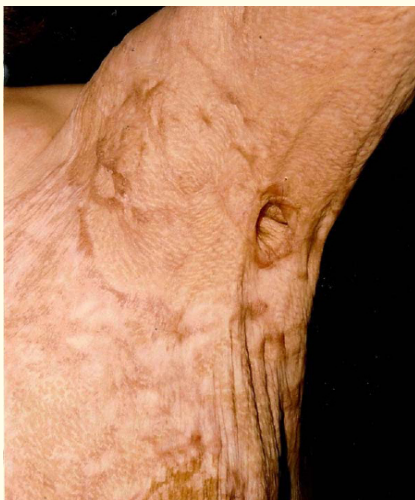

Figure 3a

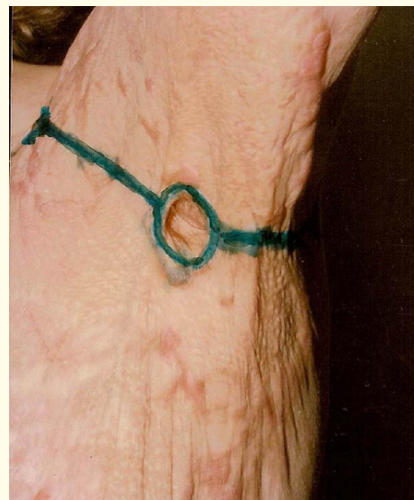

Figure 3b

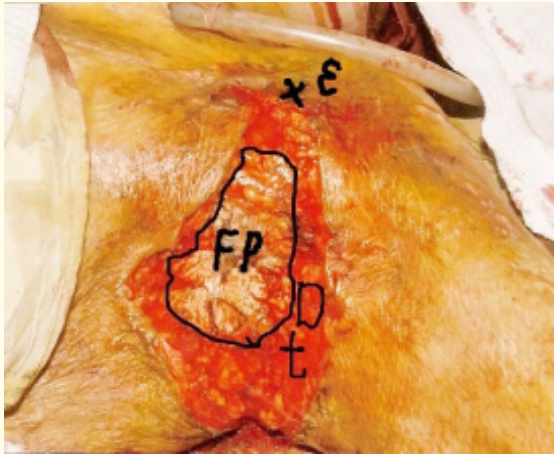


Figure 3c

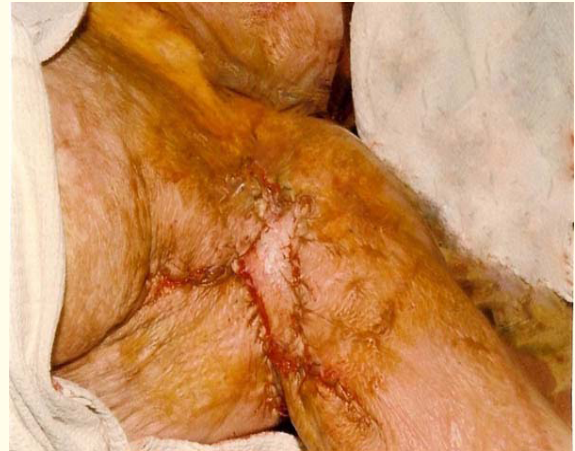

Figure 3d

Figure 3: Result of total shoulder adduction contracture treatment using immured island healthy skin and local tissue. (a, b) Before operation and planning, Y-lines for contracted scars dissection anteriorly and posteriorly from orifice to joint rotation axis; (c) healthy skin of cavity was isolated from scars and converted into FP- flap oriented in anterior-posterior direction; wound or Dt-scar surface deficit appeared around the flap; E- joint extension surface; “+”- joint rotation axis. (d) Ends of the flap connected with wound borders anteriorly and posteriorly; wound aside the flap primarily closed; flap covered central axillary zone; contracture eliminated with the flap and neighboring tissues of shoulder and chest wall, transposed to axilla for the donor wound covering; scheme of operation.

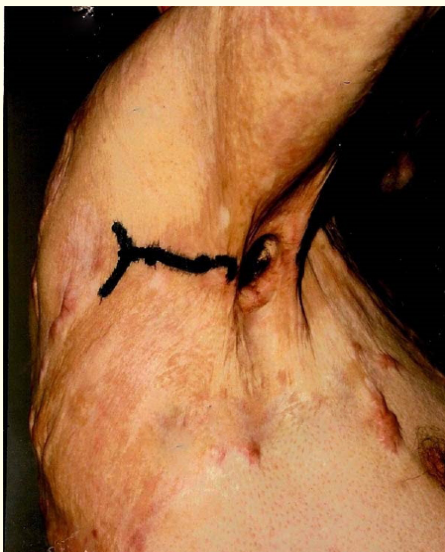

Figure 4a

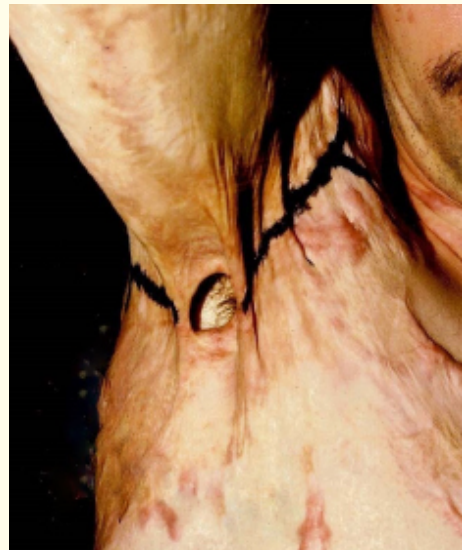

Figure 4b

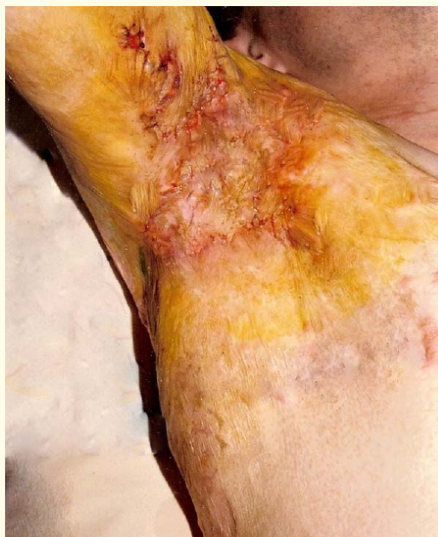

Figure 4c

Figure 4: Result of total shoulder adduction contracture treatment with immured healthy skin, being converted in long subcutaneous pedicle flap. (a, b) Pre surgery view; hairs of cupola into orifice; “I”- island skin; planning: Y-lines from orifice to joint rotation axis of contracted scars incision; (c) healthy skin of cupola mobilized from periphery and converted into lineal adipose-cutaneous subcutaneous pedicle flap; ends of which connected with wound’s edges anteriorly and posteriorly; wounds or scar surface deficit covered with local tissues, starting from the flap’s ends; two weeks after reconstruction: flap alive (FP), axillary region restored, contracture completely eliminated.

After surgery: the normal function of shoulder joint and axilla contours were restored due to (a) flap stable location and axilla suspension and (b) extended tissue surrounding the joint and flap continued to grow. These factors prevented a contracture recurrence.

Total shoulder adduction contracture treatment with open axillary island skin used in form of subcutaneous pedicle flap (Figure 5 and 6)

Scars, covering a shoulder joint, its neighboring zones and axillary fossa from periphery, leave in situ of healthy island skin (Figure 5A and 6A). Scars descended the axilla, adducted the shoulder to chest wall and fossa’s edges were smoothed.

The island skin was separated from the scars. Contracted scars were dissected from the island skin to the joint rotation axis anteriorly and posteriorly, using a Y-shaped incision for a complete the wound’s edges divergence by separation scars of FL surfaces from tissues of joint extension surface and fully contracture release (Figure 5B). The island skin was mobilized from periphery, converting island skin in subcutaneous pedicle flap, which was stretched in anterior and posterior direction with tension and connected with the wound’s edges (anterior first), suspending axilla in over correction position. The island skin could be incised from the shoulder and truncal sides for flap elongation. Depending on scar surface deficit severity, the wounds aside the flap can be covered with skin grafts (Figure 6B) or primarily closed (Figure 5C).

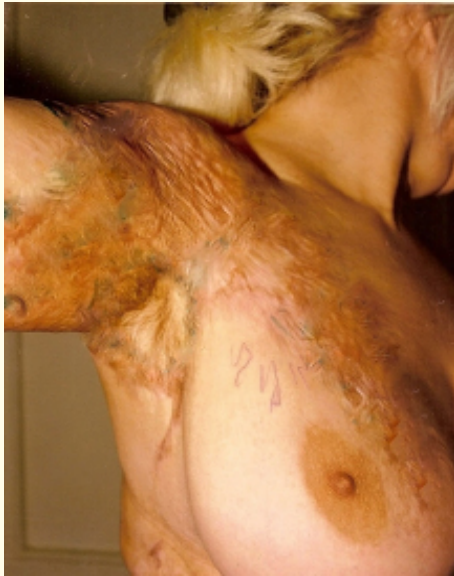

Figure 5a

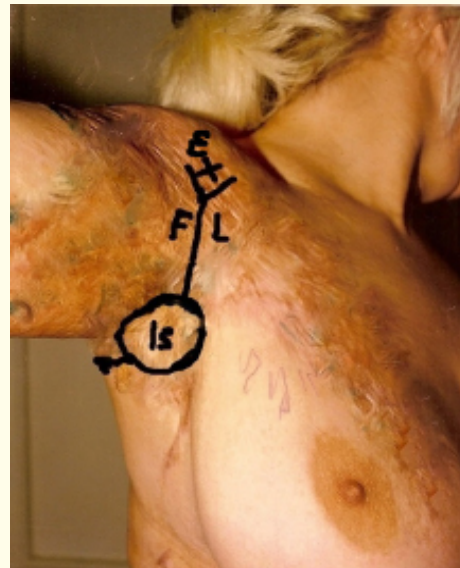

Figure 5b

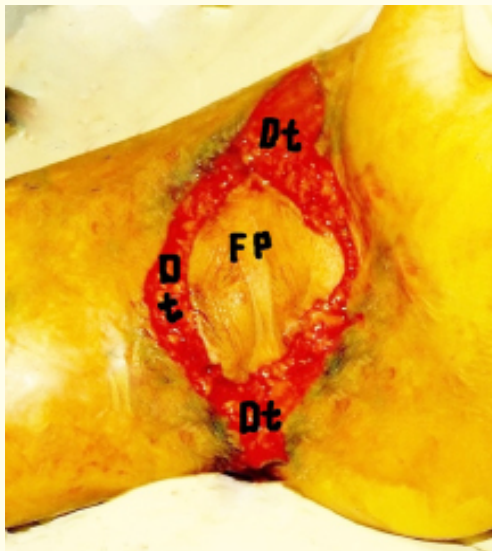


Figure 5c

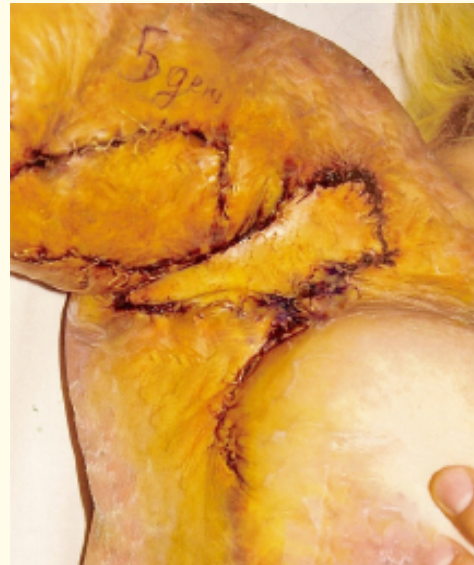

Figure 5d

Figure 5: Shoulder adduction contracture treatment using island open healthy skin in axillary cupola. (a) Pre surgery; (b) functional joint zones, planning; E- joint extension surface; "+"- crest of the joint; FL- flexion lateral surfaces; Is- axilla island healthy skin; (c) contracture released by Y-incisions of FL surfaces anteriorly and posteriorly; island of healthy skin mobilized on periphery; FP- subcutaneous pedicle flap; Dt- scar surface deficit; (d) ends of the flap extended in anterior-posterior direction and sutured to the wound's edges; wounds beside the flap primarily closed; ten days after operation: flap and transplants alive, contracture fully released; central axilla is the healthy skin or subcutaneous pedicle flap.

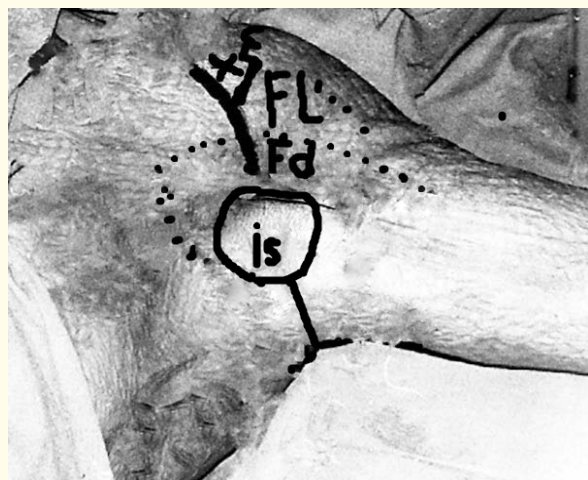


Figure 6a

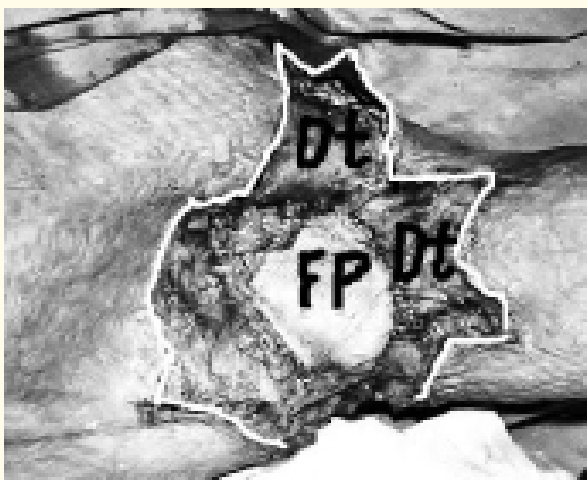


Figure 6b

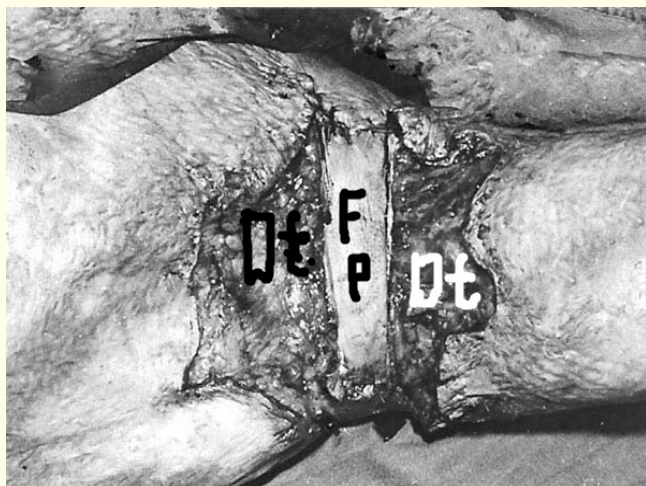


Figure 6c

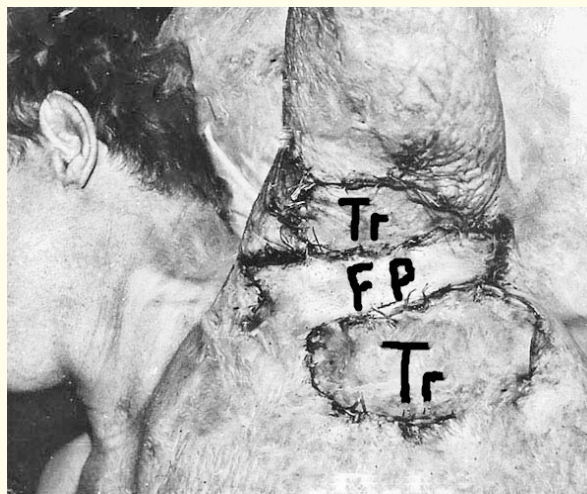


Figure 6d

Figure 6: Result of severe shoulder adduction contracture elimination with island axillary skin and skin transplants. (a) Pre-surgery, anatomy of contracture: E- joint extension surface; "+"- joint rotation axis; FL and FM surfaces; Is- island skin in axillary apex. Planning of operation: Y- lines for contracted scars dissection from the skin island to joint rotation axis; (b) island skin separated from scars, separated from periphery; scars dissected from island skin to the joint rotation axis anteriorly and posteriorly. FP- flap; Dt- scar surfaced deficit; (c) mobilized from periphery island skin and extended in anterior and posterior direction and connected with wound edges on joint rotation axis level. Flap suspended axilla with over correction and divided large wound on two: shoulder and thoracic; FP- flap; Dt- scar surface deficit; (d) ten days after surgery: flap suspended axilla; wounds covered with skin transplants, contracture eliminated; skin transplants -Tr- and subcutaneous pedicle flap (FP) alive. Axilla suspended with over correction, contracture fully eliminated.

If the island skin's surface was small (4-5 cm in diameter – "I") and the contracture was severe (Figure 7), to the neighboring scar tissue was added island skin for construction of a quadrangular adipose-skin/scar subcutaneous pedicle flap (Figure 7A and 7B). After axilla elevation and suspension by the flap, big wounds or scar surface deficit (Dt) appeared (Figure 7C) which were covered with skin transplants (Figure 7C-7E). Flap and transplants healed without complications yielding good functional and cosmetic outcomes.

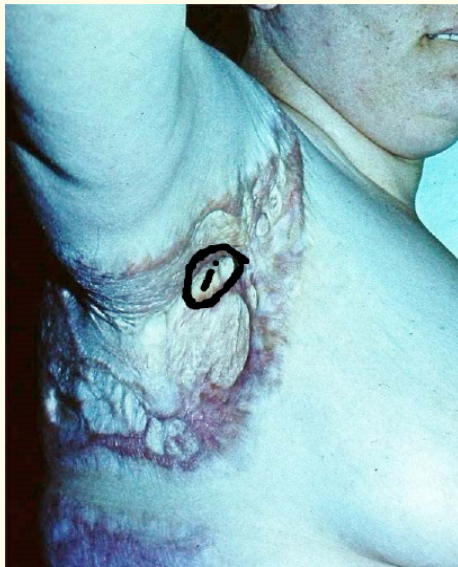

Figure 7a




Figure 7b

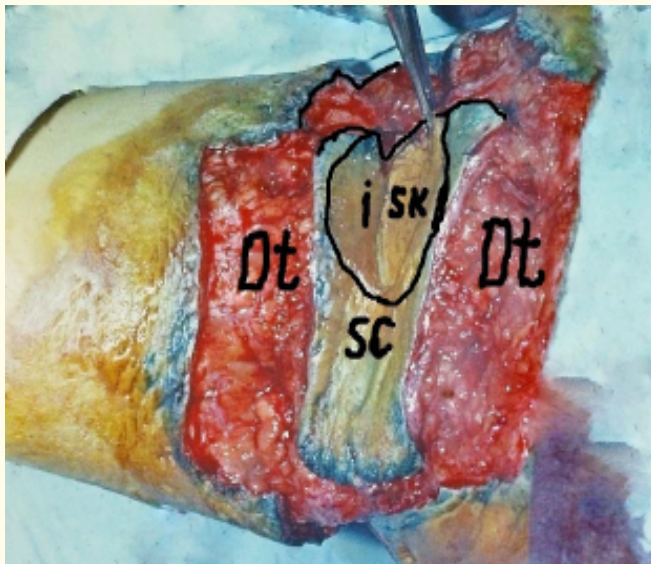


Figure 7c

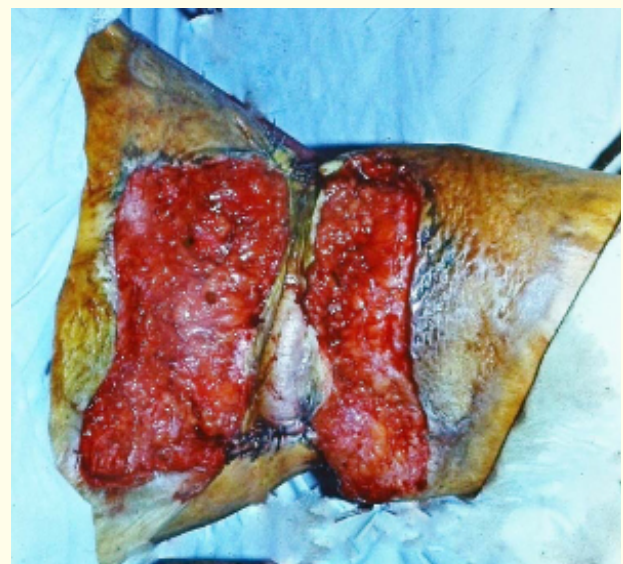

Figure 7d

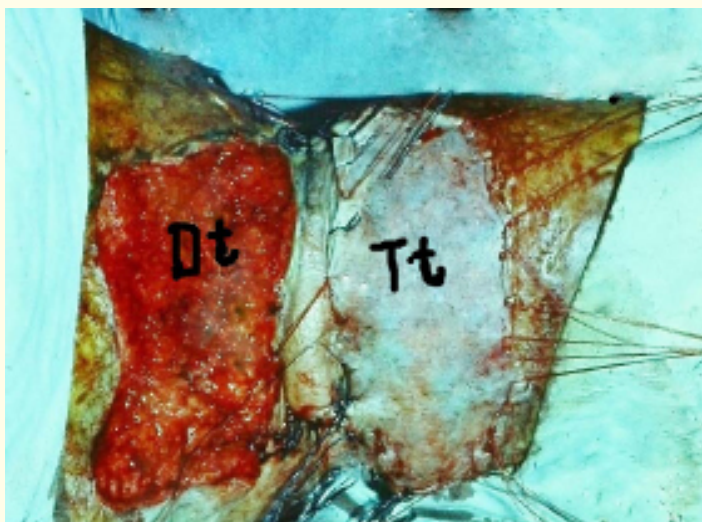


Figure 7e

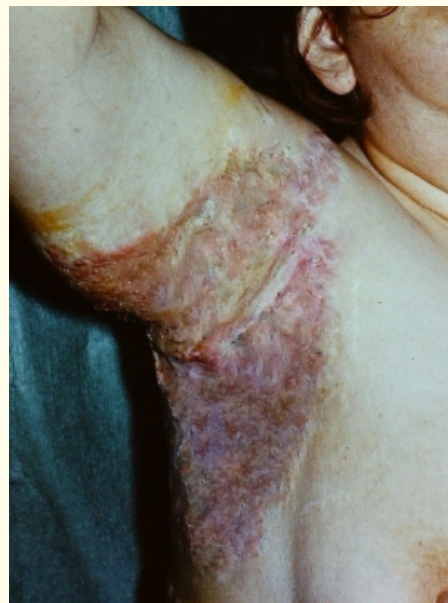

Figure 7f

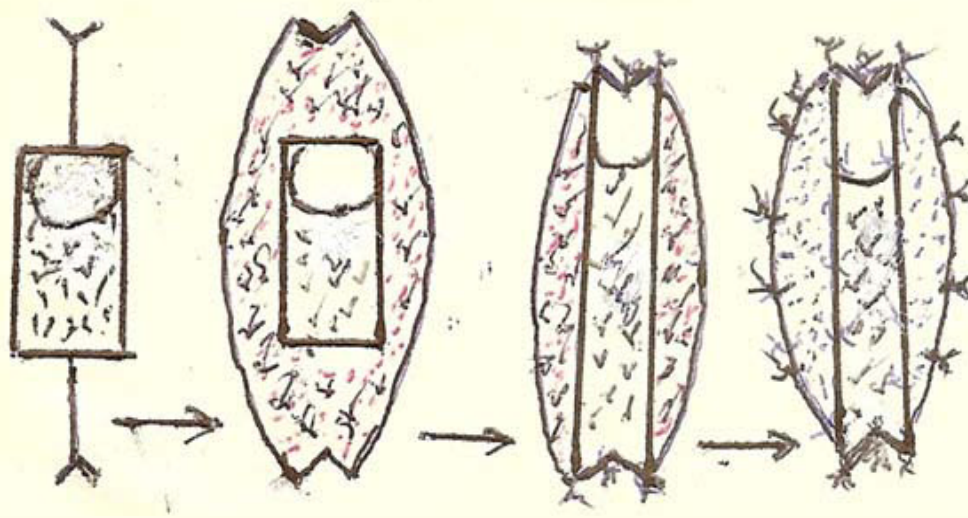


Figure 7g

Figure 7: Small island open healthy skin incorporated in quadrangular adipose subcutaneous pedicle flap. (a) Before surgery: small immured island healthy skin; (b) borders of scar quadrangular subcutaneous pedicle flap, scars attached to healthy skin; FM- flexion medial surface; I-island skin; Y-lines of contracted scar dissection from flap’s borders to the joint rotation axis; (c) contracture released, rectangular scar flap mobilized, the scars of anterior end of the flap incised, so that healthy skin was opened (exposed) and formed the anterior part of the flap; the flap is displaced to bottom of the axilla; (d) flap extended in anterior-posterior direction, its ends sutured with the wound borders at joint rotation axis level; (e) large wounds or scar surface deficit aside the flap covered with skin transplants; (f) result (five weeks after surgery): flap and skin transplant alive, contracture released completely; (g) scheme of operation.

Results of operations

In all 21 patients, the shoulder scar adduction contractures were released completely. Despite severe tension, all flaps were alive. In 2 of 9 patients when the wound aside the flap was primarily closed, superficial marginal scar necrosis occurred aside the flap; the wounds were healed with dressings not harming the outcome. Skin transplants (in 12 patients) grew well with the underlining wound tissues. Immediately after surgery, the contours of the axilla were smoothed. With time, however, the extended flap and surrounding tissues continued to grow, the tension gradually disappeared, and the axillary contours were restored. With time, the skin transplant became well-functioning skin. In three patients mild to moderate skin transplants shrinkage was observed, but it did not change the position of the flap. Thus, the flap prevented contracture recurrence. Follow-up functional results were excellent: full 180 degrees abduction and shoulder range motion were achieved. Cosmetic outcomes were good: the axillary region accepted normal outlines. The longer the period after reconstruction, the better were the follow-up results. The flap's size surface grew significantly; hairs grew well (Figure 1F). Presented data shows that the axilla suspension and division of the axillary wound into shoulder and chest prevent skin transplants shrinkage and contracture recurrence.

(Figure 1F). Presented data shows that the axilla suspension and division of the axillary wound into shoulder and chest prevent skin transplants shrinkage and contracture recurrence.

Discussion

The total shoulder scar adduction contracture is caused by scars covering all joint flexion surface (F), which consists of both (anterior and posterior) shoulder joint flexion lateral (FL) and flexion medial (fossa) (FM) surfaces./ Total contracture of own classification equaled to Type III in existing III-type classification [2] and to IV in Type IV classification [3] which are to be treated with skin transplants, regional or free flaps. The differences among numeric classifications prompted us to research the anatomy of scars' contractures of different localizations and severity. All anatomic features suggested classifying all contractures into three types: edge, medial, and total [4]. This anatomical label "total" is used in the paper. Currently, only two techniques are employed for shoulder total scar contractures treatment: skin transplantation and regional flaps transposition. Free flaps are rarely used. Skin transplants are used if the donor sites are injured by burns. Our own data and literature review have proven that skin grafts' shrinkage in axillary region continues, leading to adduction re-contracture, despite the use of long-time pressure garments and other special devices [6]. Shoulder's normal position at the rest is adduction, which promotes skin transplant shrinkage and re-contracture formation.

Dogra., *et al.* [9] documented 100 cases treatments of postburn contractures of upper extremities. Linear contractures were managed by single or multiple Z-plasty techniques whereas patients having wider and dense scars (total contracture) were managed by release/excision of scar and skin grafting. Chen., *et al.* [7] treated severe or moderate axillary burn scar contractures with a large transverse island scapular flap and expanded transverse island scapular flap in 15 adult and pediatric patients. Yotsuyanagi., *et al.* [22] used double combined Z-plasty and Zhang., *et al.* [23] proposed reversed Z-plasty and its variations for wide scar contracture release (total contractures). The mean visual analog score for patient satisfaction was 8.6 for Z-plasty group versus 5.33 for split skin grafting group. Walsh., *et al.* [10] conclude that for Type II (bilateral contractures) and III (total contracture) contractures, the regional flaps were a preferred choice whenever available. Karki., *et al.* [11] operated 44 patients with axillary contractures. Surgical treatment included split-thickness skin graft, propeller and square flaps. Various regional flaps have been used for shoulder contracture treatment: pre-expanded pedicle thoracodorsal artery perforator [8]; thoracodorsal perforator-based cutaneous island flap [12-14], scapular and parascapular flaps [15]; island scapular flap [16]; island lower trapezius myocutaneous flap [17,18]; latissimus dorsi musculocutaneous flap [19]; thoracic fasciocutaneous flap [20]; latissimus dorsi and superficial cervical artery flaps [5]. Total shoulder contractures were successfully treated using quadrangular scar subcutaneous pedicle flap [21]. Chen., *et al.* [7] treated severe or moderate axillary burn scar contractures with large transverse island scapular flap and expanded transverse island scapular flap in 15 adult and pediatric patients. Yotsuyanagi., *et al.* [22]

used double combined Z-plasty. Zhang, *et al.* [23] proposed reversed Z-plasty and its variations to release wide-scar contraction (total contractures). Stekelenburg, *et al.* [24] reported that randomized controlled trial showed that perforator-based interposition flaps result in a more effective scar contracture release than full-thickness skin grafts and should therefore be preferred over full-thickness skin grafts when possible.

Presented own data show that complete shoulder adduction contracture release, and suspension axilla with subcutaneous pedicle axillary flap, and division by the flap the large axillary wound into shoulder and chest prevent skin transplants from shrinkage and small-moderate shrinkage on flap's position in axilla and contracture from recurrence. Author convinced that this method solves the main problems of treatment the most severe (total) postburn scars shoulder contractures.

Conclusion

New surgical method was developed for treatment of severe/total shoulder adduction contractures, in cases where a small island of healthy skin had been preserved in the axillary apex. After contracted scars dissection in axilla projection anteriorly and posteriorly, the island skin was mobilized from periphery and converted into a subcutaneous pedicle flap. The ends of the flap in extended condition are connected with the wound's edges at the joint rotation axis level anteriorly and posteriorly. The extended flap stable suspends the axilla, divides the large wound into shoulder and thoracic. These factors (axilla suspension and wound division) prevent skin transplants from shrinkage. The extended flap continues to grow in length and width, and the skin transplants are gradually transformed into well-functioning skin. The new method, directed at elimination of severe shoulder contracture and restoration of the axillary region's contours. This method yields excellent functional and good cosmetic outcomes and, therefore, is preferred technique for severe (total) shoulder adduction contracture treatment in adult and children. Preservation of the small island skin in the axillary apex should be a guiding rule during the early burned tissue excision.

Bibliography

1. Schneider JC, *et al.* "Contractures in burn injury: defining the problem". *Journal of Burn Care and Research* 27.4 (2006): 508-514.
2. Kurtzman LC and Stern PJ. "Upper extremity burn contractures". *Hand Clinics* 6.2 (1990): 261-279.
3. Hallock GG. "A systematic approach to flap selection for the axillary burn contracture". *Journal of Burn Care and Rehabilitation* 14.3 (1993): 343-347.
4. Grishkevich VM. "The basic types of scar contractures after burns and methods eliminating them with trapezeplasty flaps". *Plastic and Reconstructive Surgery* 88.6 (1991): 1044-1054.
5. Ogawa R, *et al.* "Reconstruction of axillary scar contracture --retrospective study of 124 cases over 25 years". *British Journal of Plastic Surgery* 56.2 (2003): 100-105.
6. Obaidullah H, *et al.* "Figure- of-8 slint for prevention of recurrent axillary contracture after release and skin grafting". *Burns* 31.3 (2005): 283-289.
7. Chen B, *et al.* "Surgical treatment of severe or moderate axillary burn scar contracture with transverse island scapular flap and expanded transverse island scapular flap in adult and pediatric patients--A clinical experience of 15 cases". *Burns* 41.4 (2015): 872-880.
8. Kulahei Y, *et al.* "Pre-expanded pedicled thoracodorsal artery perforator flap for postburn axillary contracture reconstruction". *Microsurgery* 31.1 (2011): 26-31.

9. Dogra BB., *et al.* "Management of postburn contractures of upper extremities: A general surgeon's perspective". *Indian Journal of Burns* 24.1 (2016): 29-35.
10. Walash A., *et al.* "Treatment of postburn axillary contracture". *Menoufia Medical Journal* 27.2 (2014): 278-282.
11. Karki D., *et al.* "Post-burn axillary contracture: A therapeutic challenge!". *Indian Journal of Plastic Surgery* 47.3 (2014): 375-380.
12. Kim DY., *et al.* "Correction of axillary scar contractures with the thoracodorsal perforator-based cutaneous island flap". *Annals of Plastic Surgery* 44.2 (2000): 181-187.
13. Er E and Ucar C. "Reconstruction of axillary contractures with thoracodorsal perforator island flap". *Burns* 31.6 (2005): 726-730.
14. Duncan SFM and Smith AA. "Treatment of the burned axilla. In: Sood R, editor. Achauer and Sood's burn surgery. Reconstruction and rehabilitation". Philadelphia, PA: W. B. Saunders (2006): 282-298.
15. Nisanci M., *et al.* "Treatment modalities for postburn axillary contractures and the versatility of scapular flap". *Burns* 28.2 (2002): 177-180.
16. Turkaslan T., *et al.* "Uses of scapular island flap in pediatric axillary burn contracture (correction of contractures)". *Burns* 32.7 (2006): 885-890.
17. Elshaer WM. "Extended lower trapezius island myocutaneous flap in the repair of postburn axillary contracture". *Plastic and Reconstructive Surgery* 113.7 (2004): 2076-2081.
18. Tan KCh and Tan BK. "Extended lower trapezius island myocutaneous flap in the repair of postburn axillary contracture". *Plastic and Reconstructive Surgery* 113 (2004): 2052-2055.
19. Wilson IF, *et al.* "Latissimus dorsi myocutaneous flap reconstruction of neck and axillary burn contractures". *Plastic and Reconstructive Surgery* 105 (2000): 37-33.
20. Sakr WM., *et al.* "Options for treatment of postburn axillary contractures". *Egyptian Journal of Plastic and Reconstructive Surgery* 31 (2007): 63-71.
21. Grishkevich VM. "Shoulder adduction contracture after burn: Anatomy and treatment with quadrangular local scar subcutaneous pedicle flap, a new approach". *Burns* 39.7 (2013): 1423-1429.
22. Yotsuyanagi T., *et al.* "Double combined Z-plasty for wide-scar contracture release". *Journal of Plastic, Reconstructive and Aesthetic Surgery* 66.5 (2013): 629-633.
23. Zhang L., *et al.* "Reversed Z-plasty and its variations to release wide-scar contraction". *Burns* 40.6 (2014): 1185-1188.
24. Stekelenburg CM., *et al.* "Perforator-based Interposition flaps perform better than full-thickness grafts for the release of burn scar contractures: a multicenter randomized controlled trial". *Plastic and Reconstructive Surgery* 139.2 (2017): 501e-509e.

Volume 9 Issue 8 August 2018

©All rights reserved by Viktor M Grishkevich.