

The Aging of the Face and the Fracture of the Floor of the Orbit in Ages

Randriamanantena Tahiriavelo^{1*}, Keita Cadia², Andrianimaro Florelia³, Noémie Auger³ and Touré Gaoussou⁴

¹Maxillofacial Surgery, University of Teaching Hospital, Fianarantsoa, Madagascar

²Maxillofacial Surgery, Villeneuve Saint Georges's Hospital, France

³Intensive Care Unit, Tambohobe Fianarantsoa Teaching Hospital, Fianarantsoa, Madagascar

⁴Intensive Care Unit, Villeneuve Saint Georges Hospital, France

***Corresponding Author:** Randriamanantena Tahiriavelo, Maxillofacial Surgery, University of Teaching Hospital, Fianarantsoa, Madagascar.

Received: June 12, 2018; **Published:** July 27, 2018

Abstract

Introduction: The orbit is a crossroad of trauma of the middle third of the face whose fracture of the lower wall is the third of the facial bone fractures. This fracture of the floor of the orbit or lower wall of the orbit becomes more and more common in elderly subjects defined by the WHO as being over 60 years old. In these elderly subjects, difficulties arise during the repair of the floor of the orbit in case of fracture. Thus, the purpose of this work is to demonstrate the relationship between anatomical changes in the middle third of the face and this technical difficulty.

Patients and Method: Sixty patients were recruited, of which 30 are subjects under 40 years old and 30 are subjects over 60 years old. CT images were used for measurement and change verification.

Results: A decrease in the angulation of the floor, a retraction of the maxillary and the middle third of the face, and an erasure of the lower orbital rim were observed. In addition, a slippage of the filling material during the repair of the floor was noted.

Discussion: Knowledge of anatomical changes on remodeling in elderly subjects improves understanding and management of rejuvenation surgery but at the same time it also allows us to understand a difficulty in the management of traumatology, particularly in the repair of the floor of the orbit.

Conclusion: Our study allowed us to explain that the retraction of the maxillary, at the origin of its rocking and the lowering of the angulation of the floor as well as the erasure of the lower orbital rim are linked to the sliding of the filling material during the repair of the floor of the orbit.

Keywords: Fracture; Orbit Floor; Blow-Out; Aging; Face

Introduction

The orbit is a crossroads of the trauma of the middle third of the face and reaching the floor constitutes 1/3 of the fractures of the face. As the life expectancy of the population increases, the fracture of this floor of the orbit becomes more and more frequent in elderly subjects defined by the WHO as subjects over 60 years old [1]. Many of the age-related anatomical changes described in the literature [2] and their clinical implications in different areas of facial surgery [2-4]. Among these modifications are the bone changes [2,3,5]. These are the cause of a difficult repair of the floor of the orbit in case of fracture in the elderly. Thus, the objective of this study is to demonstrate the therapeutic implication of the remodeling of the third of the face during the repair of this floor of the orbit.

Patients and Method

Sixty patients were recruited, 30 of whom are under 40 years old and 30 of whom are over 60 years old. These patients all had fractures of the orbital floor isolated or associated with other facial lesions, having benefited from CT of the coronally and sagittally-shaped facial mass, and surveillance of more than 6 months in the surgery department maxillo-facial of the hospital center of Villeneuve Saint Georges from January 2008 to December 2011.

It is a retrospective and prospective study during which the causes of the accident (Table 1), the surgical management (Table 2), as well as the intraoperative and postoperative problems were studied. Then, on the CT images, measurements of the glabellar angle (an angle formed by a parallel to the line connecting the saddle and the nasion and a line connecting the maximum prominence of the glabella to the nasofrontal suture) were performed (table 3); the maxillary angle (an angle formed by a parallel to a line connecting the saddle and the nasion and the line connecting the most salient point of the upper part of the maxillary and the most prominent one at the maxillary-alveolar junction) (Figure 1) and the thickness of the lower orbital rim (from the upper edge of the inferior rim to the roof of the infra-orbital foramen on a sagittal section) (Figure 2). The measurements were performed using the Volume Viewer and Windows Workstation version 4.2.

Results

| Causes/age groups | Under 40 | Over 60 |
|---|----------|---------|
| Rixes | 57% | - |
| Road accident | 24% | 6% |
| Falls (malaise and / or balance disorder) | 6% | 81% |
| Other | 3% | 3% |

Table 1: Causes of the fracture.

| Number of operated patients/ages | Under 40 | Over 60 |
|----------------------------------|----------|---------|
| Operated | 80% | 20% |
| Per and postoperative problems | - | 100% |

Table 2: Distribution of interventions.

Perioperative discomfort in elderly subjects was:

- Angulation of the floor of the orbit
- Sliding of the filling material

Postoperative problems in the elderly were:

- Gene to the vision down
- Foreign body sensation described under the eye and sometimes in the eye. One patient was recaptured for the inconvenience that was disabling.

Table 3 shows measuring angles and thicknesses on the TDM.

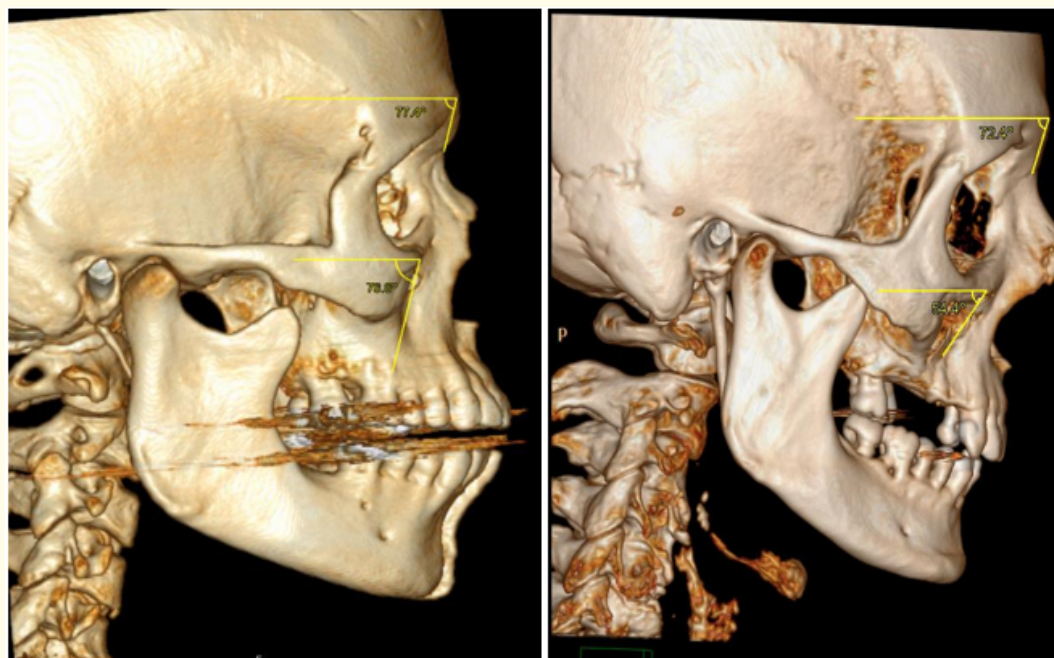


Figure 1: Illustration of measuring glabellar angle and maxillary angle.

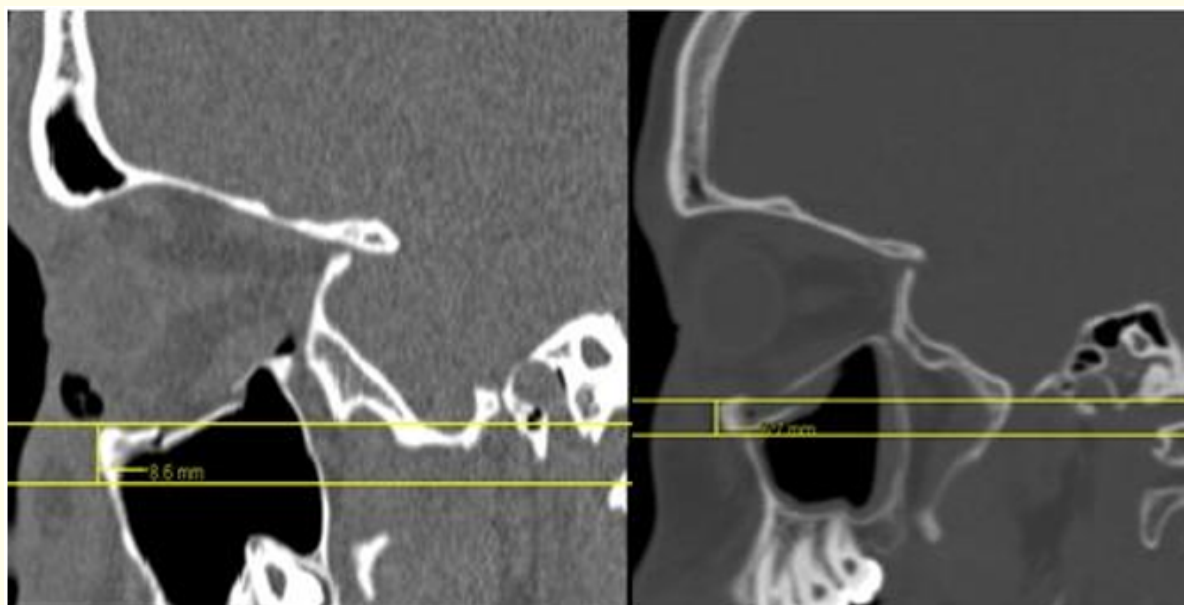

Figure 2: Measurement of lower orbital rim thickness in a young adult and an elderly.

Table 3: Distribution of glabellar angle and maxillary angle measures in 3 dimensions.

| Measures/age groups | Under 40 | Over 75 |
|---------------------|-------------|-------------|
| Glabellar angle | 75.6° (2.4) | 71.6° (2.1) |
| Maxillary angle | 71.1° (1.9) | 58.5° (2.3) |
| Bottom edge | 8 mm (1.1) | 7 mm (0.7) |

Discussion

Many of the changes described at the face level are related to age. These lesions are found either at the level of the soft parts or at the level of the bones. This knowledge brings benefits for rejuvenation surgery [6] and explanations for some difficulties encountered in trauma during the repair of the floor of the orbit.

The incidence of orbital floor fracture has been shown to increase with increasing life expectancy. The most important causes were the fall as a result of discomfort or a simple disturbance of mechanical balance. In 81% of cases it was a drop in investment or home institutions. This leads us to say that this phenomenon becomes a major health problem especially in geriatrics that requires consideration.

Lambros has shown in his studies that apart from soft tissue changes, bone changes also occur at the facial level. These changes are recoil of the maxillary bone bringing with it the entire middle third of the face in the direction of clockwise and also recoil towards the base of the skull [2,3]. Measurements have shown that this decline is accompanied by a decrease in angulations, although this is not significant for the glabellar angle according to Pessa and Zadoo [7-9]. This recoil results in a flip-flop of the lower edge of the forward orbit according to Levine and al in 2003 [10].

The decrease in the glabellar angle value in the elderly already shows the beginning of the decline in the upper part of the face. This results in a decrease in the value of the maxillary angle. The latter shows that the face is hollow at the level of the middle third of the face. The maxillary angle is much more closed in the elderly subjects related to the retraction of the jaws.

Thus, it has been argued that the face widens and recedes with age towards the base of the skull [7-9].

Apart from this decline, erasure of the orbital rim was also observed. This fact has already been described in the literature as a loss of bone thickness. Tooth avulsion is one of the factors favoring this resorption [3,11]. This phenomenon is almost constant in subjects over the age of 75, whether partial or complete.

Receding to the base of the skull, erasure of the lower orbital rim and lowering of the angulation of the floor made it difficult to install the filling material for the repair of the floor of the orbit. All this is at the origin of the sliding of the filling material. The lower orbital rim serves as a kind of reinforcement on which the material must abut not to slip back and set up well, so in case of erasure of this part, a good positioning of the material remains difficult and this turns out to be more restrictive if bone defect is important. In some cases, an adjustment of the material can be made to take advantage of the concavity preserved later. Yet the risk of using a large filler blade is the injury or incarceration of adjacent elements that is at the medial part of the orbit.

This phenomenon explains the intraoperative difficulties encountered but also the postoperative discomfort reported by the patients. Few data have been found on this notion of anatomical changes but no data has been found to argue this implication in traumatology.

Conclusion

Our study shows the retraction of the maxilla and middle third of the face described in the literature. This allowed explaining the difficulties encountered in the management of orbital trauma of the elderly. These challenges include the clinical and therapeutic impact of age-related anatomical changes in trauma. The increase in the incidence of these fractures in elderly subjects encourages further studies to better tailor a treatment taking into account these anatomical changes related to age.

Bibliography

1. Proposed working definition of an elder person in Africa for those MDS Project.
2. Lambros VS. "Personal communication" (1999).
3. Pessa JE and Chen Y. "Curve analysis of the aging orbital aperture". *Plastic and Reconstructive Surgery* 109.2 (2002): 751-755.
4. Pessa JE. "An algorithm of facial aging: Verification of Lambros's theory by three-dimensional stereolithography, with reference to the pathogenesis of midfacial aging, scleral show, and the lateral suborbital trough deformity". *Plastic and Reconstructive Surgery* 106.2 (2000): 479-488.
5. Bartlett SP, et al. "Age-related changes of the craniofacial skeleton: An anthropometric and histologic analysis". *Plastic and Reconstructive Surgery* 90.4 (1992): 592-600.
6. Fenske NA and Lober CW. "Structural and functional changes of normal aging skin". *Journal of the American Academy of Dermatology* 15 (1986): 571-585.
7. Zadoo VP and Pessa JE. "Biological arches and changes to the curvilinear form of the aging maxilla". *Plastic and Reconstructive Surgery* 106.2 (2000): 460-466.
8. Pessa JE, et al. "Relative maxillary retrusion as a natural consequence of aging: Combining skeletal and soft tissue changes into an integrated model of midfacial aging". *Plastic and Reconstructive Surgery* 102.1 (1998): 205-212.
9. Pessa JE, et al. "Concertina effect and facial aging: Nonlinear aspects of youthfulness and skeletal remodeling, and why, perhaps, infants have jowls". *Plastic and Reconstructive Surgery* 103.2 (1999): 635-644.
10. Levine RA, et al. "Adult facial growth: Applications to aesthetic surgery". *Aesthetic Plastic Surgery* 27.4 (2003): 265.
11. Behrents RG. "Growth in the Aging Craniofacial Skeleton, Monograph 17, Craniofacial Growth Series". Ann Arbor, Mich.: University of Michigan Center for Human Growth and development (1985).

Volume 9 Issue 8 August 2018

©All rights reserved by Randriamanantena TahiriariVELO., et al.