

Comparative Outcome between Salter Innominate Osteotomy and Zigzag Osteotomy Combined Fibular Allograft for Developmental Dysplasia of the Hip in Children

Nguyen Ngoc Hung* and Hoang Hai Duc

Vietnam National Hospital for Pediatrics, Vietnam

*Corresponding Author: Nguyen Ngoc Hung, Associate Professor, Vietnam National Hospital for Pediatrics, Vietnam.

Received: January 25, 2018; Published: March 12, 2018

Abstract

Background: Salter 1961, and Hung 2011 have reported Iliac osteotomy surgical treatment for Developmental Dysplasia of the hip in Children, both procedures were applying in some countries.

Materials and Methods: Between 2000 and 2015, 421 patients with DDH underwent open reduction, and Iliac osteotomy. They have divided two Groups, Group 1 with 284 hips of 245 patients (39 bilateral hips) were operated Salter Innominate Osteotomy from January, 2000 to November 2011; and Group 2 with, 198 hips of 176 patients (22 bilateral) were operated Zigzag Osteotomy Fibular combined Allograft from December, 2011 to April 2015. Dislocations were graded according to Tonnis system. The acetabular index was measured on Roentgenography. Clinical evaluation of modified McKay criteria, and Roentgenographic evaluation of Severin. No skin or bone traction before surgery, either derotational varus or valgus osteotomies

Results: The patients was performed at an average age of 21 months (12 to 36); the average age at latest follow-up was 13 years, 4 months (5 years, 2 months to 17 years, 3 months); and the average time follow-up was 7 years, 6 months (5 years, 9 months to 16 years, 8 months) in Group1. Patients were treated at an mean age of 22 months (12 to 36); The mean follow-up was 72.1 months (58 to 115); and the mean follow-up time was 41 months (32 to 53 months) in Group 2. Gender: Boy are 105 (24.9%), Girl are 316 (75.1%); Number hip: 284 hips in Group 1, 198 hips in Group 2, total: 482 hips; Side: Bilateral are 56 (13.3%), Left are 295 (70.1%), Right are 70 (16.6%); Tonnis grade: Tonnis 3 in 115 (23.9%) hips, Tonnis. 4 in 367 (76.1%) hips. Group 1/Group 2 show: Acetabular Index: Pre-operation 42.85/46.5; Post-operation 24 months: 19.45°/20.1°; At latest 16.75°/19.9°; Improvement Pre-Immediate Operation of AI: 23.56° (45.0%)/25.35° (45.5%), Pre- At latest: 16.75° (60.9%)/17.5° (57.2%). Accepted Results (Excellent and Good) 262 (92.2%) hips in Group 1 and 188 (91.0%) hips in Group 2 (P value: 0.598613) and none accepted 22 (7.8%) hips in Group 1 and 10 (5.0%) hips in Group 2 (P value: 0.19888) Limited Trendelenburg gait and Incision in SIO/ZPFA 41/6 and 17 cm/6 cm.

Conclusion: The functional and radiographic results of surgical reconstruction for DDH according to McKay and Severin classifications in 284 hips of Group1/198 hips of Group 2 with clinically and radio graphically good or excellent results were 92.5% and 82.6%/95% and 93.9%. ZOFA technique didn't use autograft wedge and Kirchner wire so without complications of them. The blood loss from ZOFA procedure is acceptable. Blood transfusion after surgery is not mandatory in this procedure.

Keywords: Congenital Dislocation of the Hip; Development Dysplasia of the Hip; Bone Allograft, Re-Dislocation, Central Edge Angle

Introduction

Developmental dysplasia of the hip (DDH) was pathologic condition with dysplasia of the acetabular and Dislocation of the Hip. This status common diagnose when the children start walking due to lack of screening programme. The treatment of DDH in new born and child of walking age are quite different principles and post-operative complications. The some changing anatomies common shown child

of walking age such as acetabular dysplasia, extraarticular soft tissues, fibrofatty tissue in the acetabulum, hypertrophied ligamentum teres, increased femoral anteversion, capsular constriction, and fixed inversion of limbus [1].

The some procedures of treatment of DDH include Bracing, Traction, Closed reduction, Open reduction (OR), and Pelvic or/and Femoral osteotomies [2,3]. The incidence of osteonecrosis of the femoral head has been changed when immobilization hip in plater cast with abduction of the hip 45-50 degrees.

Treatment for DDH should early reduction and stabilization of the joint and improvement of the acetabular normal growth. Although close reduction have been reported with good result 34% and 66% of patients need an operation [4].

In 1961, Salter RB have been described surgical technique acetabuloplasty with innominate osteotomy for Congenital Dislocation of the hip, this technique was widely used in the world. However, this procedure still had some complications and apply for children below 7 years only.

Salter reported radiography with good or excellent in 92% of patients [5].

Post-operative results Salter Innominate osteotomy was related and affected to age of the patient at time operation [6], need OR [7], with or without preoperative traction [4,8], Unilateral or bilateral treatment [3,9].

In 2011, Hung NN have been reported surgical technique acetabuloplasty with Zigzag Osteotomy combined Fibular Allograft (ZOFA) for DDH [10].

Post-operative complications commonest show are Avascular necrosis (AVN), resubluxation or dislocation. Gage and Winter reported having 154 with closing reduction and had AVN in 51 hips (33%) [11]. Morcuende, *et al.* reported that AVN in 43% of 93 hips was treated with OR through an anteromedial approach [12]. Gulman, *et al.* reported 52 hips with OR and Salter's osteotomy and shown AVN in 33 hips (63%) [6]. The subsequent development of the hip may be significantly impaired by AVN. The factors that are associated with the occurrence of osteonecrosis require further detailed study. The incidence of re-dislocation after OR varies was reported. It seems that depending on the approach used, the age of the patient at the time of initial reduction, and perhaps the specialty of the surgeon.

It has been reported that occurring in 0% - 8% after OR through an anterolateral approach [13,14], and when the medial approach is used, this figure rises to 5% - 14% [14-16]. It has been reported to occur in 0% - 8% following open reduction via an anterolateral approach [13,14], and used the medial approach, this figure rises to 5% - 14% [14-16].

The purpose of this study was to compare the results of Salter innominate osteotomy and Zigzag osteotomy combined Fibular allograft. for developmental Dysplasia of the hip in children aged one and three years.

The purpose of this study was Comparative Outcome between Original Salter Innominate Osteotomy and Zigzag Osteotomy combined Fibular Allograft for Developmental Dysplasia of the Hip in Children aged one and three years.

Materials and Methods

Between 2000 and 2015, 421 patients with DDH underwent OR and Iliac osteotomy (IO) and divided two Groups. Group 1, 284 hips of 245 patients (39 bilateral hips) were operated SIO from January, 2000 to November 2011, and Group 2, 198 hips of 176 patients (22 bilateral) were operated ZOFA from December, 2011 to April 2015.

Patients with teratologic dislocations, neuromuscular disorders and connective tissue, and patients with a previous history of open hip surgery in another hospital were excluded. Patients had Tonnis grades Type I and type II were excluded. Only patients with levels III and IV were included in this study. This study was evaluated with retrospective outcomes and complications following OR and IO. All patients

were operated by a surgeon (author) and evaluated by two and evaluated by two orthopedic surgeons, who were not participation to operate those patients.

All members have confirmed their agreement. This research has been approved by our Institute's Ethics Review Committee and is implemented in accordance with the principles of the Helsinki Declaration.

None had preoperative skin or skeletal traction, nor derotational varus or valgus osteotomies.

Patients were treated at a mean age of 21 months (12 to 36); The mean latest follow-up age was 13 years, 4 months (5 years, 2 months to 17 years, 3 months); and the average time is 7 years, 6 months (5 years, 9 months to 16 years, 8 months) in Group 1.

Patients were treated at an mean age of 22 months (12 to 36); The mean latest follow-up was 72.1 months (58 to 115); and the mean follow-up time was 41 months (32 to 53 months) in Group 2.

Dislocations of the hip according to use Tonnis system [4]. The acetabular index was measured as a common procedure for assessing acetabular dysfunction and subsequent maintenance.

The angle CE is the angle formed by a vertical line through the center of the femoral head and a line from the center through the lateral edge of the acetabular roof. The center of the femoral head is found with the help of concentric circles on a transparent plate. In young children, however, the ossified part of the capital epiphysis is flat which makes determination of the center somewhat difficult. From the age of 8 the center can be measured with accuracy [17].

Surgical technique

Salter Innominate Osteotomy

Surgical procedures include OR, capsulorrhaphy and Salter's surgical with Smith-Peterson's approach to the hip joint. No traction was applied to the hip before the operation. The adductor longus was tenotomy through percutaneous and iliopsoas muscles by the muscular tenotomy in the pelvic bone. The redundant joint capsule is separated from the surrounding gluteus muscles and the joint is exposed with an incision parallel to the rim of the acetabulum. Soft tissue blockages have been eliminated, and transverse ligaments have been transected to create space for the reduction. With the femoral head reduced, the articular capsules were trimmed along the acetabular margin and repaired with interrupted stitches to protect the reduction. The innominate osteotomy technique, including exposures, osteotomy, Autograft, correction, and fixation, was described by Salter [5].

Zigzag Osteotomy combined Fibular Allograft

If under general anesthesia could not abductor hip above 60° should adduction of muscle tenotomy.

Zadeh's stability test was used after OR [18], which was a major indicator of the need for pelvic osteotomies. Only reveal the inner panel of the pot, not reveal the outside of the ilium. Iliac Osteotomy, the first line, transversal line at just above anterior inferior iliac spine 5 mm; the second line, go down and internal oblique to create angle 90 or 135° with the first line (create 90° angle with AI < 45° and 135° with AI > 135° - α angle) distance 5 - 7 mm length; the thirst line, to go internal obliquely to create angle 90 -135 ° too, with the second line (create 90° angle with AI < 45° and 135° with AI > 135° - β angle) (Figure 1). A distance of 8 to 10 mm and horizontal of the first line; fourth line, thirst line connected and down, distance 10 mm in length; The fifth line, perpendicular to the fourth line, goes into the horizontal line, a distance of 6 - 8 mm in length. After outlining the pelvic osteotomy produced by multiple drill -holes, a small pointed osteotome was used to complete the cuts by connecting these boreholes (Figure 1).

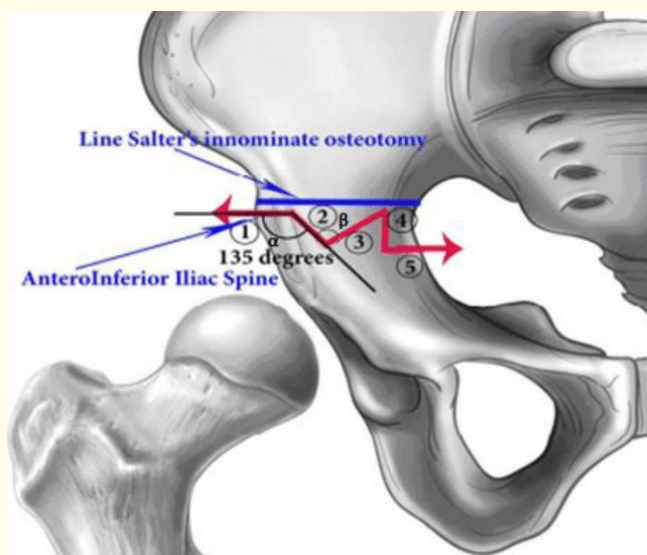


Figure 1: Lines osteotomy of Ilium. Angle β and α are 135°.

Next, use curette to remove cancellous at both side on top and bottom of the ilium stool to create a slot receiving fibula allograft. Fibular Allograft is placed between the two sides of the ilium and maintains its movement (Figure 2) so that Fibular grafting lateral displacement 2 mm is needed, and fibular allograft is compressed between both side on top and bottom segment of ilium.

To measure the distance to the underside of the pelvic segment from 11 to 13 mm, the equilibrium equal distance from anterior superior iliac spine to anterior inferior iliac spine and the lower front hip was measured according to Salter's technique [5].

The osteotomy should be very stable when the two segments are engaged.

The distal segment of the iliac occurs to pass through the pubic symphysis, as in the Salter graft, and is pulled in exactly the same way, thus anterior and lateral acetabular coverage occurs simultaneously, as described by Salter and Dubos [5,19]. The Osteotomy is held open with a wedge of bone graft, whose base is the length from the front higher than the first pinch. The lower, reliable improvement of the front and lateral covering is 25 degrees and 15 degrees respectively [5]. The distal rotation of the distal segment occurs through the pubic symphysis, as in the Salter osteotomy, and is pulled in exactly the same way, so the frontal and outer acetabular coverage occurs simultaneously, as described by Salter and Dubos [5,19].

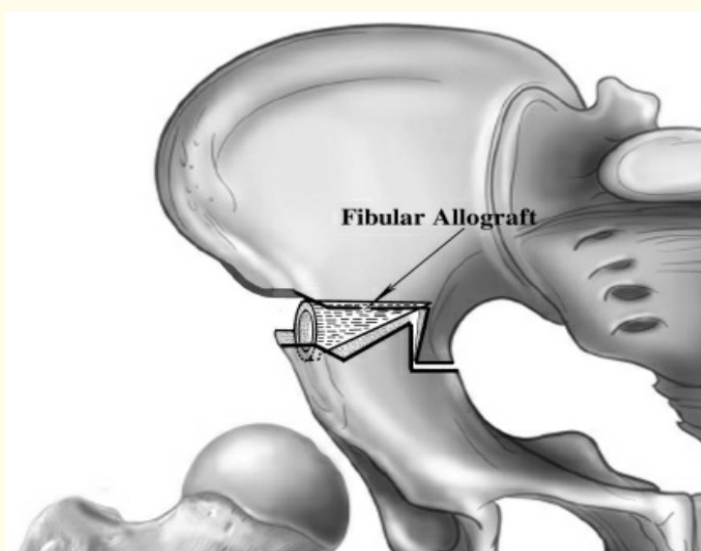


Figure 2: The Fibular Allograft is placed between the two fragments of Ilium.

A bilateral hip spica cast with the hips in human position was applied at surgery. Hip spica was maintained for 3 months in a double hip spica cast with the hip maintained at 30° flexion and 45° abduction, neutral rotation position. After removed spica cast, abduction brace was used for 3 months. Afterwards, the brace was worn at night for an additional 3 months for a total brace time of 6 months.

Evaluating Result

Patients are scheduled to return to the outpatient clinic every 3 months for the first time after 3 month, 6 month, 1 year, and 2 year follow-up surgery and then after each period of the year.

Patients were evaluated clinically for each visit such as affected hip movement, walking quality, Trendelenburg test, and the presence of any pain.

Radiation of each hip was performed to assess deterioration, AI, and presence or absence of AVN. The preoperative radiographic image of each patient was evaluated to determine the AI and the station. Changes in leg length can be measured by physicians during physical exams and through X-rays. Usually, the doctor measures the hip level when the child is standing barefoot.

Assessment of AVN of the femoral head was classified according to Kalamchi and MacEwen's classification [15]: Grade 1: Changes affecting the ossific nucleus; Grade 2: Lateral physeal damage; Grade 3: Central physeal damage; Grade 4: Total damage to the head and physis.

X-ray classification according to Severin [20] was used for radiographic evaluation of postoperative outcomes: Grade 1: normal; Grade 2: Moderate change of head or thighs or muscles; Grade 3: Dysplastic no subluxed; Grade 4: subluxed; Grade 5: Head articulating with secondary acetabulum in upper of the original acetabulum; Grade 6: Dislocated; Grade 7: Arthritic.

Barrett's modification of McKay's criteria [21] was classified for the clinical assessment of postoperative results: Excellent result: Stable, painless hip, no limp, negative Trendelenburg sign, full range of motion; Good result: Stable, painless hip, slight limp, slight degree in range of motion; Fair result: Stable, painless hip, limp, positive Trendelenburg sign, and limited range of motion, or a combination of these; Poor result: Unstable or painful hip, or both, positive Trendelenburg sign.

Statistical analysis

Data were analyzed using the Epi Info Software Public 6.04 for epidemiology, developed by the Centers for Disease Control and Prevention (CDC) in Atlanta, Georgia, USA, <http://www.ncdc.gov/epiinfo/html/prevVersion.htm>. We have taken the χ^2 quiz and the t-test to compare the average among the groups before and after surgery. P values below 0.05 are considered statistically significant.

Results

Between 2000 and 2015, 421 patients with DDH underwent OR and Iliac osteotomy (IO) and divided two Groups. Group 1, 284 hips of 245 patients were operated SIO from January, 2000 to November 2011, and Group 2, 198 hips of 176 patients were operated ZOFA from December, 2011 to April 2015.

Gender: Boy are 105 (24.9%), Girl are 316 (75.1%); Number hip: 284 hips in Group 1, 198 hips in Group 2, total: 482 hips; Side: Bilateral are 56 (13.3%), Left are 295 (70.1%), Right are 70 (16.6%); Tonnis grade: Tonnis 3 in 115 (23.9%) hips, Tonnis. 4 in 367 (76.1%) hips.

	Number Patients	Gender		Side			Tönnis - Hips		Age at Operation (months)	Age La. F-U (Ye, mo)	Time F-U (Ye, mo)
		Boy (%)	Girl (%)	Left (%)	Right (%)	Bilateral (%)	Tön. 3 (%)	Tön. 4 (%)			
Group 1	245	63 (25.7)	182 (74.3)	172 (70.2)	39 (15.9)	34 (13.9)	69 (24.3)	215 (75.7)	15.4 (12 - 36)	9,5 (5,4 - 16,8)	9,8 (6,8 - 16,4)
		245 Patients									
Group 2	176	42 (23.9)	134 (76.1)	123 (69.9)	31 (17.6)	22 (12.5)	46 (23.2)	152 (76.8)	14.8 (12 - 36)	4,9 (3,2 - 6,7)	4,9 (3,5 - 6,6)
		176 Patients									
	421	105 (24.9)	316 (75.1)	295 (70.1)	70 (16.6)	56 (13.3)	115 (23.9)	367 (76.1)	15.1 (12-36)		
		421 Patients									

Table 1: Data of the Patient.

Age La.F-U: Age at latest Follow-up; Time F-U: Time Follow-up; Age La.F-U: Age at latest Follow-up; Time F-U: Long time Follow-up; Ye, mo: Years, months; Gro.: Group.

Number patient: 421; Gender: Boy are 105 (24.9%), Girl are 316 (75.1%); Number hip: 284 hips in Group 1, 198 hips in Group 2, total: 482 hips; Side: Bilateral are 56 (13.3%), Left are 295 (70.1%), Right are 70 (16.6%); Tönnis grade: Tönnis 3 in 115 (23.9%) hips, Tönnis. 4 in 367 (76.1%) hips. Age at time Operation: 15.1 months (12 - 36 months). Average age at latest Follow-up: 9 years, 5 months (5 years, 4 months - 16 years, 8 months) in Group 1; Average age at latest Follow-up: 4 years, 9 months (3 years, 2 months - 6 years, 7 months) in Group 2. Average duration Follow-up: 9 years, 8 months (5 years, 6 months - 16 years, 4 months) in Group 1, Average duration Follow-up: 4 years, 9 months (3 years, 5 months - 6 years, 6 months) in Group 2.

		Acetabular Index						
		Pre-Op (°)	Imm.Op (°)	PostOpe. 3 mo (°)	PostOpe. 6 mo (°)	PostOpe. 12 mo (°)	PostOpe. 24 mo (°)	At latest (°)
Group 1	284	42.85	23.56	22.88	21.5	29.54	19.45	16.75
	SD	4.404	2.5452	2.0212	2.280	1.769	1.708	1.248
	Range	36.1 - 51.5	18.2 - 29.3	18.1 - 28.4	16.6 - 25.8	15.3 - 23.4	15.2 - 23.5	14.6 - 18.6
	P value	< 0.05						< 0.05
	Impro.	45.0%			60.9%			
Group 2	198	46.5°	26.1°	22.53	21.68	20.59	20.1	17.5
	SD	4.567	2.398	2.275	2.00	1.805	1.432	1.649
	Range	31.2 - 66.1°	25.35 - 26.8°	18.9 - 25.4	17.7 - 25.2	16.5 - 22.5	16.1 - 23.8	14.4 - 21.6
	P value	< 0.05						< 0.05
	Impro.	45.5%			57.2%			

Table 2

Pre-Op: Pre-Operation; Imm.Op: Operation Immediately; PostOpe.: Post-Operation; mo: month; Impro: Improvement.

Group 1 Group 2 show: Acetabular Index: Pre-operation 42.85/46.5; Post-operation 24 months: 19.45°/20.1°; At latest 16.75°/19.9°; Improvement Pre-Immediate Operation of AI: 23.56° (45.0%)/25.35° (45.5%), Pre- At latest: 16.75° (60.9%)/17.5° (57.2%).

	Wedge graft			Kirschner wire		Blood loss (ml)	Time Operation (minute)
	Absorption	Displacement	Broken	Immigration	Broken		
Group 1 n = 284 (Autograft)	4 (1.5%)	5 (1.8 %)	2 (0.7%)	3 (1.1%)	2 (0.7%)	180 (150-250)	80 (60-90)
Group 2 n = 198 (Allograft)	0	0	0	0	0	95 (85-120)	90 (75-105)

Table 3: Complications of Graft fragment, Kirschner wire, Blood loss, and Time Operation.

Salter Innominate Osteotomy have been used Autograft and Kirschner wire so with Absorption, displacement, Immigration, broken. Zigzag Osteotomy combined Fibular Allograft without those complications because didn't use them.

Blood loss according to the ZOFA procedure is acceptable. After surgery, blood transfusion is not necessary in this procedure.

	Number hip	Modified McKay criteria for clinical evaluation			
		Excellent (%)	Good (%)	Fair (%)	Poor (%)
Group 1	284	210 (73.9)	52 (18.3)	15 (5.3)	7 (2.5)
Group 2	198	153 (77.3)	35 (17.7)	7 (3.5)	3 (1.5)
P value		0.4043	0.8588	0.366123	0.692956

Table 4: Barrett Modified McKay criteria for clinical evaluation [20].

Accepted Results (Excellent and Good) 262 (92.2%) hips in Group 1 and 188 (91.0%) hips in Group 2 (P value: 0.598613) and none accepted 22 (7.8%) hips in Group 1 and 10 (5.0%) hips in Group 2 (P value: 0.19888)

The skin incision (Smith-Peterson) was used in all prospective cases SIO. Average scar skin length in SIO/ZOFA: 17 cm (15 - 20 cm)/6 (4 - 8 cm).

The defect Anterolateral of the Ilium because it were removed wedge graft so prominent of affected hip all patient had operated Salter innominate Osteotomy.

	Number hip	Severin criteria					
		Type I (%)	Type II (%)	Type III (%)	Type IV (%)	Type V (%)	Type VI (%)
Group 1	284	221 (77.8)	42 (14.8)		14 (4.9)		7 (2.5)
Group 2	198	158 (79.8)	28 (14.1)		9 (4.5)		3 (1.6)
P value		0.7270	0.8500		0.9609		0.5789

Table 5: Deformity of femoral head or neck or acetabulum according to Severin [22].

Group 1/Group 2 with favorable result 263 hips (92.6%)/188 hips (94.9%), P value 0.302074: and none favorable 21 hips (7.4%)/10 hips (5.1%), P value 0.302074.

Center edge angle (CEA) of Wiberg [17]	Preoperative (°)		Immediate Operative (°)		Latest Follow-up (°)	
	Range	Average	Range	Average	Range	Average
Group 1 (SIO) n = 284	-	-	7 - 35	27	16 - 45	33
Group 2 (ZOFA) n =198	-	-	8 - 33	26	17 - 48	36

Table 6: Center edge angle (CEA) of Wiberg [17].

Salter innominate Osteotomy with Latest follow- up for 284 hips and average CEA 33°. Patients in this group 1, average age at latest follow-up was 9.6 years (6.8 - 16.8 years). In Group 2 (Zigzag Osteotomy combines Fibular Allograft) with Latest follow- up for 116 hips and average CEA 36°, those patients with average age at latest follow-up was 7.2 years (5,4 - 16.8 years) (there were 82 patients with age below 5 years old).

	Redislocation	Avascular necrosis (%)	Coxa magna (%)	Coxa vara (%)	Fracture (%)	Trendelenburg gait (%)	Infection (%)	Limb Discrepancy (%)	Lateral cuta. nerve (%)
Group 1 n= 284	22 (7.8%)	72 (25.4)	7 (2.5)	6 (2.1)	4 (1.4)	41 (14.3)	0	26 (9.2)	8 (2.8)
Group 2 n= 198	14 (7.1%)	47 (23.7)	4 (2.02)	5 (2.5)	3 (1.5)	6 (3.0)	0	14 (7.1)	3 (1.5%)
P value	0.7812	0.685	0.9907	0.99076	0.7713	< 0.05		0.4144	

Table 7: Complications.

Lateral cuta.nerve: Lateral cutaneous nerve of the thigh

Some complications such as Redislocation, Avascular necrosis, Coxa magna, Coxa vara, Fracture was not statistically significant (P Value > 0.05). Trendelenburg gait were Statistical significance (P Value < 0.05).

	No. hips with AVN (%)	Classification according to Kalamchi			
		I (%)	II (%)	III (%)	III (%)
Group 1 n = 284	72 (25.4)	9 (12.5%)	48 (66.7%)	15 (20.8%)	0
Group 2 n = 198	47 (23.7)	5 (10.6%)	34 (72.3%)	8 (17.1%)	
P value	0.7812				

Table 8: Avascular Necrosis according to Kalamchi [15]

AVN Classification according to the Kalamchi SIO/ZOFA with Grade I: 25.4%/23.7%, Grade II: 12.5%/10.6%, Grade III: 20.8%/17.1%.

Illustrations

Case 1

A girl, 22 months old, with Developmental Dysplasia of the Left hip. Tonnis grade 4. Preoperative Acetabular Index was 37°. Femoral Neck Anteversion Angle was 35°. Shaft-Neck Angle was 140°. MRI with Acetabular anteversion 22.9°. The patient have been operated OR and traditional Salter innominate Osteotomy. Patient place bilateral hip spica cast with the hips in human position was applied at surgery. Hip spica was maintained for 3 months in a double hip spica cast with the hip maintained at 30° flexion and 45° abduction, neutral rotation position. After removed spica cast, abduction brace was used for 3 months. Afterwards, the brace was worn at night for an additional 3 months for a total brace time of 6 months.

AI operation Immediately were 21°, CEA 27°. Age at time Follow-up was 10 years - 4 months with AI 15.8°, CEA 38.2°. Result according to Barrett Modified McKay criteria for clinical evaluation was good and Deformity of femoral head or neck or acetabulum according to Severin was Type II.

Operative Incision (Figure 3), Scar incision 18 cm lengthen (Figure 4), AI pre-operative 43.3 and poet-operative 6 months was 21.1° (Figure 5A and 5B).

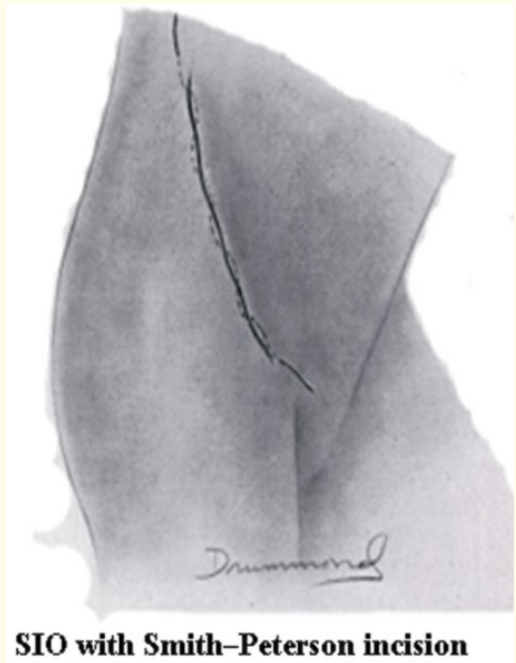

Figure 3: Operative Incision.

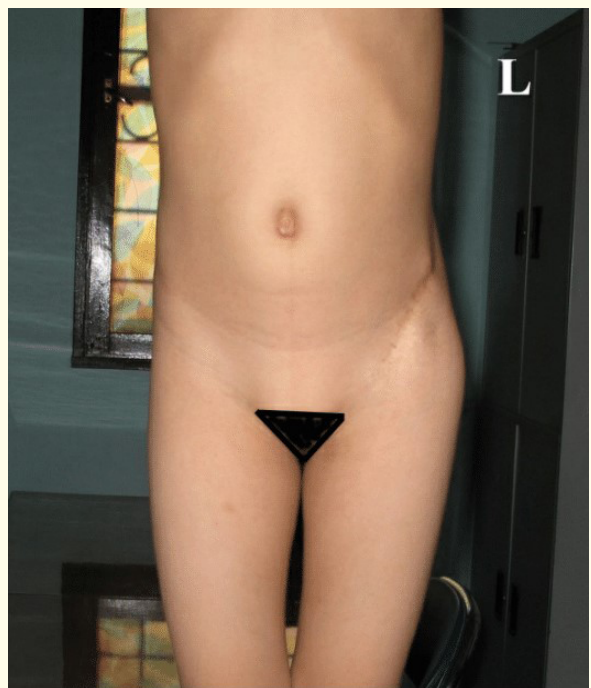

Figure 4: Post-Operative Scar incision 18 cm.

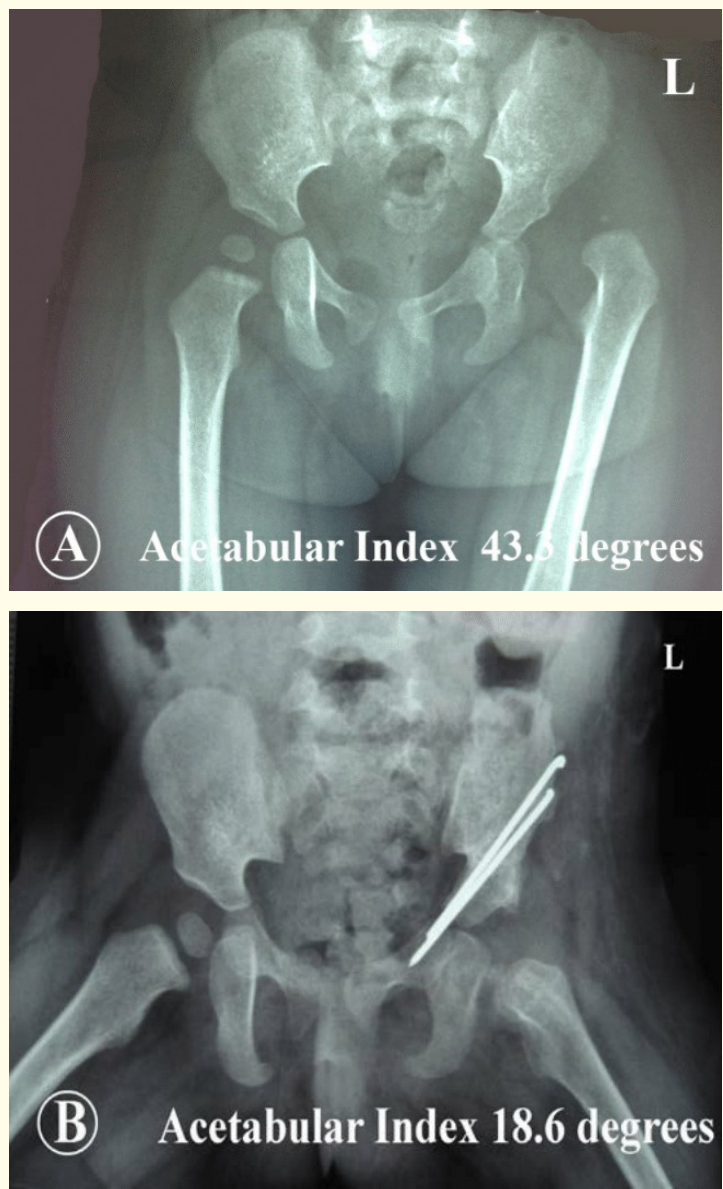


Figure 5A and 5B: Figure 5A, AI Pre-operation was 43.3°; Figure 5B, AI Post-Operative 6 months was 18.6°.

The patient with Positive Trendelenburg gait (Figure 6A and 6B), Prominent affected hip (Figure 7A and 7B). The patient had well functional result with patient sitting cross legged (Figure 8). Postoperative Roentgenography 10 years, 4 months (Figure 9).

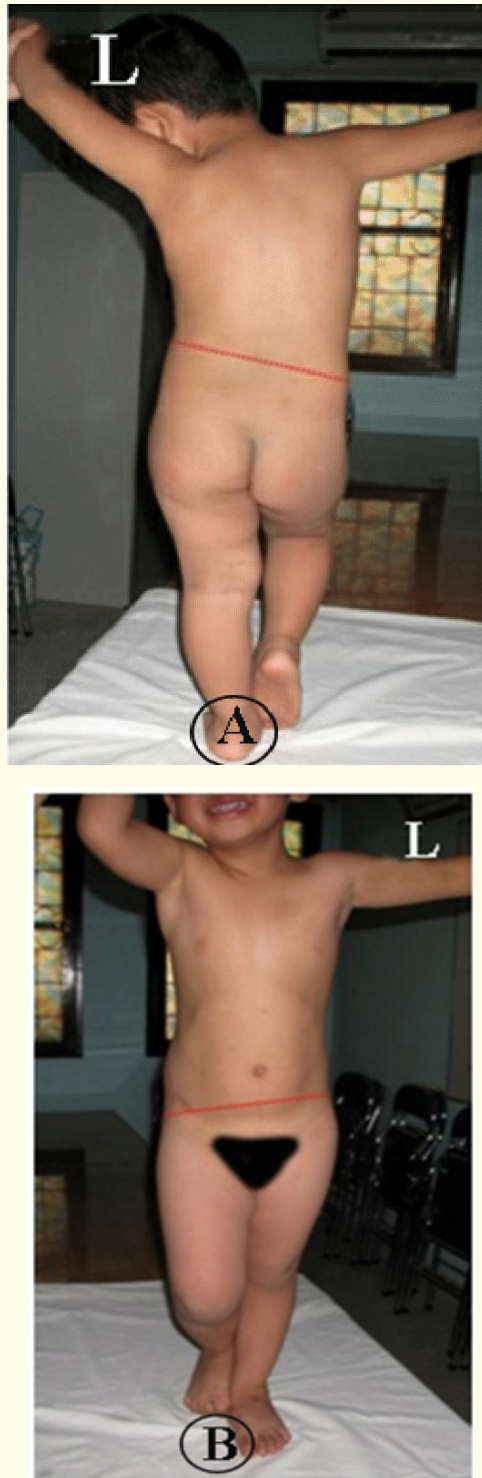


Figure 6A and 6B: Positive Trendelenburg gait.

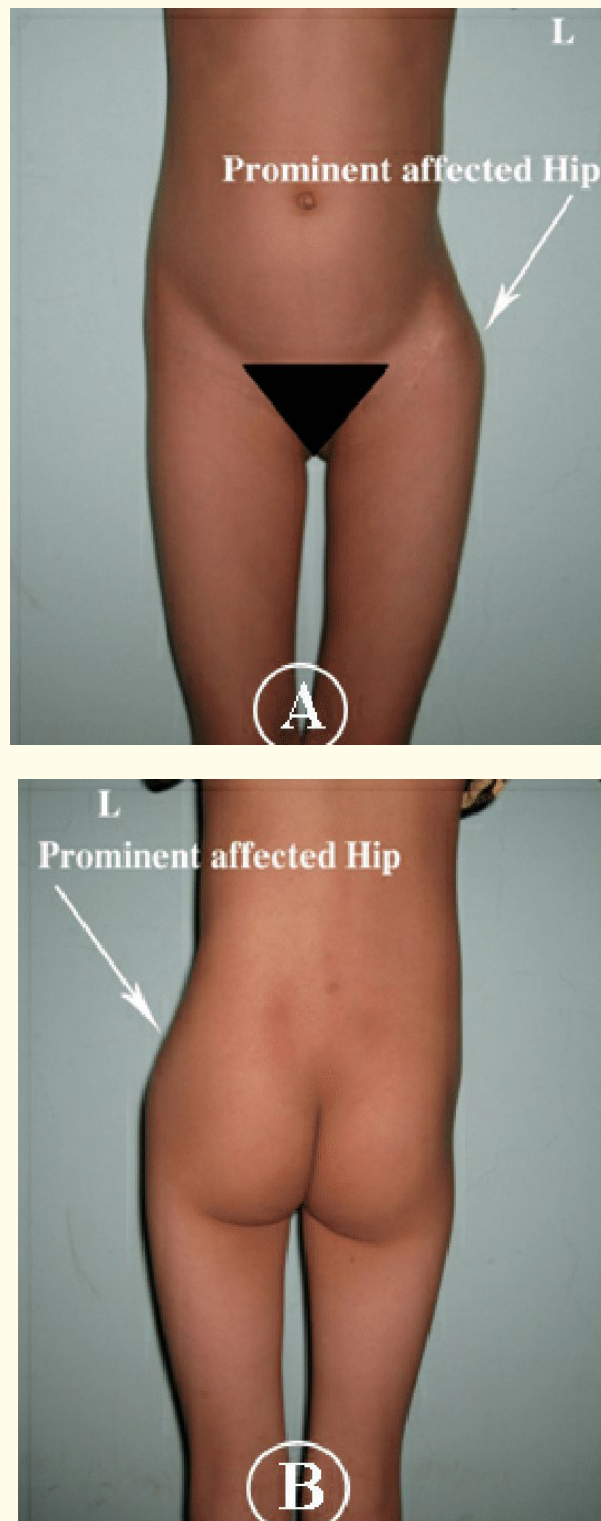


Figure 7A and 7B: Prominent affected hip.

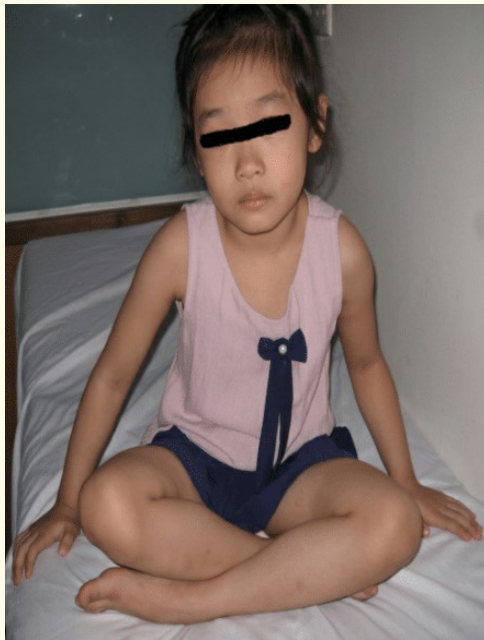

Figure 8: Well functional result with patient sitting cross legged.

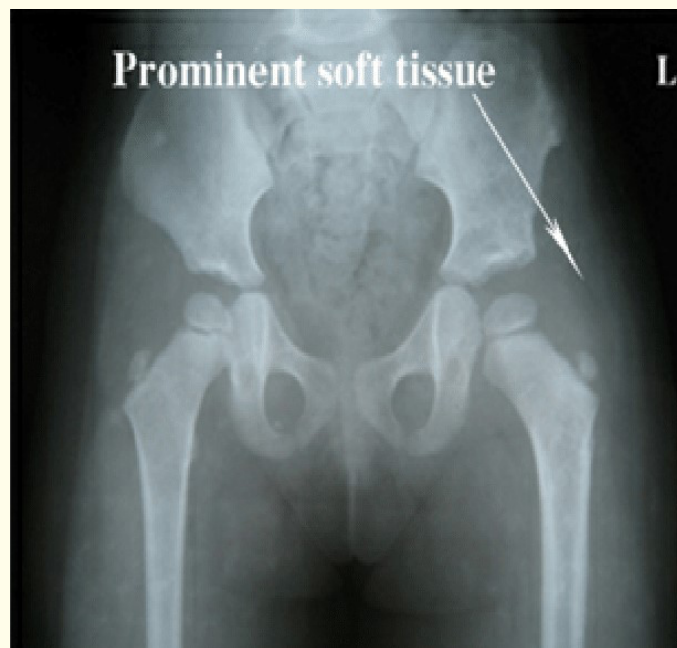

Figure 9: Postoperative Roentgenography 10 years, 4 months.

Case 2

A girl, 18 months old, with Developmental Dysplasia of the Left hip. Tonnis grade 4. Preoperative Acetabular Index was 41°. Femoral Neck Anteversion Angle was 39°. Shaft-Neck Angle was 145°. MRI with Acetabular anteversion 25.8°. The patient have been operated OR and ZOFA. Patient place bilateral hip spica cast with the hips in human position was applied at surgery. Hip spica was maintained for 3 months in a double hip spica cast with the hip maintained at 30° flexion and 45° abduction, neutral rotation position. After removed spica cast, abduction brace was used for 3 months. Afterwards, the brace was worn at night for an additional 3 months for a total brace time of 6 months.

AI Operation Immediately were 26.4°, CEA 29°. Age at time Follow-up was 6 years-2 months with AI 17.6°, CEA 35.2°. Result according to Barrett Modified McKay criteria for clinical evaluation was good and Deformity of femoral head or neck or acetabulum according to Severin was Type II.

Operative Incision (Figure 10), Scar incision 6 cm lengthen (Figure 11), The patient with negative Trendelenburg gait (Figure 12A and 12B), none Prominent affected hip (Figure 13A and 13B). The patient had well functional result with patient sitting cross legged (Figure 14). Postoperative Roentgenography 6 years, 2 months (Figure 15).

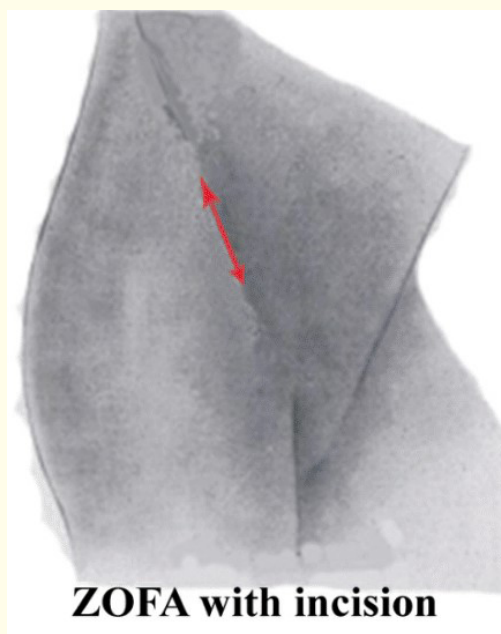


Figure 10: Operative Incision.

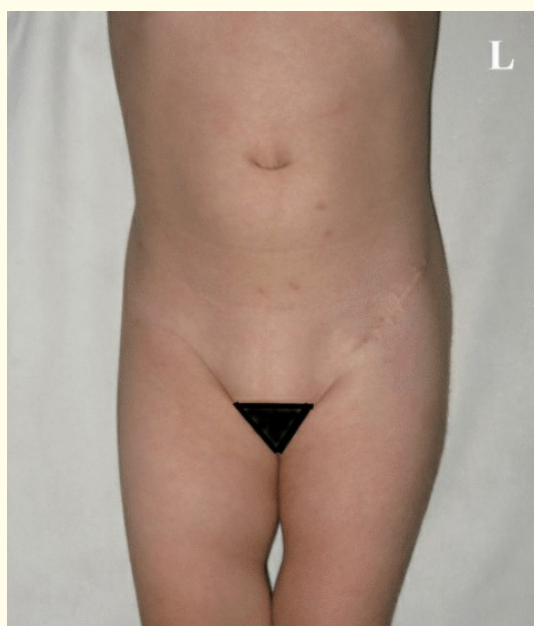


Figure 11: Post-Operative Scar incision 6 cm.

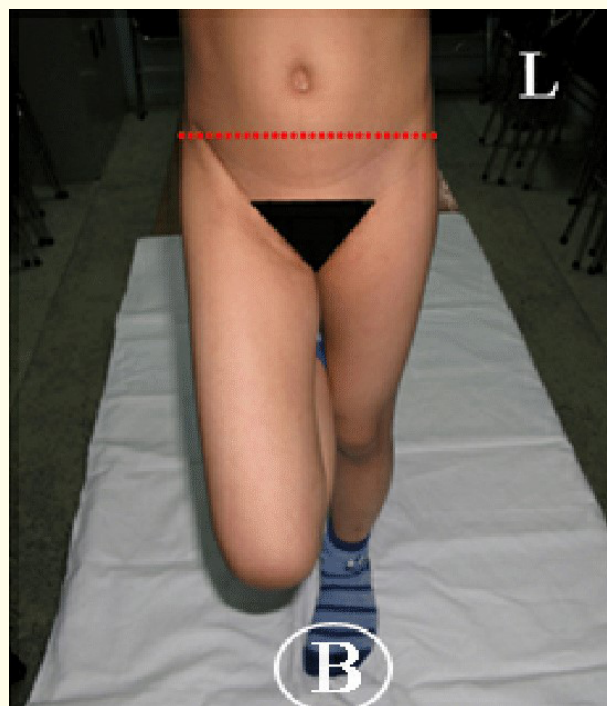
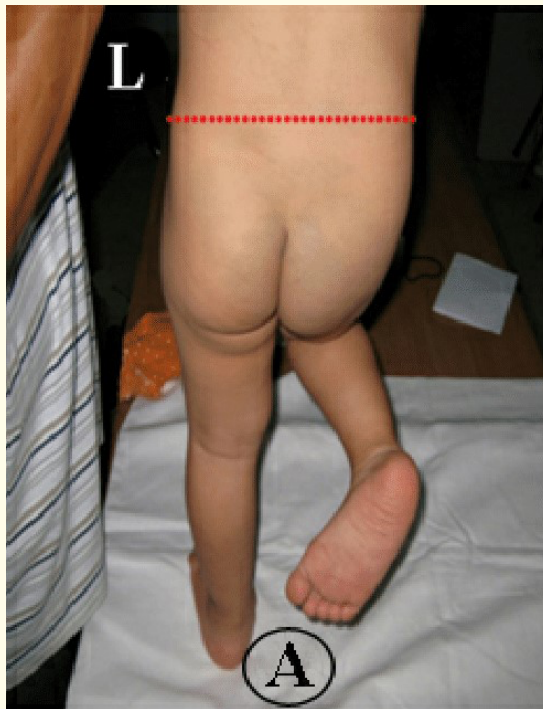

Figure 12A and 12B: Negative Trendelenburg gait.

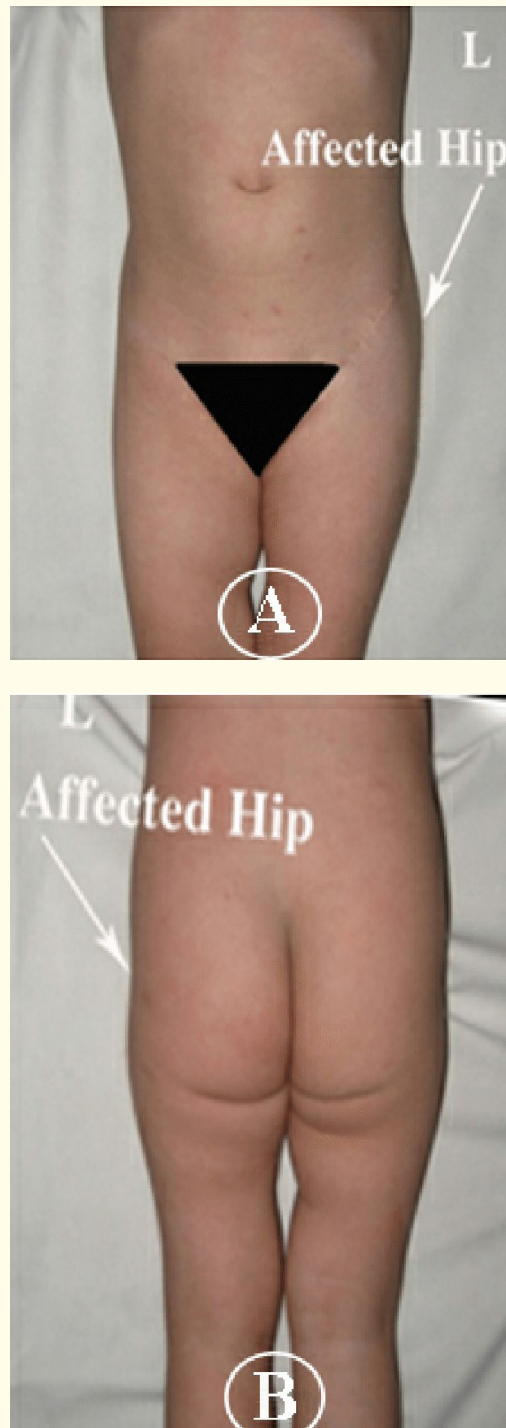


Figure 13A and 13B: None Prominent affected hip.

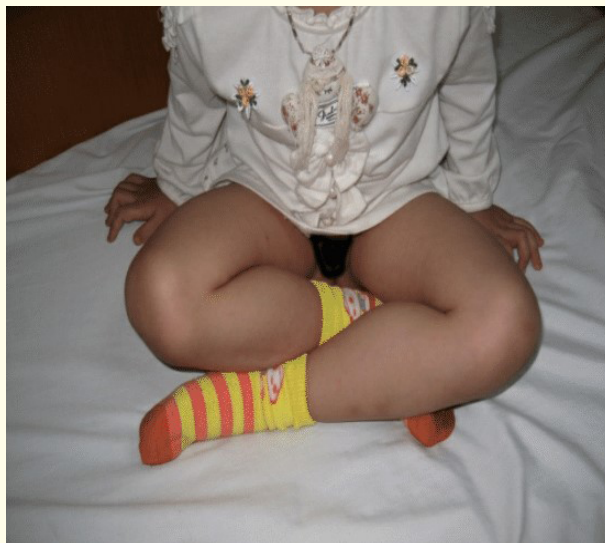

Figure 14: Well functional result with patient sitting cross legged.

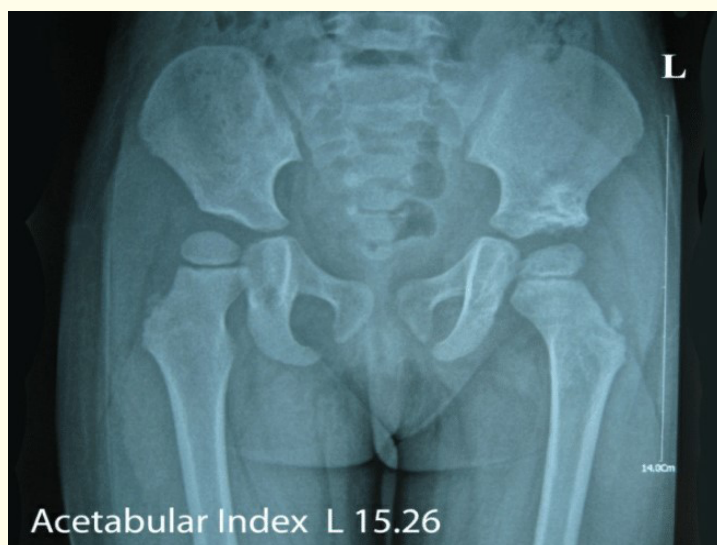

Figure 15: Postoperative Roentgenography 6 years, 2 months.

Discussion

Pelvic osteotomies

There are many types of pelvic osteotomies to treat the dysplastic hips. To determine which bone resorption surgery is most appropriate, we should consider concentric the femoral head, age of the patient, and condition of the triradiate cartilage.

The Children below 7 years old usually apply Salter innominate osteotomy or Pemberton osteotomy [22]. Salter and Pemberton acetabuloplasty surgery is the procedure for acetabular deficiency in DDH.

After surgical removal of cartilage tissue, a surgeon removes cartilage tissue that will redirect the entire body of scar tissue after surgical removal of cartilage tissue. The goal of these procedures is to improve thigh maturation for asceticism.

Following a complete trans-iliac osteotomy, Salter osteotomy redirects the total acetabulum, and crease hinging the horizontal branch of the triradiate cartilage, Pemberton acetabuloplasty osteotomy redirects the shape of the acetabulum following an incomplete osteotomy. The goal of these procedures are to improve the coverage of the femoral head for acetabular dysplasia.

In 1961, Salter [5] described innominate osteotomy for DDH by redirection of acetabulum into a unit. Sater performed transverse osteotomy of the ilium perpendicular to the iliac axis from just above the anterior inferior iliac spine to the sciatic notch.

It is designed to protect the acetabular shape while adjusting the abnormal frontal face of the acetabulum in DDH. The pubic symphysis serve as a rotating hinge and the acetabulum can be diverted to cover the anterolateral deficiency in a concentrically reduced hip after the osteotomy [5].

From 18 months to 4 years of age this group, Salter and Dubos reported 93.6% of good or good results in patients treated from 18 months to 4 years and there was no failure to reconsider 15 years of follow-up 140 patients. The results were excellent or good in only 56.7% with children had 4-10-year-old age group [19]. However, this procedure is not recommended in children more 7 years old [22].

However, implementing its proper technique is not easy. This erroneous procedure leads to a catastrophic outcome of not achieving a concentric reduction of the hip joint before innominate osteotomy. Our patients with age at time operation from 12-36 months (Table 1).

After Salter 1961, some authors performed iliac osteotomy beginning from just above the anterior inferior iliac spine redirects the shape of the acetabulum with purpose are to improve the coverage of the femoral head for acetabular dysplasia such as Pemberton PA 1965 [22], Tavares JO [23], Perlik PC., *et al.* [24], Hung NN 2011 [10].

Hung 2011 [10] performed iliac osteotomy in DDH with Zigzag osteotomy. This procedure is performed by a transverse osteotomy of the ilium perpendicular to the iliac axis from just above the anterior inferior iliac spine to the 5 mm (1 line), line 2 (5 mm), with a 90° angle with the AI. < 45° and 135° with AI > 45° to sciatic point. Line 2 and 3 to create angle the same line 1 and 2 too (Figure 1). Our line have bar osseous is created line 4 and 5 the same fulcrum. The bar osseous bar to prevent move of postero-internal distal ilium.

The Zigzag osteotomy acetabuloplasty have hinging the horizontal branch of the triradiate cartilage following an complete osteotomy but with osseous bar as fulcrum and the aim of this procedures are to improve the anterolateral coverage of the femoral head, and don't decrease in the internal diameter of the pelvis and to avoid damage of the triradiate cartilage (Figure 2). Immediately operate (Figure 2), shown SIO/ZOFA Operation Immediately improvement 19.3° (43.5%) P value < 0.05/ 21.15° (45.5%) P value < 0.05. Statistical significance (Table 2).

There are two bars osseous and two slots in proximal and distal segment of the ilium; this stability is apparent during surgery by grafts unable to translate or rotate or slipped.

This transplant stability specifically removes the need for conventional internal fixation of bone-cutting surgery. Extrusion or transfer of fibular Allograft did not occur in our series. In the document, the rate of graft displacement ranges between 0% and 17%, the rate of graft displacement ranges between 0% and 17% [21,25-27].

In the surgical OZFA, the grafting displacement rate was 0% in this study. Post-operative result of graft may be the result of the care taken to check the stability this technique (Figure 2). After surgery, the fibular allografts were completely incorporated mean 14 weeks (range, 12 weeks - 17 weeks). In SIO with wedge graft Absorption 1.5%, Displacement 1.8%, Broken 0.7% (Table 3).

Severin 1941 [20] suggests that 21 degrees at 10 years of age and above are normal corners of normal. If the angle is less than 21 degrees, the acetabulum is considered normal; If over 21 degrees, some failure of the development of different degrees have been recognized and they are classified as good (22 - 24 degrees), fair (25 - 27 degrees) and poor if the angle exceeds 27 degrees.

The post-operative SIO and ZOFA 24 months with AI are 19.5° and latest result 15.75°/AI are 20.1° and latest result 17.5 in this study (Table 2). Our results with SIO/ZOFA according to Barrett Modified McKay criteria for clinical evaluation [21] with Satisfactory and an unsatisfactory were the same (P value > 0.05) (Table 4).

The Salter's osteotomy is suitable for an acetabulum with a short pelvic and acetabular index of up to 35°, while the Pemberton acetabuloplasty is suitable for an acetabulum with a long pelvic portion and an acetabular index of up to 50° [25,26] or 45° [28]. The SIO initially described have to expose both tables of ilium, so increasing the amount of bleeding in the operation [5].

The mean blood loss in SIO/ZOFA 180 ml (150-250) [19]/95ml (85 - 120), the blood loss from ZOFA is acceptable. After operation, blood transfusion was no required in this procedure. The mean time Operation in SIO/ZOFA 80 minute (60-90) [19]/90 (75 - 105) (Table 3).

ZOFA did not expose the outside of the ilium, so hip abductor muscles were not injury and to reduce rate Trendelenburg test. Witzleb WC [29] showed 13% postoperative the three months follow-up examination. Showed SIO/ZOFA with Trendelenburg gait 41 (14.3%) / 6 (3.0%) P value < 0.05. We didn't use Kirschner wire so without complication of it (Table 3). Several research works have evaluated the functional and radiographic outcomes of surgical reconstruction for DDH. Karakas., *et al.* [30] with 67% of the clinical outcome and 65% of the good results in terms of graphics or excellent results according to McKay [8] and Severin [20] classification in 55 hip with the reconstruction of an one-stage hip stage. Forlin., *et al.* [31] have reported series of 20 children (24 hips) with DDH treated reconstruction who were 4 and 12 years of age.

They had excellent or excellent results in 17% (70%) of the hips under McKay and Sever in the classification. Poor results were reported in patients over 7 years at the time of hip reconstruction. Umer., *et al.* [32] reported a series of 23 patients (29 hips) treated with a hip reconstruction. Patients with an mean age of 6.8 years. According to the Mc Key classification [8], Mean follow-up time was 19.6 months, excellent or good results were obtained at hip 25 (86%). According to Severin's classification [20], Ganger., *et al.* [33] with excellent or good results in 80% of the hip after treatment with a hip stage reconstruction, the median follow-up was 3.5 years. Galpin., *et al.* [34] results in 75 - 85% of patients after clinical and clinical evaluation. Previous studies have shown that better results are obtained when younger patients are at the time of surgery [19]. In this study, the functional and radiographic results of surgical reconstruction for DDH according to McKay [8] and Severin [20] classifications in 284 hips of Group1/198 hips of Group 2 with clinically and radio graphically good or excellent results were 92.5% and 82.6%/95% and 93.9% (Table 4 and 5). Issues such as extrusion, rotation and absorption, leading to loos of acetabular correction, were often noted in cases that have been treated in our hospital.

In cases of bilateral dislocation, the iliac crest autograft was found to be profusely weak at the time of the second hip surgery due to spica immobilisation after first hip surgery. Autograft concern is further supported by authors who suggest the routine use of internal fixation, especially in older children [35,36]. Graft displacement resulting in redislocation of the hip has been reported in the literature [22,37]. We believe that these complications can be attributed to the paucity of the autograft. Concerns regarding the integrity of the autograft prompted the authors to use a more stable and structurally sound interposition material which could be contoured to the shape of the osteotomy site.

The use of allograft in paediatric orthopaedics has gained acceptance and is regarded to be safe. In this study, Salter innominate Osteotomy used wedge Autograft and shown complications such as Absorption 1.5%, Displacement 1.8%, Broken 0.7% (Table 3).

Center-Edge angle

The CE angle is an excellent method of studying the development of the hip jointing radiograms. It is simple and unlike other measurements [38] requires only a few lines to be drawn on the radiogram [39]. The results of the present investigation confirm previous findings. CE angles exceeding 25° in adults are normal and values between 20° and 25° are borderline. In children under 15 years of age, however, 20° or more should be considered as normal and values between 15 and 20° as uncertain [40].

The CEA in this study improved to postoperative immediately value of 26°; This value continues to improve in the next phase, reaching an mean of 34.5°. These results are comparable to those of similar studies reported in the literature [41,42].

This angle is considered to be of particular importance as it is believed to be involved in the risk of bone loss. In our study, hips with favorable CEA were found to have very good survival rates at the end of the next stage, with no evidence of arthrosis. These results are also comparable to those reported in the literature. This angle is considered to be of particular importance as it is believed to be associated with a risk of bone loss. In our study, hips with favorable CEA were found to have very good survival rates at the end of the next stage, with no evidence of arthrosis. These results are also comparable to those reported in the literature [17,41]. In addition, the hip with unfavorable CEA showed a less favorable outcome and varying degrees of hip arthrosis (Grade 2 and 3). In this study, average CEA in SIO/ZOFA Immediate Operative were 27°/26°, and Latest Follow-up were 33°/36° (Table 6).

Redislocation of the Hip

Putti [43] distinguished subluxation from dislocation on the basis of the relationship between the articular surfaces of the femoral head and the acetabulum.

He noted that the femoral head in subluxation was arranged abnormally in the socket, whereas in dislocation, the head lay completely away from the acetabulum. Although the articulation were in contact, the femoral head are not congruently or concentrated in the acetabulum. In the current study, two patients (4.5%) had recurrences of the hip.

The redislocation in 3 of 54 hips with Rudolf, *et al.* [33] reported, Grill [44] reported 12 of 50 hips with redislocation and resubluxation. Ruszkowski and Pucher [45] with one of 33 hips in 26 children with redislocation. Both Tachdjian [46] and Fixsen [47] confirm that the reasons for failure to maintain a reduced hip are a poorly executed osteotomy, a lax capsulorrhaphy and excessive femoral anteversion. The capsulorrhaphy have helped to prevent posterior displacement in the early postoperative period while the hip is remodeling. In this study, had 22 (7.8%) hips in SIO and 14 (7.1%) hips with redislocation.

We assume that technical failure is often the cause of re-dislocation with all had an intact an intact anteromedial capsule, there was an inverted transverse ligament, tight psoas tendon, eversion of the limbus, and densing anterior capsule. We performed with all the hips that had been removed by scar tissue; adductor tenotomy; hips required release of the psoas tendon, eversion of the limbus; release of the transverse ligament was required.

The hips required femoral shortening (average of 1.5 cm), should be performed in hips from ten and twelve weeks after repeat open reduction In this study, there were Re-Dislocation in SSIO/ZOFA were 22/14 hips (Table 7).

Avascular Necrosis Femoral Head

Vascular necrosis, also known as bone necrosis, bone marrow infarction, aseptic necrosis and ischemic necrosis, is a cellular necrosis of interrupted bone components that supply blood. Without blood, bone tissue would die and bone would collapse. If AVN is involved in bones, it often results in the destruction of joint articular surfaces.

AVN is commonly show in the complications of DDH, they had rate management programs, and the rate of AVN affection among our pediatric patient cohort is comparable to published results zero to 73 per cent [41,48]. The early signs of AVN serve as an independent variable.

AVN had related with the age of the patient at the time of operation, gender, Iliac Osteotomy procedures, and immobilization hip in the plaster cast.

Unfortunately, AVN of the femoral head and physis lesions after treatment for DDH replacement are a serious complication and prevent good long-term outcomes [49]. The actual rate of AVN is very difficult, if not impossible, to evaluate because there are many different treatments for the DDH. In addition, the criteria to determine the presence of AVN vary considerably with each series. The most feared complication of DDH is AVN. Diagnosis can be difficult, and a series of radiographs is needed in a considerable time. In the early stages, it is defined as epiphysitis.

Later, blood vessel damage progresses in femoral proximal areas and in the acetabulum. Kalamchi and MacEwen classify changes in blood vessels. Kalamchi reported that the frequency of AVN was from 0% to 73%. [15]. Barrett reported shown AVN was 6% [21]. Hajdar reports AVN is 8.1% [50]. In the cause of AVN, there are two factors: obstruction of the extracellular pocket by fixation and mechanical pressure. In this study, AVN Classification according to the Kalamchi SIO/ZOFA with Grade I: 25.4%/23.7%, Grade II: 12.5%/10.6%, Grade III: 20.8%/17.1% (Table 8).

We have Postoperative results and to compare outcome between SIO and ZOFA with the same critical clinical according to Baret [21] and critical roentgenography according to Severin [20]. We could not compare SIO, ZOFA and some other paper and agree Mohameds [48] opinion that “We found it difficult to compare the results of SIO in different studies for the following reasons:

1. The results of the operation tend to change with time (the studies differ widely as to the follow-up period).
2. The variability between the studied reports with regard to the age of the patients, and the younger the age of the patient at the time of surgery, the better the outcome would be.
3. Some authors exclude patients with evidence of AVN of the femoral head established before the operation or patients who underwent previous surgical attempts, whereas others do not make it clear whether their series included cases with preoperatively established aseptic necrosis or underwent previous surgeries or not.
4. All the studies focused their attention on the results of SIO, although the index operation varied between different studies, as some authors performed only SIO, whereas others performed combined pelvic and femoral osteotomies at the same setting or as staged surgeries.
5. A difference was found in performing the operative technique of SIO between different centers, in addition to the different preoperative management techniques, which in turn would influence the final outcome of the surgery”.

Conclusion

Compared between Salter Innominate Osteotomy and Zigzag Osteotomy combined Fibula Allograft with the same criteria for clinical and roentgenography evaluation for postoperative results.

The functional and radiographic results of surgical reconstruction for DDH according to McKay and Severin classifications in 284 hips of Group1/198 hips of Group 2 with clinically and radio graphically good or excellent results were 92.5% and 82.6%/95% and 93.9%. ZOFA technique didn't use autograft wedge and Kirschner wire so without complications of them. The blood loss from ZOFA procedure is acceptable. Blood transfusion after surgery is not mandatory in this procedure. Limited Trendelenburg gait and Prominent affected hip in ZOFA. Mean Incision of SIO/ZOFA 17 cm/6 cm.

Limits in this Study

1. This paper with retrospective for SIO and retrospective for ZOFA, not homogeneous data.
2. The patients were not followed-up to skeletal maturity.

Bibliography

1. Bhuyan BK. "Outcome of one-stage treatment of developmental dysplasia of hip in older children". *Indian Journal of Orthopaedics* 46.5 (2012): 548-555.
2. Morel G. "The treatment of congenital dislocation and subluxation of the hip in the older child". *Acta Orthopaedica Scandinavica* 46.3 (1975): 364-399.
3. Weinstein SL, et al. "Developmental hip dysplasia and dislocation: Part II". *Instructional Course Lectures* 53 (2004): 531-542.
4. Harris NH, et al. "Acetabular development in congenital dislocation of hip". *Journal of Bone and Joint Surgery. British Volume* 57.1 (1975): 46-52.
5. Salter RB. "Innominate osteotomy in the treatment of congenital dislocation and subluxation of the hip". *Journal of Bone and Joint Surgery. British Volume* 43 (1961): 518-539.
6. Gulman B, et al. "Salter's innominate osteotomy in the treatment of congenital hip dislocation: a long-term review". *Journal of Pediatric Orthopaedics* 14.5 (1994): 662-666.
7. Morin C, et al. "Retrospective review at skeletal maturity of the factors affecting the efficacy of Salter's innominate osteotomy in congenital dislocated, subluxed, and dysplastic hips". *Journal of Pediatric Orthopaedics* 18.2 (1998): 246-253.
8. McKay DW. "A comparison of the innominate and the pericapsular osteotomy in the treatment of congenital dislocation of the hip". *Clinical Orthopaedics and Related Research* 98 (1974): 124-132.
9. Salter RB, et al. "Avascular necrosis of the femoral head as a complication of treatment for congenital dislocation of the hip in young children: a clinical and experimental investigation". *Canadian Journal of Surgery* 12.1 (1969): 44-61.
10. Hung NN. "Congenital Dislocation of the Hip in Children between the Ages of One and Three: Open Reduction and Modified Salter Innominate Osteotomy Combined with Fibular Allograft". *Open Journal of Orthopedics* 3 (2013): 137-152.
11. Gage JR and Winter RB. "Avascular necrosis of the capital femoral epiphysis as a complication of closed reduction of congenital dislocation of the hip". *Journal of Bone and Joint Surgery. American Volume* 54.2 (1972): 373-388.
12. Morcuenede JA, et al. "Long-term outcome after open reduction through an anteromedial approach for congenital dislocation of the hip". *Journal of Bone and Joint Surgery. American Volume* 79.6 (1997): 810-817.
13. Hsieh SM and Huang SC. "Treatment of Developmental Dysplasia of the Hip after Failed Open Reduction". *Journal of the Formosan Medical Association* 97.11 (1998): 763-769.
14. McCluskey WP, et al. "Treatment of Failed Open Reduction for Congenital Dislocation of the Hip". *Journal of Pediatric Orthopaedics* 9.6 (1989): 633-639.
15. Kalamchi A and MacEwen GD. "Avascular Necrosis Following Treatment of the Hip". *The Journal of Bone and Joint Surgery* 62.6 (1980): 876-888.
16. Tonnis D. "Review of the Literature on Open Reduction of the Hip in Congenital Dysplasia and Dislocation of the Hip in Children and Adults". Springer, Heidelberg (1987): 332.
17. Wiberg G. "Studies on dysplastic acetabula and congenital subluxation of the hip joint: with special reference to the complication of osteoarthritis". *Acta Chirurgica Scandinavica* 83 (1939): 58-135.

18. Zadeh HG., *et al.* "Test of stability as an aid to decide the need for osteotomy in association with open reduction in developmental dysplasia of the hip A Long - Term Review". *Journal of Bone and Joint Surgery. British Volume* 82-B.1 (2000): 17-27.
19. Salter RB and Dubos JP. "The first fifteen years' personal experience with innominate osteotomy in the treatment of congenital dislocation and subluxation of the hip". *Clinical Orthopaedics and Related Research* 98 (1974): 72-103.
20. Severin E. "Contribution to knowledge of congenital dislocation of hip joint: late results of closed reduction and arthrographic studies of recent cases". *Acta Chirurgica Scandinavica* 84 (1941): 1-142.
21. Barrett WP, *et al.* "The Effectiveness of the Salter Innominate Osteotomy in the Treatment of Congenital Dislocation of the Hip". *The Journal of Bone and Joint Surgery* 68.1 (1986): 79-87.
22. Pemberton PA. "Pericapsular osteotomy of the ilium for treatment of congenital subluxation and dislocation of the hip". *Journal of Bone and Joint Surgery. American Volume* 47 (1965): 65-86.
23. Tavares JO. "Modified Pemberton Acetabuloplasty for the Treatment of Congenital Hip Dysplasia". *Journal of Pediatric Orthopaedics* 24.5 (2004): 501-507.
24. Perlik PC., *et al.* "A combination pelvic osteotomy for acetabular dysplasia in children". *Journal of Bone and Joint Surgery. American Volume* 67.6 (1985): 842-850.
25. Lin CJ., *et al.* "Intraoperative Instability for Developmental Dysplasia of the Hip in Children 12 to 18 Months of Age as a Guide to Salter Osteotomy". *Journal of Pediatric Orthopaedics* 20.5 (2000): 575-578.
26. Bohm P and Brzuske A. "Salter Innominate Osteotomy for the Treatment of Developmental Dysplasia of the Hip in Children: Results of Seventy-Three Consecutive Osteotomies after Twenty-Six to Thirty-Five Years of Follow-Up". *The Journal of Bone and Joint Surgery. American Volume* 84.2 (2002): 178-186.
27. Ito H., *et al.* "Middle-Term Results of Salter Innominate Osteotomy". *Clinical Orthopaedics and Related Research* 387 (2001): 156-164.
28. Abdullah., *et al.* "Evaluation of the results of operative treatment of hip dysplasia in children after the walking age". *Alexandria Journal of Medicine* 48.2 (2012): 115-122.
29. Witzleb WC., *et al.* "Short-term outcome after posterior versus lateral surgical approach for total hip arthroplasty - a randomized clinical trial". *European Journal of Medical Research* 14.6 (2009): 256-263.
30. Karakas ES., *et al.* "One-stage treatment of congenital dislocation of the hip in older children". *Journal of Pediatric Orthopaedics* 15.3 (1995): 330-336.
31. Forlin E., *et al.* "Treatment of developmental dysplasia of the hip after walking age with open reduction, femoral shortening, and acetabular osteotomy". *Orthopedic Clinics of North America* 37.2 (2006): 149-160.
32. Umer M and Nawaz H. "Developmental Dysplasia of Hip - Where do we stand". *Journal of the Pakistan Medical Association* 58 (2008): 2-4.
33. Ganger Rudolf., *et al.* "Treatment options for developmental dislocation of the hip after walking age". *Journal of Pediatric Orthopaedics* 14.3 (2005): 139-150.
34. Galpin RD., *et al.* "One-stage treatment of congenital dislocation of the hip in older children, including femoral shortening". *The Journal of Bone and Joint Surgery. American Volume* 71.5 (1989): 734-741.

35. Vedantam R., *et al.* "Pemberton osteotomy for the treatment of developmental dysplasia of the hip in older children". *Journal of Pediatric Orthopaedics* 18.2 (1998): 254-258.
36. Wada A., *et al.* "Pemberton osteotomy for developmental dysplasia of the hip in older children". *Journal of Pediatric Orthopaedics* 23.4 (2003): 508-513.
37. Szepesi K., *et al.* "Pemberton's pericapsular osteotomy for the treatment of acetabular dysplasia". *Journal of Pediatric Orthopaedics* 5.4 (1996): 252-258.
38. Brückl R., *et al.* "Eine Abgrenzung normaler und dysplastischer jugendlicher Hüftgelenke durch den Hüftwert". *Archiv Fur Orthopädische Und Unfall-Chirurgie* 74 (1972): 13-32.
39. Catterall RCF. "Ex umbris eruditio. Editorials and Annotations". *The Journal of Bone and Joint Surgery* 60-B (1968): 455.
40. Mandal S and Bhan S. "The center-edge angle of Wiberg in the adult Indian population". *Journal of Bone and Joint Surgery. British Volume* 78-B.2 (1996): 320-321.
41. Al-Ghamdi A., *et al.* "Dega osteotomy for the correction of acetabular dysplasia of the Hip: a radiographic review of 21 cases". *Journal of Pediatric Orthopaedics* 32.2 (2012): 113-120.
42. El-Sayed M., *et al.* "The effect of Dega acetabuloplasty and salter innominate osteotomy on acetabular remodeling monitored by the acetabular index in walking DDH patients between 2 and 6 years of age: short- to middle-term follow-up". *Journal of Children's Orthopaedics* 6.6 (2012): 471-477.
43. Putti V. "Early Treatment of Congenital Dislocation of the Hip". *Journal of Bone and Joint Surgery* 47 (1965): 602-606
44. Grill F. "Treatment of Hip Dislocation after Walking Age". *Archives of Orthopaedic and Trauma Surgery* 102.3 (1984): 148-153.
45. Ruszkowski K and Pucher A. "Simultaneous Open Reduction and Degatransiliac Osteotomy for Developmental Dislocation of the Hip in Children under 24 Months of Age". *Journal of Pediatric Orthopaedics* 25.5 (2005): 695-701.
46. Tachdjian MO. "Congenital Dislocation of the Hip". Churchill Livingstone, New York (1982).
47. Fixsen JA. "Anterior and Posterior Subluxation of the Hip Following Innominate Osteotomy". *Journal of Bone and Joint Surgery* 69.3 (1987): 361-364.
48. El-Sayed MMH. "Single-stage open reduction, Salter innominate osteotomy, and proximal femoral osteotomy for the management of developmental dysplasia of the hip in children between the ages of 2 and 4 years". *Journal of Pediatric Orthopaedics* 18.4 (2009): 188-196.
49. Tönnis D and Heinecke A. "Acetabular and Femoral Anteversion: Relationship with Osteoarthritis of the Hip". *Journal of Bone and Joint Surgery* 81.12 (1999): 1747-1770.
50. Haidar RK., *et al.* "Simultaneous Open Reduction and Salter Innominate Osteotomy for Developmental Dysplasia of the Hip". *Journal of Bone and Joint Surgery* 78 (1996): 471-476.

Volume 9 Issue 4 April 2018

©All rights reserved by Nguyen Ngoc Hung and Hoang Hai Duc.