

## Concomitant Fractures of the Acromion, Coracoid, and Anterior Glenoid in Association with Dislocation of the Glenohumeral Joint: A Case Series

José Arturo Pacheco-Núñez<sup>1</sup>, Bobby Dezfuli<sup>2\*</sup>, Rafael R Bernal<sup>3</sup> and Joseph E Sheppard<sup>2</sup>

<sup>1</sup>National Autonomous University of Honduras, School of Medicine, Tegucigalpa, Honduras

<sup>2</sup>Department of Orthopaedic Surgery, Banner-University Medical Center, Tucson, Arizona, USA

<sup>3</sup>Department of Mechanical Engineering, University of Arizona, Tucson, Arizona, USA

\*Corresponding Author: Bobby Dezfuli, Department of Orthopaedic Surgery, Banner-University Medical Center, Tucson, Arizona, USA.

Received: February 05, 2018; Published: March 07, 2018

### Abstract

Concomitant fractures of the acromion and coracoid process are infrequent scapular injuries, accounting for 0.1% of fractures overall, and are even more uncommon when they happened in conjunction with a shoulder dislocation. There is no reported case of this triple injury in particular. This type of injury may be missed on the standard radiographic series. The use of 3D CT scan reconstruction is useful for fracture assessment. We report two rare cases of a fracture of the coracoid process, acromion process, a bony Bankart lesion, and glenohumeral dislocation. The common denominators in each case are the high-energy transfer to the trunk, glenoid fracture concordant with the direction of force application, and concomitant process fractures, indicative of the violence of the energy transfer.

**Keywords:** Coracoid Fracture; Acromion Fracture; Glenohumeral Dislocation

### Introduction

Scapular fractures are an uncommon injury, it accounts for no more than 5% of total shoulder fractures and only 1% of overall fractures. They are usually caused by high-energy vehicular trauma. Glenoid fractures in association with superior shoulder suspensory complex injuries are even more uncommon. Accordingly, there are often associated injuries of the ipsilateral extremity, shoulder girdle, and thorax. Scapular fractures are frequently neglected in patients with multiple fractures, because focus to other life-threatening problems is given [1-14].

The scapula is engulfed by a large muscle mass, so that when fractures do occur displacement of the fragments is usually minimal and complete healing is the rule [4,5,8]. Scapular fracture rarely do require open reduction, and operative treatment is indicated when they are displaced glenoid intra-articular and juxtaarticular fractures co-existing with soft-tissue damage in which conservative measures alone, function will not be restored and post-traumatic osteoarthritis will develop [10,13] as in one of the cases further discussed.

We present the pathoanatomic features of two patients with fractures of the acromion process, coracoid, and glenohumeral dislocation in combination with the pitfalls and principles of successful operative management.

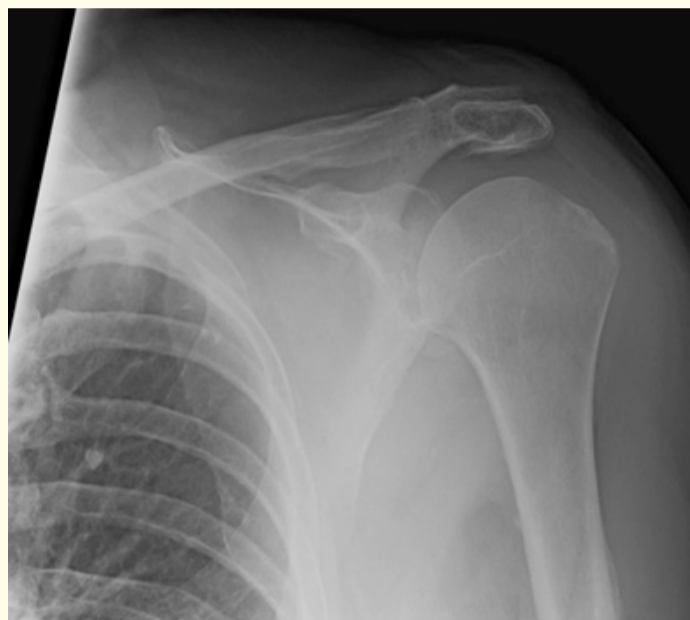### Clinical Cases

#### Case #1

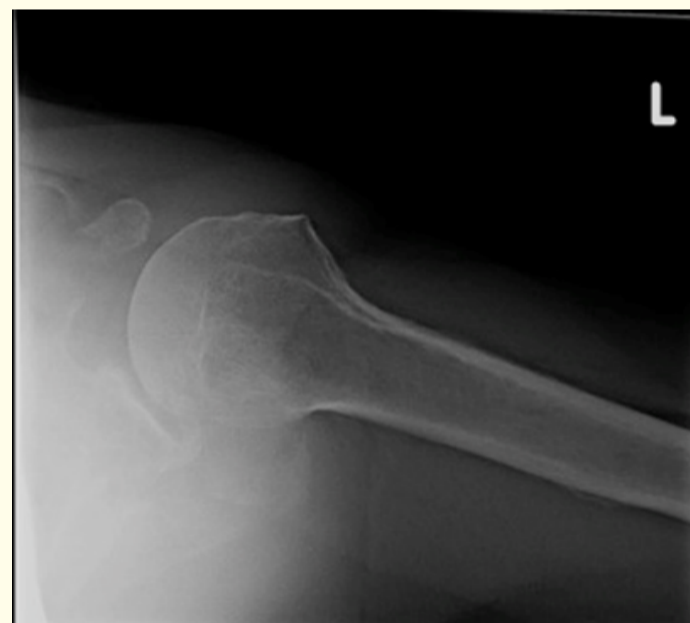A 68-year-old male was seen at the orthopaedic outpatient clinic with pain in his left shoulder, one month after being involved in a motorcycle accident. Since the time of his injury he noted pain and difficulty in moving his shoulder. Physical examination revealed a

palpable bony prominence at the lateral aspect of his scapular spine that was tender to palpation over his acromion, active and passive abduction of 30° and 90° respectively, and mild atrophy of the supra-and-infraspinatus muscles. The X-rays of the left shoulder showed definitive fracture except for slight anterior glenohumeral subluxation (Figure 1). Magnetic resonance imaging revealed fractures of the acromion and scapular spine, a Hill-Sachs lesion, fractures extending into the neck region, a large osseous Bankart lesion, and tendinosis of the subscapular and supraspinatus. Preoperative CT scan with 3D reconstruction (Figure 2a - d and Figure 5) demonstrated a fracture of the base of the acromion in conjunction with an anterior bony Bankart lesion involving the glenoid and a coracoid fracture.

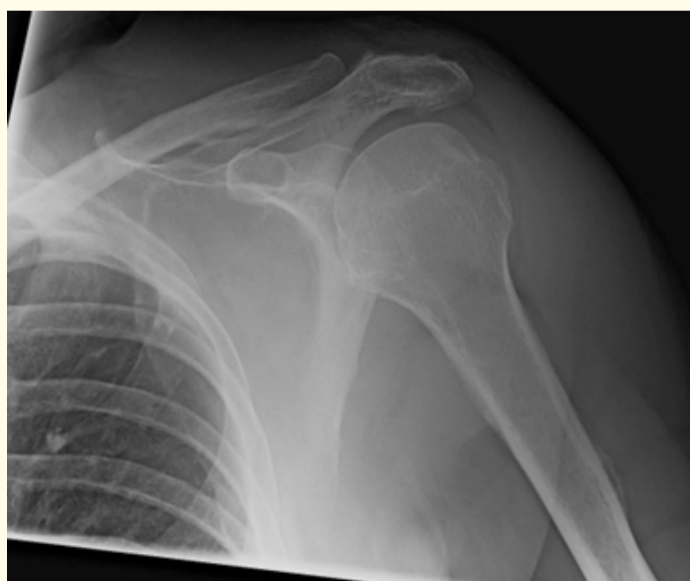A transacromio-clavicular fixation was performed using a 3.5-mm pelvic recon plate, lag screw fixation using standard AO technique, and additional 3.5 fully threaded cancellous screws. The bony Bankart lesion, which was too large for arthroscopic management was repaired in conjunction with the capsule, subscapularis, and supraspinatus with #2 FiberWire figure-of-eight interrupted sutures and the coracoid fracture with a 3.5 mm partially threaded cannulated screw. Two weeks postop X-rays (Figure 3) showed complete loss of fixation and recurrent subluxation of his humeral head anteriorly, after patient felled while repairing his garage. There was a tear in the superior capsule and subscapularis, which were then repaired with #2 FiberWire figure-of-eight interrupted sutures gaining satisfactory restoration of anterior stability. At one week follow up from his revision surgery, radiographic assessment (Figure 4) revealed no evidence of hardware failure, and at six weeks follow up from his revision surgery, there was no pain, however, there was substantial stiffness and evidence of posttraumatic osteoarthritis of the glenohumeral joint.



a

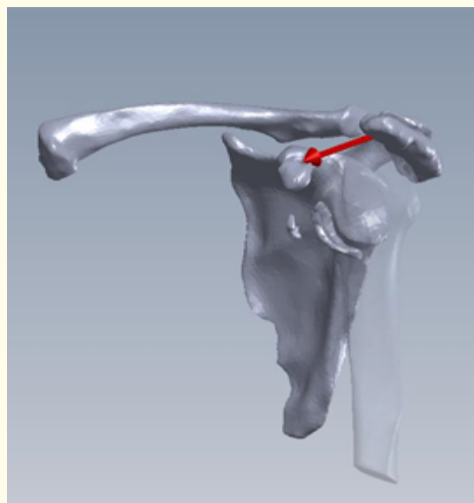


b

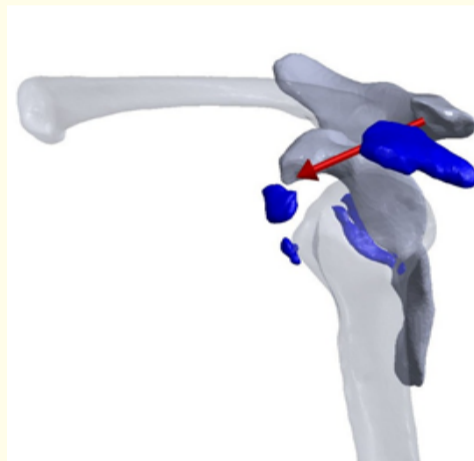

c

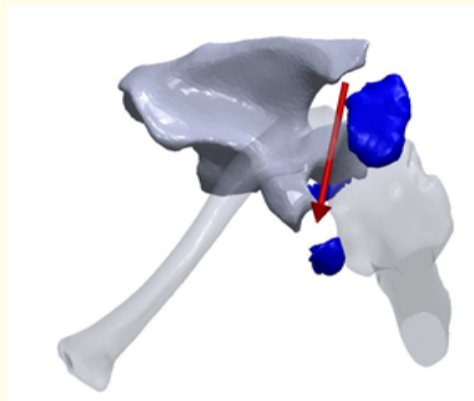
**Figure 1:** Outpatient clinic shoulder radiographs showing no definitive fracture. Slight glenohumeral subluxation.



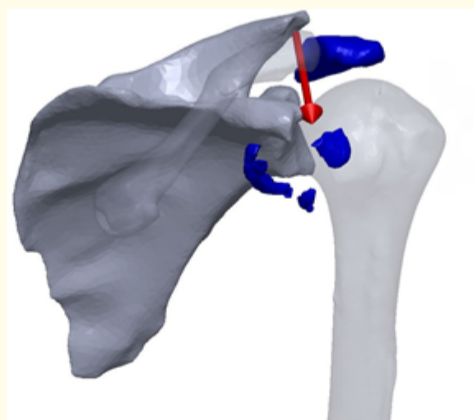
a



b

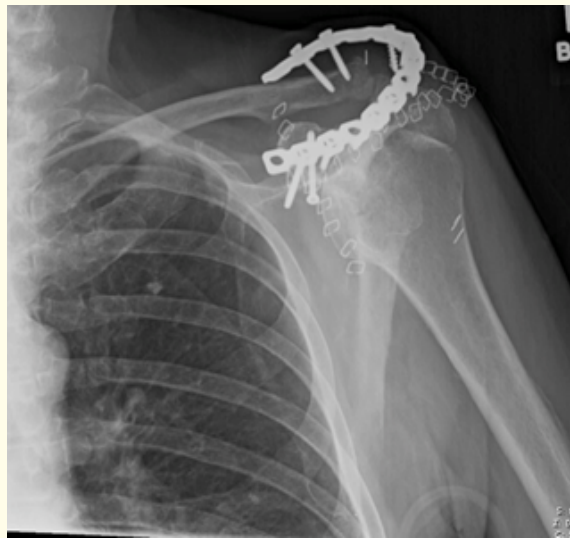

c

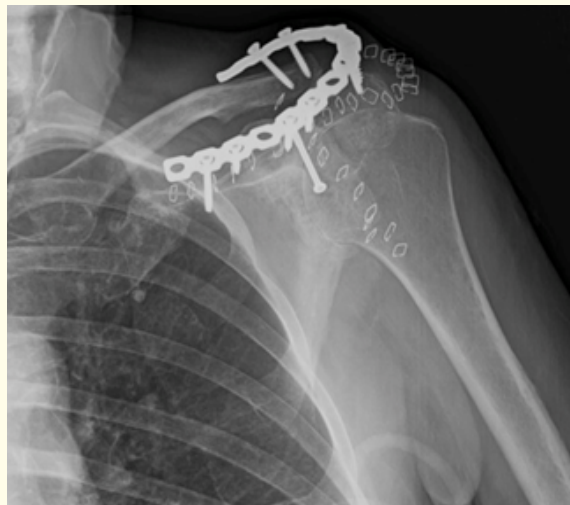

d

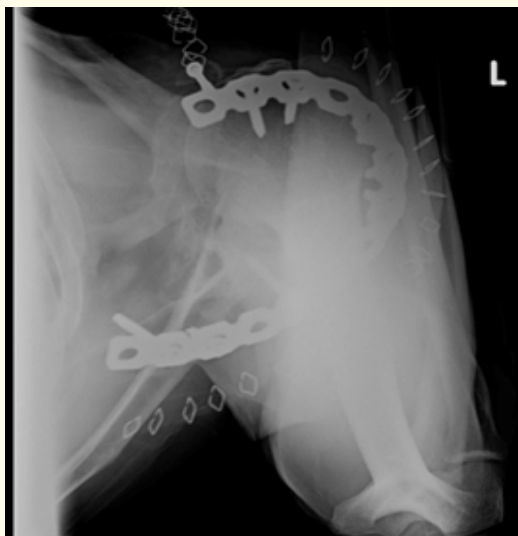**Figure 2A-D:** 3D CT scan Reconstruction. Blue fragments show fractures of the coracoid, acromial, and anterior glenoid, as well as the Bankart lesion.



a

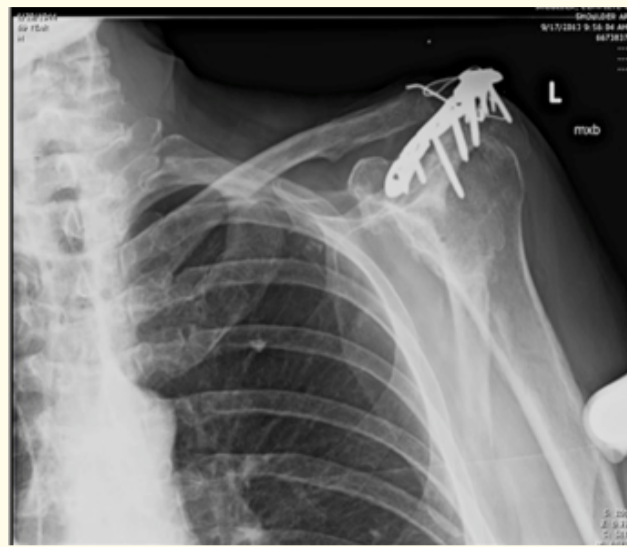

b

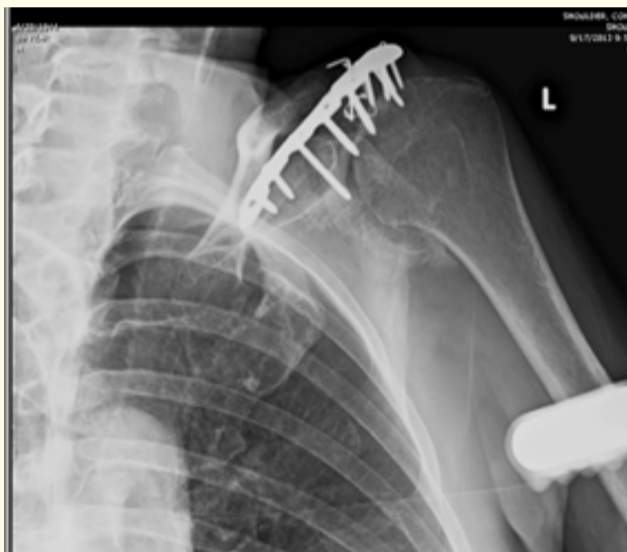

c

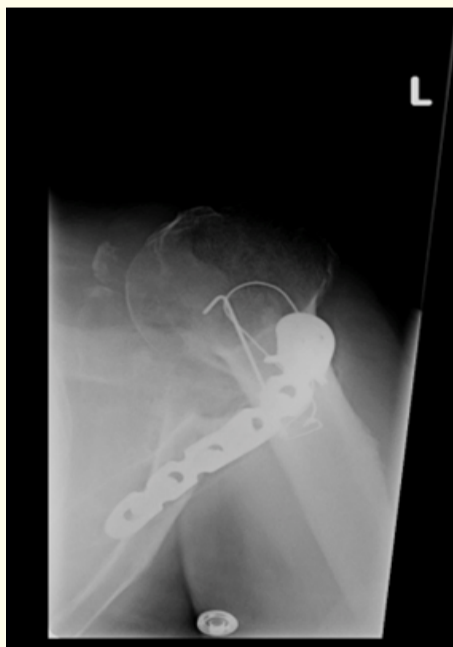**Figure 3A-C:** CT reconstruction of pre-operative shoulder injury pattern of patient #1. Transversely oriented fracture through the proximal left acromion with mild anterior displacement of the distal-most fracture fragment, displaced fracture through the base of the coracoid, displaced fracture through the left scapular body and spine; intra-articular extension and complex involvement at the glenoid and incongruity of its glenoid articular surface.



a

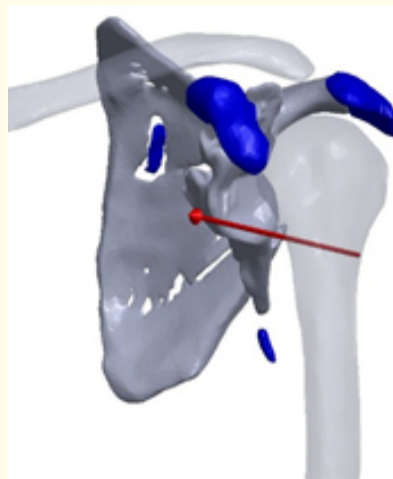


b

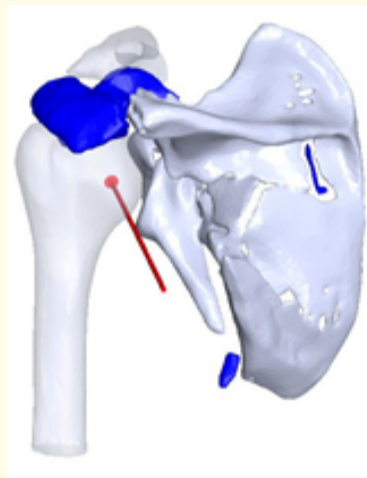


c

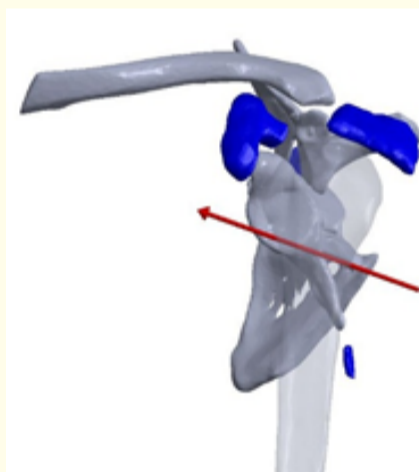
**Figure 4:** Outpatient clinic shoulder radiographs after index procedure. Complete loss of fixation and recurrent subluxation of his humeral head anteriorly.



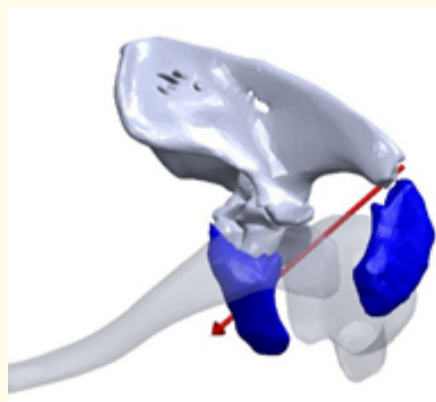
a



b



c



d

**Figure 5:** Outpatient clinic shoulder radiographs after second procedure. No evidence of hardware failure lucency.



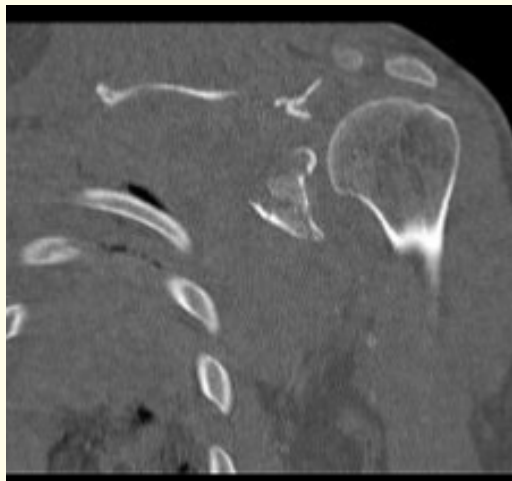
Case #2

A 34-year-old male, sustained a high-energy injury, from a motorcycle crash, to his left forequarter at that time. Two days after, he was able to provide an examination, which was remarkable for an axillary nerve palsy. Pre-operative radiographs (Figure 6) and a CT scan with 3D reconstruction (Figure 7 and Figure 9) was obtained and revealed a transversely oriented fracture through the proximal left acromion with mild anterior displacement of the distal-most fracture fragment, with a displaced fracture through the base of the coracoid, displaced fracture through the left scapular body and spine; which demonstrated intra-articular extension and complex involvement at the glenoid and incongruity of its glenoid articular surface, with mild posterior and proximal subluxation of the left humeral head relative to the glenoid. He underwent surgery under general anesthesia. After exposing the highly comminuted area of the lateral scapular border, anatomic reduction was achieved and a reconstruction plate was contoured and affixed to the retroglenoid articular surface, extending down the lateral scapular border. The acromion fracture was reduced and transfixed with 1.6 mm K-wires. A lateral left-sided distal clavicle plate was contoured to the acromial spine and affixed using standard 3.5 mm cortical and locking 2.4 mm distal screws.

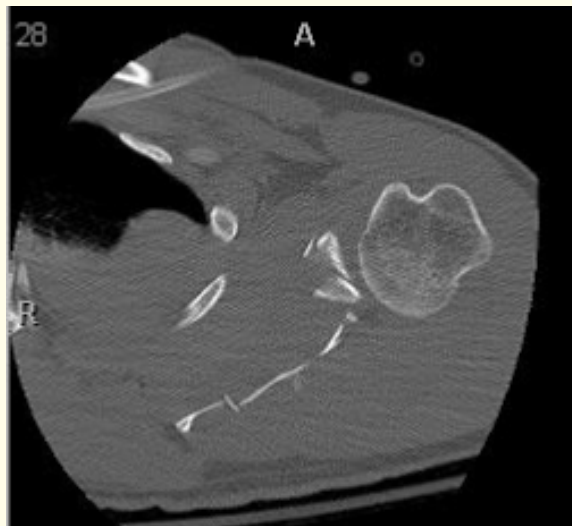
At two months followup, radiographs were obtained (Figure 8), showing well-placed surgical hardware without evidence of complication and/or failure. Focused musculoskeletal exam showed 50 degrees with forward flexion and abduction; -10 degrees of external rotation with weakness in external rotation and internal rotation to buttocks; atrophy of the infraspinatus; axillary sensation and motor function preserved. Distally EPL, FPL, and interosseous function were intact as well as sensation to light touch in radial, median, and ulnar autogenous zones.

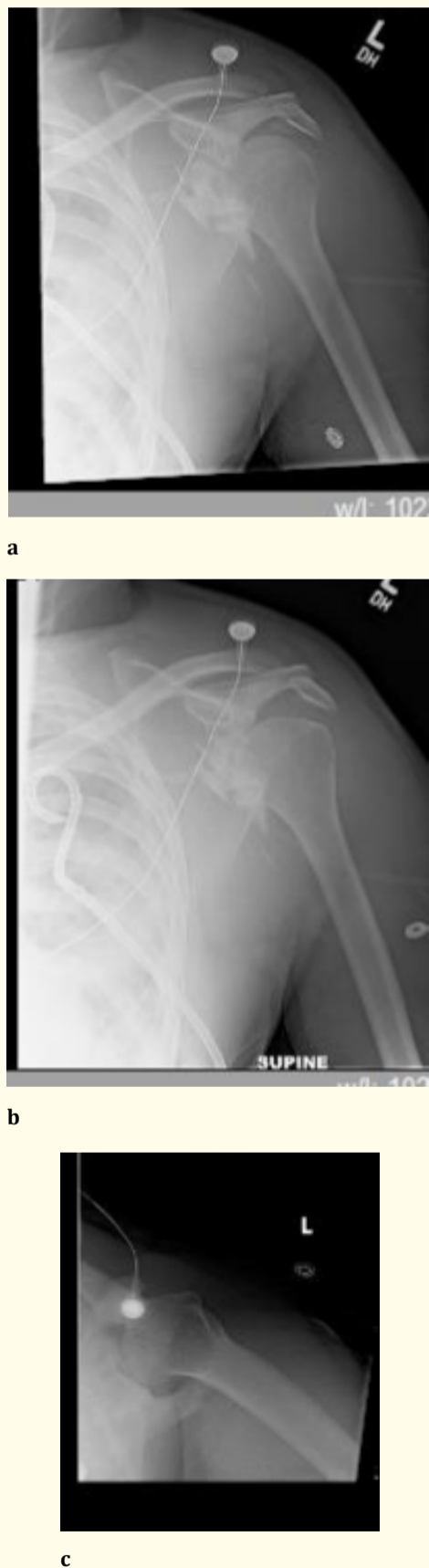

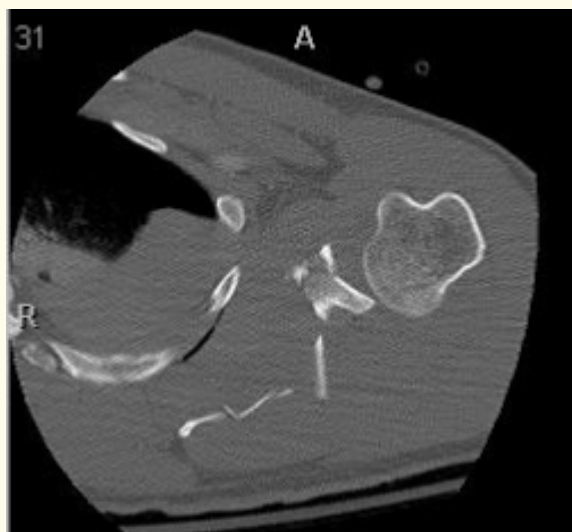Figure 6: Pre-operative radiographs of patient #2 with complex scapular fracture and posterior glenohumeral subluxation.



a



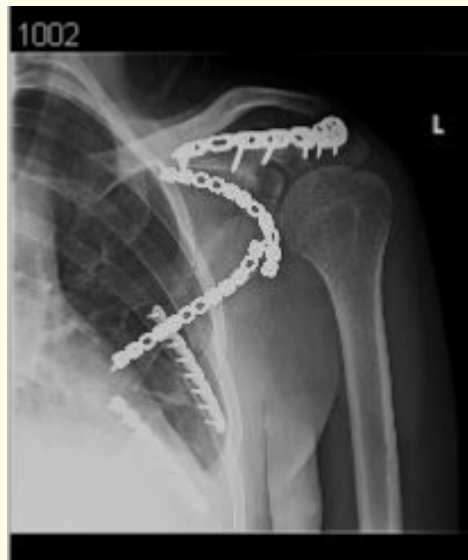b



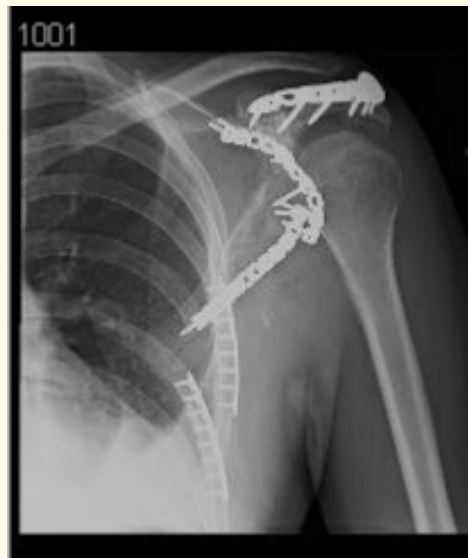c

**Figure 7:** CT reconstruction of shoulder injury pattern in patient #2.

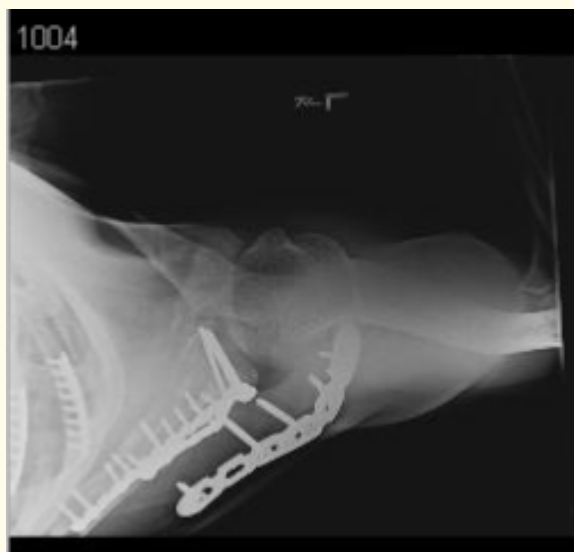



a

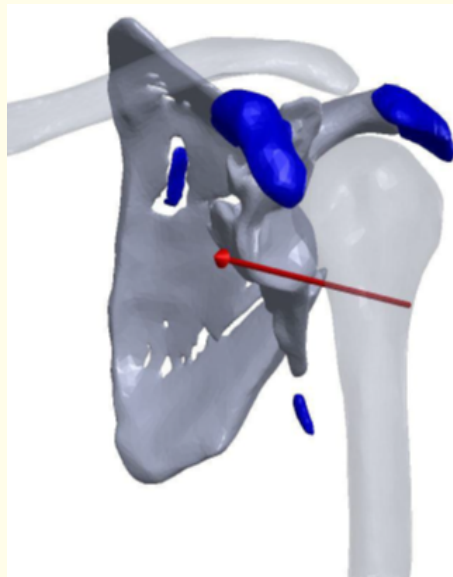


b

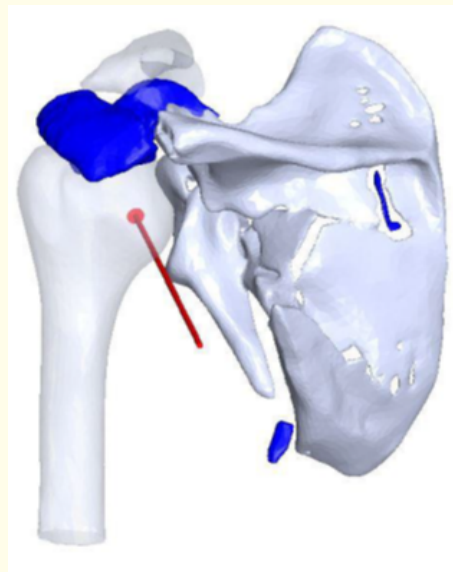


c

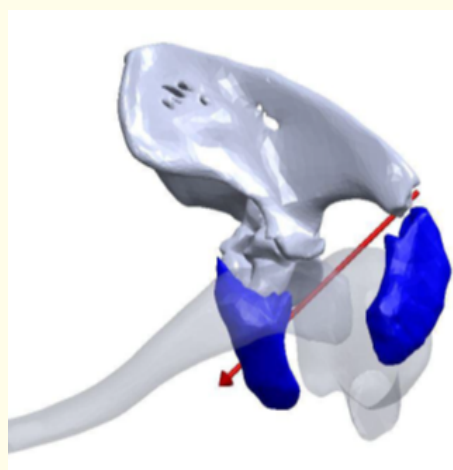
Figure 8A-C: CT reconstruction of pre-operative shoulder injury pattern of patient #2.



a



b



c

**Figure 9:** Post-operative radiographs of patient #2. Reduced scapular fractures in acceptable alignment and reduced glenohumeral joint.

## Discussion

Concomitant fractures of scapular processes in conjunction with glenoid cavity components are very uncommon [10,11,13]. The first to describe a concomitant fracture of the coracoid and acromion with glenohumeral subluxation was John South in 1839 [34]. Zhi-Quan reported in a study of 10 patients between 2007 - 2012, one patient with a concomitant acromion, glenoid Ideberg type III (transverse, superior glenoid), and a lesser tuberosity fracture; another patient presented with an acromion, distal clavicle and glenoid Ideberg type III fractures; and two patients presented with fractures of the acromion and glenoid Ideberg type III [14].

In a bony Bankart glenoid lesion, the larger the bone defect, the more significant the joint instability and the greater the likelihood of recurrent anterior shoulder dislocation. Bankart fractures often occur in conjunction with Hill-Sachs lesions. If one is identified, the other is 2.67 times more likely to be present [21]. These concomitant injuries are the result of high-energy trauma. They are associated with other life-threatening conditions such as injury to the chest, cranium, cervical spine, and aorta [2,3,8,22,23]. The most common causes of injury are motorcycle accidents (60%) [2,6,9,24], followed by motor vehicle crashes (16.7%), and falls (8%) [2,4,7,22,25]. The rarity of the injury is likely because of the thick soft tissue envelope that surrounds the scapula [1,3]. Some protection is conferred by the mobility of the glenohumeral articulation and other joints that make up the shoulder complex. These include the acromioclavicular joint, sternoclavicular joint, and scapulothoracic articulation [3]. Physical examination may reveal swelling, ecchymosis, crepitus and local tenderness [1,22]. With respect to scapula fracture location, scapula body and spine are the most common (approximately 30%), followed by isolated fractures of the scapular neck (25%), glenoid cavity (10%), acromion (8%) [4,22,26-28], and coracoid process (2 - 13%) [11,12,19,29,30]. Combination fractures are rare. Coracoid and scapular body fracture account for 7% of fractures [22,31-33], acromion and scapular body fractures for 2% [24], acromion and coracoid fractures for 19% [11], and glenoid cavity and scapular neck fractures for 27 - 44% [4]. Most acromion fractures are associated with other periarticular injuries, such as coracoid process fracture, clavicle fracture, scapular neck or body fracture, acromioclavicular dislocation or glenohumeral dislocation [26]. The presence of an acromial fracture should always alert the physician for associated pathology [26,28].

Bauer reported one patient in a study of 25 subjects between 1981-1991 [6] with a concomitant fracture of the acromion and coracoid process with acromioclavicular dislocation in a 48-year-old male. Ogawa, *et al.* reported in a series of 67 patients between 1974 -1994 thirteen patients (19%) presented with concomitant coracoid and acromion fractures [11]. Anavian, *et al.* reported a study of 27 scapular fractures from 1998 - 2007, with one patient (3%) who presented with a fracture of the coracoid and acromion [35]. Individual case reports of concomitant fractures of the coracoid and acromion caused by motor vehicle and motorcycle accidents have been reported [31,36,37].

To our knowledge, the association of a coracoid process, bony Bankart lesion, and acromion fracture with anterior shoulder dislocation is undescribed. Cottias reported a greater tuberosity fracture, coracoid fracture, and anterior glenoid fracture in a 33-year-old patient [38] and Hitesh reported a 48-year-old patient with an anterior shoulder dislocation, Bankart lesion, Hill-Sachs lesion and coracoid process fracture [39]. Goss reported a double disruption of the superior shoulder complex consisting of fractures of the acromion process, coracoid process, and superior angle of the scapular body [3]. Oh, *et al.* noted that of the 13 patients in their series, one had an acromion and intraarticular glenoid fracture while another had an acromion and scapular neck fracture [40].

A standard radiographic series for evaluation of scapular fractures should include a true anteroposterior view of the glenohumeral joint, axillary view, and a scapular Y view [1,22,39,41-43]. CT scans with three - dimensional reconstruction is likely the most useful imaging method for surgical planning [3,22]. A double contrast CT arthrography has been used to show a Bankart lesion [18].

Operative indications for scapular fractures, included either a painful nonunion, concomitant operative scapular fractures, greater than 1cm displacement on X-ray, or multiple disruptions of the superior shoulder suspensory complex. Various studies emphasized the therapeutic and prognostic difference of two groups of scapular fractures. The first group consisted on non- or minimally displaced fractures of the body, neck, and apophyses. These consist of more than 90% of the scapular fractures. Conservative management usually

brings about good results. The second group included displaced fractures of the glenoid, unstable fractures of the neck, and major dislocations in apophyseal fractures. Patient outcome with open reduction and internal fixation is better than with conservative treatment [1,6,7,11,19,12,33,35].

The literature indicates that surgeons have taken multiple approaches in the surgical treatment of coracoid fractures. Ogawa, et al. [11] favored a single malleolar screw with concurrent wiring, Duan, et al. recommended a hook plate [13] when associated with acromioclavicular dislocation, Wang, et al. [19] treated one patient with Kirschner wires, Lim addressed the fractures by open reduction and internal fixation (ORIF) of the acromion using a tension band wire and ORIF of the coracoid with a lag screw [36], Lin performed an ORIF of the acromion and coracoid with a malleolar screw and washer [31]; and Choi performed an ORIF of the acromion using a plate and screw fixation of the coracoid treatment. Goss performed an ORIF of the acromion with a dorsal tension band technique without addressing the coracoid fracture [3].

Traumatic anterior shoulder instability is a common problem with an accepted treatment algorithm of initial nonsurgical treatment, with surgical stabilization indicated after recurrent instability [16,17,20,44]. Surgical treatment consists of open repair as described by Matsen [44] and Henry [20] or arthroscopic repair with suture anchors as described by Snyder [44].

## **Conclusion**

The lack of evidenced-base treatment for concomitant fractures of scapular processes makes its management a more challenging one. With increasing rates of multi-trauma patients, a careful physical examination and a high level of suspicion must be maintained in order to decrease misdiagnosis. Radiographic evaluation alone may not sensitive for identification these fractures. The role of three-dimensional CT scan reconstruction is a useful tool for diagnosis. A combination of compression and tension based fixation should be employed to adequately address the forces in this fracture array.

## **Acknowledgements**

No financial support was received for this study.

## **IRB**

All human studies have been approved by the appropriate ethical committee when indicated. Patients' informed consents were obtained prior to study.

## **Conflict of Interest**

The authors declare no conflicts.

## **Bibliography**

1. Voleti PB, et al. "Fractures of the scapula". *Advanced Orthopaedic* (2012): 903850.
2. Akaraborworn O, et al. "Scapular fractures and concomitant injuries". *Chinese Journal of Traumatology* 15.5 (2012): 297-299.
3. Goss TP. "Double disruptions of the superior shoulder suspensory complex". *Journal of Orthopaedic Trauma* 7.2 (1993): 99-106.
4. Scavenius M and Sloth C. "Fractures of the scapula". *Acta Orthopædica Belgica* 62.3 (1996): 129-132.
5. Ideberg R, et al. "Epidemiology of scapular fractures. Incidence and classification of 338 fractures". *Acta Orthopaedica Scandinavica* 66.5 (1995): 395-397.
6. Bauer G, et al. "Displaced scapular fractures: indication and long-term results of open reduction and internal fixation". *Archives of Orthopaedic and Trauma Surgery* 114.4 (1995): 215-219.

7. Scarano JL, et al. "Comminuted scapular body fractures: A report of three cases managed conservatively in chiropractic settings". *Journal of the Canadian Chiropractic Association* 57.2 (2012): 176-184.
8. Pathania VP, et al. "Unusual presentation of fracture scapula". *Medical Journal Armed Forces India* 58.3 (2002): 257-258.
9. Gosens T, et al. "Fracture of the scapular body: functional outcome after conservative treatment". *Journal of Shoulder and Elbow Surgery* 18.3 (2009): 443-448.
10. Wu F, et al. "An unrecognized case of a scapula fracture sustained through an unusual indirect mechanism". *Case Reports in Orthopedics* (2013): 8489953.
11. Ogawa K, et al. "Fractures of the coracoid process". *The Journal of Bone and Joint Surgery. British Volume* 79.1 (1997): 17-19.
12. Eyres KS, et al. "Fractures of the coracoid process". *The Journal of Bone and Joint Surgery. British Volume* 77.3 (1995): 425-428.
13. McArthur N and Singh B. "Good clinical outcome following non-operative treatment of concomitant fractures of coracoids process and distal end of clavicle: A case report". *Journal of Orthopaedic Case Reports* 2.2 (2012): 14-16.
14. Qin H, et al. "Surgical treatment of Ideberg type III glenoid fractures with associated shoulder suspensory complex injury". *Orthopedics* 36.10 (2013): e1244-e1250.
15. Slabaugh MA, et al. "Restoring the labral height for treatment of Bankart lesions: a comparison of suture anchor constructs". *Arthroscopy* 26.5 (2010): 587-591.
16. Novotny JE, et al. "Kinematics of the glenohumeral joint with Bankart lesion and repair". *Journal of Orthopaedic Research* 16.1 (1998): 116-121.
17. Blasier RB, et al. "The Bankart repair illustrated in cross-section. Some anatomical considerations". *American Journal of Sports Medicine* 17.5 (1989): 630-637.
18. Cetik O, et al. "Open repair of Bankart lesions using suture anchors in hard workers". *Acta Orthopaedica Belgica* 72.6 (2006): 664-670.
19. Yu KS, et al. "Coracoid process fracture combined with acromioclavicular joint dislocation and coracoclavicular ligament disruption". *Sicot Case-Reports* (2002): 1-11.
20. Brophy RH and Marx RG. "The treatment of traumatic anterior instability of the shoulder: non-operative and surgical treatment". *Arthroscopy* 25.3 (2009): 298-304.
21. Wong JCT, et al. "Fractures complicating anterior shoulder dislocation in adults". *Israeli Journal of Emergency Medicine* 7.3 (2007): 27-33.
22. Vam Noort A. "Scapular fractures". In: Buchholz RW, Heckman JD, Court-Brown CM, Tornetta P III. Eds. *Rockwood & Green's Fractures in Adults*. Philadelphia: Lippincott Williams & Wilkins (2010): 1144-1164.
23. Tucek M, et al. "Bilateral scapular fractures in adults". *International Orthopaedics* 37.4 (2013): 659-665.
24. Cole PA, et al. "Radiographic follow-up of 84 operatively treated scapula neck and body fractures". *Injury* 43.3 (2012): 327-333.
25. Groot D, et al. "Spontaneous scapular spine fracture related to rotator cuff pathology: a report of two cases". *Strategies in Trauma and Limb Reconstruction* 7.2 (2012): 105-107.
26. Fernandes MR and Fernandes RJ. "Fracture of the acromion associated with arterial lesion case report". *Journal of Vascular Surgery* 9.2 (2010): 95-99.

27. Mehdi Nasab SA. "Isolated displaced fractures of the acromion: a rare case report and the consequence of treatment by open reduction and pin fixation". *Archives of Trauma Research* 1.4 (2013): 184-186.
28. Nissen CW. "The acromion: fractures an os acromiale". *Operative Techniques in Sports Medicine* 12.1 (2004): 32-34.
29. Gogoi P, et al. "Coracoid process fracture: a report of two cases and brief review of literature". *Open Journal of Orthopedics* 3.2 (2013): 153-156.
30. Di Paola M and Marchetto P. "Coracoid process fracture with acromioclavicular joint separation in an American football player: a case report and literature review". *American Journal of Orthopedics* 38.1 (2009): 37-40.
31. Lin MS., et al. "Concomitant fracture of the coracoid process and the acromion: report of a case". *Journal of Emergency and Critical Care Medicine* 19.1 (2008): 8-11.
32. Bahk MS., et al. "Acromioclavicular and sternoclavicular injuries and clavicular, glenoid and scapular fractures". *Journal of Bone and Joint Surgery. American Volume* 91.10 (2009): 2492-2510.
33. Schofer MD., et al. "Fractures of the scapula: long-term results after conservative treatment". *Archives of Orthopaedic and Trauma Surgery* 129.11 (2009): 1511-1519.
34. South JF. "Case of fracture of the coracoid process of the scapula, with partial dislocation of the humerus forwards and fracture of the acromion process of the clavicle". *Medico-Chirurgical Transactions* 22 (1839): 100-109.
35. Anavian J., et al. "Surgery for scapula process fractures: good outcomes in 26 patients". *Acta Orthopaedica* 80.3 (2009): 344-350.
36. Lim KE., et al. "Concomitant fracture of the coracoid and acromion after direct shoulder trauma". *Journal of Orthopaedic Trauma* 10.6 (1996): 437-439.
37. Choi JS., et al. "Concomitant fracture of the coracoid process and the acromion—a case report". *Journal of the Korean Orthopaedic Association* 44.2 (2009): 279-283.
38. Cottias P., et al. "Fractured coracoid with anterior shoulder dislocation and greater tuberosity fracture—report of a bilateral case". *Acta Orthopaedica Scandinavica* 71.1 (2000): 95-97.
39. Lal H., et al. "Recurrent shoulder dislocations secondary to coracoid process fracture: a case report". *Journal of Orthopaedic Surgery* 20.1 (2012): 121-125.
40. Oh W., et al. "The treatment of double disruption of the superior shoulder suspensory complex". *International Orthopaedics* 26.3 (2002): 145-149.
41. Bushnell BD., et al. "Bony instability of the shoulder". *Arthroscopy* 24.9 (2008): 1061-1073.
42. Vanden Berghe G., et al. "Glenohumeral joint instability: the orthopedic approach". *Seminars in Musculoskeletal Radiology* 9.1 (2005): 34-43.
43. Lapner PC., et al. "Scapula fractures". *Orthopedic Clinics of North America* 39.4 (2008): 459-474.
44. Archetti Netto N., et al. "Treatment of Bankart lesions in traumatic anterior instability of the shoulder: a randomized controlled trial comparing arthroscopy and open techniques". *Arthroscopy* 28.7 (2012): 900-908.

**Volume 9 Issue 4 April 2018**

**©All rights reserved by Bobby Dezfuli., et al.**