

Tarsal Sinus Syndrome by Osteoid Osteoma. Ct Guided Excision. Case Report and Literature Review

Pardo Coello M Mar* and **Franco Peris Ernesto**

Almansa General Hospital, Albacete, Spain

***Corresponding Author:** Pardo Coello M Mar, Almansa General Hospital, Albacete, Spain.

Received: September 17, 2017; **Published:** October 10, 2017

Abstract

Osteoid Osteoma is a benign osteoblastic lesion. It represents 15% of all benign bone tumors. 10% of osteomas appear in ankle and foot.

Case Report: We present the case of a 30y.o. patient, with ankle pain for months. No pathology was detected in Rx or MRI. The diagnosis was obtained by TAC.

Discussion: Clinical presentation is not common in all patients, moreover, imaging test do not always provide an accurate diagnosis. Sometimes MRI no difference between osteomas, osteoblastomas, chondroblastomas or osteomyelitis.

Conclusion: The percutaneous technique TAC-guided allows complete resection of the lesion. This procedure also allows a very-low bone resection and patient improvement weeks after surgery.

Keywords: *Osteoma; Ankle; CT-Guided; Treatment*

Introduction

Osteoid osteoma is a benign osteoblastic lesion, usually circumscribed and small in size, representing about 15% of all benign bone tumors. Of the total osteomas, around 10% appear in the ankle and foot region, mainly in spongy and subperiosteal bone.

The main clinical characteristic is nocturnal pain, with no traumatic antecedents, which usually improves with NSAIDs. However, this clinical presentation may vary, as it may be overlapping or confused with other pathologies, and thus difficult to diagnose.

In view of the case of a patient with this pathology, diagnosed and treated in our center by non-invasive surgery and tomography help; we have conducted a study, which aims to review osteoid osteomas published in the literature during the last years, which have been treated by percutaneous excision guided by CAT and without reaching large open surgeries or open surgeries.

Case Report

We present the case of a 30-year-old patient with left ankle pain of several months of evolution, with no prior traumatic history. Initially diagnosed as Tarsal Sinus Syndrome in the left ankle. In the absence of improvement with infiltration of corticoids, sessions of Rehabilitation and treatment with NSAIDs, it was decided to complete the study with imaging tests such as simple Rx, MRI or Electromyography.

In these tests there is no pathological finding that guides us about what the patient presents; since they are all within normalcy (Figure 1).

The diagnosis is finally obtained by thin-cutting CT, in which a lesion with radiolucency and sclerosis compatible with an osteoid osteoma in the left talus appears in the area near the left ankle (Figure 2).

In our case, CT-guided excision was chosen, being a great help and a labeling of the lesion prior to the patient's surgery was performed (Figure 3).

Citation: Pardo Coello M Mar and Franco Peris Ernesto. "Tarsal Sinus Syndrome by Osteoid Osteoma. Ct Guided Excision. Case Report and Literature Review". *EC Orthopaedics* 8.1 (2017): 26-29.

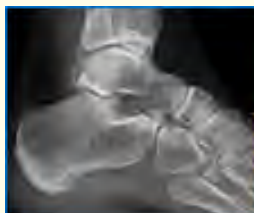

Figure 1

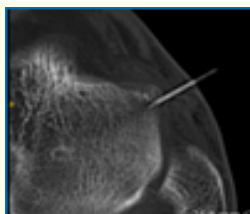


Figure 2

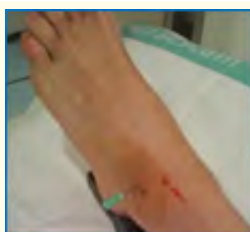

Figure 3

Thus, with the pre-labeling of the osteoma by CT, a complete and accurate excision of the osteoma was achieved, with a minimum approach and remission of the clinic within a few weeks of the intervention, as well as the patient's incorporation into his work and daily activities.

Likewise, this technique allowed the obtaining of sufficient surgical material to establish an adequate anatomopathological diagnosis, which confirmed the nature of the lesion (Figure 4).

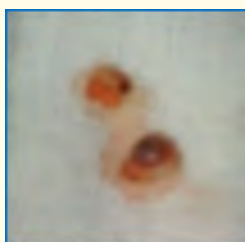

Figure 4

Discussion

The clinical presentation of this entity is very variable, since sometimes the symptoms are atypical and may be the same as, for example, those of a subtalar arthritis, osteochondritis, tarsal coalitions, osteochondromas. This can cause the diagnosis to be delayed, ranging from 6 months to more than one year after the start of the clinic.

Similarly, the diagnosis is difficult, and in the image tests such as MRI does not always distinguish between pathologies such as osteoblastomas, chondroblastomas, Brodie abscesses, osteomyelitis or osteoid osteomas; so a test that helps us in the diagnosis is the tomography.

The CT scan has not always been used for resection of this lesion percutaneously, since the most commonly used was the excision of the nidus by arthrotomy, however, it was not uncommon to find any other juxtaarticular lesion (Figure 5).

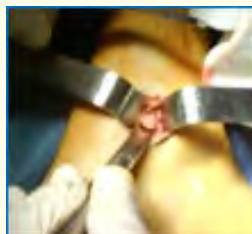

Figure 5

The first published cases of osteoid osteoma excision with CT appear around the beginning of the 1990s [1-3], resections of this lesion in astragalus. In the decade of the 2000 this technique is increased notably publishing series of more than 20 cases (Table 1).

Estudios Previos
I. Turan (1995) [2] 1 caso
L. Massari (1998) [3] 2º MTT
G. Scarfi (2005) [4] 2 casos
E. Boch (2005) [5] 9 casos-1
J.M. Sarabia (2009) [6] 21 casos-1

Table 1

Conclusions

Finally, and to conclude, we want to emphasize that we must think of this entity in patients with possible ankle pathologies of torpid evolution, without evident pathological image lesion and with clinical refractory to the treatment.

Bibliography

1. Mahmoud A. "Osteoid osteoma of the talus". *The Foot* 13.3 (2003): 166-168.
2. I Turan. "Osteoid osteoma of the talus-percutaneous radical excision TC-guided". *The Foot* 5.3 (1995): 149-151.
3. L Massari., *et al.* "Osteoid Osteoma at the base of the second metatarsal bone: case report". *Foot and Ankle Surgery* 4.2 (1998): 83-86G.
4. Scarfi C., *et al.* "Sinus tarsi syndrome caused by osteoid osteoma. A report of two cases". *Foot and Ankle Surgery* 12 (2006): 157-160.

5. E Bosch., *et al.* "Osteoma osteoide: Resección percutánea guiada por tomografía computada". *Revista Chilena de Radiología* 11.2 (2005): 45-50.
6. JM Sarabia Condes. "Treatment of osteoid osteoma by means CT-guided". *Revista Española de Cirugía Ortopédica y Traumatología* 54.1 (2010): 20-26.

Volume 8 Issue 1 October 2017

© All rights reserved by Pardo Coello M Mar and Franco Peris Ernesto.