

Injuries to the Lisfranc Joint and its Significance for the Patient

Ekkehard Pietsch*

Orthopaedic and General Surgeon, The-Expert-Witness.de, Hamburg, Germany

***Corresponding Author:** Ekkehard Pietsch, Orthopaedic and General Surgeon, The-Expert-Witness.de, Hamburg, Germany.

Received: March 15, 2017; **Published:** April 15, 2017

Abstract

Injuries to the tarsometatarsal joint (TMT) are rare but have a relevant impact on the patient. Three cases are presented that reflect various injury mechanisms. A review of the literature focuses on the injuries and their future prognosis.

Keywords: *Lisfranc injuries; Injuries to the TMT joint*

Introduction

The Lisfranc, or tarsometatarsal joint is named after Jacques Lisfranc de Saint-Martin (1790-1847) who worked as a French Napoleonic-era field army surgeon. He preferred to perform an amputation through this joint as it was faster than cutting through the bone in soldiers who injured a foot as they fell off a horse with the foot caught in the stirrup and developed gangrene. Although Lisfranc did not describe the injuries or mechanism of injury in the tarsometatarsal region, his name is used to describe injuries in this joint line. Today, it is used to describe an injury to the midfoot centered on the 2nd tarsometatarsal joint.

It is the articulation of the tarsus with the metatarsal bases, whereby the first three metatarsals articulate respectively with the three cuneiforms, and the 4th and 5th metatarsals with the cuboid. The Lisfranc ligament spans from the medial cuneiform to the 2nd metatarsal base on the plantar aspect of the foot. Its integrity is crucial for the stability of the Lisfranc joint. Sagittal plane motion takes place at the fifth TMT joint with 10 to 20 degrees and the 1st TMT, which allows significant sagittal and also coronal plane motion [1].

Injuries to the TMT joint complex occur in 1 in 55,000 persons each year, which contributes in 0.2% to all fractures [2]. They are two to four times more common in men with an average age in the mid-thirties [3].

The relevance of the TMT joint lies in the transition of forces during the midstance phase of gait as it facilitates forward progression of body weight on a stable foot [4]. Loss of midfoot stability during midstance leads to a failure to position the foot effectively for the push-off phase. It can manifest as abnormal foot posture [5,6] often characterized by a lower arch and negative talar first metatarsal angle. These changes may lead to an increased tensile stress on the supporting plantar ligaments as the foot is loaded and contributes to the development of foot pain [7]. It also impacts the foot's ability to function effectively as a rigid lever. Arch lowering during the push-off phase of gait may also lead to greater demands on muscular and ligamentous supports, leading further to tissue stress and pain during level walking, stair ascent and descent as well as in any activities that require heel raise.

Hodge [8] and Burns [9] described the key relationship between plantar loading and the development of foot pain with higher plantar loads resulting in higher pain scores.

The common mechanism of the injury is usually described as a result of indirect or direct trauma. In indirect injuries, a longitudinal force extends through the midfoot, e.g. a fall from a height leading on the forefoot or forced hyperflexion forces at the midfoot in a motor vehicle accident. The mechanism of a direct trauma is a crushing force onto the midfoot, e.g. a heavy object landing on the foot. Vuori [10] could not find a relationship between the mechanism of injury and the type of Lisfranc joint dislocation.

The varying degree of violence can cause associated injuries, which can involve fractures of the metatarsals, cuneiforms, navicular and cuboid [10-12].

The amount of energy that is applied to the TMT joint contributes to the clinical presentation of the injury. A high-energy trauma can cause severe deformity due to displaced fractures and/or dislocations at the TMT joint. In this respect, a midfoot swelling, deformity due to the resultant displacement or ecchymosis may be more obvious. The foot can appear shortened and abducted at the forefoot. The massive foot swelling accompanying these injuries can mask the bone deformity, however.

Low-energy injuries, in contrast, are thought to be primarily ligamentous injuries involving the Lisfranc ligament. Their clinical appearance can be very subtle and potentially missed on initial evaluation or the standard X-ray. The patient may be able to enter the examination room with a limb or weight-bearing on the heel.

Closed injuries can lead to a compartment syndrome. Clinically, a compartment syndrome should be suspected when the pain is out of proportion with the injury, constant, or if it cannot be controlled with analgesia.

There are several classifications that have not proven to be useful for determining the treatment or the prognosis for this injury. The most common classification is that of Quenu and Kuss [13], which has been modified by Hardcastle [14] and relabeled by Myerson [3]:

Classification modified by Myerson (1986)
Type A: Total incongruity - medial or lateral displacement
Type B: Partial incongruity - medial (type B1) or lateral (type B2)
Type C: Divergent displacement - partial (type C1) or total (type C2)

However, for the prognosis, the site of the injury is essential. Chido and Myerson [15] suggested a classification based on the three anatomic columns of the foot:

Columns of the midfoot according to Chido and Meyerson (2001)
Medial column: includes first tarsometatarsal joint
Middle column: includes second and third tarsometatarsal joints
Lateral column: includes fourth and fifth tarsometatarsal joints (most mobile)

The relevance for this model lies in the risk of OA. Komenda [16] found post-traumatic arthritis more commonly at the base of the second metatarsal, suggesting that incongruity is better tolerated at the medial and lateral columns. The lateral column, in contrast, has the greatest amount of sagittal plane motion, but is the least likely to be involved in post-traumatic arthritis.

Usually, the diagnosis can be made on X-ray films. X-rays need to include ap, oblique and true lateral views. Weight-bearing lateral views may not be tolerated in the acute phase. The initial radiographs may be inaccurate. It is estimated that almost 20% are missed on initial presentation in the hospital [10,17,18] as true lateral views may not be included in the standard views.

It requires a high index of clinical suspicion to form a proper diagnosis. Therefore, CT scans contribute to further visualisation of fracture extensions and involvement of the adjacent joints. MRI scans detect ligament injuries, especially the integrity of the dorsal and plantar bundles of the Lisfranc ligament, the plantar tarsal-metatarsal ligaments, and the medial-middle cuneiform ligament. It may even serve as a predictor for midfoot stability when the plantar Lisfranc ligament bundle is used as a predictor. Rupture or grade-2 sprain of the plantar ligament between the first cuneiform and the bases of the second and third metatarsals is highly suggestive of an unstable midfoot for which then surgical stabilisation is recommended [19].

There are radiographic signs that suggest an injury in the Lisfranc:

- Disruption of the continuity of a line drawn from the medial base of the second metatarsal to the medial side of the middle cuneiform.

- Widening of the interval between the first and second ray
- The medial side of the base of the fourth metatarsal does not line up with medial side of cuboid on oblique view.
- Disruption of the medial column line (line tangential to the medial aspect of the navicular and the medial cuneiform).
- Lateral views (non-weight-bearing radiographs) may show dorsal displacement of the proximal base of the first or second metatarsal
- AP views may see a bony fragment (fleck sign) in first intermetatarsal space, which suggests the avulsion of Lisfranc ligament from the base of 2nd metatarsal
- Oblique views: malalignment of fourth metatarsal and cuboid

Case Reports

The following cases show that complex injuries can also occur as low impact injuries with little clinical symptoms. As treating physician or, later, as medical expert (witness) the question arises, which relevance the injury has regarding the long-term perspective and the risk of osteoarthritis.

First Case

A 39-year-old woman crossed the dance floor in high heels. She missed a step and twisted her ankle into supination. She felt immediate pain in her foot and was unable to bear weight afterwards. The following day, she presented in A and E where swelling was documented that included the whole foot. X-rays and CT scans were conducted. The standard X-rays raised suspicion due to a widening between the second and third ray. CT scans revealed fractures to the cuneiforms.

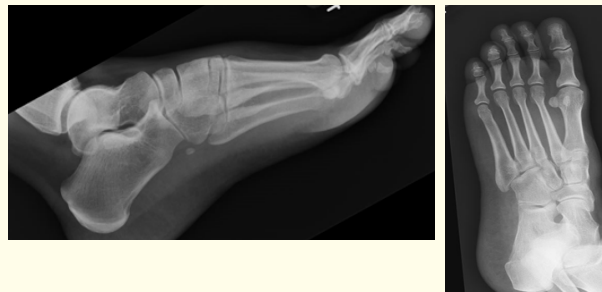

Figure 1: XR left foot: Widening of the 2nd and 3rd ray.

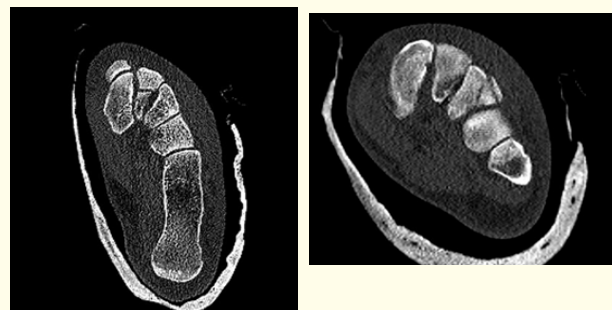


Figure 2: CT scan with fractures to the cuneiforms II and III.

Her treatment included an open reduction with an internal plate fixation. 13 months after surgery, the patient complained of moderate and constant pain in her left foot. Her night rest was still disturbed. Her foot over the scar sites had become oversensitive. She had difficulties walking on uneven ground, which is felt as painful. Also, her comfortable walking distance is reduced to 15 minutes. She suffers from swelling episodes that are mainly located over the first MCP. Also, she feels pain over the first metatarsal joint. She has difficulties climbing stairs or carrying weights and cannot wear heels anymore.

On examination, the patient stands with a flat foot deformity, which is more pronounced on the affected than on the opposite side. She indicates tenderness on movements of the subtalar and midfoot joints. Dorsi and palmar flexion is unimpeded. The range of movement in her subtalar joint is 60 percent as compared to the opposite side. Midfoot mobility is stiff. She indicates tenderness on lateral compression and axial compression of the first and second digit. Also, mobilisation of the first and second metatarsal is indicated as painful.

Second Case

A 54-year-old man was chasing a sheep on a meadow. He overlooked a ditch that was overgrown with grass and stepped into a 2-foot-deep hole. He wore normal shoes and noticed immediate and immobilising pain in his foot. Some moderate swelling occurred over the mid- and forefoot. On examination, the patient had only minor swelling over the midfoot with localised pain on lateral compression of the midfoot and on plantar palpation. His ankle and subtalar joint appeared without tenderness on mobilisation, the midfoot mobility, in contrast, was painfully reduced.

Initial X-rays found some widening and irregularity between the first and second metatarsal bone. The true lateral view revealed dislocation in the Lisfranc joint line.

CT-scans were conducted that found some extensive bone injuries to the cuboids, dislocation of the second metatarsal bone. The base of the second metatarsal bone had some destruction of the joint facet with approximately 50% involvement.

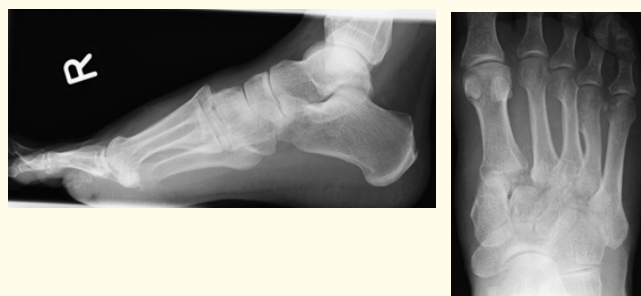

Figure 3: XR left foot: lateral view with prominence in the TMT joint line. AP with fracture dislocation of the 1st and 2nd ray.

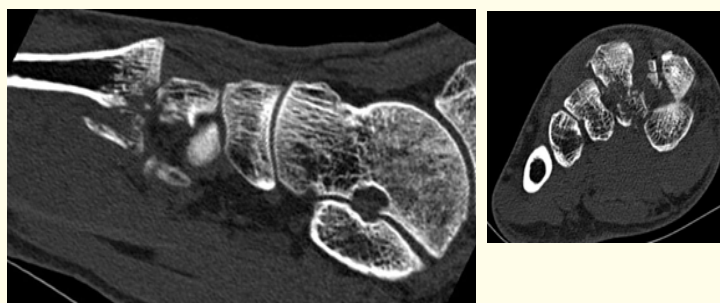


Figure 4: CT scan with complex fracture dislocation of base of the 2nd ray, separation between the 1st and 2nd metatarsal and comminuted fractures of the cuneiforme II.

Case 3

A 54-year old chef sustained a motorbike accident. He came off his motorbike and was catapulted into a ditch where he impacted the ground with his feet first. He sustained multiple fractures including an open tibia fracture, a fracture to the femur and wrist as well as an open fracture dislocation of his TMT joint. The diagnosis was made under Image Intensifier in theatre during the process of applying the external fixator. All injuries occurred on the same side. He underwent a second stage reduction and fixation of his Lisfranc injury, which included K-wiring. The K-wires were removed some 12 weeks after surgery.

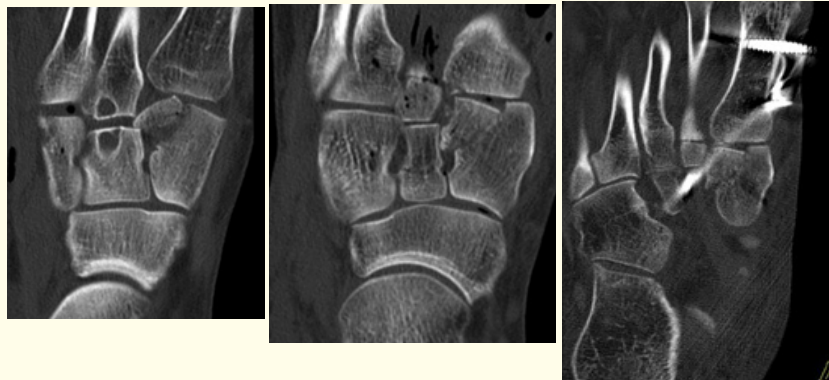

Figure 5: CT scan with complex fracture dislocation of the cuneiforme I. Initial and temporary retention achieved in external fixator and extraarticular screw.

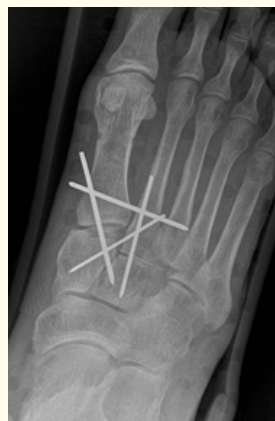

Figure 6: K-wire fixation leading to anatomical reduction. The wires were removed later.

37 months after injury, the patient continues complaining of symptoms in his foot. He experiences difficulties when he walks or climbs stairs. At home, he is able to climb stairs without difficulties, which is mainly due to his installed grab rail. However, without a rail, he can only take one step at a time. His comfortable walking distance is 1 mile but he walks with a limp. He feels insecure when he stands and turns bearing weight on his right foot or when he changes directions. He can't stand for more than 1 hour. He has no trust bearing full weight on his foot, for example, when he lifts a bucket of water or a heavy tray. Also, he finds it difficult to balance heavier items, e.g. potatoes or a sack or rice, which are loose and prone to move around. It causes severe discomfort in his right foot. Also, he does not tolerate security boots and only wears trainers or sandals. He feels insecure walking on uneven ground as he may lose his balance. He walks more easily on flat surfaces.

On examination, the range of movement in his ankle joint is unimpeded. Pro and supination is reduced by 20%, midfoot mobility by 20% in comparison to the opposite side. He indicates tenderness on midfoot mobilization in the Lisfranc joint line and tenderness on palpation of the base of the fifth metatarsal. He has no Achilles tendon tightness. The patient is unable to stand on his heels or toes.

Discussion

Ligament injuries and fracture-dislocations involving the tarsometatarsal joints may lead to chronic pain and functional loss because of arthritis, deformity, residual ligamentous instability, and associated soft-tissue injury. Untreated, they result in poor outcomes.

They are prone to be missed in 20% of the patients due to the discrete presentation or in polytraumatized patients.

It is presently accepted that fracture-dislocations of the tarsometatarsal junction of the foot are best treated if an anatomic and stable restoration is achieved. The reduction of the second metatarsal ray is the keystone and the first step of surgical reconstruction followed by the other structures involved.

This can be achieved by closed, percutaneous or open methods. Today, the standard approach consists of an open reduction with internal or transarticular fixation or primary fusion [20]. Debate remains as to which approach is better. More recently, bridge plating has been used more often. The joint spanning function stabilises the reduced fracture dislocation temporarily and aims at minimising the articular damage as in transarticular screw fixation. It leads to at least to similar results compared with transarticular fixation in terms of functional outcomes and patient satisfaction [21].

However, despite correct surgical technique and postoperative management, a symptom-free recovery is uncommon [22]. The risk is markedly increased if the extent of the injury has initially been missed, only partially treated, or if the anatomy was not restored [23]. Nonanatomic reduction, osteomyelitis, deformity of toes, planus foot, and discomfort on prolonged walking are the most common unfavorable outcomes.

But despite a seemingly anatomic restoration of normal alignment, many patients fare poorly. This applies to fractures as well as merely ligamentous injuries undergoing screw fixation [24]. The results from Teng [25] revealed that when anatomic reduction is accomplished in tarsometatarsal fracture dislocation of the foot, objective measures of gait analysis are returned to normal. But despite excellent radiographic results and a return to normal dynamic walking patterns, subjective patient outcomes were less than satisfactory.

The outcome strongly correlates with an anatomic and stable reduction. A review of the literature reveals a better clinical and functional outcome in patients with stable conditions. The best surgical treatment, however, remains controversial. Most surgeons agree that an appropriate reduction is better and easier achieved by open reduction with a stable temporary screw or dorsal plate fixation or by open primary partial arthrodesis rather than by closed reduction or Kirschner wire fixation.

Posttraumatic arthritis is a complication that is strongly associated with Lisfranc joint injuries. The most common area of involvement is the first, second, and fourth TMT joint [3]. The incidence after ORIF varies between 40% and 94% [23]. The high incidence may depend on the fixation technique. On the one hand, it is directly proportional to the area of damage on the articular surface. On the other hand, the iatrogenic destruction of tarsometatarsal joint surfaces cartilage as a result of the chosen fixation modality may be one further contributing reason of post traumatic arthritis. But OA can also occur in primary arthrodesis. Reinhardt [26] found in his population at a mean of 42 months in 3/25 radiographic signs of OA.

Arthritis may occur early. It can already be noted after 2 to 3 years [27]. These results are in keeping with other studies. In a follow-up over 8 years and more, Abbasian [28] could find arthritis in 8/29 patients with mere ligamentous injuries and 10/29 patients with osseous involvement. Apparently, there was no significant difference in the outcome between the chosen treatment modality.

Zhang (2013) concluded that the incidence of post-traumatic osteoarthritis was higher in the patients with non-anatomic reduction, cuneiform bone fracture/dislocation and comminuted intra-articular fractures of Lisfranc joints. After an average of 3,5 years, 9/35 showed signs of osteoarthritis.

In a review by Stavlas [12], post-traumatic radiographic arthritis occurred in 49.6% of the patients. 7.8% of them were severe enough to warrant an arthrodesis.

Dubois-Ferrière [29] found at a mean of 10,9 years in 72% radiographic evidence of OA, 54% being symptomatic.

The primary aim of treatment is to afford pain relief by enhancing midfoot stability and modifying the loads sustained at the affected joints. Nonsurgical options involve non-steroidal anti-inflammatory drugs (NSAIDs), full-length rigid foot plates, and shoe modifications. If these methods fail, arthrodesis of the painful tarsometatarsal joints is the treatment of choice [30]. The surgical goal is to reduce painful motion and increase the stability of the foot. This goal can be obtained through partial or total fusion of the tarsometatarsal joints [31].

The treating specialist should also be aware that a patient undergoing ORIF has an increased risk of hardware removal along with its associated morbidity. The risk is increased in patients with intraarticular fixation rather than primary fusion [32].

Conclusion

Although rare, injuries to the TMT joint can occur even as low impact injuries in day-to-day life. If missed, the prognosis is poor. The aim of a stable and pain free condition cannot always be achieved. Osteoarthritis is common and occurs at an already early stage. Even if treatment is adequate, painful restrictions can develop or remain, which can result in a salvage arthrodesis.

Bibliography

1. Ouzounian TJ and Shereff MJ. "In vitro determination of midfoot motion". *Foot Ankle* 10.3 (1989): 140-146.
2. Englanoff G., et al. "Lisfranc fracture-dislocation: a frequently missed diagnosis in the emergency department". *Annals of Emergency Medicine* 26.2 (1995): 229-233.
3. Myerson MS., et al. "Fracture dislocations of the tarsometatarsal joints: End results correlated with pathology and treatment". *Foot and Ankle International* 6 (1986): 225-242.
4. Song J., et al. "Foot type biomechanics. Comparison of planus and rectus foot types". *Journal of the American Podiatric Medical Association* 86.1 (1996): 16-23.
5. Wadsworth DJ and Eadie NT. "Conservative management of subtle Lisfranc joint injury: a case report". *Journal of Orthopaedic and Sports Physical Therapy* 35.3 (2005): 154-164.
6. Hunt AE., et al. "Inter-segment foot motion and ground reaction forces over the stance phase of walking". *Clinical Biomechanics (Bristol, Avon)* 16.7 (2001): 592-600.
7. Gazdag AR and Cracchiolo A. "Rupture of the posterior tibial tendon. Evaluation of injury of the spring ligament and clinical assessment of tendon transfer and ligament repair". *Journal of Bone and Joint Surgery- American* 79.5 (1997): 675-681.
8. Hodge MC., et al. "Novel Award First Prize Paper: Orthotic management of plantar pressure and pain in rheumatoid arthritis". *Clinical Biomechanics (Bristol, Avon)* 14.8 (1999): 567-575.
9. Burns J., et al. "The effect of pes cavus on foot pain and plantar pressure". *Clinical Biomechanics (Bristol, Avon)* 20.9 (2005): 877-882.
10. Vuori JP and Aro HT. "Lisfranc joint injuries: trauma mechanisms and associated injuries". *Journal of Trauma* 35.1 (1993): 40-45.
11. Nithyananth M., et al. "Long-term outcome of high-energy open Lisfranc injuries: a retrospective study". *Journal of Trauma* 70.3 (2011): 710-716.

12. Stavlas P, *et al.* "The role of reduction and internal fixation of Lisfranc fracture-dislocations: a systematic review of the literature". *International Orthopaedics* 34.8 (2010): 1083-1091.
13. Quenu E and Kuss G. "Study on the dislocations of the metatarsal bones (tarsometatarsal dislocations) and diastasis between the 1st and 2nd metatarsals [French]". *Revue De Chirurgie Orthopedique Et Reparatrice De L'Appareil Moteur* 39 (1909): 281-336, 720-791, 1093-1134.
14. Hardcastle PH, *et al.* "Injuries to the tarsometatarsal joint: Incidence, classification and treatment". *Journal of Bone and Joint Surgery-British* 64.3 (1982): 349-356.
15. Chiodo CP and Myerson MS. "Developments and advances in the diagnosis and treatment of injuries to the tarsometatarsal joint". *Orthopedic Clinics of North America* 32.1 (2001): 11-20.
16. Komenda GA, *et al.* "Results of arthrodesis of the tarsometatarsal joints after traumatic injury". *Journal of Bone and Joint Surgery-American* 78.11 (1996): 1665-1676.
17. Myerson M. "The diagnosis and treatment of injuries to the Lisfranc joint complex". *Orthopedic Clinics of North America* 20.4 (1989): 655-664.
18. Arntz CT and Hansen ST. "Dislocation and fracture dislocations of the tarsometatarsal joints". *Orthopedic Clinics of North America* 18.1 (1987): 105-114.
19. Raikin SM, *et al.* "Prediction of midfoot instability in the subtle Lisfranc injury. Comparison of magnetic resonance imaging with intraoperative findings". *Journal of Bone and Joint Surgery- American* 91.4 (2009): 892-899.
20. Mittlmeier T and Beck M. "Tarsometatarsal injuries--an often neglected entity". *Therapeutische Umschau* 61.7 (2004): 459-465.
21. van Koperen PJ, *et al.* "Functional Outcomes After Temporary Bridging with Locking Plates in Lisfranc Injuries". *Journal of Foot and Ankle Surgery* 55.5 (2016): 922-926.
22. Krause F, *et al.* "Current Swiss Techniques in Management of Lisfranc Injuries of the Foot". *Foot and Ankle Clinics* 21.2 (2016): 335-350.
23. Mulier T, *et al.* "Severe Lisfrancs injuries: primary arthrodesis or ORIF?" *Foot Ankle International* 23.10 (2002): 902-905.
24. Kuo RS, *et al.* "Outcome after open reduction and internal fixation of Lisfranc joint injuries". *Journal of Bone and Joint Surgery- American* 82-A11 (2000): 1609-1618.
25. Teng AL, *et al.* "Functional outcome following anatomic restoration of tarsal-metatarsal fracture dislocation". *Foot Ankle International* 23.10 (2002): 922-926.
26. Reinhardt KR, *et al.* "Treatment of Lisfranc fracture-dislocations with primary partial arthrodesis". *Foot Ankle International* 33.1 (2012): 50-56.
27. Sun-jun Hu, *et al.* "Outcome comparison of Lisfranc injuries treated through dorsal plate fixation versus screw fixation". *Acta Ortopédica Brasileira* 22.6 (2014): 315-320.

28. Abbasian MR., *et al.* "Temporary Internal Fixation for Ligamentous and Osseous Lisfranc Injuries: Outcome and Technical Tip". *Foot Ankle International* 36.8 (2015): 976-983.
29. Dubois-Ferrière V., *et al.* "Clinical Outcomes and Development of Symptomatic Osteoarthritis 2 to 24 Years After Surgical Treatment of Tarsometatarsal Joint Complex Injuries". *Journal of Bone and Joint Surgery- American* 98.9 (2016): 713-720.
30. Coss HS., *et al.* "Abduction stress and AP weightbearing radiography of purely ligamentous injury in the tarsometatarsal joint". *Foot Ankle International* 19.8 (1998): 537-541.
31. Coetzee JC. "Making sense of lisfranc injuries". *Foot and Ankle Clinics* 13.4 (2008): 695-704.
32. Smith N., *et al.* "Does Open Reduction and Internal Fixation versus Primary Arthrodesis Improve Patient Outcomes for Lisfranc Trauma? A Systematic Review and Meta-analysis". *Clinical Orthopaedics and Related Research* 474.6 (2016): 1445-1452.

Volume 5 Issue 6 April 2017

© All rights reserved by Ekkehard Pietsch.