

## Predicting Intra-Operative Periprosthetic Fracture during Uncemented Hemiarthroplasty for Intracapsular Neck of Femur Fractures

Harpal Uppal<sup>1</sup>, Anil Dhadwal<sup>2</sup>, Chris Downham<sup>1</sup>, Ben Dean<sup>4</sup>, Partha Bose<sup>3</sup>, Adnan Saithna<sup>5\*</sup>

<sup>1</sup>Department of Trauma and Orthopaedic, University Hospital Coventry and Warwickshire, UK

<sup>2</sup>Department of Trauma and Orthopaedics Alexandra Hospital, Redditch, UK

<sup>3</sup>Department of Neurological Rehabilitation Oxford Statistical Consulting, Oxford, UK

<sup>4</sup>Department of Clinical Neurosciences, Nuffield Orthopaedic Centre, Oxford, UK

<sup>5</sup>Department of Musculoskeletal Biology, Southport and Ormskirk Hospitals NHS trust, UK

\*Corresponding Author: Adnan Saithna, Department of Musculoskeletal Biology, Southport and Ormskirk Hospitals NHS trust, UK.

Received: March 16, 2016; Published: May 16, 2016

### Abstract

**Context:** Current guidelines recommend cemented over uncemented hemiarthroplasty for intracapsular neck of femur fractures. However, the use of uncemented implants remains prevalent. This in part is due to their “user- friendly nature”, the avoidance of polymethylmethacrylate complications and shorter operating times. However, uncemented implants are associated with an increased risk of periprosthetic fracture.

**Aims:** The objective of this study was to develop a simple tool to be used at the pre-operative planning stage to assess patients for the risk of intra-operative fracture.

**Method:** A retrospective review of a 3-year cohort of neck of femur patients (n= 235) was conducted. Radiographic measurements of the width of the intra medullary canal of the proximal femur were compared in a bootstrapping analysis between patients who experienced an intra-operative fracture (n=13) and those who did not.

**Results:** Kolmogorov Smirnov two-sample analysis demonstrated that the population of patients who sustained an intra-operative fracture were significantly different to those who did not by virtue of the fact that they had larger measurements of the intramedullary canal. Intra-operative fracture is significantly more likely in those patients who have an upper LT width and a lower LT width of greater than 38.5 mm and 26 mm respectively.

**Conclusions:** Simple measurements of canal width are easily obtained and can help identify patients at high risk of intra-operative fracture. Clinicians should consider using a cemented prosthesis for those patients whose measurements exceed the recommended values.

**Keywords:** *Uncemented hemiarthroplasty; Hip fracture; Intra-operative fracture; Complications*

### Key Messages

There is an increased risk of intra-operative fracture when using an uncemented versus cemented implant for hemiarthroplasty of the hip.

Simple measurements based on calibrated plain films can help identify those patients with increased risk of intra-operative fracture.

Clinicians should consider using a cemented implant in patients who are stratified as high risk.

### Introduction

In the United Kingdom, the majority of patients who sustain an intracapsular neck of femur fracture are treated with a hemiarthro-

plasty of the hip [1]. Traditionally, an uncemented technique has been considered safer than a cemented technique as it avoids the rare but serious risk of systemic polymethylmethacrylate related complications. In addition, the use of uncemented implants is associated with shorter operating times, which are obviously favoured in frail, elderly patients with multiple co-morbidities. Despite these perceived advantages, Parker, *et al.* reported in their 2010 randomised controlled trial that cemented hemiarthroplasty is associated with better pain relief and function with no statistically significant difference in mortality or post-operative medical complications [2]. These findings were further supported by evidence from the Cochrane review, which also suggested reduced postoperative pain and increased mobility [3]. Furthermore, data from the Australian National Joint Replacement Registry also supports the use of cemented implants due to the considerably higher rate of revision surgery associated with the use of uncemented prostheses [4].

In light of these studies, the UK body responsible for producing clinical guidelines for health professionals (National Institute for Health and Clinical Excellence (NICE)) have recommended the use of cemented over uncemented implants [5]. Despite these guidelines, opinions between orthopaedic surgeons regarding prosthesis choice in neck of femur fracture patients remains divided. This is evidenced by data from the National Hip Fracture Database Report which showed that 15.8% of all hemiarthroplasties in the UK are still performed with uncemented implants [6].

One of the most popular uncemented implants is the Austin-Moore Hemiarthroplasty (AMH) [7]. This was developed in the 1950's and has gone through minor revisions in design over the last 60 years. The key features are that of a mono-bloc implant with a keel and voids in the stem to allow bony ingrowth. There are a number of studies which have suggested that use of the AMH is associated with an increased risk of peri-prosthetic fracture [8,9]. As the implant remains in popular use, we sought to determine whether simple measurements performed on plain radiographs could provide information about risk of peri-prosthetic fracture. The objective was to develop a simple tool to be used at the pre-operative planning stage that would allow surgeons who are considering using an AMH to risk assess patients and identify those in whom they should use a cemented implant instead.

### Methods

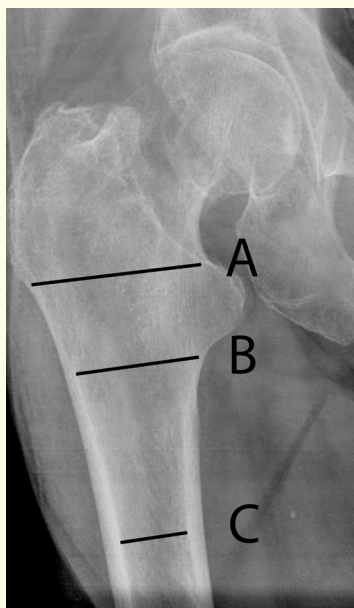
It is our departmental policy to perform uncemented hemiarthroplasty of the hip with an AMH for displaced intracapsular neck of femur fractures. We identified two hundred and fifty eight consecutive patients who underwent hemiarthroplasty of the hip via the hospital theatre management computer system (Bluespier International, Worcestershire, UK) which had, at the time of data collection, been in operation for three years. We did not exclude any patients. The operation notes, patient records and post-operative radiographs were reviewed independently by two observers to determine if an intra-operative peri-prosthetic fracture had occurred.

Plain postoperative radiographs were viewed (using PACS software by AGFA) by two observers and measurements made of the implant size. The magnification of the radiographs was corrected for by creating a ratio of the radiograph size and the actual implant size as recorded from the operation notes. Using this ratio the femoral canal diameter was measured at the level of the top of the lesser trochanter (Upper LT), bottom of the lesser trochanter (Lower LT) and at 75 mm distal to the lesser trochanter (75 mm LT) (Figure 1). Measurements were made perpendicular to the femoral shaft and according to the methods of Sen, *et al.* [10]. Anonymised data was also collected upon the seniority of the surgeon operating, and the age and gender of the patient. Due to errors in record keeping particularly with regard to radiographs these measurements could only be made for 235 patients.

Statistical analysis was performed by a statistician using Mat lab 7.0 software. Two groups of patients were identified, patients with no intra-operative fractures (Group A) and patients with intra-operative fractures (Group B). The inherent problem in investigating intra-operative peri-prosthetic fracture is that it is a rare event resulting in small sample sizes in any study investigating it. In addition, whilst the normal distribution is traditionally a well-regarded one for biometric purposes, it seems inaccurate to make assumptions of normality for variables such as age in such a select population. To overcome these two problems, we have used bootstrapping and non-parametric testing respectively to compare the characteristics from the two groups. Bootstrapping involves repeatedly drawing observations from a parent sample to create different re samples. If for example we had a sample of 20 observations, we could only calculate one instance of their average. In bootstrapping we could create a 100 samples, each with 50 observations in them (each sample would naturally have at

least one value appearing more than once). In this way we could derive 100 estimates of the average, giving us not only an unbiased estimate of the mean but also an unbiased estimate of the distribution of the mean statistic. For our study, we have created 10,000 bootstrap samples, each with 100 observations from each of Group A and Group B. From each sample we can then estimate the average age, upper LT, lower LT and 75 mm LT, giving us 10,000 observations for each of them.

For the purpose of comparing the distributions from each of the two groups, we can now use the Kolmogorov Smirnov two-sample test. This test measures the maximum distance in the difference of the empirical distribution functions for the two characteristics being considered. In the event of this value being significantly high, it indicates that they are from different distributions. This test has the added advantage of not making any distributional assumptions.



**Figure 1:** The level of the top of the lesser trochanter (Upper LT), bottom of the lesser trochanter (Lower LT) and at 75 mm distal to the lesser trochanter (75 mm LT).

## Results

Thirteen intra-operative peri-prosthetic fractures were observed in our group of 258 patients. These were classified using the Vancouver system [11]. Ten patients sustained Vancouver type A fractures and three Vancouver type B fractures. There were no type C fractures. All fractures were successfully treated with cerclage wires. Histograms of age, upper LT, lower LT and 75 LT (Figures 2 a, b, c, d) demonstrate that the distribution of these variables is not normal, validating our decision to use boot strapping and the Kolmogorov Smirnov test.

The average age in groups A and B was 83 and 85 years respectively. Kolmogorov Smirnov tests were performed on the bootstrap distributions (Figures 3 a, b, c, d) of each of the average age, upper LT, lower LT and 75 mm LT. The level of significance was set at 5%. These analyses lead to a rejection of the null hypothesis, that these variables come from the same distribution for each of them, in favour of the alternative hypothesis, that the distribution for each characteristic in Group B is greater than that in Group A. This result supports the theory that older patients and patients with larger Upper LT, Lower LT and 75 mm LT measurements are more likely to suffer a fracture than younger patients, or patients with smaller measurements.

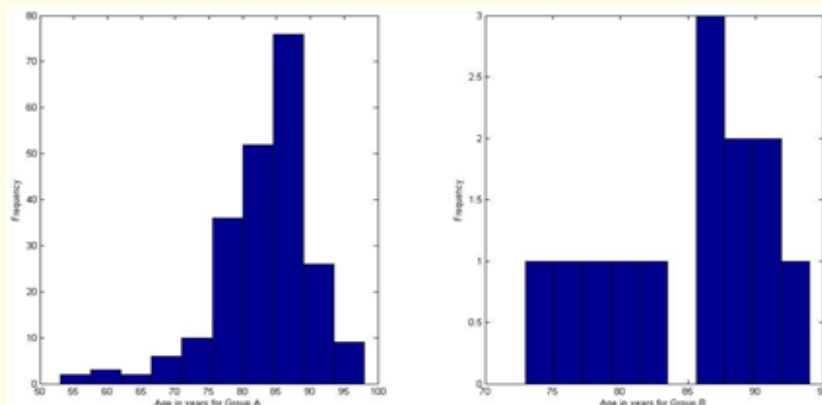


Figure 2a: Age distribution.

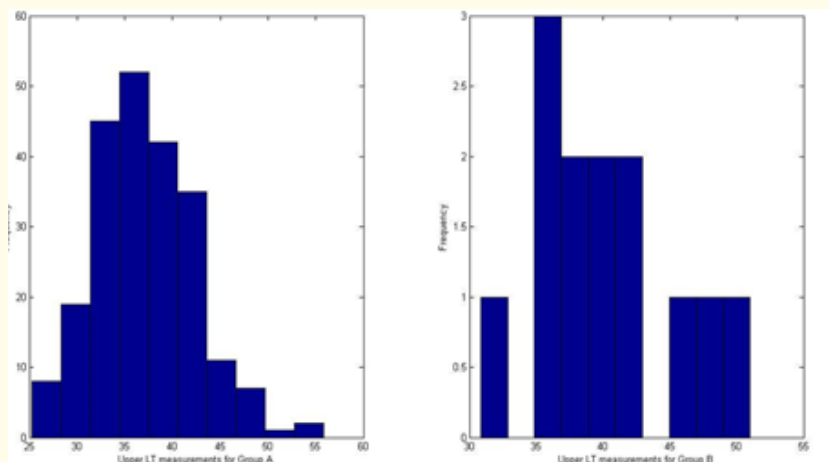


Figure 2b: Upper LT distribution.

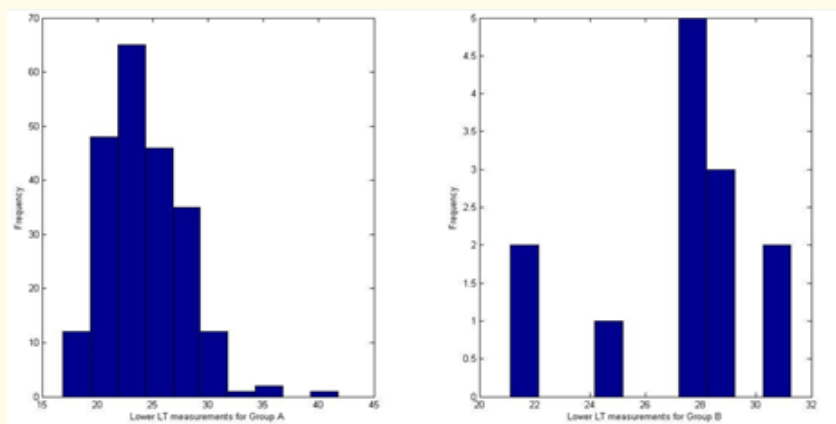


Figure 2c: Lower LT distribution.

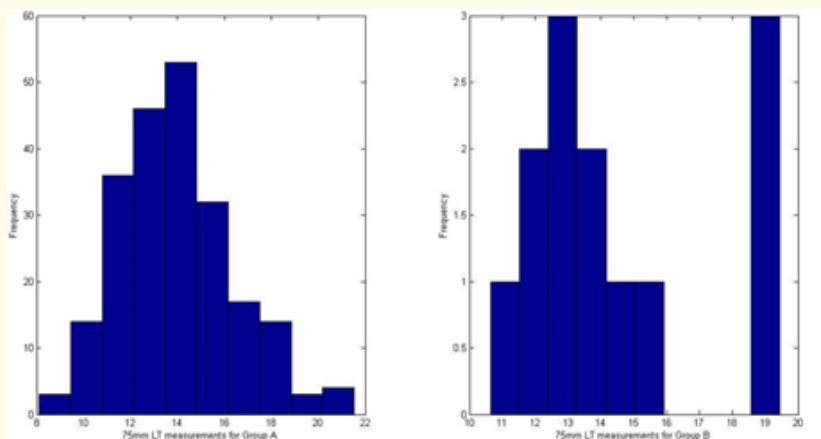


Figure 2d: 75mm LT Distribution.

Due to the small number of patients who sustained an intra-operative fracture, we were unable to make any calculations that might allow us to establish a threshold above which the procedure would be inadvisable for any of the above characteristics. However, this is an issue with analysis of any complication that occurs reasonably infrequently. It is therefore reasonable on examination of Figs 2b and 2c to suggest that measurements above 38.5 mm for the Upper LT, and 26 mm for the lower LT would be a reasonable guideline to advise against performing the procedure, after which factors such as age should be considered.

We did not find sex or grade of surgeon to have any prognostic influence on risk of peri-prosthetic fracture. The Chi squared with Yates correction was 0.11 for having a consultant surgeon scrubbed or not ( $p = 0.736$ ). The Chi squared with Yates correction was 0.025 for female patients being more likely to sustain a fracture ( $p = 0.9$ ).

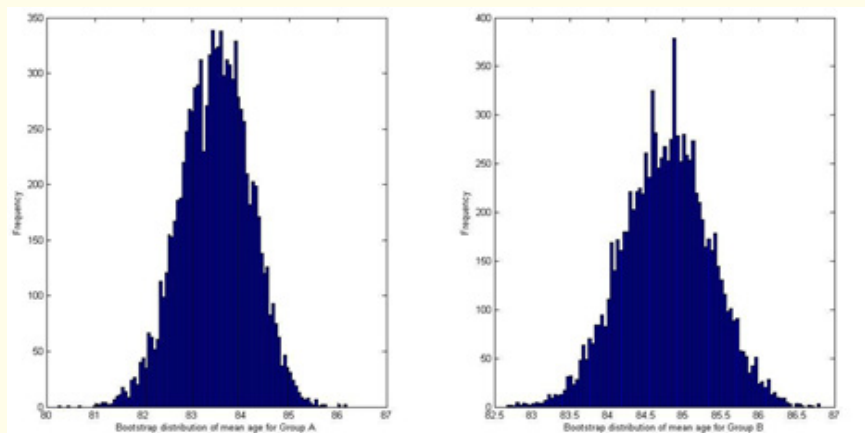


Figure 3a: Age Bootstrap distribution.

### Discussion

Osteoporosis is a major risk factor for intraoperative peri-prosthetic fracture when using an uncemented implant. Blain, et al. demonstrated by histomorphometry that osteoporosis is associated not only with proximal femoral cortical thinning but also increased marrow star volume [12]. We postulated that simple measurements of femoral canal diameter could provide a surrogate marker for these more

elaborate measurements and therefore provide useful information to assist in predicting risk of intra-operative fracture.

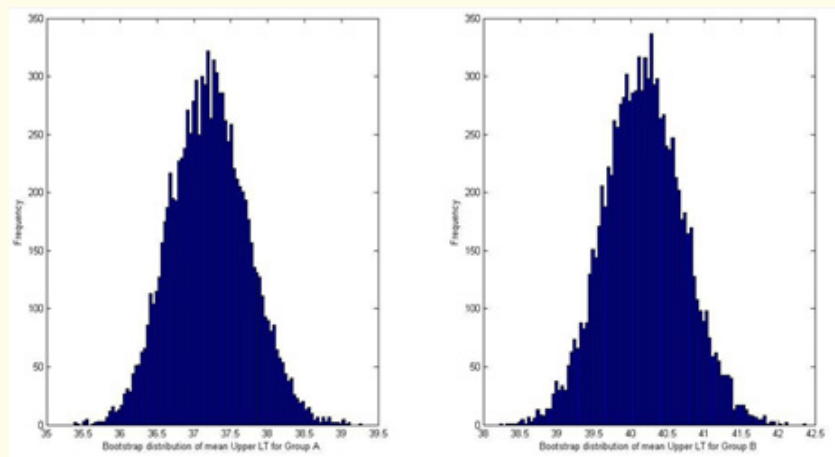


Figure 3b: Upper LT Bootstrap distribution.

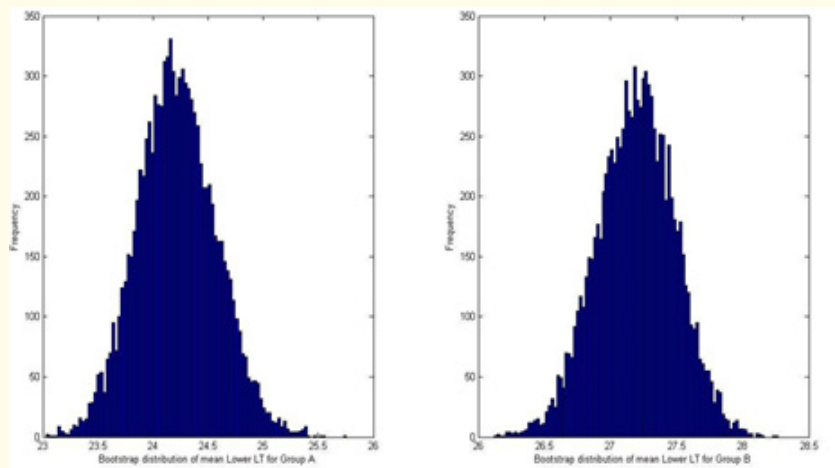


Figure 3c: Lower LT Bootstrap distribution.

We demonstrated that intra-operative fracture is significantly more likely in those patients who have upper and lower LT widths of greater than 38.5 mm and 26 mm respectively. It is quite easy to determine these measurements from plain radiographs provided that a scale marker is used. Many centres now routinely use pre-operative planning to facilitate precise restoration of femoral offset, leg length and alignment and also to reduce the duration of surgery and the risk of periprosthetic fracture [13,14]. As such, the use of sizing balls or an equivalent method at the time of taking initial emergency department radiographs is common and therefore we feel that the proposed technique can easily be adopted into clinical practice.

It is reassuring to see that our work concurs with that of previous authors who have used the Dorr classification and cortical thickness ratios to also demonstrate that proximal femoral morphology predicts the risk of intra-operative fracture during hemiarthroplasty of the hip. Dorr types B (proximal bone loss and widening of canal) and C (considerable loss of cortical thickness resulting in very wide intramedullary canal) have been demonstrated to be at increased risk of fracture [15]. Our measurements allow a greater degree of preci-

sion in recording these morphological changes than the Dorr classification which is simply descriptive. Furthermore, one of the practical problems in using the previously described measurements of cortical thickness is that they rely on high quality radiographs that can be difficult to obtain in trauma patients. Our measurements record the intramedullary canal diameter, which due to the much greater value compared to the cortical thickness, is less susceptible to large errors as a result of mal-rotation of the limb.

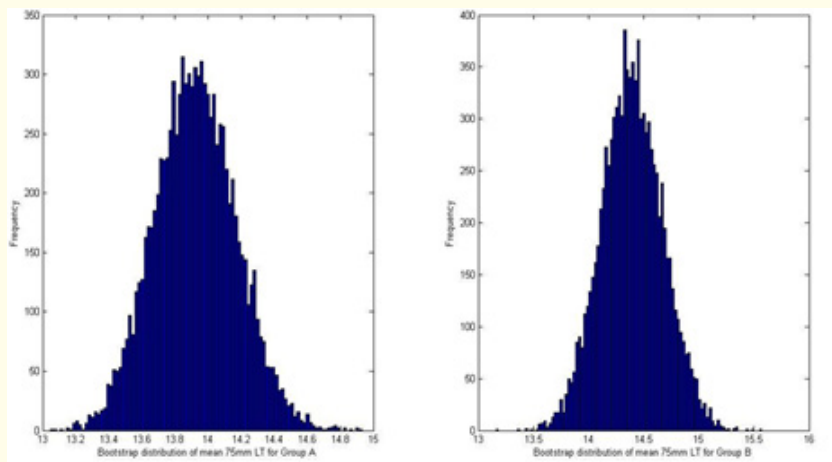


Figure 3d: 75 mm LT Bootstrap distribution.

NICE guidelines recommend the use of a cemented implant for intracapsular fractures of the neck of femur but uncemented implants are still in popular use and equivalent outcomes have been reported [5,16]. It is beyond the scope of this paper to discuss the numerous considerations required when selecting an implant nor the merits and weaknesses of the literature upon which the NICE guidance is based. However, several authors have reported that there is an increased risk of peri-prosthetic fracture with uncemented implants [8,9]. Despite this, uncemented implants like the AMH are regarded as being more “user- friendly” and perhaps more forgiving of error than cemented prostheses [17]. Thus, concerns regarding the systemic effects of cement and the low cost of implants may be driving the continued use of the AMH.

The message of this paper is not to advocate one type of implant over any other but rather to put forward a simple system of measurements that provide additional information to the surgeon in order to assist them in assessing a patients risk for peri-prosthetic fracture and perhaps select a cemented implant if that patient is identified as being at high risk.

The main limitation of this study is that only the AMH was used at our centre during the study period. It is quite possible that stems of different design and geometry would not behave in the same way and so the external validity of our results is unknown and applicability to other implants requires further study. A further limitation is that we did not stratify patients according to other recognised risk factors such as rheumatoid arthritis, Paget’s, disease, osteoporosis and chronic steroid usage [18]. The rationale for this was because this was a retrospective study and we could not be confident in the completeness of the data available for those parameters. However, many patients with neck of femur fractures will have additional risk factors and therefore our study design reflects a pragmatic approach.

### Conclusion

Uncemented hemiarthroplasty of the hip is associated with an increased risk of peri-prosthetic fracture. We advocate measuring the diameter of the femoral canal at the upper and lower borders of the lesser trochanter as part of the pre-operative planning process. If these figures exceed 38.5 mm or 26 mm respectively, then this indicates a statistically significantly elevated risk of intra-operative peri-prosthetic fracture. This should alert the clinician to the need to consider using a cemented implant and technique instead. These figures are based on using the AMH and further study is required to determine validity for other implants.

## **Bibliography**

1. Jameson SS, *et al.* "Cemented Versus Cementless Hemiarthroplasty for Intracapsular Neck of Femur fracture-A Comparison of 60,848 Matched Patients using National Data". *Injury, International Journal of the Care of the Injured* 44.6 (2013): 730-734.
2. Parker MI, *et al.* "Cemented Versus Uncemented Hemiarthroplasty for Intracapsular Hip Fractures: A Randomised Controlled Trial in 400 Patients". *The Journal of Bone and Joint Surgery* 92.1(2010): 116-122.
3. Parker M J, *et al.* "Arthroplasties (With and Without Bonecement) for Proximal Femoral Fractures in Adults". *Cochrane Database Systematic Reviews* 16.6 (2010): CD001706.
4. No-authors-listed. Australian Orthopaedic Association, National Joint Replacement Register (2010):
5. National Institute for Health and Clinical Effectiveness. The management of hip fracture in adults (2011):
6. No-authors-listed. National Hip Fracture Database National Report (2013):
7. Crossman PT, *et al.* "A Survey of the Treatment of Displaced Intracapsular Femoral Neck Fractures in the UK". *Injury* 33.5 (2002): 383-386.
8. McGraw IWW, *et al.* "Incidence of Periprosthetic Fractures After Hip Hemiarthroplasty: Are Uncemented Prostheses Unsafe"? *Injury, International Journal of the Care of the Injured* 44.12 (2013): 1945-1948.
9. Phillips JRA, *et al.* "Periprosthetic Fractures Around Hip Hemiarthroplasty Performed for Hip Fracture". *Injury, International Journal of the Care of the Injured* 44.6 (2013): 757-762.
10. Sen RK, *et al.* "Proximal Femoral Medullary Canal Diameters in Indians: Correlation between Anatomic, Radiographic and Computed Tomographic Measurements". *The Journal of Orthopaedic Surgery (Hong Kong)* 18.2 (2010): 189-194.
11. Duncan CP and Masri BA. "Fractures of the Femur after Hip Replacement". *Instructional course lectures* 44 (1995): 293-304.
12. Blain H, *et al.* "Cortical and Trabecular Bone Distribution in the Femoral Neck in Osteoporosis and Osteoarthritis". *Bone* 43.5 (2008): 862-868.
13. Carter L W, *et al.* "Determination of Accuracy of Preoperative Templating Of Noncemented Femoral Prostheses". *The Journal of Arthroplasty* 10.4 (1995): 507-513.
14. Michalikova M, *et al.* "The Digital Pre-Operative Planning of Total Hip Arthroplasty". *Acta Polytechnica Hungarica* 7.3 (2010): 137-152.
15. Nash W and Harris A. "The Dorr Type and Cortical Thickness Index of the Proximal Femur for Predicting Peri-Operative Complications during Hemiarthroplasty". *Journal of Orthopaedic Surgery (Hong Kong)* 22.1 (2014): 92-95.
16. Kendrick B J, *et al.* "Corail Uncemented Hemiarthroplasty with a Cathcart Head for Intracapsular Hip Fractures". *The Bone and Joint Journal* 95-B.11 (2013): 1538-1543.
17. Weinrauch PC, *et al.* "Early Prosthetic Complications after Unipolar Hemiarthroplasty". *ANZ Journal of Surgery* 76.6 (2006): 432-435.
18. Mayle RE and Della Valle CJ. "Intra-Operative Fractures during THA. See it Before it Sees Us". *The Bone and Joint Journal* 94.11 Suppl A (2012): 26-31.

**Volume 3 Issue 3 May 2016**

**© All rights reserved by Adnan Saithna, *et al.***