

# Does it have to be done Arthroscopically? Comparison between Open and Arthroscopic Anterior Cruciate Ligament Replacement Using a Bone-Tendon-Bone Autograft – A Prospective 5 Year Follow-Up Study

Sebastian Gottfried Walter\*, Tom Sascha Thomas, Luca Tafuro, Wolfram Thomas

Department for Orthopedic Surgery, Arthro-Surgery-Group, Rome, Italy

\*Corresponding Author: Sebastian Gottfried Walter, Department for Orthopedic Surgery, Arthro-Surgery-Group, Rome, Italy.

Received Date: January 25, 2016; Published Date: February 09, 2016

## Abstract

**Purpose:** To investigate the outcomes of an open and an arthroscopic technique for the reconstruction of the Anterior Cruciate Ligament (ACL).

**Methods:** This prospective randomized controlled trial includes 126 patients. 65 were assigned to an open ACL replacement and 61 to an arthroscopic ACL replacement, always using Bone-patellar tendon-bone (BPTB) autografts. Outcome assessment included re-rupture findings, International Knee Documentation Committee (IKDC) and Lysholm-Tegner scores, KT-1000 arthrometer measurements, Lachman, single-leg hop- and pivot-shift tests as well as range of motion (ROM) control.

**Results:** In the time between April 2008 and May 2010 we prospectively evaluated 62 patients using this open approach and 49 patients using an arthroscopic technique. Patients of the “open” group improved the IKDC score for 46.3 points comparing preoperative values with the 5 year follow-up. After 3 years and more there is no statistical difference between both groups when comparing IKDC score and Lysholm score. In addition, Ligament laxity demonstrated to be almost equal over the complete follow-up period.

**Conclusion:** Although minimal invasive open techniques seem to be widely buried in oblivion and unfashionable in an arthroscopic dominated scientific discourse, they may have equivalent clinical long term results and can therefore be considered as a solid treatment option.

**Keywords:** Anterior Cruciate Ligament Reconstruction; ACL; Bone-tendon-Bone; Autograft; Mini Open

## Level of evidence: I

### Introduction

Ruptured anterior Cruciate ligaments (ACL) are among the most common diagnoses of the knee joint -especially in young patients [1]. Therefore, a broad spectrum of techniques describing adequate treatment options and procedures has been published. [2-12]. However, there is controversy which technique offers the best outcome in terms of functionality and stability as each of them promises advantages and is associated with certain pitfalls. [12-18] Formerly ACL reconstructions were carried out with open techniques [19] but eventually replaced completely by arthroscopic techniques. Based on our clinical experience and data [20, 21] from the time when arthroscopic techniques were finding their way into standard ACL replacement we believed the mini-open technique to be still a comparable treatment alternative. Thus we hypothesized that there would be no difference in clinical outcome between ACL reconstructions performed under arthroscopic visualization or direct, “open” visualization.

**Citation:** Sebastian Gottfried Walter, et al. “Does it have to be done Arthroscopically? Comparison between Open and Arthroscopic Anterior Cruciate Ligament Replacement Using a Bone-Tendon-Bone Autograft – A Prospective 5 Year Follow-Up Study”. *EC Orthopaedics* 3.1 (2016): 233-242.

## Does it have to be done Arthroscopically? Comparison between Open and Arthroscopic Anterior Cruciate Ligament Replacement Using a Bone-Tendon-Bone Autograft – A Prospective 5 Year Follow-Up Study

### Material and Methods

From 2008 to 2010 153 patients with ACL rupture underwent reconstruction with either an open or an arthroscopic method of BPTB-graft insertion. Patients were eligible to participate in the study if

1. They were older than 18 years,
2. Had an established diagnosis based on clinical or radiological features,
3. Declared consent to participate on regular follow-up appointments, and
4. Had no history of neuromuscular or systemic disease. Patients were excluded if
  - a. They had bilateral ACL injuries,
  - b. Multi-ligament injuries,
  - c. Articular cartilage lesions greater than Outerbridge II and
  - d. Previous articular injury to, or surgery on, the affected or contralateral knee.

Over a period of 2years, 74 subjects were treated with a minimal invasive open approach using BPTB-autografts and 79 subjects were treated arthroscopically receiving BPTB grafts as well. All interventions were done by one senior surgeon who is experienced in both techniques or under his direct supervision. Prior to the start of the study subjects were randomized by a randomization program. All patients were assessed two experienced, independent and blinded examiners before surgery, as well as 6 weeks, 3, 6, 12, 24, 36 and 60 months after the intervention. Examiners were blinded as they had no access to the randomization list and the operation protocols. Furthermore, the scars on the operated knee were covered with band aids by a nurse previous to the examination in a way that a distinction between open and arthroscopic treatment was not possible and testings could be done without limitations.

Demographical data, time interval between the initial injury and the surgical treatment as well as the Tegner scale scores were calculated using median (range) values. Measurements with the KT-1000 (MEDmetric® Corp., San Diego, CA, USA), IKDC and Lysholm score evaluated using mean (standard deviation) values. For the KT-1000 measurements, an anteroposterior load of 30 pounds was applied on the knee positioned in 25° of flexion. Subjects were evaluated on the Lachmann test and Pivot- shift test. Four categories were defined for the Lachmann test: 0: 1.0 - 2.0 mm, 1+: 2.0- 5.0 mm, 2+: 5.0- 10.0 mm and 3+: >10.0 mm. The same was done for the Pivot-shift test, defining 0: equal, 1+: glide, 2+: clunk and for 3+: gross. As a measurement for the primary outcome the IKDC score was used. Postoperatively extension respective flexion deficits were recorded (Table 2) as well as the single leg hop test (Table 3). Furthermore, a Visual Analogue Scale (VAS) was used to determine the postoperative pain.

	Open Group	Arthroscopic Group	p-Value
Age (years, range)	37 (18;62)	35 (18;59)	n.s.
Male/Female	32/30	25/24	
Right/Left	36/26	30/19	
Time from Injury to surgery (months, range)	4 (0,2;17)	3 (0,5; 12)	n.s.
Cartilagedamage n (%)	20 (32)	19 (39)	n.s.
Meniscuslesion n (%)	32 (52)	22 (45)	n.s.
Tegnerpre	5 (3;7)	5 (3;7)	n.s.
Tegner 6 weeks	3 (2;3)	3 (2;3)	
Tegner 3 months	3 (2;4)	3 (2;4)	
Tegner 6 months	4 (2;5)	4 (2;5)	

**Citation:** Sebastian Gottfried Walter, *et al.* "Does it have to be done Arthroscopically? Comparison between Open and Arthroscopic Anterior Cruciate Ligament Replacement Using a Bone-Tendon-Bone Autograft – A Prospective 5 Year Follow-Up Study". *EC Orthopaedics* 3.1 (2016): 233-242.

## Does it have to be done Arthroscopically? Comparison between Open and Arthroscopic Anterior Cruciate Ligament Replacement Using a Bone-Tendon-Bone Autograft – A Prospective 5 Year Follow-Up Study

Tegner 12 months	4 (3;7)	4 (3;7)	
Tegner 24 months	5 (4;7)	5 (3;8)	
Tegner 36 months	5 (3;7)	5 (3;7)	
Tegner 60 months	5 (3;7)	5 (3;7)	
Lysholmpre	47.7 (±7.3)	46.0 (±7.3)	n.s.
Lysholm 6 weeks	66.3 (±3.6)	63.6 (±4.8)	
Lysholm 3 months	73.0 (±4.1)	69.7 (±5.1)	
Lysholm 6 months	83.4 (±4.7)	84.2 (±6.2)	
Lysholm 12 months	88.7 (±4.3)	89.1 (±3.7)	
Lysholm 24 months	89.4 (±3.7)	87.4 (±5.4)	
Lysholm 36 months	89.0 (±4.1)	87.8 (±5.7)	
Lysholm 60 months	89.0 (±4.4)	86.9 (±6.5)	
IKDC pre	42.7 (±5.1)	44.7 (±7.0)	n.s.
IKDC 6 weeks	66.0 (±3.1)	64.9 (±4.5)	
IKDC 3months	73.8 (±3.1)	73.2 (±3.6)	
IKDC 6 months	82.6 (±3.9)	81.7 (±4.3)	
IKDC 12 months	87.1 (±3.6)	86.6 (±3.8)	
IKDC 24 months	89.2 (±3.9)	88.3 (±4.1)	
IKDC 36 months	89.8 (±3.8)	88.5 (±4.1)	
IKDC 60 months	89.9 (±4.0)	88.6 (± 4.2)	
KT-1000 pre	6.2 (±2.3)	6.6 (±2.8)	n.s.
KT-1000 12 months	1.2 (±0.2)	1.0 (±0.5)	
KT-1000 36 months	1.4 (±0.2)	1.5 (±0.5)	
KT-1000 60 months	1.4 (±0.1)	1.3 (± 0.7)	

**Table 1:** Demographic data of Open and Arthroscopic Group. Values for age, time to intervention and Tegner score are given as the median (range in parentheses). Values for IKDC, Lysholm and KT-1000 are presented as average with standard deviation. p-Values resulted from a two sided t-test for comparison with the intervention group. n.s.= non significant

Measurement accuracy was set at 0.1 mm, 0.1 point and 1°. For statistical analyses SPSS 22.0 (IBM Corporation, New York, USA) was used. Differences between the groups were compared using the independent two sample t test for continuous variables and the Chi-square test for categorical variables. All statistical assessments were two- sided and a p value of < 0.05 was considered as statistically significant. Based on pivot- shift measures a post-hoc power analysis was done. Defining the power as 0.80 and expecting positive pivot-shift rates in 36% [22] it was found that 49 patients would have been required in each group. This study was approved by the ethics committee. All procedures were approved by the institutional review board, and informed consent was obtained from all individual participants prior to inclusion into the study.

## Does it have to be done Arthroscopically? Comparison between Open and Arthroscopic Anterior Cruciate Ligament Replacement Using a Bone-Tendon-Bone Autograft – A Prospective 5 Year Follow-Up Study

	Preoperative		p-Value	12 months		p-Value	36 months		p-Value	60 months		p-Value
	Open Group	Arthr. Group		Open Group	Arthr. Group		Open Group	Arthr. Group		Open Group	Arthr. Group	
Lachmann n (%)			n.s.			n.s.			n.s.			n.s.
Lachmann 0	0 (0)	0 (0)		58 (94)	43 (88)		56 (90)	43 (88)		57 (92)	42 (86)	
Lachmann 1+	0 (0)	0 (0)		4 (6)	6 (12)		5 (8)	6 (12)		5 (8)	7 (14)	
Lachmann 2+	43 (69)	26 (53)	0.021	0 (0)	0 (0)		1 (2)	0 (0)		0 (0)	0 (0)	
Lachmann 3+	19 (31)	23 (47)	0.011	0 (0)	0 (0)		0 (0)	0 (0)		0 (0)	0 (0)	
Pivot-shift test n (%)			n.s.			n.s.			n.s.			n.s.
Pivot-shift test 0	0 (0)	0 (0)		57 (92)	44 (90)		55 (88)	43 (88)		55 (88)	43 (88)	
Pivot-shift test 1+	3 (5)	5 (10)		5 (8)	3 (6)		6 (9)	6 (12)		5 (8)	5 (10)	
Pivot-shift test 2+	49 (79)	32 (65)	0.044	0 (0)	2 (4)		2 (3)	0 (0)		2 (4)	1 (2)	
Pivot-shift test 3+	13 (21)	12 (25)		0 (0)	0 (0)		0 (0)	0 (0)		0 (0)	0 (0)	
Positive rate Pivot shift	100	100		8	10		12	12		12	12	
Extension deficit (°)				1.1 (±0.7)	1.3 (±0.8)	n.s.	1.3 (±0.6)	1.4 (±0.7)	n.s.	1.2 (±0.6)	1.4 (±0.7)	n.s.
Flexion deficit (°)				1.4 (±0.7)	1.2 (±0.6)	n.s.	1.3 (±0.6)	1.2 (±0.6)	n.s.	1.3 (±0.5)	1.2 (±0.6)	n.s.

**Table 2:** Presented is the development of Lachmann and Pivot-shift test over time for both groups. Also average values for extension and flexion deficits are shown.

	Open Group			Arthr. Group			p-Value
	Grade A	Grade B	Grade C	Grade A	Grade B	Grade C	
Single leg hop test n (%)							n.s.
6 months	51 (82)	7 (12)	4 (6)	37 (76)	5 (10)	7 (14)	
12 months	59 (95)	3 (5)	0 (0)	43 (88)	5 (10)	1 (2)	
24 months	58 (94)	4 (6)	0 (0)	44 (90)	5 (10)	0 (0)	
36 months	59 (97)	2 (3)	0 (0)	45 (92)	4 (8)	0 (0)	
60 months	59 (97)	2 (3)	0 (0)	46 (94)	3 (6)	0 (0)	

**Table 3:** Shown are the results of the single leg hop test for Open and Arthroscopic Surgery. Three possible levels are indicated: Grade A: > 90 % of the distance jumped on the contralateral (uninvolved) limb; Grade B: 75-90% and Grade C: < 75%.

Postoperative Pain	1 <sup>st</sup> day	3 months	6 months
Open Group	3.7 ± 1.7	2.1 ± 1.4	1.4 ± 1.1
Arthroscopic Group	3.0 ± 2.0	1.3 ± 1.0	1.6 ± 1.5
p- Value	n.s.	0.015	n.s.

**Table 4:** Postoperative Pain Scores on a VAS scale from 0-10. Pain scores were evaluated on the first post-operative day as well as 3 months and 6 months after the intervention. After 3 months pain scores are significantly higher for the "open group".

### Surgical approach

The patients underwent either general inhalational or spinal block anaesthesia and were then brought into a supine position thus allowing the knee to be moved passively over the whole Range of Motion (ROM). The ACL deprived knee joint is primarily examined arthroscopically to detect -and if necessary treat- concomitant injuries such as Meniscus lesions or cartilage defects [23]. While meniscal

**Citation:** Sebastian Gottfried Walter, *et al.* "Does it have to be done Arthroscopically? Comparison between Open and Arthroscopic Anterior Cruciate Ligament Replacement Using a Bone-Tendon-Bone Autograft – A Prospective 5 Year Follow-Up Study". *EC Orthopaedics* 3.1 (2016): 233-242.

## Does it have to be done Arthroscopically? Comparison between Open and Arthroscopic Anterior Cruciate Ligament Replacement Using a Bone-Tendon-Bone Autograft – A Prospective 5 Year Follow-Up Study

lesions were treated with partial meniscectomy, cartilage defects were treated either with abrasion or matrix-induced autologous chondrocyte implantation (MACI). However, this was done only if there were radiologic or clinical signs suspicious for such damages.

A midline incision of the skin reaching from the center of the patella to the tibial tubercle was made thus presenting the patellar ligament beneath [17] Before resecting the BTB graft, one hole (0.8 mm) is drilled into each osseous part to be harvested. Thereafter the graft is harvested having a diameter of 8-10 mm, consisting of a 20-25 mm long osseous block of the distal patella, the patellar ligament and a 20 mm long block of the tibial tubercle. While the later is a mobilized using chisel the patellar part of the graft is sawed with a bone cutter. Before removing the BPTB-graft, it is attached proximally and distally to a guiding thread. It is then completely dissected and shaped by an assisting surgeon. Meanwhile the surgeon mobilizes the Hoffa fat body ventrally, leaving it attached as much as possible. An insertion guide is placed onto the tibial footprint of the ACL, and then the correct angle of the jig under simulation of the full ROM is determined assuring that there is no impingement. Eventually this position is fixed by inserting a K wire through the appropriately inclined tibia into the femur. According to the diameter of the BPTB-graft, the insertion tunnel is drilled using the K wire as guide. On the femur the tunnel depth is limited to 20-25 mm in order to guarantee an optimal fit of the graft. At this point, another insertion guide (DePuyMitek Inc., Raynham, MA, USA) is adjusted in order to prepare the insertion channels for the Rigidfix® Pins (DePuyMitek Inc., Raynham, MA, USA) in the femur. The BPTB-graft is now inserted from distal and pulled into its final position. ROM is now tested for the second time. The femoral part of the BPTB-graft is then mounted by placing parallelly two 2.7 mm RIGIDfix® Crosspins from lateral into the osseous part using a femoral insertion guide. To fix the tibial part of the graft an ABSOLUTE® interference screw (DePuy Mitek Inc., Raynham, MA, USA) is inserted from distal. The joint is now again controlled for a complete ROM. The Hoffa fat body is then restored in its original position. The wound is closed in layers starting with the split patellar ligament followed by the closure of the skin. The other two entry spots for placing the BPTB-graft are closed with single stitch sutures. Finally, sutures and joint are covered by sterile wound dressing. The arthroscopic control group was treated with the same technique. However, after harvesting the BPTB autograft, the patellar tendon was closed and all further steps made arthroscopically. [24]

### Postoperative treatment

After the operation, the knee joint is mobilized on a continuous passive motion machine and is provided a cryocuff. A knee joint brace with limited flexion of 60° is applied for 4 weeks. Sutures are removed after 10 days. After 4 weeks the patients are encouraged to gain a full active range of motion primarily which is accompanied by a physiotherapeutic progression to strengthening program by focusing on isometric quadriceps reinforcement. Stationary bike, proprioception exercises are important parts of this concept that are expanded to jogging, swimming in straight line and bicycling after 3 months. After 6 months pivot sports such as ski, tennis and squash are allowed if the criteria of full range of motion, no effusion, normal muscle strength and knee stability are met. Contact sports are supposed to be omitted until the eighth month.

### Results

In the time between 04/2008 and 05 /2010, we operated 74 subjects using the described open approach. Of these 65 were included into the study and 62 of those were included in the final analysis, with 30 of them being female and 32 male. 1 subject was lost to follow-up as he moved out of country. We operated 36 right and 26 left knee joints. The median age of the patients at the time of operation was 37(18;62) years. Subjects were operated in the median after 4 (0.2;17) months after the initial event. The mean duration of this type of surgery was 43 min (37-65 min).

As a control we used data of 49 patients that were treated arthroscopically (Table 1). In this group 7 subjects were lost to follow-up as 3 of them moved out of country, 1 died, 1 was subject to imprisonment and 2 declined to participate on further regular visitations. Demographic data of this group did not show statistical significant differences compared to the “open group” as the median age was 35 (18; 59). In this group 25 male and 24 female subjects were treated, 30 on the right and 19 on the left side. With a mean of 69 min (55-78 min) the arthroscopic procedure took longer than the open technique. In all cases, rehabilitation went without infections. 2 subjects of the “open group” (3%) and 5 of the arthroscopic group (10%) needed a revision. In each, the “open group” as well in as in the

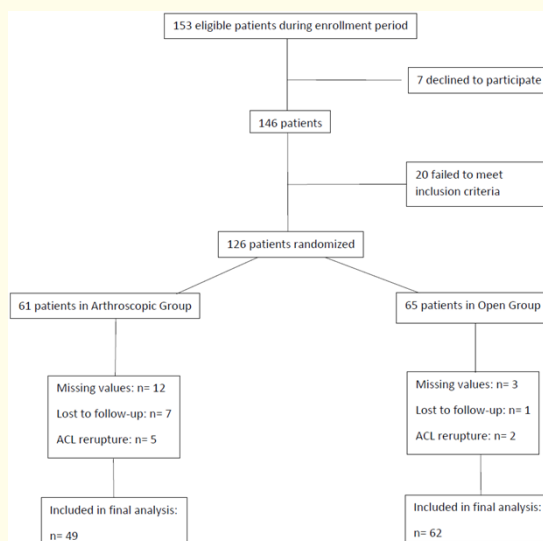
**Citation:** Sebastian Gottfried Walter, *et al.* “Does it have to be done Arthroscopically? Comparison between Open and Arthroscopic Anterior Cruciate Ligament Replacement Using a Bone-Tendon-Bone Autograft – A Prospective 5 Year Follow-Up Study”. *EC Orthopaedics* 3.1 (2016): 233-242.

## Does it have to be done Arthroscopically? Comparison between Open and Arthroscopic Anterior Cruciate Ligament Replacement Using a Bone-Tendon-Bone Autograft – A Prospective 5 Year Follow-Up Study

arthroscopic group there was one case of patella fracture in the early postoperative phase detected. The other case to be revised in the “open group” (11 months) and another three cases in the arthroscopic group (after 6, 10 and 16 months) had to undergo revision due to traumatic damages of the ACL caused by sportive activities. In one arthroscopically treated case, the BTB graft loosened after 6 weeks as the interference screw was not placed appropriately.

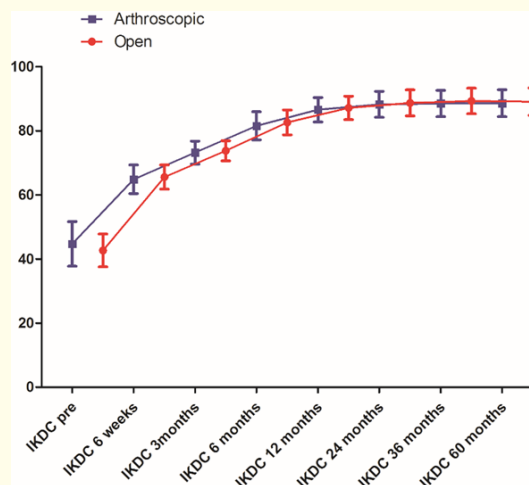
The preoperative Tegner Score Value described the status before the event that lead to the ACL rupture. After 12 months, patients became an MRI for radiologic proof of intactness of the ACL. There we found no evidence for a secondary loosening or anew lesion. The development of the Lysholm score and the IKDC score values are shown in Table 1. Subjects treated with the open technique stated a median Tegner score of 5 (3;7) before tearing their ACL. 6 weeks after surgery it was 3 (2;3), slightly improving its range to 2-4 after 3 months. After 6 months Tegner score was found at 4 (2;7);  $p = 0.04$  and after 12 months at 5 (3; 8);  $p = 0.025$ . This level was maintained also after 24 months (3;8), 36 months (3;7) and after 60 months (3; 7). The anteroposterior tibial translation was measured with the KT-1000 arthrometer by exerting 135 N. The preoperative anteroposterior tibial translation was  $6.2 (\pm 2.3)$ , which significantly decreased after 12 months to  $1.2 (\pm 0.2)$ ,  $p = 0.017$  and to eventually increased slightly to  $1.4 (\pm 0.1)$  after 36 months. Similar results were found in the arthroscopically treated group, too. There the mean preoperative anteroposterior tibial translation was  $6.6 (\pm 2.8)$  and  $1.0 (\pm 0.5)$  after 12 months. After 36 months the tibial translation was  $1.5 (\pm 0.3)$ .

Furthermore subjects were clinically evaluated using the Pivot-shift test and Lachmann test with between group differences but tremendous improvements in the postoperative phase (Table 2). In all operated knees, postoperative extension deficits remained under  $5^\circ$  and flexion deficits under  $10^\circ$ , thus achieving a normal ROM. The results of the single leg hop test did not show any significant difference, too. (Table 3)



**Figure 1:** Participant flowchart. One patient in the Open Group and seven patients in the Arthroscopic Group were lost to follow-up. Among these patients, four (Arthroscopic group) relocated and lost contact. In another 4 cases patients were satisfied with their outcomes and declined to continue to participate in follow-up. Seven patients experienced re-ruptures. Five of these were caused by injury during sports. One injury (Arthroscopic Group) occurred 50 months after reconstruction and the other one (Open Group) happened 4 months after the intervention.





**Figure 2:** Development of the IKDC-Score values in the open as well as in the intervention group plotted over time. Lines joining the boxes represent the mean values for each group. The boxes represent the data distribution between 25 % and 75 % of the sample; whiskers represent between 5 % and 95 % of the sample. For illustration purposes the data for the “open” group were slightly shifted to the right.

### Discussion

After harvesting the BPTB-autograft the only anatomical structure hindering the surgeon from gaining a direct access to the damaged ACL is the Hoffa Body. Thus, a mobilization of that structure seems to be a logic consequence. This principle provides the sight and space necessary to place the ACL functionally and anatomically correctly. The exact placement of the BTB-transplant is essential for satisfying functional outcomes and long term biomechanical stability. [25] Although arthroscopic methods can deliver just as good results in terms of Graft-Placement, the process may be exhausting due to an awkward handling of arthroscopic devices and imprecise judgment of the ACL movement during ROM control. Soft tissues -apart from the Hoffa body- are not more manipulated than in arthroscopic procedures.

Although this is discussed controversially [26-28], we commend a refilling of the osseous defects on patella and tibia with cancellous bone and the use of Mitek® pins for the femoral fixation. Yet, a further development of this technique might consider the possibility of inserting the BTB-graft through the “joint window” respective trans-ligamentary approach instead of pulling it through the working tunnel, that way creating an “all-inside” solution. We made the experience that especially physical active patients profited from the intervention as they returned to demanding sportive activities no later than one year after the intervention in a manner as they used to exercise this activity previously to the trauma. When comparing the non-arthroscopic group with the arthroscopic control group one will note outcomes that are largely congruent. In terms of functional long-term results there seems to be no difference (Table 1).

Interestingly almost 18 years ago Gerich., *et al.* [21] concluded both arthroscopic and open procedure to have similar clinical outcomes although they used different methods and other operation techniques. Sadoghi., *et al.* [29] compared the Bone-Tendon-Bone autografts with doubled hamstrings and found similar functional results for the BPTB group as presented in this study, also they used cross pin fixation for the femoral part and an interference screw on the tibia. However, follow-up was 2 years only. Harilainen., *et al.* [30] stated slightly better results for the Lysholm score after 5 years (95%), but a greater laxity in terms of anteroposterior tibial translation ( $1.5 \pm 3.0$ ). Although the subject number was similar, fixation technique differed by using an interference screw for the femoral part as well. Another study done by Zaffagnini., *et al.* [22] showed somewhat lower results for the mean IKDC (82%) after 5 years. In contrast

**Citation:** Sebastian Gottfried Walter, *et al.* “Does it have to be done Arthroscopically? Comparison between Open and Arthroscopic Anterior Cruciate Ligament Replacement Using a Bone-Tendon-Bone Autograft – A Prospective 5 Year Follow-Up Study”. *EC Orthopaedics* 3.1 (2016): 233-242.

to our study the preoperative median Tegner score was higher -which could be explained by less heterogeneity of the presented cohort. With regard to larger systematic review data of arthroscopic techniques the functional long term results of the open technique presented in this study seem to be comparable and similar with those of arthroscopic methods for the BTB replacement. [31] However this needs to be backed up by further research. Duffee, *et al.* [32] found a relatively high proportion of revisions necessary when drilling the femoral tunnel transtibially. This was explained by the diverse angle of the graft inside the femoral tunnel in relation to its orientation inside the joint and an increased likelihood of an impingement. In contrast other data suggest that this is cannot be the only argument as similar clinical outcomes were found when comparing the anteromedial transportal and modified transtibial technique. [33]

A lower rate of revision in this study could be caused by the intraoperative ROM testing for graft impingement previously to the drilling. As in the “open group” the mean intervention time was shorter and the fact that cost-intensive arthroscopic operation devices were not necessarily required a study investigating whether the open method is more cost efficient compared to arthroscopic methods would be an attractive field for near future research.

Shortcomings of this study are the smaller number of subjects of the arthroscopically treated control group. Although the same post-operative rehabilitation protocol was prescribed to all patients, the quality and consistency of rehabilitation may have varied without strict supervision. Incomplete follow-up radiographic material may limit the ability of this study to draw important conclusions. There were no significant differences observed in the preoperative parameters but difficult to control clinical and individual factors may have had an important impact. Yet the number of patients included in the open-technique-group may be sufficient for this study but needs to be enlarged in further studies to increase validity. Strength of this study is the presentation of recently open/ non-arthroscopically treated subjects with a meaningful follow-up time of 5 years.

### Conclusion

Although this technique seems to be widely buried in oblivion and unfashionable in an arthroscopic dominated scientific discourse, it has demonstrated satisfying clinical results that bear a comparison with arthroscopic techniques and therefore a consideration as one solid alternative to other established techniques is recommended.

### Bibliography

1. Griffin LY, *et al.* “Understanding and preventing noncontact anterior cruciate ligament injuries: a review of the Hunt Valley II meeting, January 2005”. *The American journal of sports medicine* 34.9 (2006): 1512-1532.
2. Guglielmetti L, *et al.* “Anterior cruciate ligament reconstruction: a new cortical suspension device for femoral fixation with transtibial and transportal techniques”. *Journal of orthopaedic surgery and research* 9 (2014) 110.
3. Jones KG. “Reconstruction of the Anterior Cruciate Ligament. A Technique Using the Central One-Third of the Patellar Ligament”. *The Journal of bone and joint surgery. American volume* 45 (1963): 925-932.
4. Kartus J, *et al.* “Donor-site morbidity and anterior knee problems after anterior cruciate ligament reconstruction using autografts”. *Arthroscopy : the journal of arthroscopic & related surgery : official publication of the Arthroscopy Association of North America and the International Arthroscopy Association* 17.9 (2001): 971-980.
5. Lee RJ and Ganley TJ. “The 5-strand hamstring graft in anterior cruciate ligament reconstruction”. *Arthroscopy techniques* 3.5 (2014): e627-e631.
6. Sarzaeem MM, *et al.* “ACL reconstruction using bone-patella tendon-bone autograft: press-fit technique vs. interference screw fixation”. *Archives of orthopaedic and trauma surgery* 134.7 (2014): 955-962.
7. Hirzinger C, *et al.* “ACL injuries and stem cell therapy”. *Archives of orthopaedic and trauma surgery* 134.11 (2014): 1573-1578.
8. Mahalingam VD, *et al.* “Fresh Versus Frozen Engineered Bone-Ligament-Bone Grafts for Sheep Anterior Cruciate Ligament Repair”. *Tissue engineering. Part C, Methods* 21.6 (2014): 548-556.

---

**Citation:** Sebastian Gottfried Walter, *et al.* “Does it have to be done Arthroscopically? Comparison between Open and Arthroscopic Anterior Cruciate Ligament Replacement Using a Bone-Tendon-Bone Autograft – A Prospective 5 Year Follow-Up Study”. *EC Orthopaedics* 3.1 (2016): 233-242.



9. Proffen BL., et al. "Bio-Enhanced Repair of the Anterior Cruciate Ligament". *Arthroscopy : the journal of arthroscopic & related surgery : official publication of the Arthroscopy Association of North America and the International Arthroscopy Association* 31.5 (2015):990-997.
10. Lenschow S., et al. "Comparison of outside-in and inside-out technique for tibial fixation of a soft-tissue graft in ACL reconstruction using the Shim technique". *Archives of orthopaedic and trauma surgery* 134.9 (2014): 1293-1299.
11. Dawson AG., et al. "Is Anterior Cruciate Reconstruction Superior to Conservative Treatment?" *The journal of knee surgery* 29.1 (2014): 74-79.
12. Shelbourne KD., et al. "Anterior Cruciate Ligament Reconstruction With Contralateral Autogenous Patellar Tendon Graft: Evaluation of Donor Site Strength and Subjective Results". *The American journal of sports medicine* 43.3 (2014):648-653.
13. Xie X., et al. "A meta-analysis of bone-patellar tendon-bone autograft versus four-strand hamstring tendon autograft for anterior cruciate ligament reconstruction". *The Knee* 22.2 (2014):100-110.
14. Sohn OJ., et al. "Comparison of the Modified Transtibial Technique, Anteromedial Portal Technique and Outside-in Technique in ACL Reconstruction". *Knee surgery & related research* 26.4 (2014): 241-248.
15. Slone HS., et al. "Quadriceps Tendon Autograft for Anterior Cruciate Ligament Reconstruction: A Comprehensive Review of Current Literature and Systematic Review of Clinical Results". *Arthroscopy : the journal of arthroscopic & related surgery : official publication of the Arthroscopy Association of North America and the International Arthroscopy Association* 31.3 (2014): 541-554.
16. Andernord D., et al. "Patient Predictors of Early Revision Surgery After Anterior Cruciate Ligament Reconstruction: A Cohort Study of 16,930 Patients With 2-Year Follow-up". *The American journal of sports medicine* 43.1 (2015): 121-127.
17. Kartus J., et al. "Comparison of traditional and subcutaneous patellar tendon harvest. A prospective study of donor site-related problems after anterior cruciate ligament reconstruction using different graft harvesting techniques". *The American journal of sports medicine* 28.3 (2000): 328-335.
18. Group M. "Effect of graft choice on the outcome of revision anterior cruciate ligament reconstruction in the Multicenter ACL Revision Study (MARS) Cohort". *The American journal of sports medicine* 42.10 (2014): 2301-2310.
19. Fergusson CM. "Anterior cruciate ligament reconstruction: middle-third bone/patella tendon/bone autograft". *Journal of the Royal College of Surgeons of Edinburgh* 86.10 (2000): 2143 -2155.
20. Gerich TG., et al. "[Endoscopic versus limited open technique for replacement of the anterior cruciate ligament. 4 years outcome of a prospective study]". *Unfallchirurg* 101.7 (1998): 551-556.
21. Gerich TG., et al. "One- versus two-incision technique for anterior cruciate ligament reconstruction with patellar tendon graft. Results on early rehabilitation and stability". *Knee surgery, sports traumatology, arthroscopy : official journal of the ESSKA* 5.4 (1997): 213-216.
22. Zaffagnini S., et al. "Prospective and randomized evaluation of ACL reconstruction with three techniques: a clinical and radiographic evaluation at 5 years follow-up". *Knee surgery, sports traumatology, arthroscopy : official journal of the ESSKA* 14.11 (2006): 1060-1069.
23. Cox CL., et al. "Are articular cartilage lesions and meniscus tears predictive of IKDC, KOOS, and Marx activity level outcomes after anterior cruciate ligament reconstruction? A 6-year multicenter cohort study". *The American journal of sports medicine* 42.5 (2014): 1058-1067.
24. Guo L., et al. "Anterior cruciate ligament reconstruction with bone-patellar tendon-bone graft: comparison of autograft, fresh-frozen allograft, and gamma-irradiated allograft". *Arthroscopy : the journal of arthroscopic & related surgery : official publication of the Arthroscopy Association of North America and the International Arthroscopy Association* 28.2 (2012): 211-217.
25. Biggs A., et al. "Rehabilitation for Patients Following ACL Reconstruction: A Knee Symmetry Model". *North American journal of sports physical therapy : NAJSPT* 4.1 (2009): 2-12.
26. DuMontier TA., et al. "Patella fracture after anterior cruciate ligament reconstruction with the patellar tendon: a comparison between different shaped bone block excisions". *The american journal of knee surgery* 14.1 (2001): 9-15.

**Citation:** Sebastian Gottfried Walter, et al. "Does it have to be done Arthroscopically? Comparison between Open and Arthroscopic Anterior Cruciate Ligament Replacement Using a Bone-Tendon-Bone Autograft – A Prospective 5 Year Follow-Up Study". *EC Orthopaedics* 3.1 (2016): 233-242.

27. Frank RM., *et al.* "Closure of patellar tendon defect in anterior cruciate ligament reconstruction with bone-patellar tendon-bone autograft: systematic review of randomized controlled trials". *Arthroscopy : the journal of arthroscopic & related surgery : official publication of the Arthroscopy Association of North America and the International Arthroscopy Association* 31.2 (2015): 329-338.
28. Jones KJ., *et al.* "Quantitative assessment of patellar vascularity following bone-patellar tendon-bone autograft harvest for ACL reconstruction". *Knee surgery, sports traumatology, arthroscopy : official journal of the ESSKA* 2015.
29. Sadoghi P., *et al.* "Reconstruction of the anterior cruciate ligament: a clinical comparison of bone-patellar tendon-bone single bundle versus semitendinosus and gracilis double bundle technique". *International orthopaedics* 35.1 (2011): 127-133.
30. Harilainen A., *et al.* "Randomized prospective study of ACL reconstruction with interference screw fixation in patellar tendon autografts versus femoral metal plate suspension and tibial post fixation in hamstring tendon autografts: 5-year clinical and radiological follow-up results". *Knee surgery, sports traumatology, arthroscopy : official journal of the ESSKA* 14.6 (2006): 517-528.
31. Xie X., *et al.* "A meta-analysis of bone-patellar tendon-bone autograft versus four-strand hamstring tendon autograft for anterior cruciate ligament reconstruction". *The Knee* 22.2 (2015): 100-110.
32. Duffee A., *et al.* "Transtibial ACL femoral tunnel preparation increases odds of repeat ipsilateral knee surgery". *The Journal of bone and joint surgery. American volume* 95.22 (2013): 2035-2042.
33. Lee JK., *et al.* "Anatomic single-bundle ACL reconstruction is possible with use of the modified transtibial technique: a comparison with the anteromedial transportal technique". *The Journal of bone and joint surgery. American volume* 96.8 (2014): 664-672.

**Volume 3 Issue 1 February 2016**

**© All rights are reserved by Sebastian Gottfried Walter., *et al.***