

## Bilateral Patella Tendon Ruptures Associated With Anabolic Steroid Abuse

Davies J<sup>1\*</sup> M Qulaghassi<sup>1</sup>, Studnicka K<sup>2</sup> and Kanvinde R<sup>2</sup>

<sup>1</sup>Department of Orthopaedics, Princess of Wales Hospital, Abertawe Bro Morgannwg University Health Board, United Kingdom

<sup>2</sup>Department of Orthopaedics, Betsi Cadwaladr University Health Board, United Kingdom

**\*Corresponding Author:** John F Davies, Orthopaedic Registrar, Princess of Wales Hospital Abertawe Bro Morgannwg University Health Board, Coity Rd, Bridgend, CF31 1RQ, United Kingdom.

**Received:** July 17, 2015; **Published:** July 25, 2015

### Abstract

Bilateral patella tendon ruptures are rare and typically seen in patients with systemic disease or long term corticosteroid therapy. There are no previous documented cases of bilateral patella tendon ruptures in association with anabolic steroid abuse. Bilateral quadriceps ruptures associated with anabolic steroids have been previously reported in two cases. A patient with bilateral, simultaneous mid-substance patella tendon ruptures who had been using anabolic steroids during a training regime for a competitive weight lifting event is presented with a discussion of the literature.

**Case Presentation:** A 31 year old previously fit and healthy male, presented after simultaneous bilateral loss of knee extension whilst training for a strong man competition. He described the sensation of his knees suddenly giving way during a training activity involving sprinting with alternating rapid acceleration and deceleration, carrying a 200 kg dead weight on his back. The patient had been using androgenic testosterone related anabolic steroids in a stacked regime. Clinical examination demonstrated a palpable gap with loss of active extension in both knees. Bilateral patella alta was shown on xray according to Insall-Salvati index, and ultrasound scan confirmed mid-substance tears of both patella tendons. The patient underwent a successful repair of both tendons and subsequent rehabilitation.

**Conclusion:** Bilateral simultaneous patella tendon rupture in association with anabolic steroids is hitherto unrecognized: only bilateral quadriceps ruptures have previously been documented before in the literature. Clinicians should have awareness of this potential complication in patients using anabolic steroids. In this case, surgical treatment of bilateral knee extensor mechanism injuries was successful and the patient was able to return to training activities.

**Keywords:** Patella tendon; anabolic steroid; Knee

### Introduction

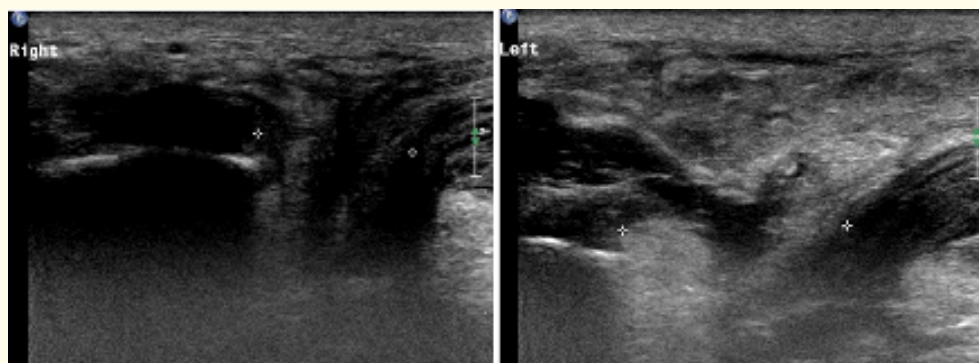
Bilateral patella tendon ruptures associated with systemic disease and known cases of anabolic steroid associated bilateral quadriceps rupture are documented in the literature, however bilateral patella tendon ruptures in association with anabolic steroid abuse has not been previously described. The case of a patient with bilateral simultaneous mid-substance patella tendon rupture who had been using anabolic steroids during their training regime for a competitive weight lifting event is presented with a discussion of the literature.

### Case Presentation

A 31 year old previously fit and healthy male presented after a simultaneous bilateral loss of knee extension whilst training for a strong man competition. He described the sensation of his knees suddenly giving way during a training activity involving sprinting with alternating phases of rapid acceleration and deceleration carrying a 200 kg dead weight on his back. He initially landed on one bent knee

and was then unable to rise from this kneeling position. On initial assessment in the emergency department, clinical examination demonstrated a mild effusion and palpable gap in the mid substance of both patellar tendons. The patient displayed loss of active knee extension bilaterally whilst maintaining passive extension and active knee flexion. Initial radiographs demonstrated the appearance of bilateral patella alta according to Insall-Salvati ratio [1] and no evidence of bony injury. Prior to injury, the patient had used a stacked regime of several anabolic steroids, starting initially with trenbolone hexahydro benzylcarbonate and stanozolol for 8 weeks followed by human chorionic gonadotrophin (HCG) for 3 weeks. Following this he used sustanon 250, an injectable blend of four esterized testosterone, and nandrolonedecanoate for 12 weeks, tamoxifen for 20 weeks, and boldenone for 12 weeks and then testosterone enanthate for 24 weeks and HCG for a further 3 weeks.

Ultrasound scan confirmed an acute full thickness mid substance patellar tendon rupture bilaterally (Figure 1) and the patient underwent surgical repair the following day. The intra-operative appearance, in both knees, was of haematoma with frayed and completely severed ends of both tendons in the middle third. A repair was performed in a Krackow fashion, with 5.0 ethibond suture (Johnson and Johnson, New Jersey). On table, 90 degrees of flexion was achieved in both knees and, as a secure repair was achieved with no gap between the tendon ends, a transosseuscerclage wire augmentation was not used. Both knees were immobilized in hinged braces with flexion limited to 45 degrees and the patient allowed to fully weight bear with crutches. The patient underwent subsequent rehabilitation with physiotherapists and was able to regain strength training and had a full range of motion by 3 months.



**Figure 1:** Ultrasound images of right and left patella tendons demonstrating bilateral mid-substance tears.

### Discussion

Anabolic steroid associated tendon rupture in both upper and lower extremities is well recognized [2-9], the bilateral patella tendon ruptures was never been seen in association with steroids. In terms of the extensor mechanism of the knee, bilateral quadriceps rupture associated with anabolic steroid abuse in competitive body builders has been identified previously in two case reports [10-12]. In one, a professional body builder sustained ruptures when he attempted to squat lift a weight of 181.5 kg [11]. In the other, a competitive body builder jumped from a height of 15 feet onto flexed knees causing the ruptures to occur [10]. During surgery in both of these patients, the site of rupture was found to be at the enthesis, with extension into the extensor retinaculum. Interestingly, a case of spontaneous anterior cruciate ligament rupture has been described after an apparently trivial injury in a bodybuilder taking anabolic steroids, which was managed conservatively after initial arthroscopy [12].

Several theories exist as to the exact mechanism of failure in anabolic steroid associated tendon rupture. One proposed mechanism is that a mismatch occurs due to increased muscle mass and muscle strength in individuals, without corresponding increase in the strength of the tendon, predisposing to mechanical overload and failure [12]. As the biceps, triceps and quadriceps tendons are often ruptured in body builders, this theory may explain why this occurs: as they are attached to multipennate muscles generating high forces. A further

contributory factor may be due to alteration in the collagen fibrils that causes tendon failure: due to the effects of exercise, anabolic steroids or both acting together in combination. This alteration is postulated as being either in the mechanical properties of the collagen under loading conditions [13-14], or the presence of dysplastic changes in the tendon ultrastructure [15]. Biomechanical studies on rat tendons have demonstrated that anabolic steroid administration caused a stiffer tendon, which failed with less elongation under load [13-14]. Overall, the ultimate tensile strength of the tendon was not affected but exercise and anabolic steroids in combination caused an increased diameter of the collagen fibrils [13]. Previously, dysplasia had been postulated to occur from the appearance of frayed irregular collagen fibrils identified on electron microscopy in mice subjected to exercise and anabolic steroids [15]. These findings have since been disproved by other studies, including an explant study of ruptured biceps tendons in humans biopsied at the time of surgery, which demonstrated no difference in the tendon ultrastructure between controls and the study group of patients using anabolic steroids [9]. Both groups displayed similar areas of dysplastic frayed collagen, demonstrating that anabolic steroid usage is not solely responsible for dysplastic ultra structural changes in tendons.

Bilateral patella tendon rupture occurs rarely, and are most often seen in association with tendinitis or conditions that predispose to tendon rupture: renal failure, dialysis and uraemia; secondary hyperparathyroidism; rheumatoid arthritis; systemic lupus erythematosus; chronic acidosis and administration of corticosteroids [2,16-18]. The main mechanism for unilateral patella tendon rupture is overloading of the extensor mechanism typically during athletic activity [16-18]. This is typically by flexing the knee combined with a rapidly applied high tensile stress from quadriceps contraction [19]. Simultaneous bilateral ruptures are rare and associated with systemic disease, repetitive microtrauma or corticosteroid administration [17-18,20]. Davidsson's theory of repetitive microtrauma leading to rupture proposes the cause of tendon failure and rupture is as a result of prior multiple recurrent micro tears within the tendon substance [20]. In this case, this patient had been competitively training for a strong man competition which would have involved repetitive submaximal loading of his patella tendons and consequently subclinical repetitive microtrauma may have occurred prior to rupture.

### Conclusion

The mechanism of tendon failure in this case may have been multi-factorial due to the prolonged and large amounts of anabolic steroids used by this individual, in combination with mechanical overload that occurred during his intense training regime. Bilateral simultaneous patella tendon ruptures in association with anabolic steroid abuse is hitherto unrecognized, previously only bilateral quadriceps ruptures having been documented before. Clinicians dealing with patients who use anabolic steroids for competitive training should have an awareness that bilateral patella tendon ruptures can occur, during assessment for a knee extensor mechanism injury. Early primary patella tendon repair using Krackow technique lead to a successful outcome.

### Conflict of Interest

No financial interest or any conflict of interest exists.

### Bibliography

1. Carson WG Jr, et al. "Patellofemoral disorders: physical and radiographic evaluation. Part II: Radiographic examination". *Clinical Orthopaedics* 185 (1984): 178-186.
2. Rose PS and Frassica FJ. "A traumatic bilateral patella tendon rupture: A case report and review of the literature". *Journal of Bone and Joint Surgery* 83-A.9 (2001): 1382-1386.
3. Kramhoft M and Solgard S. "Spontaneous rupture of the extensor pollicislongus tendon after anabolic steroids". *Journal of Hand Surgery* 11B.1 (1986): 87.
4. Bach BR, et al. "Triceps rupture: a case report and literature review". *The American Journal of Sports Medicine* 15 (1987): 285-289.
5. Herrick RT and Herrick S. "Ruptured triceps in a power lifter presenting as a cubital tunnel syndrome: a case report". *The American Journal of Sports Medicine* 15.5 (1987): 514-516.

6. Hill JA, *et al.* "The athletic polydrug abuse phenomenon A case report". *The American Journal of Sports Medicine* 11.4 (1983): 269-271.
7. Stannard JP and Bucknall AL. "Rupture of the triceps tendon associated with steroid injections". *The American Journal of Sports Medicine* 21.3 (1993): 482-485.
8. Visuri T and Lindholm H. "Bilateral distal biceps tendon avulsions with the use of anabolic steroids". *Medicine & Science in Sports & Exercise* 26.8 (1994): 941-944.
9. Evans NA, *et al.* "Ultra structural analysis of ruptured tendon from anabolic steroid users". *Injury* 29.10 (1998): 769-773.
10. Liow RY and Tavares S. "Bilateral rupture of the quadriceps tendon associated with anabolic steroids". *British Journal of Sports Medicine* 29.4 (1995): 77-79.
11. David HG, *et al.* "Simultaneous bilateral rupture quadriceps rupture: a complication of anabolic steroid abuse". *The Bone & Joint Journal* 77.1 (1995): 159-160.
12. Freeman BJC and Rooker GD. "Spontaneous rupture of the anterior cruciate ligament after anabolic steroids". *British Journal of Sports Medicine* 29.4 (1995): 274-275.
13. Miles JW, *et al.* "The effects of anabolic steroids on the biomechanical and histological properties of rat tendon". *Journal of Bone and Joint Surgery* 74.3 (1994): 411-422.
14. Inhofe PD, *et al.* "The effects of anabolic steroids on rat tendon: an ultra structural, biomechanical and biochemical analysis". *The American Journal of Sports Medicine* 23.2 (1995): 227-232.
15. Mischa H. "Tendon injuries induced by exercise and anabolic steroids in experimental mice". *International Orthopaedics* 11.2 (1987): 157-162.
16. Cree C, *et al.* "Bilateral patella tendon ruptures: a missed diagnosis". *Knee Surgery, Sports Traumatology, and Arthroscopy* 15.11 (2007): 1350-1354.
17. Taylor B, *et al.* "Bilateral patella tendon rupture at different sites without predisposing systemic disease or steroid use". *Iowa Orthopaedic Journal* 29 (2009): 100-104.
18. Kellersman R, *et al.* "Bilateral tendon rupture without predisposing systemic disease or steroid use: a case report and review of the literature". *Archives of Orthopaedic and Trauma Surgery* 125.2 (2005): 127-133.
19. Maffuli N and Wong J. "Ruptures of the Achilles and Patella tendons". *Clinics in Sports Medicine* 22.4 (2003): 761-776.
20. Splain SH and Ferencz C. "Bilateral simultaneous infrapatellar tendon rupture: support for Davidsson's theory". *Orthopaedic Review* 17 (1988): 802-805.

### Volume 2 Issue 1 July 2015

© All rights are reserved by John F Davies, *et al.*