

Non Surgical Repair of Tendon, Cartilage & Neurogenic Conditions - A Paradigm Shift in Musculoskeletal Medicine and Pain Management by Percutaneous Regenerative Intervention

Arockia Doss*

Radiologist, Image Guided Therapy Clinic, Nedlands, Western Australia

***Corresponding Author:** Arockia Doss, Radiologist, Image Guided Therapy Clinic, Nedlands, Western Australia.

Received: October 14, 2015; **Published:** October 29, 2015

Abstract

Painful conditions of tendons, cartilage, and nerves can be debilitating. Until recently, repeated corticosteroid injections or surgery were the only treatment options that were considered. Degeneration of the underlying tissue is the hallmark lesion in most of these cases. Image guided percutaneous treatment with autologous orthobiologicals derived from blood and mesenchymal stem cells towards regeneration and stabilisation of degenerating tissues is a new paradigm shift in the management of these conditions. Regenerative treatment is aimed at resolving the underlying pathology by reducing inflammation, creating an optimal chemical milieu that allows relief from painful tendons, cartilage and nerves. This article describes the most common conditions that may be treated by this new approach.

Keywords: *Degeneration; tendon tear; cartilage; Labral tear; Meniscal tear; Tendinosis; Tendinopathy; PRP; stem cells; ultrasound; image guided; osteoarthritis; intervertebral disc; annular tear; reflex sympathetic dystrophy; complex regional pain syndrome; neuralgia; neuropathic pain*

A number of painful chronic tendon, cartilage and neural conditions are treated with manual therapy, long term oral and or topical non steroidal anti-inflammatories (NSAIDs), opiates, corticosteroid injections and surgery. NSAIDs and opiates are not ideal long term options due to end organ damage and addiction respectively. A landmark meta-analysis on the use of corticosteroid injections in chronic painful tendinopathy suggested that corticosteroid injections are ineffective in the long term [1]. In addition, there is a high risk of osteoporosis, wedge compression vertebral fractures [2] and infection [3], after repeated corticosteroid injections. If corticosteroid injections fail, surgical treatment is considered the next step in those with persisting symptoms. However, there is high quality evidence that contradicts this approach. For example, Level 1 studies show no efficacy in the commonest surgical procedures of arthroscopic repair for degenerative rotator cuff tears [4] and arthroscopic partial meniscectomy for degenerative meniscal tears [5], in comparison to sham procedures or placebo.

Painful tendon, cartilage and neural conditions constitute an unmet medical need and a significant health care burden. Many of these patients are unable to return to a normal productive life and are at significant risk of drug dependency. There is an urgent need to radically change the approach to managing these conditions.

Degeneration is the hall mark lesion in a number of painful chronic tendon, cartilage and neural conditions. In tendons, ligaments, fibrocartilage and hyaline cartilage, degeneration results in poor tissue quality, loss of structure and a failure to cope with functional demand. An impaired healing response results in a combination of poor healing and a catabolic effect with progressive tissue damage.

Citation: Arockia Doss. "Non Surgical Repair of Tendon, Cartilage & Neurogenic Conditions - A Paradigm Shift in Musculoskeletal Medicine and Pain Management by Percutaneous Regenerative Intervention". *EC Orthopaedics* 2. 5 (2015): 159-167.

Regeneration or Stabilisation of Degenerated Tissue: The ideal treatment option should be minimally invasive and be able to provide an optimal chemical milieu to ensure a normal healing response that would re-generate or stabilise damaged tissue. Over a period of 6 to 12 weeks, an improvement in painful dysfunction should enable graded initiation of activity that would allow optimal remodulation of neo-tissue appropriate to the anatomical region and functional needs of the individual. Such a treatment should also attract the shortest downtime with rapid return to a productive stage with a favourable cost benefit ratio.

Autologous Biological Therapeutic Agents: Autologous Platelet Rich Plasma (PRP), Autologous Conditioned Serum (ACS), Tenocyte & Chondrocyte Implantation, Mesenchymal Stem Cells are some of the autologous biological agents that are now currently available for use in percutaneous regenerative interventional treatment. Of these, the most popular are autologous PRP and mesenchymal stem cells (MSC). Aside from the autologous nature and point of care delivery of treatment, the rationale for the use of PRP and MSC's is on the basis of anti-inflammatory [6] and regenerative properties. PRP is rich in several growth factors that stimulate matrix gene expression proliferation and differentiation of stem cells. PRP injections in tendinosis has been shown to be non toxic and efficacious [7]. ACS has an anti-inflammatory effect due to interleukin receptor 1 antagonist activity. The author uses photo activated PRP that contains interleukin receptor 1 antagonist (IL-1ra).

Percutaneous Image Guided Regeneration

The ability to accurately diagnose and percutaneously deliver treatment to the damaged body part is an inherent advantage with image guided radiological interventions. The ability to regenerate degenerating painful tissues is a major leap forward in the natural evolution of the treatment paradigm of these conditions.

The past decade has seen an explosion in the availability of biologics. These range from point of care products on one end of the spectrum, to complex products that undergo processing in dedicated laboratories prior to use. Percutaneous delivery of biologics under imaging guidance has opened up a new paradigm in the management of a number of conditions. The following article will summarise the common conditions that may be treated in this manner.

During percutaneous infiltration of biologics a tenotomy of the tissue allows the opening up of collapsed tears and these are filled with the biological agent. In some cases tenotomy should be performed down to the base of the foot print of the tendon to ensure optimal treatment of the fibrocartilage interface at the enthesis.

Rotator Cuff Tears

There is currently no optimal treatment option for degenerative rotator cuff tears. Percutaneous tenotomy and infiltration of PRP is an emerging alternative option to surgery. Application of PRP in treating degenerative rotator cuff lesions is on the basis of its role in regulation of matrix gene expression and cell proliferation [8]. Neo tendon tissue due to regeneration has been shown in a patient with a full thickness foot print rotator cuff tear after PRP under ultrasound guidance with excellent clinical outcome at two years [9].

A trial comparing corticosteroid injection and PRP injection into the subacromial space for subacromial impingement has been completed and results are awaited [10]. Rha., *et al.* showed that patients undergoing needling and PRP of the rotator cuff, did better, compared to needling alone in those with a partial tear less than 1 cm thus suggesting that PRP resulted in a better outcome [11].

Intraoperative PRP during surgical rotator cuff reconstruction has not been shown to be beneficial (12, 13, 14). However it has to be noted that such papers only highlight the diversity in various PRP products e.g: liquid versus semisolid versus gel PRP, the concentration of platelets, and should not be used to judge a product with inherent natural diversity. However, there is the urgent need for a more stringent approach to standardizing the type of PRP product used.

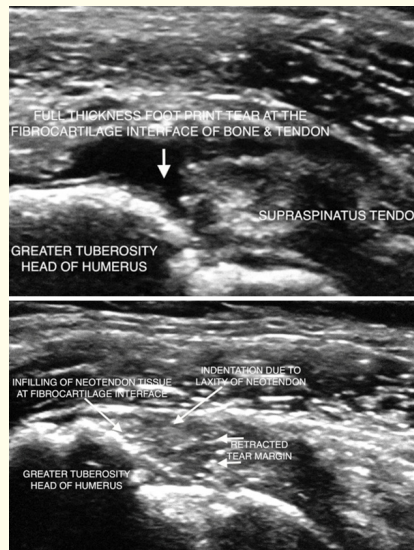


Figure 1: (a) Pre and (b) post liquid PRP tenotomy of a full thickness foot print tear of the supraspinatus tendon in an elderly female patient. Note neotissue that fills the full thickness tear defect. The patient is now two and a half years post treatment and completely free of symptoms with full function of the treated shoulder, having avoided surgery. Published under Creative Commons License from original article published in F1000 research (reference 9).

Osteoarthritis (OA)

There is no treatment to cure OA. Aside from pain, a major concern from OA is progressive deterioration in overall health from reduced levels of activity resulting in increased risk of poor diabetic control, hypertension and coronary or cerebrovascular disease. Patients with severe pain are left with either joint arthroplasty with its attendant risks from peri-operative and post surgical complications, failure or risk of long term medications. Image guided percutaneous treatment using PRP, ACS, mesenchymal stem cells have emerged as available options in the management of OA that may enable patients the option to mobilise better without highly invasive joint replacement.

PRP exerts an anti-inflammatory effect on osteoarthritic chondrocytes in hyaline cartilage [6] and regenerates meniscal fibrocartilage in vitro [15]. A randomised control trial showed statistically significant improvement in knee function after PRP, when patients with OA of the knees were randomly assigned to treatment with PRP or with placebo [16]. Jo, *et al.* showed that intra-articular injection of 1.0×10^8 [8] autologous adipose derived mesenchymal stem cells into the osteoarthritic knee improved function and pain of the knee joint without causing adverse events and reduced cartilage defects by regeneration of hyaline-like articular cartilage. They used second look arthroscopy and histological analysis in their study [17]. In a level 4 study, adipose-derived mesenchymal stem cell therapy for elderly patients with knee OA was effective in cartilage healing, reducing pain, and improving function out to two years [18].

Osteoarthritis of the thumb carpometacarpal and triscaphoid joints occurs in conjunction with degeneration of the flexor carpi radialis. Percutaneous autologous PRP of the joints and tendons provides pain relief, neotissue regeneration and restoration of function.

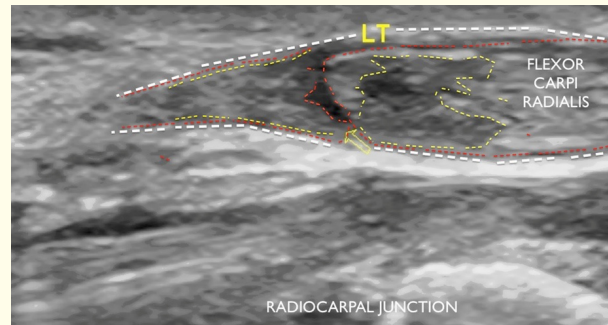


Figure 2A: Full thickness tear (red broken line and yellow arrow) of a degenerate flexor carpi radialis that occurred about 10 days after PRP to an osteoarthritic triscaphoid joint (not shown). The FCR tear occurred with forced extension of the wrist when the patient waxed a client upon returning to work as a beautician. This tear was treated with PRP and tenotomy under ultrasound control.

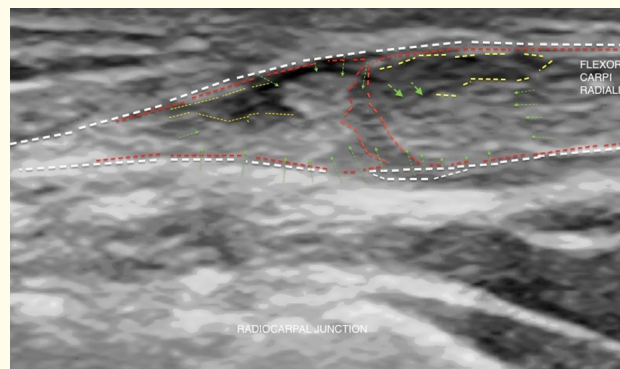


Figure 2A: Followup ultrasound shows neo-tissue that fills the tear defect and improved tendon appearance. There was marked resolution of symptoms and she returned to work as a beautician, having avoided surgery.

Degenerative Labral Tears of the Shoulder and Hip

Shoulder and hip Labral degenerative tears are similar to meniscal fibrocartilage degenerative tears in that, they are pain generators with risk of progressing to OA after surgical removal of the labrum or by natural progression. The typical lesion is the superior Labral anterior to posterior (SLAP) degenerative tear. Ultrasound guided Labral treatment with PRP [19] and or mesenchymal stem cells offer a viable alternative to surgical removal. Labral tears stabilise after PRP treatment under ultrasound guidance thus allowing preservation of the labrum. Any alteration in the risk of progressive degenerative arthritis following PRP is unknown.

Degenerative tears of the Plantar Plate

Fore foot metatarsalgia is pain usually due to degeneration of the second metatarsal head plantar plate at the metatarsophalangeal joint. The plantar plate is a fibrocartilagenous structure similar to meniscus of the knee and labrum of the shoulder or hip. Percutaneous treatment with PRP under ultrasound guidance is a viable option to alleviate symptoms and avoid surgery.

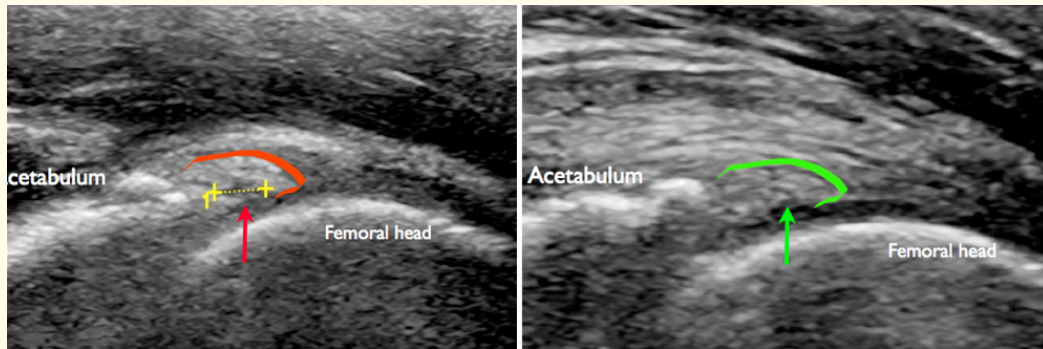


Figure 3: A) Anterior acetabular labral tear in a 40 year old female, pre procedure sagittal ultrasound on the left shows articular side tear (red arrow) of a mildly swollen labrum (in red margins). B) at 10 weeks post PRP ultrasound shows stabilisation of the tear (green arrow) and mild reduction in swelling of labrum (green margin). The patient has now avoided removal of labrum for more than two years. Changes to the rate of progression of arthritis by this labral preservation approach is currently unknown.

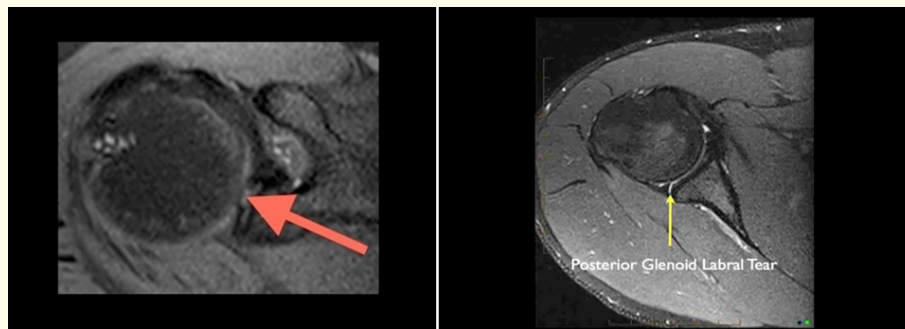


Figure 4: A) Axial MRI of the shoulder shows a superior labral anterior to posterior (SLAP) tear (red arrow) in a volley ball player with shoulder pains for many years. This was treated by ultrasound guided liquid PRP. The patient has now avoided surgery for more than two years. Changes to the rate of progression of arthritis by this labral augmentation approach is currently unknown. B) posterior glenoid labral tear in another patient who had an injury during bench pressing accident with a force impacting into the posterior shoulder; Both patients received PRP with subsequent dramatic reduction in pain and improvement in shoulder function at followup. Changes to the rate of progression of arthritis by this labral augmentation approach is currently unknown. Published under Creative Commons License from original publication from F1000 research (reference 19).

Plantar Fasciitis

Plantar fasciitis is due to degeneration that occurs typically at the medial band fascial attachment into the base of the calcaneum. The fascia degenerates and splits resulting in painful dysfunction with loading due to the arch of the foot. Ultrasound guided percutaneous fasciotomy with simultaneous injection of PRP is an effective non surgical option that may avoid surgical fasciotomy. PRP for plantar fasciitis has been shown to be significantly more effective than corticosteroid injections [20].

Degenerative Tendinosis including Epicondylitis and Trochanteric Bursitis

Level 1 evidence shows improved patellar tendon healing with PRP [21]. At two year follow up, in a double blind randomised controlled trial, an ongoing positive effect was observed in lateral epicondylitis treated with PRP when compared with corticosteroid injection [22].

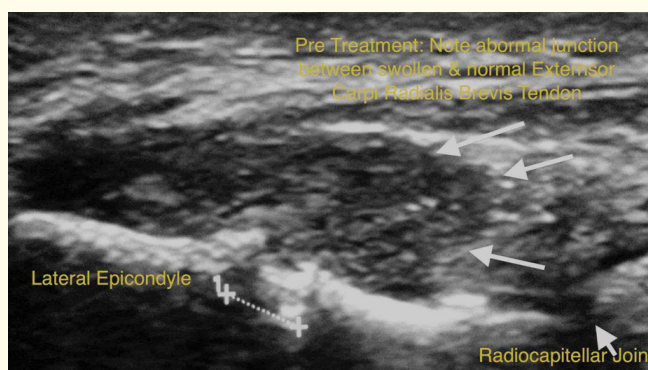


Figure 5A: Lateral epicondylitis in a patient with a tear and tendinosis of the common extensor tendon treated with PRP and tenotomy under ultrasound guidance,

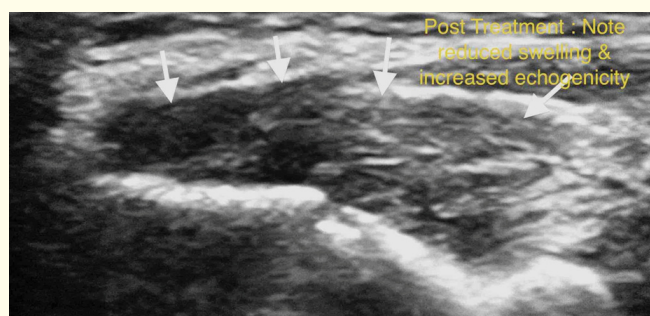


Figure 5B: Follow up ultrasound shows neotissue fibrillar appearance with an improved tendon appearance post PRP tenotomy. Patient had resolution of symptoms and returned to normal activities.

The common condition of trochanteric bursitis may be a specific clinical presentation that may include one or more of trochanteric bursitis, tendinosis of the gluteus tendons, and external coxa saltans. Some others suggest 'trochanteric bursitis' is a misnomer as there is no inflammation [23]. A randomised controlled trial showed corticosteroid injections showed positive effect at three months but there was no difference at 12 month followup in comparison to usual treatment in primary care [24]. Any tendon with features of tendinosis and in substance delamination splits or tears may be considered for percutaneous tenotomy and infiltration with biologicals. Examples include Common Flexor/Extensor tendons of the elbow, achilles, flexor carpi radialis and triscaphoid joint, distal biceps tendon, collateral ligaments, iliopsoas tendon amongst other tendons and ligaments.

Intervertebral Disc Degeneration (IVDD) & Annulus Fibrosus Lesions

It is estimated that the annual medical and disability cost of LBP in the US is \$100 billion per annum. One of the commonest lesions is degeneration or derangement of the intervertebral disc (IVD). IVD is a complex structure with a peripheral ligamentous annulus

fibrosus (AF) composed of 'fibroblast like' material similar to tendoligamentous structures elsewhere in the body. Within the boundaries of an intact AF, a gel like nucleus pulposus (NP) composed of 'chondrocyte like' material and proteoglycan acts as a shock absorber. The central nucleus pulposus absorbs and transmits axial loading by movement of water molecules. The peripheral annulus is attached to the adjacent bony vertebra through an enthesis or end plate and designed to withstand shear stress and strain. The pathology of IVDD is poorly understood. There is a complex interaction with loss of architecture, altered biochemistry and increased sensitisation of the sinuvertebral nerve. With degeneration of the IVD this function is lost. Degeneration, tearing or fissuring of the annulus fibrosus together with other multiple factors contribute to progressive irreversible loss of structure and function of the IVD. There is no optimal treatment option for disc degeneration and annulus fibrosus lesions. Intervertebral fusion surgery is aimed at symptom relief and not restoration of function of the affected disc. With surgery there are post surgical risks and delayed risks of adjacent segment hypermobility and degeneration.

There is an urgent need for optimal management options for IVD. Animal studies using PRP in degenerative discs have shown a reparative effect [25] and a protective effect if used early rather than later [26]. A preliminary clinical study in 12 patients showed intradiscal injection in IVDD to be safe and effective at twelve months follow up [27]. There are ongoing non randomised clinical trials testing intradiscal PRP and autologous adipose derived MSC's [28] and a phase I-II trial, prospective, randomized, blinded, and controlled for the treatment IVDD using expanded bone marrow MSCs [29].

Early phase 2 trials of allogeneic mesenchymal stem cell injection into degenerate intervertebral disc have shown some promise [30]. Autologous mesenchymal stem cell injections into intervertebral discs is now offered routinely in some clinics [31].

Neuropathic Pain

Pain that originates from a pathological condition of a nerve is termed neuropathic pain. Degeneration of the neural structure is considered the key finding in a number of neuropathic conditions. Regeneration of damaged cavernous nerves has been shown to occur after treatment with PRP in an animal model [32].

PRP and induced MSC's promote regeneration of facial nerve after axotomy in an animal model [33]. Pain relief from Trigeminal neuralgia has been reported after PRP to the infraorbital nerve [34].

Reflex Sympathetic Dystrophy (RSD) & Complex Regional Pain Syndrome (CRPS)

CRPS Type 1 & 2 are poorly understood conditions that occur typically after trauma to an extremity. CRPS Type 1 is when there is no defined nerve injury and was formally referred to as Reflex Sympathetic Dystrophy (RSD). CRPS Type 2 is said to occur when there is a well defined neural injury. There is a rapid onset of severe pain, episodic skin discolouration with swelling with altered sensation to touch and allodynia. It is postulated that there is sympathetic dysregulation, inflammation, hyper sensitisation of the central nervous system and cerebral cortical disorganisation. There is no optimal treatment option for RSD. Individuals can be left with a crippling painful condition for life. There is a case series report on the use of PRP in CRPS Type 1 and Type 2 that has shown improvement in neuropathic pain and marked reduction in features of sympathetic dysregulation [35].

Conclusion

Percutaneous image guided treatment of tendons, cartilage and nerves using autologous biological agents are likely to impact substantially in the management of a number of degenerative conditions traditionally injected with corticosteroids. There is an urgent need for research into autologous orthobiologic options to assess their efficacy in the management of these conditions as an alternative to repeated corticosteroid injections or surgery.

Bibliography

1. Coombes BK, *et al.* "Efficacy and safety of corticosteroid injections and other injections for management of tendinopathy: a systematic review of randomised controlled trials". *Lancet* 376.754 (2010): 1751-1767.
2. Mandel S, *et al.* "A retrospective analysis of vertebral body fractures following epidural steroid injections". *The Journal of Bone & Joint Surgery* 5.95 (2013) : 961-964.
3. Multistate Investigation of Suspected Infections Following Steroid Injections
4. J. Kukkonen, *et al.* "Treatment of non-traumatic rotator cuff tears: A randomised controlled trial with one-year clinical results". *The Bone & Joint Journal* 96.B-1 (2014): 75-81.
5. Sihvonen R, *et al.* "Arthroscopic Partial Meniscectomy versus Sham Surgery for a Degenerative Meniscal Tear". *The New England Journal of Medicine* 369.26 (2013): 2513-2522.
6. van Buul GM, *et al.* "Platelet-rich plasma releasate inhibits inflammatory processes in osteoarthritic chondrocytes". *The American Journal of Sports Medicine* 39.11 (2011): 2362-2370.
7. Dallaudière B, *et al.* "Efficacy of intra-tendinous injection of platelet-rich plasma in treating tendinosis: comprehensive assessment of a rat model". *European Radiology* 23.10 (2013): 2830-2837.
8. Chris Hyunchul Jo, *et al.* "Platelet-Rich Plasma Stimulates Cell Proliferation and Enhances Matrix Gene Expression and Synthesis in Tenocytes From Human Rotator Cuff Tendons With Degenerative Tears". *The American Journal of Sports Medicine* 40.10 (2012): 1035-1045.
9. Doss A (2013) Neotendon infilling of a full thickness rotator cuff foot print tear following ultrasound guided liquid platelet rich plasma injection and percutaneous tenotomy: favourable outcome up to one year.
10. <http://www.clinicaltrials.gov/ct2/show/NCT01123889>.
11. Rha DW, *et al.* "Comparison of the therapeutic effects of ultrasound-guided platelet-rich plasma injection and dry needling in rotator cuff disease: a randomized controlled trial". *Clinical Rehabilitation* 27.2 (2013): 113-122.
12. Rodeo SA, *et al.* "The effect of platelet-rich fibrin matrix on rotator cuff tendon healing: a prospective, randomized clinical study". *The American Journal of Sports Medicine* 40.6 (2012): 1234-1241.
13. Castricini R, *et al.* "Platelet-rich plasma augmentation for arthroscopic rotator cuff repair: a randomized controlled trial". *The American Journal of Sports Medicine* 39.2 (2011): 258-265.
14. Bergeson AG, *et al.* "Effects of platelet-rich fibrin matrix on repair integrity of at-risk rotator cuff tears". *The American Journal of Sports Medicine* 40.2 (2012): 286-293.
15. Ishida K, *et al.* "The regenerative effects of platelet-rich plasma on meniscal cells in vitro and its in vivo application with biodegradable gelatin hydrogel". *Tissue Engineering* 13.5 (2007): 1103-1112.
16. Patel S, *et al.* "A. Treatment with platelet-rich plasma is more effective than placebo for knee osteoarthritis: a prospective, double-blind, randomized trial". *The American Journal of Sports Medicine* 41.2 (2013): 356-364.
17. Jo CH, *et al.* "Intra-articular injection of mesenchymal stem cells for the treatment of osteoarthritis of the knee: A proof-of-concept clinical trial". *Stem Cells* 32.5 (2014): 1254-1266.
18. Koh YG, *et al.* "Clinical results and second-look arthroscopic findings after treatment with adipose-derived stem cells for knee osteoarthritis". *Knee Surgery, Sports Traumatology, Arthroscopy* 41.2 (2013): 356-364.
19. Vander Kraats R and Doss A. "Glenoid Labral Tear: follow up case series on ultrasound guided autologous platelet rich plasma in conjunction with a progressive rehabilitation program [v1; ref status: approved 1, approved]". *F1000Research* 1.68 (2012): (doi: 10.12688/f1000research.1-68.v1).
20. Raymond R Monto. "Platelet-Rich Rich Plasma is More Effective than Cortisone for Chronic Severe Plantar Fasciitis". *Foot and ankle international* 35.4 (2014): 313-318.
21. Adriano Marques de Almeida, *et al.* "Patellar Tendon Healing With Platelet-Rich Plasma: A Prospective Randomized Controlled Trial". *The American Journal of Sports Medicine* 40.6 (2012): 1282-1288.

22. Gosens., *et al.* "Ongoing Positive Effect of Platelet-Rich Plasma Versus Corticosteroid Injection in Lateral Epicondylitis. A Double-Blind Randomized Controlled Trial With 2-year Follow-up". *The American Journal of Sports Medicine* 39.6 (2011): 1200-1208.
23. Silva F., *et al.* "Trochanteric bursitis: refuting the myth of inflammation". *JCR: Journal of Clinical Rheumatology* 14.2 (2008): 82-86.
24. Brinks A., *et al.* "Corticosteroid injections for greater trochanteric pain syndrome: a randomized controlled trial in primary care". *The Annals of Family Medicine* 9.3 (2011): 226-234.
25. Shuji Obata., *et al.* "Effect of autologous platelet-rich plasma-releasate on intervertebral disc degeneration in the rabbit anular puncture model: a preclinical study". *Arthritis Research & Therapy* 14.6 (2012): R241.
26. Gullung GB., *et al.* "Platelet-rich plasma effects on degenerative disc disease: analysis of histology and imaging in an animal model". *Evidence-Based Spine-Care Journal* 2.4 (2011):13-18.
27. Akeda K., *et al.* "Intradiscal Injection of Autologous Platelet-Rich-Plasma releasate for the Treatment of Discogenic Low Back Pain Patients". 2012.
28. <http://www.clinicaltrials.gov/ct2/show/study/NCT02097862>
29. <http://clinicaltrials.gov/show/NCT01860417>
30. <http://www.mesoblast.com/products/orthopedic-diseases-of-the-spine/intervertebral-disc-repair>
31. <http://spinerevolution.com/adult-stem-cell/>
32. Xie-Gang Ding., *et al.* "The effect of platelet -rich plasma on cavernous nerve regeneration in a rat model". *Asian Journal of Andrology* 11.2 (2009): 215-221.
33. Cho HH., *et al.* "Effect of neural-induced mesenchymal stem cells and platelet-rich plasma on facial nerve regeneration in an acute nerve injury model". *Laryngoscope* 120.5 (2010): 907-913.
34. Doss AX. "Trigeminal Neuralgia Treatment: A Case Report on Short-Term Follow up After Ultrasound Guided Autologous Platelet Rich Plasma Injections". *Webmed Central* 3.5 (2012).
35. Doss A. "Case Series Report: Ultrasound Guided Autologous Liquid Platelet Rich Plasma - A new treatment option for Chronic Regional Pain Syndrome and Reflex Sympathetic Dystrophy". *Webmed central* (2014).

Volume 2 Issue 5 October 2015

© All rights are reserved by Arockia Doss.