

Glenohumeral Arthrosis Treatment with Reverse Shoulder Prosthesis Developed for Chronic Villonodular Synovitis

Umut Hatay Golge^{1*}, Ersin KUYUCU², Ferdi GKSEL¹, Burak KAYMAZ¹

¹Department of Orthopaedics and Traumatology, Canakkale Onsekiz Mart University, Turkey

²Department of Orthopaedics and Traumatology, Denizli Government Hospital, Turkey

***Corresponding Author:** Umut Hatay Golge, Department of Orthopaedics and Traumatology, Canakkale Onsekiz Mart University School of Medicine, Canakkale, Turkey.

Received: July 28, 2015; **Published:** September 04, 2015

Abstract

Pigmented villonodular synovitis (PVNS) is a proliferative disorder of the synovium that affects joints, bursae, or tendon sheaths. PVNS can be seen in joints in two forms: nodular or diffuse involvement. The clinical and radiological symptoms are not specific to the disease and usually mimic other joint diseases. This report is of a patient with pigmented villonodular synovitis of the shoulder that caused advanced arthrosis. The patient did not have previous trauma and infection and had received no surgical treatment for synovitis. The patient came to our clinic because of pain and limited joint mobility. The patient had advanced stage arthrosis and massive rotator cuff rupture, which were treated with reverse shoulder prosthesis.

Keywords: Reverse shoulder arthroplasty; Pigmented villonodular synovitis; Arthrosis

Introduction

Pigmented villonodular synovitis (PVNS) is a relatively rare proliferative disorder that seems to arise principally from the synovium and most frequently occurs in the knee and foot of young individuals [1]. PVNS usually occurs in young adults, between the 3rd and 4th decades of life, with men and women equally affected [2]. PVNS can present in a diffuse or localized/circumscribed form, and is usually monoarticular. Polyarticular involvement is exceptionally rare [2,3].

The knee and the hand are the most commonly affected sites, whereas shoulder involvement is relatively rare (< 2%) [4,5]. The condition may present as osteoarthritis with cystic erosions, usually on the humeral side. If a joint has been destroyed, synovectomy may have to be combined with arthroplasty [6].

PVNS with shoulder involvement is very rare and has not been reported in the literature on arthrosis. This report is about a patient with PVNS of the shoulder that caused extensive arthritic changes that were treated with reverse shoulder arthroplasty.

Case Report

At 75-year-old male outpatient with a long history of pain who had received medical treatment at various centers presented at our center with limited motion of the right shoulder. There was no history of trauma or infection. The patient had received intra-articular steroid injection therapy with occasional anti-inflammatory drugs for pain and swelling.

The physical examination, right shoulder, redness, swelling and heat was no difference. Active and passive shoulder movements, especially flexion, internal and external rotation and abduction with more movement was painful. The patient had no deltoid muscle atrophy. The patient's blood count, serum electrolytes, C-reactive protein (CRP), and sedimentation results were normal. Advanced stage glenohumeral arthrosis and cystic degeneration, especially of the humeral head structures were observed on radiography. The acromioclavicular joint and the acromion presented a similar appearance (Figure 1a,1b). Rotator cuff tendon rupture was observed on all

Citation: Umut Hatay Golge., *et al.* "Glenohumeral Arthrosis Treatment with Reverse Shoulder Prosthesis Developed for Chronic Villonodular Synovitis". *EC Orthopaedics* 2.2 (2015): 60-64.

radiography and magnetic resonance imaging (MRI) findings in the glenohumeral joint capsule, and muscle retraction and subacromial-subdeltoid, and subcoracoid bursa common effusion increased (Figure 2a,2b).

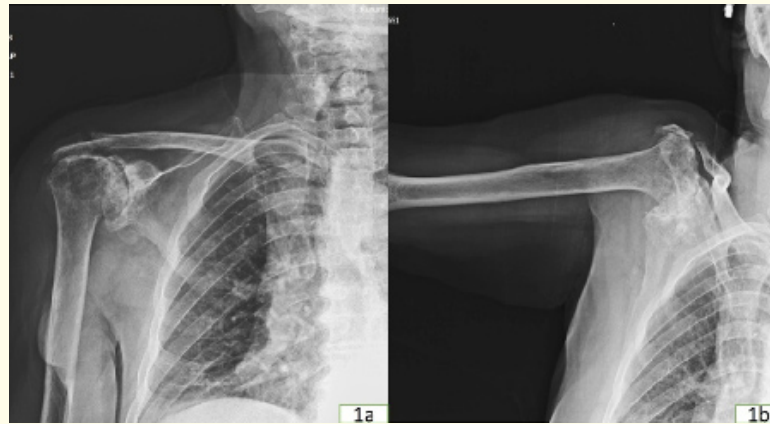


Figure 1a, 1b: Preoperative anterior posterior radiograph.

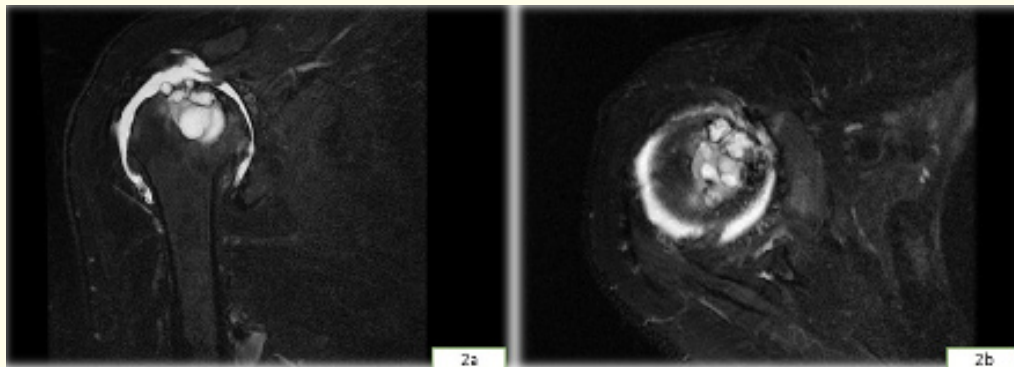


Figure 2a, 2b: Magnetic resonance images of coronal and axial images.

Due to the current findings, the patient was considered for reverse shoulder prosthesis. The deltopectoral incision joint capsule had been reached, and rotator cuff arthropathy had developed. Hypertrophic soft tissue masses extending to the posterior and anteroinferior osteophytes and yellow brown rust in the joint were excised. A reverse shoulder prosthesis was performed. Because of the cyst's current humeral head, a transverse osteotomy was performed under the neck. Extensive glenoid osteophytes were cleaned out of the fracture. Therefore a cemented glenoid component was applied (Figure 3). Postoperative neurovascular complications were not observed. Preoperatively, the visual analog scale (VAS) pain score was 8 points. After 6 months, the postoperative VAS pain score was 1 point. Passive movement was started 14 days after surgery. Two months later, the patient had recovered nearly complete passive and active range of motion.

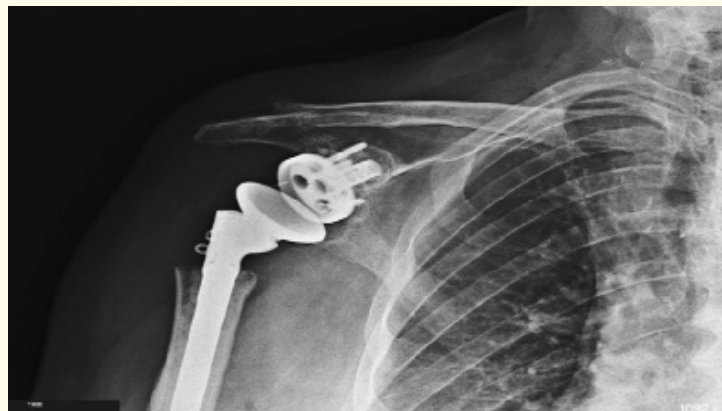


Figure 3: Postoperative radiograph.

The gross specimen was partially hard and red-brown and measured about 6.5 × 6.0 × 6.0 cm. Histopathological examination revealed papillary, villous, and nodular proliferation projected in the synovial space (Figure 4a,4b). The histomorphology findings were consistent with right shoulder villonodular synovitis.

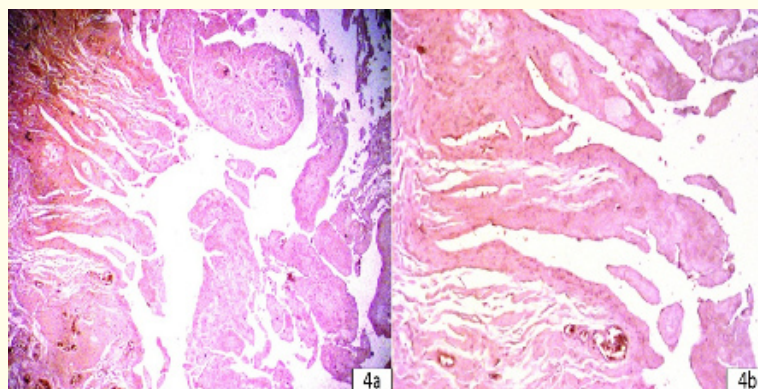


Figure 4a, 4b: The histomorphology findings were consistent with right shoulder villonodular synovitis.

Discussion

Pigmented villonodular synovitis is a nonneoplastic tissue proliferative disorder that originates from the synovium of joints, bursae, or tendon sheaths. Pigmented villonodular synovitis is a rare disorder, with an annual incidence of 1.8 cases per 1 million individuals [7]. The mean age at the time of diagnosis is 60.7 (range, 18-84) years for women and 43.5 (range, 5-64) years for men [8]. PVNS of the shoulder typically occurs in older patients as a diffuse form; a combination of intra- and extra-articular lesions is not uncommon [2,8,9]. In our case, diffuse intra-articular involvement was present.

The radiographic appearance of the diffuse form of PVNS is usually normal. The localized form varies from normal osseous anatomy with soft tissue mass, subacromial effusion, or small cystic erosion of the subchondral bone in the early stages of disease to juxta-articular cystic lucency of the glenoid and humeral head in the late stages [10,11]. On conventional radiography, we do not consider glenohumeral arthrosis in patients. Thus, we use advanced MRI examination. MRI is the imaging modality of choice in PVNS and is useful for diagnosis, surgical planning, and follow-up.

Citation: Umut Hatay Golge., *et al.* "Glenohumeral Arthrosis Treatment with Reverse Shoulder Prosthesis Developed for Chronic Villonodular Synovitis". *EC Orthopaedics* 2.2 (2015): 60-64.

The simultaneous occurrence of PVNS and a rotator cuff tear has been reported. However, to our knowledge, PVNS of the shoulder has not been reported in association with a rotator cuff manifesting subacromial erosion. The cause of rotator cuff tears remains unclear in the setting of PVNS, although they are probably caused by impingement syndrome. Furthermore, aggressive lesions may infiltrate into the synovial membrane and cause rotator cuff tears. In our case, a massive rotator cuff tear was present. Most authors recommend local excision in cases of localized PVNS and total synovectomy in cases of diffuse PVNS. For a severely affected joint with bony destruction, synovectomy with arthroplasty is indicated.

For the shoulder joint, arthroplasty with total synovectomy is rarely performed. To the best of our knowledge, a total of 6 cases published in 5 reports have been treated with shoulder arthroplasty with total synovectomy [3,5,7]. A total of 2 cases published in 1 report were treated with hemiarthroplasty with total synovectomy[6].

When massive arthritic changes are present, total synovectomy alone may be insufficient and should be combined with shoulder arthroplasty [7,8]. The 2-year results were good for 2 patients with PVNS treated with total shoulder arthroplasty [12]. The hemiarthroplasty results are superior to those of total shoulder arthroplasty in patients with osteoarthritis [13].

In conclusion, treatment of advanced stage glenohumeral arthrosis accompanied by rotator cuff arthropathy caused by PVNS with reverse shoulder arthroplasty is a good choice.

Bibliography

1. Mankin H., *et al.* "Pigmented villonodular synovitis of joints". *Journal of Surgical Oncology* 103.5 (2011): 386-389.
2. Llauger J., *et al.* "Nonseptic monoarthritis: imaging features with clinical and histopathologic correlation". *Radiographics* (2000): S263-S278.
3. Dorwart RH., *et al.* "Pigmented villonodular synovitis of synovial joints: clinical, pathologic, and radiologic features". *AJR. American journal of roentgenology* 143.4 (1984): 877-885.
4. Flandry F., *et al.* "Pigmented villonodular synovitis of the shoulder". *Orthopedics* 12.5 (1989): 715-718
5. Schwartz HS., *et al.* "Pigmented villonodular synovitis. A retrospective review of affected large joints". *Clinical Orthopaedics and Related Research* 247 (1989): 243-255.
6. Petsatodis G., *et al.* "Hemiarthroplasty for pigmented villonodular synovitis of the shoulder: a report of two cases". *Journal of orthopaedic surgery (Hong Kong)* 19.1 (2011): 116-119.
7. Toro FG., *et al.* "Total shoulder arthroplasty in pigmented villonodular synovitis: a case report". *Journal of Shoulder and Elbow Surgery* 11.2 (2002): 188-190.
8. Muller LP., *et al.* "Pigmented villonodular synovitis of the shoulder: review and case report". *Knee Surgery, Sports Traumatology, Arthroscopy* 7.4 (1999): 249-256.
9. Wirbel RJ., *et al.* "Villonodular synovitis of the shoulder". *Orthopedics* 23.7 (2000): 731-733.
10. Sawmiller CJ., *et al.* "Extra-articular pigmented villonodular synovitis of the shoulder: a case report". *Clinical Orthopaedics and Related Research* 335 (1997): 262-267.
11. Aydin H., *et al.* "Pigmented villonodular synovitis of shoulder; radiologic assessment with MRI findings". *The New Journal of Medicine* 27 (2010): 122-125.
12. Johansson JE., *et al.* "Pigmented villonodular synovitis of joints". *Clinical Orthopaedics and Related Research* 163 (1982): 159-166.
13. Levy O and Copeland SA. "Cementless surface replacement arthroplasty (Copeland CSRA) for osteoarthritis of the shoulder". *Journal of Shoulder and Elbow Surgery* 13.3 (2004): 266-271.

Volume 2 Issue 2 September 2015

© All rights are reserved by Umut Hatay Golge., *et al.*