

Retinal Vasoproliferative Tumour Secondary to Intermediate Uveitis

Bora Yüksel*, Fatih Gümüş and Tuncay Küsbeci

University of Health Sciences, Izmir Bozyaka Teaching Hospital, Izmir, Turkey

*Corresponding Author: Bora Yüksel, University of Health Sciences, Izmir Bozyaka Teaching Hospital, Izmir, Turkey.

Received: June 23, 2022; Published: December 30, 2022

Abstract

A 23-year-old female with intermediate uveitis presumably secondary to multiple sclerosis presented with blurred vision and floaters in the left eye. Differential diagnosis revealed no infectious condition. Retinal phlebitis and macular edema was observed in predominantly on the left eye. SD-OCT revealed macular edema and subretinal fluid on the left eye. Cranial magnetic resonance imaging showed paraventricular demyelinating plaques. Vasoproliferative tumor (RVPT) was noticed at the inferior peripheral retina. In order to prevent tractional retinal detachment, the lesion was treated with barrier laser photocoagulation and external cryotherapy. Also intravitreal anti-VEGF (bevacizumab) injection was performed. After initial intravenous pulse methylprednisolone treatment, intravitreal dexamethasone implant (Ozurdex) was injected to suppress inflammation and control macular edema for longer. At last visit, vitreous was clear, macular edema resolved and visual acuity improved in both eyes. RVPT showed partial regression and remained inactive.

Keywords: Multiple Sclerosis (MS); Bevacizumab; Ozurdex; Intermediate Uveitis

Introduction

Intermediate uveitis is an inflammatory syndrome commonly affecting children and young adults [1]. Predominant site of inflammation is in the vitreous. The term pars planitis refers to the idiopathic form with no associated infection or systemic disease. Relatively quiet anterior uveitis may be seen. Inflammatory cells may aggregate in the inferior vitreous, namely “snowballs”. Retinal peripheral phlebitis, macular edema and optic disc edema are common findings. It may be associated with various conditions, including sarcoidosis, multiple sclerosis (MS), syphilis, tuberculosis, lyme and toxocariasis. In chronic intermediate uveitis cases; retinal detachment, neovascularization, vitreous hemorrhage and retinoschisis can occur [2]. In rare cases, the inflammatory complexes evolve into secondary peripheral retinal vasoproliferative tumors that are vascular masses with exudative retinopathy and slightly dilated vessels (RVPT) [3].

Case Report

A 23-year-old lady presented with blurred vision and floaters on her left eye for one week. Ocular history revealed an inflammation and redness on her left eye with spontaneous improvement which was occurred 5 years ago during her pregnancy. She reported that attack repeated 3 times within the last year. She had no medication. She also denoted that her maternal uncle had MS.

On examination; best corrected visual acuity was 0.7 on the right eye and 0.16 on the left. Intraocular pressure was 14 and 15 mmHg with Goldmann applanation tonometry respectively. On biomicroscopy; + 1 positive cells were observed in the left anterior chamber, right eye was normal. Dilated fundus biomicroscopy revealed heavy vitiritis and snowball opacities at the posterior pole of the right eye and inferior vitreous in both eyes (Figure 1). There was vascular sheathing in the peripheral retinal vessels on both eyes.

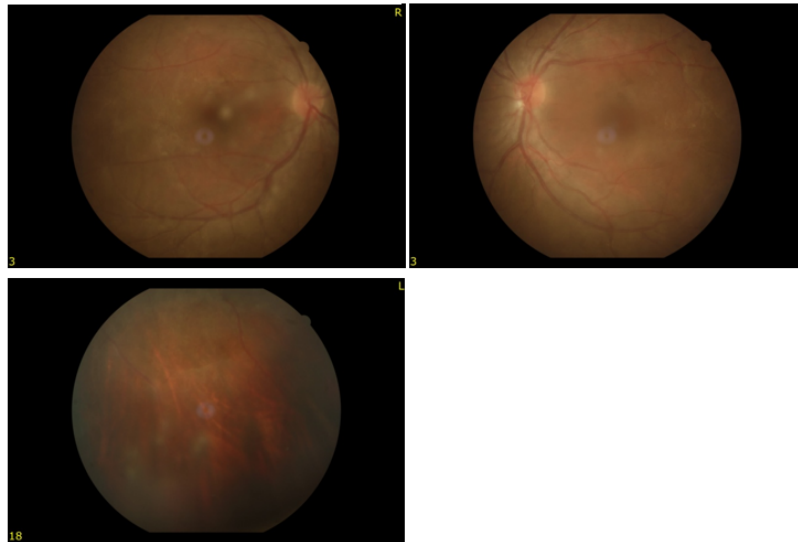


Figure 1: Intermediate uveitis. Snowball opacities at posterior pole of the right eye and inferior periphery in the left eye (not seen in this colour photograph).

Systemic work-up for differential diagnosis: There was no hilar lymphadenopathy on chest x-ray. Serum angiotensin-converting enzyme level was 1.49 U/L and calcium level was 8.7 mg/dl that are normal. There was no space occupying lesion on computerized thorax tomography. Quantiferon-tb gold plus test was negative for tuberculosis. Sarcoidosis and tuberculosis were excluded. Rheumatology consultation was normal. Patient had no gastrointestinal symptoms. Toxoplasma, syphilis, brucella and Lyme serologies were all negative.

A diagnosis of intermediate uveitis was made. The patient was hospitalized and intravenous pulse methyl prednisolone treatment was started. Topical steroids and cycloplegics were started. After vitreous haziness cleared a bit, a yellowish-gray mass with feeding vessels was noticed in inferior peripheral retina of the left eye. It was diagnosed as retinal vasoproliferative tumor (RVPT). A barrier photocoagulation with argon laser around the lesion to prevent retinal detachment. After few days a fluorescein angiography (FA) was performed. It revealed diffuse retinal vasculitis with leakage on both eyes and a cystoid macular edema on the left eye. RVPT was seen as a hyperfluorescent mass inferiorly (Figure 2).

Spectral domain OCT revealed cystoid macular edema and subretinal fluid on the left eye (Figure 3).

Cranial magnetic resonance imaging revealed a myriad of millimetric lesions hypointense in T1 weighted imaging at periventricular area at the level of centrum semiovale in both cerebral hemisphere. These lesions were highly suggestive of demyelinating MS lesions (Figure 4). Thus, we avoided anti TNF agents that may aggravate MS.

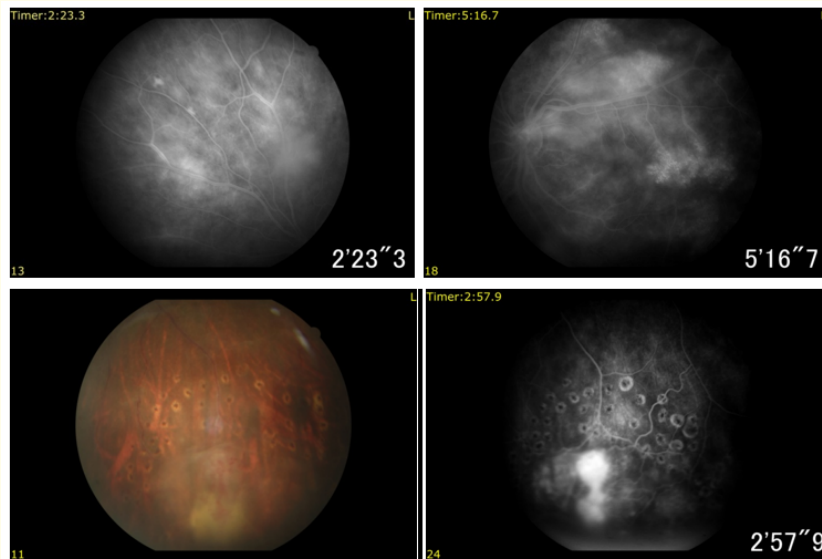


Figure 2: Fluorescein angiography. Diffuse retinal vasculitis with leakage on both eyes also cystoid macular edema on the left eye. Retinal vasoproliferative tumor with feeding vessels. Barrier laser scars (bottom left). Tumor showed hyperfluorescence in midphase FA (bottom right).

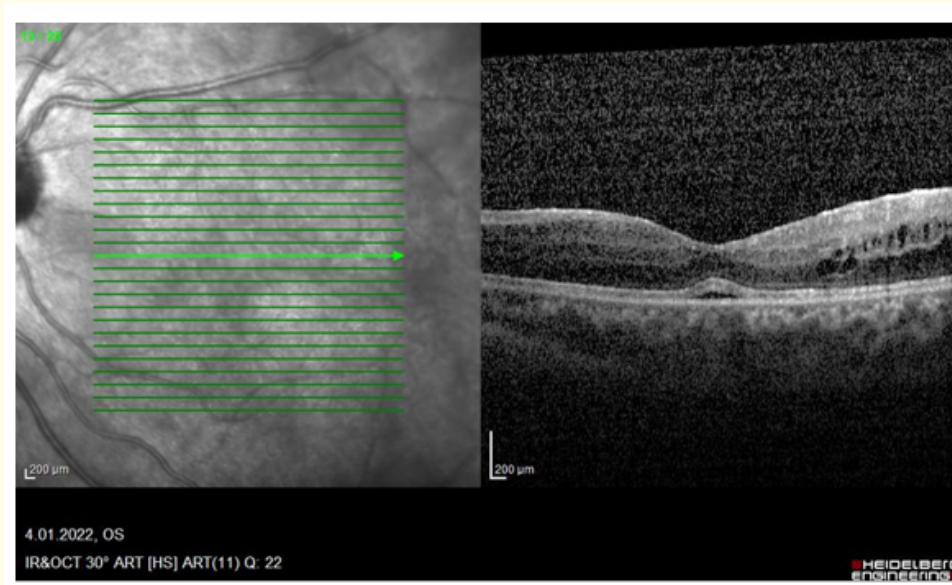


Figure 3: Spectral domain OCT showing intraretinal fluid accumulation temporal to fovea and serous macula detachment in the left eye.

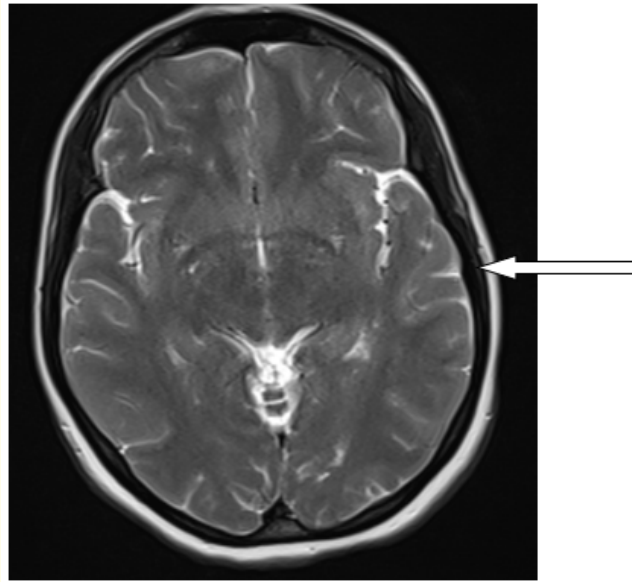


Figure 4: Cranial magnetic resonance imaging showing a myriad of millimetric lesions hypointense in T1 weighted imaging at periventricular area at the level of centrum semiovale in both cerebral hemisphere (arrow).

Since the yellowish-gray lesion at inferior retina with feeding vessels which are not tortuous as much, a diagnosis of retinal vasoproliferative tumour secondary to intermediate uveitis was made.

Treatment: To suppress bilateral massive vitritis and macular edema, intravenous pulse methyl prednisolone 250 mg was given for three days followed by oral 80 mg methyl prednisolone combined with azathioprine (Imuran, 50 mg 2x1). Frequent topical steroids and cycloplegics were given. In order to get tumor regression, an intravitreal anti-VEGF (bevacizumab, 1,25 mg/0,05 ml) injection was performed. Tumour whitened a little bit. But it did not regress completely. External cryotherapy with double freeze method provided further regression. In order to suppress inflammation for longer period, dexamethasone intravitreal implantation (Ozurdex) was performed. After all treatments, vision of the patient to 0.6 and 0.7, vitreous cleared in both eyes and macular edema resolved. RVPT remained stable and regressed. Since the patient had no neurological symptoms, she was taken under follow-up by neurologists.

Discussion and Conclusion

At the beginning of 1980s, Shields, *et al.* reported 12 retinal vascular masses with unknown etiology and they called it "Presumed Acquired Retinal Hemangioma" [4]. Baines, *et al.* reported a similar case and gave the name of "peripheral nodular retinal telangiectasis" [5]. Hiscott ve Mudhar, suggested that the lesion could be a part of proliferative vitreoretinopathies and called it "reactive retinal gliosis" [6]. Suh, *et al.* reported a "Coat's like" subretinal exudation in patients with pars planitis [7]. Felder and Brockhurst defined 5 peripheral retinal angiomas in patients with pars planitis [8]. Since, reactive gliosis and vascular proliferation was found in histopathologic studies, the name of the lesion has been changed as retinal vasoproliferative tumour (RVPT). These lesions are associated with telangiectasis, retinal hemorrhage and exudation and usually located in inferotemporal peripheral retina. These solid tumours have a feeding artery and draining vein that are not tortuous as much [9]. They may occur as primary idiopathic or secondary to retinitis pigmentosa,

uveitis, sickle cell disease, past surgery or retinopathy of prematurity. In RVPTs secondary to intermediate uveitis; inflammation can trigger retinal vascular changes, breakdown of blood-retina barrier and resulting fibrose proliferation and angiogenesis [10]. Differential diagnosis includes retinal hemangioblastomas, Coat's disease, peripheral exudative chorioretinopathy, retinal and choroidal metastasis and amelanotic choroid malignant melanomas [9].

Although RVPT is a benign tumour, it may cause macular exudation, vitreous hemorrhage and epiretinal membrane resulting in visual loss. RVPT secondary to intermediate uveitis should be treated aggressively [10]. Treatment modalities include cryotherapy, laser photocoagulation, brachytherapy, intravitreal anti-VEGF and dexamethasone implant [11]. All these treatments were carried out in our patient except brachytherapy and provided visual improvement and partial tumour regression in our patient. In patients with intermediate uveitis having RVPT and vascular leakage on fluorescein angiography, more aggressive treatment including systemic immunosuppression [10]. Likewise, pulse intravenous and oral steroids was used in our patient. Steroids were gradually tapered and stopped, systemic immunosuppression was maintained with azathioprine along with intravitreal dexamethasone implant.

Laser photocoagulation is simple and effective method for management of retinal exudation in RVPT [12]. In our patient, laser barrier prevent further retinal exudation and detachment. RVPTs show a strong immunoreactivity against VEGF. Thus, anti-VEGF injections including bevacizumab may be an effective treatment [13]. Partial stabilization of the tumour was achieved with a single bevacizumab intravitreal injection in our case. Manjandavida, *et al.* showed that transconjunctival double-freeze cryotherapy was effective in tumours with a diameter < 6 mm [14]. Cryotherapy was employed in our patient to get further regression of the tumour. Cebeci, *et al.* reported that combined photodynamic therapy and intravitreal dexamethasone implant was effective in RVPT [15]. Intravitreal dexamethasone inhibits leucostasis, reestablishes blood-retina barrier and decreases the vascular leakage. Likewise, we performed intravitreal dexamethasone on our patient to suppress intraocular inflammation and tumour growth.

In conclusion, early diagnosis and prompt treatment of RVPT and intermediate uveitis carry an utmost importance to prevent patients from sight-threatening complications.

Bibliography

1. Paroli MP, *et al.* "Intermediate uveitis: comparison between childhood-onset and adult-onset disease". *European Journal of Ophthalmology - SAGE Journals* 24 (2014): 94-100.
2. Brockhurst RJ. "Retinoschisis. Complication of peripheral uveitis". *Archives of Ophthalmology* 99 (1981): 1998-1999.
3. Shields CL, *et al.* "Retinal vasoproliferative tumors: comparative clinical features of primary vs secondary tumors in 334 cases". *The Journal of the American Medical Association Ophthalmology* 131.3 (2013): 328-334.
4. Shields JA, *et al.* "Presumed acquired retinal hemangiomas". *Ophthalmology* 90 (1983): 1292-1300.
5. Baines PS, *et al.* "Posterior non-vascularized proliferative extraretinopathy and peripheral nodular retinal telangiectasis". *Transactions of the Ophthalmological Societies of the United Kingdom* 102.4 (1982): 487-491.
6. Hiscott P and Mudhar H. "Is vasoproliferative tumour (reactive retinal gliosis) part of the spectrum of proliferative vitreoretinopathy?" *Eye* 23 (2009): 1851-1858.
7. Suh DW, *et al.* "Coats'-like response in pars planitis". *Retina* 19.1 (1999): 79-80.
8. Felder KS and Brockhurst RJ. "Neovascular fundus abnormalities in peripheral uveitis". *Archives of Ophthalmology* 100.5 (1982): 750-754.

9. Heimann H., *et al.* "Vasoproliferative tumors of the retina". *British Journal of Ophthalmology* 84 (2000): 1162-1169.
10. Pichi F., *et al.* "Vasoproliferative tumors in intermediate uveitis". *Retina* 40.9 (2020): 1765-1773.
11. W Saito., *et al.* "Expression of vascular endothelial growth factor and intravitreal anti-VEGF therapy with bevacizumab in vasoproliferative retinal tumors". *Retina* 33.99 (2013): 1959-1967.
12. Krivosic V., *et al.* "Management of idiopathic retinal vasoproliferative tumors by slit-lamp laser or endolaser photocoagulation". *American Journal of Ophthalmology* 158.1 (2014): 154-161.
13. Saito W., *et al.* "Expression of vascular endothelial growth factor and intravitreal anti-VEGF therapy with bevacizumab in vasoproliferative retinal tumors". *Retina* 33.9 (2013): 1959-1967.
14. F Manjandavida., *et al.* "Cryotherapy induced release of epiretinal membrane associated with retinal vasoproliferative tumor: analysis of 16 cases". *Retina* 34.8 (2014): 1644-1650.
15. Cebeci Z., *et al.* "Intravitreal dexamethasone implant (Ozurdex) and photodynamic therapy for vasoproliferative retinal tumours". *The Canadian Journal of Ophthalmology* 49.4 (2014): e83-e84.

Volume 14 Issue 1 January 2023

©All rights reserved by Bora Yüksel, *et al.*