

## Laser Surgery for Pigmentary Glaucoma

Fokin VP<sup>1</sup>, Balalin SV<sup>2,3\*</sup>, Sarkisyan AS<sup>4</sup> and Balalin AS<sup>4</sup>

<sup>1</sup>Director, Professor, Volgograd Branch of the S. Fedorov National Medical Research Center "MNTK "Eye Microsurgery", Volgograd, Russian Federation

<sup>2</sup>Head of the Scientific Department, Volgograd Branch of the S. Fedorov National Medical Research Center "MNTK "Eye Microsurgery", Volgograd, Russian Federation

<sup>3</sup>Professor at the Eye Disease Department, Volgograd State Medical University, 1 Ploshchad' Pavshikh Bortsov, Volgograd, Russian Federation

<sup>4</sup>Ophthalmologist, Volgograd Branch of the S. Fedorov National Medical Research Center "MNTK "Eye Microsurgery", Volgograd, Russian Federation

**\*Corresponding Author:** Balalin SV, Head of the Scientific Department, Volgograd Branch of the S. Fedorov National Medical Research Center "MNTK "Eye Microsurgery", and Professor at the Eye Disease Department, Volgograd State Medical University, 1 Ploshchad' Pavshikh Bortsov, Volgograd, Russian Federation.

**Received:** November 16, 2022; **Published:** December 23, 2022

### Abstract

**Purpose:** To analyze the efficacy of a complex technology of laser surgery for pigmentary glaucoma which consists of YAG-laser iridectomy in the first stage followed by multistage selective laser trabeculoplasty to achieve a mild pigmentation degree of the trabecula in 360°.

**Materials and Methods:** Laser iridectomy was performed in 19 patients (38 eyes) aged 18 to 54 years old with pigmentary glaucoma after achieving the values of the individual IOP level using drug therapy. Then after 4 weeks SLT was carried out. If an exogenous pigmentation was  $\geq 2$  st., SLT has been repeated several times every 4 - 6 months. Observation period: from 4 to 15 years.

**Results:** The glaucoma process stabilization was achieved in all cases. The level of true IOP decreased by  $6.6 \pm 0.3$  mm Hg (-30%,  $p < 0.05$ ), Becker's coefficient by  $121 \pm 4.3$  (-60%,  $p < 0.001$ ), the instillations number by  $0.57 \pm 0.09$  (-70%,  $p < 0.001$ ). The indicators increased: the average value of the total retinal photosensitivity by  $381 \pm 4.3$  dB (15%,  $p < 0.001$ ), the average threshold of the retinal photosensitivity by  $2.6 \pm 0.1$  dB (10%,  $p < 0.001$ ), the intraocular liquid outflow by  $0.08 \pm 0.013$  (72%,  $p < 0.001$ ). Drug hypotensive therapy was canceled at 16 eyes (42.1%).

**Conclusion:** The complex method of pigmentary glaucoma laser surgery in the form of YAG-laser iridectomy and the multistep SLT is effective and safe. It may be performed for a decrease of increased ophthalmotonus level to the individual IOP against the background of drug treatment.

**Keywords:** Pigmentary Glaucoma; YAG-Laser Iridectomy; Selective Laser Trabeculoplasty

### Introduction

Prophylaxis and treatment of glaucoma is a topical medical problem. Pigmentary glaucoma occurs in patients of younger, working age, and therefore is not only a medical but also a social problem [1].

Pigmentary dispersion syndrome plays the leading role in pigmentary glaucoma pathogenesis that is mostly caused by posterior iris prolapse with formation of back pupil block, friction between suspensory ligaments and iris pigment epithelium with pigment cells alteration and following pigment granules accumulation in trabecula that decreases the aqueous outflow, increases the intraocular pressure and glaucoma optic atrophy development [1-4].

Laser iridectomy has been successfully used to eliminate back pupillary block in pigmentary glaucoma [1,5].

Selective laser trabeculoplasty (SLT), which improves aqueous outflow due to photothermolysis of pigment granules on the trabecula, is widely used to reduce elevated intraocular pressure in primary open angle glaucoma [3,5-10].

A known method of complex treatment of pigmentary glaucoma includes selection of medications, laser iridectomy and a single selective laser trabeculoplasty. The authors recommend to perform laser treatment in the early and moderate stages of the disease [5].

Disadvantages of this method: the authors did not assess the effectiveness of photothermolysis of pigment granules and the residual degree of pigmentation after selective laser trabeculoplasty. In pigmentary glaucoma with pigmentary dispersion syndrome, degrees III-IV (intense and very intense) of pigmentation are usually observed and cannot be completely lysed after a single procedure of selective laser trabeculoplasty.

If medication and laser surgery are inefficient, patients with pigmentary glaucoma are recommended to undergo surgical treatment of glaucoma: microinvasive non-penetrating deep sclerectomy or sinus trabeculectomy. This surgery directs the movement of intraocular fluid through the surgical canal and reduces aqueous outflow along the trabecular pathway, resulting in its gradual obliteration.

In 2021 Sarkisyan AS, Balalin AS, Balalin SV proposed multistage laser surgery for pigmentary glaucoma: laser iridectomy and multistage SLT. The achievable clinical result consists in increasing efficacy and safety of pigmentary glaucoma treatment due to removing the pupillary block and improving the outflow of the intraocular fluid through the trabecular meshwork, reducing the number of instillations or canceling the use of medications to decrease the intraocular pressure. This was made possible by repeated stages of selective laser trabeculoplasty to maximize the effect of photothermolysis of pigment granules in the trabecular area [11].

Before laser surgery it is necessary to reach the target level of intraocular pressure against the background of medical treatment in order to perform all the necessary treatment steps later [12-15].

### Purpose of the Study

To analyze the efficacy of a complex technology of laser surgery for pigmentary glaucoma which consists of YAG-laser iridectomy in the first stage followed by multistage selective laser trabeculoplasty to achieve a mild pigmentation degree of the trabecula in 360°.

### Materials and Methods

A retrospective study of the treatment results of 19 patients (38 eyes) with primary open-angle pigmentary glaucoma was performed. Mean age: 32.8 ± 7.3 years (18 to 54 years). Men - 13 (26 eyes), women - 6 (12 eyes). Follow-up period: 4 to 15 years.

#### Inclusion criteria:

- Presence of pigment dispersion syndrome;
- pigmentary glaucoma stages I, II, III;
- CPC pigmentation of III-IV stages before treatment;
- Achievement of the target intraocular pressure using medical treatment.

**Exclusion criteria:**

- Terminal glaucoma;
- Previous surgical glaucoma treatment;
- Failure to achieve a target intraocular pressure on medication prior to SLT.

All patients underwent advanced ophthalmological examination before and after treatment, including determination of the best corrected visual acuity (Phoropter 16625B phoropter, Reichert/Leica, USA), tonometry (non-contact tonometer/pachymeter NT-530, NIDEK CO. LTD., Japan; Maklakov tonometer), static automated perimetry (Perigraph Pericom visual field measuring device, SPETSMEDPRIBOR SPA, Russia), ultrasound biometry (AVISO A/B, Quantel Medical Aviso, France), corneal pachymetry (ultrasound biometry on a Tomey AL 3000 A-B scanning system, Tomey Corp, Germany), biomicrophthalmoscopy (slit lamp “Takagi SM-70”, Japan), gonioscopy with three-mirror Goldman lens, tonography (tonograph “Glaustest 60”, Russia), determination of individually tolerable (target) level of intraocular pressure according to the table with regard to patient’s age and level of diastolic blood pressure in the brachial artery.

The method of laser surgery for pigmentary glaucoma was carried out as follows. After primary open-angle pigmentary glaucoma was detected in a patient, glaucoma medication was administered to reduce the increased ophthalmotonus to the target pressure. Then laser surgery was performed: laser iridectomy to eliminate back pupil block with iris prolapse detected by gonioscopy and ultrasound biomicroscopy. Then 4 weeks after laser iridectomy, selective laser trabeculoplasty was performed on ½ of trabecula.

One month after selective laser trabeculoplasty the hypotensive effect was assessed as well as the effectiveness of photothermolysis according to the degree of residual pigmentation. At the second and higher degrees of pigmentation, selective laser trabeculoplasty was repeated every 4 - 6 months until a weak degree of pigmentation (I degree) or its absence throughout the trabecular meshwork was obtained. The hypotensive effect of laser treatment was assessed under the control of tonometry and medications were corrected: injections of medications were reduced or completely cancelled.

Statistical processing was performed using STATISTICA 10 for Windows and Numbers for macOS for quantitative characteristics: true intraocular pressure (mm Hg), ease of outflow of intraocular fluid (mm<sup>3</sup>/min×mm Hg), minute aqueous humor volume (mm<sup>3</sup>/min), Becker ratio (BC), total retinal light sensitivity (dB), retinal light sensitivity threshold (dB) and number of instillations. Parametric analysis with determination of Student’s t-test and p-value level were used for data processing.

**Results**

The mean values of clinical and functional indices before and after laser surgery for pigmentary glaucoma are presented in table 1.

Indicators	Baseline	YAG-laser iridectomy + SLT	P
P <sub>o</sub> , mm Hg	22,4 ± 1,8	15,8 ± 2,1	< 0,05
C, mm <sup>3</sup> /min×mm Hg	0,11 ± 0,016	0,19 ± 0,003	< 0,001
F, mm <sup>3</sup> /min	0,9 ± 0,09	0,7 ± 0,07	> 0,05
P <sub>o</sub> /C	204 ± 24,9	83 ± 20,6	< 0,001
SSNS (dB)	2456 ± 44,9	2837 ± 40,6	< 0,001
PSChS (dB)	24,8 ± 0,4	27,4 ± 0,5	< 0,001
MD (dB)	-1,68 ± 2,5	-1,62 ± 2,5	> 0,05
PSD (dB)	1,82 ± 0,34	1,74 ± 0,35	> 0,05
Number of instillations	1,89 ± 0,15	0,57 ± 0,09	< 0,001

**Table 1:** Mean values of ocular hydrodynamics and static perimetry indices before and after complex laser treatment (YAG-laser iridectomy + SLT), M ± s.

After combined laser surgery of primary open angle pigmentary glaucoma in the form of YAG-laser iridectomy and multistage selective laser trabeculoplasty stabilization of glaucoma process was achieved in all cases. In 16 eyes (42.1%) drug hypotensive therapy was canceled. There were no complications in the intra- and postoperative period.

After combined laser surgery for pigmentary glaucoma in the form of YAG-laser iridectomy and multistage selective laser trabeculoplasty, the patients showed a reliable decrease of true intraocular pressure by  $6,6 \pm 0,3$  mmHg from the initial level by 30%, improvement of aqueous humor outflow to  $0,19 \pm 0,003$  mm<sup>3</sup>/min×mmHg by 72%. Improvement of ocular hydrodynamics indices was characterized by a subsequent reliable decrease of instillation rate from  $1.89 \pm 0.15$  to  $0.57 \pm 0.09$  - by 70%.

The indices of static automated perimetry increased significantly: mean value of total retinal photosensitivity by 113 points increased from  $2456 \pm 44.9$  to  $2837 \pm 40.6$  dB ( $t = 6.29$ ;  $p < 0.001$ ), mean value of retinal photosensitivity threshold increased from  $24.8 \pm 0.4$  to  $27.4 \pm 0.5$  dB ( $t = 4.1$ ;  $p < 0.001$ ).

**Clinical example**

Patient G., 23 years old, presented with the following complaints: gradual deterioration of vision in both eyes for a year, constant “rainbow circles”.

9.11. 2017 G. The patient underwent full diagnostic examination.

Visual acuity: VOD = 0.02 sph. - 6,0 D = 0,1; VOS = 0.01 sph. - 6,0 D = 0,05.

Results of ultrasound biometry on both eyes: OD - lens - 3.54 mm, anterior chamber depth - 3.57 mm; OS - lens - 3.54 mm, anterior chamber depth - 3.56 mm. Deep anterior chamber of the eye was noted on both eyes. Tonometric IOP: TOD = 30 mmHg; TOS = 28 mmHg.

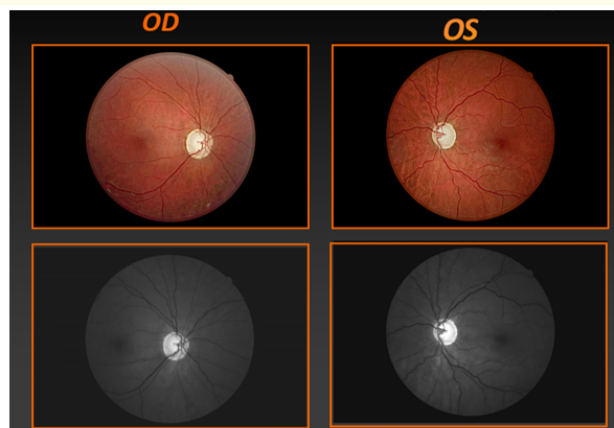
Tonography results: OD - P<sub>0</sub> = 25 mmHg, OS - P<sub>0</sub> = 23.2 mmHg.

C = 0.05 mm<sup>3</sup>/mmHg/min, C = 0.07 mm<sup>3</sup>/mmHg/min.


F = 1.97 mm<sup>3</sup>/min, F = 0.57 mm<sup>3</sup>/min.

P<sub>0</sub>/C = 514, P<sub>0</sub>/C = 331.

On ophthalmoscopy: OU - ONH is pale gray, borders are clear. E/D = 0.8. Marginal glaucoma excavation. Central area of the retina - moderate dyspigmentation.



**Figure 1:** Patient's fundus image.



**Figure 2:** OD, OS: Expressed pigmentation of the trabecula.

Static threshold perimetry data:

OD (2017): MD 24-2: -31.45 dB P < 0.5%; PSD 24-2: 5.71 dB P < 0.5%;


OS (2017): MD 24-2: -32.25 dB P < 0.5%; PSD 24-2: 6.21 dB P < 0.5%.

Based on the diagnostic data described above, the patient was diagnosed with pigmentary advanced (III b) glaucoma of both eyes.

Instillation of hypotensive drugs in both eyes was prescribed: Sol. Latanoprosti 0.005% 1 drop in the evening, Sol. Brinzolamidi 1% + Sol. Timololi 0.5% 1 drop 2 times a day.

Using the conservative hypotensive treatment the IOP OU was reduced to 11-15 mmHg.

After achieving the target pressure using medical treatment, complex laser surgery for pigmentary glaucoma was applied to both eyes in the form of YAG-laser iridectomy and multistage selective laser trabeculoplasty. Selective laser trabeculoplasty was performed on each eye 4 times, the interval between the stages was 6 months. No complications were detected.



**Figure 3:** OD, OS: Weak trabecular pigmentation after multistage SLT.

23.01.2020 G. Visual acuity on the background of instillation in the OU preparation Sol. Tafluprosti 0.0015% 1 drop in the evening:

VOD = 0.02 sph. concave - 6.0 D = 0.6; VOS = 0.01 sph. concave - 5.5 D = 0.5.

IOP OD = 11 mmHg, IOP OS = 10.5 mmHg.

Static threshold perimetry data with no negative trend:

OD (2021): MD 24-2: -29.46 dB P < 0.5%; PSD 24-2: 7.8 dB P < 0.5%;

OS (2021): MD 24-2: -32.21 dB P < 0.5%; PSD 24-2: 5.99 dB P < 0.5%.

At 2 months after cancelation of Sol. Tafluprosti 0.0015%: IOP OD = 13.0 mmHg, IOP OS = 12.5 mmHg.

### Discussion

YAG-laser iridectomy and selective laser trabeculoplasty are effective laser surgery techniques for pigmentary glaucoma due to elimination of pupillary refraction and improvement of the intraocular fluid outflow through the trabecular meshwork, resulting the decrease intraocular pressure using fewer instillations or cancelation of medications [5,11]. This is made possible through repeated stages of selective laser trabeculoplasty to maximize the effect of photothermolysis of pigment granules in the trabecular area [11]. Before laser surgery for pigmentary glaucoma it is necessary to achieve a target level of intraocular pressure using medical treatment, allowing the stabilization of visual function in glaucoma patients [12-15].

### Conclusion

Combined laser surgery for pigmentary glaucoma in the form of YAG-laser iridectomy and multistage selective laser trabeculoplasty is an effective and safe technique that can be performed provided the increased ophthalmotonus is reduced to the target intraocular pressure.

### Bibliography

1. National guide to glaucoma for practicing physicians. Edited by E.A. Egorov/M (2019): 384.
2. Egorov EAVN Alekseev. "Pathogenesis and treatment of primary open-angle glaucoma". M (2017): 224.
3. Erichev VP and Rogozina EA. "Selective laser trabeculoplasty as a starting method of primary open angle glaucoma treatment". *National Journal of Glaucoma* 19.1 (2020): 47-54.
4. Pasenova IG and Alekseeva KV. "Analysis of efficacy of selective laser trabeculoplasty". *Siberian Scientific Medical Journal* 39.3 (2019): 39-44.
5. Fabrikantov OL., et al. "Experience of combined laser treatment of pigmentary glaucoma". *Vestnik Ophthalmologii* 6 (2018): 68-71.
6. Kurysheva NI., et al. "Efficiency of selective laser trabeculoplasty in the treatment of various forms of glaucoma". *Glaucoma News* 1 (2017): 66-69.
7. Yablokova NV., et al. "Analysis of laser treatment of pigmentary glaucoma". *Vestnik of Tambov State University* 4 (2017): 751-756.
8. Latina MA and Park C. "Selective targeting of trabecular meshwork cells: in vitro studies of pulsed and CW laser interactions". *Experimental Eye Research* 60 (1995): 359-371.

9. Lee JW, *et al.* "Correlation of intraocular pressure between both eyes after bilateral selective laser trabeculoplasty in open-angle glaucoma". *Journal of Glaucoma* 25.3 (2016): 248-252.
10. Woo DM, *et al.* "Intraocular pressure- lowering medications and long-term outcomes of selective laser trabeculoplasty". *Clinical and Experimental Ophthalmology* 43 (2015): 320-327.
11. Sarkisyan AS, *et al.* "Complex technology of laser surgery of pigmentary glaucoma". *Modern Technologies in Ophthalmology* 2 (2021): 81-84.
12. Balalin SV and Fokin VP. "On the role of intraocular pressure in the diagnosis and treatment of primary open-angle glaucoma". *AMJ. Clinical Ophthalmology* 4 (2010): 36-43.
13. Fokin VP and Balalin SV. "Modern organizational and medical technologies in the diagnosis and treatment of primary glaucoma". *Ophthalmosurgery* 2 (2011): 43-49.
14. Fokin VP, *et al.* "Tolerance and intolerance of the optic nerve in primary open-angle glaucoma" (2016): 208.
15. Balalin SV, *et al.* "Software for determining the tolerant and target pressure in patients with primary open-angle glaucoma". *Clinical Ophthalmology* 4 (2013): 144-147.

**Volume 14 Issue 1 January 2023**

**©All rights reserved by Balalin SV., *et al.***