ECRONICON OPEN ACCESS

EC OPHTHALMOLOGY
Case Report

Pressure Induced Stromal Keratitis/Interface Fluid Syndrome: A Case Report and Updated Incidence

Karl Stonecipher*, Joseph Parrish and Amy Tippin

Clinical Professor of Ophthalmology, University of North Carolina, Clinical Adjunct Professor of Ophthalmology, Tulane University, USA

***Corresponding Author:** Karl Stonecipher, Clinical Professor of Ophthalmology, University of North Carolina, Clinical Adjunct Professor of Ophthalmology, Tulane University, USA.

Received: May 30, 2022; **Published:** June 29, 2022

DOI: 10.31080/ecop.2022.13.00913

Abstract

The authors present a case report of a patient with pressure induced stromal keratitis (PISK) also known as Interface fluid syndrome (IFS) after laser assisted *in-situ* keratomileusis (LASIK) which resolved with discontinuation of the corticosteroids and institution of pressure lowering pharmaceuticals. The incidence with corticosteroids surrounding LASIK has been as high as 2.9% but with newer corticosteroid formulations the incidence is reported as 0.039% (31/80147).

Keywords: *Pressure Induced Stromal Keratitis (PISK); Interface Fluid Syndrome (IFS); Laser Assisted In-Situ Keratomileusis (LASIK)*

Introduction

Pressure induced stromal keratitis (PISK) or Interface Fluid Syndrome is a rare complication after laser assisted *in-situ* keratomileusis (LASIK). The syndrome known as Pressure Induced Stromal Keratitis (PISK) or also known as interface fluid edema syndrome is uncommon and often confused with diffuse lamellar keratitis (DLK) [1-6]. When the patient is considered to have DLK or nonspecific haze the first therapeutic is usually to increase the steroid which makes PISK or IFS worse for differentiation of the two items is imperative. Diffuse lamellar keratitis is a sterile inflammation of the cornea whereas PISK is actual interface fluid related to the increased intraocular pressure from the steroid induced pressure rise.

Case Report

A 37-year-old nurse was referred for LASIK. Her manifest refraction was -1.75 spherical OU with 20/20 BCVA OU. Her past ocular history is only significant that her mother has a history of glaucoma and her referring physician notes her cup to disc ratio is 0.45 OD and 0.55 OS. Visual fields were normal. She underwent Topographic Guided LASIK without issues and on postoperative day one she was 20/15 in the eyes individually and 20/15 OU UCVA. CustomVue wavefront analysis preoperatively is seen in figure 1.

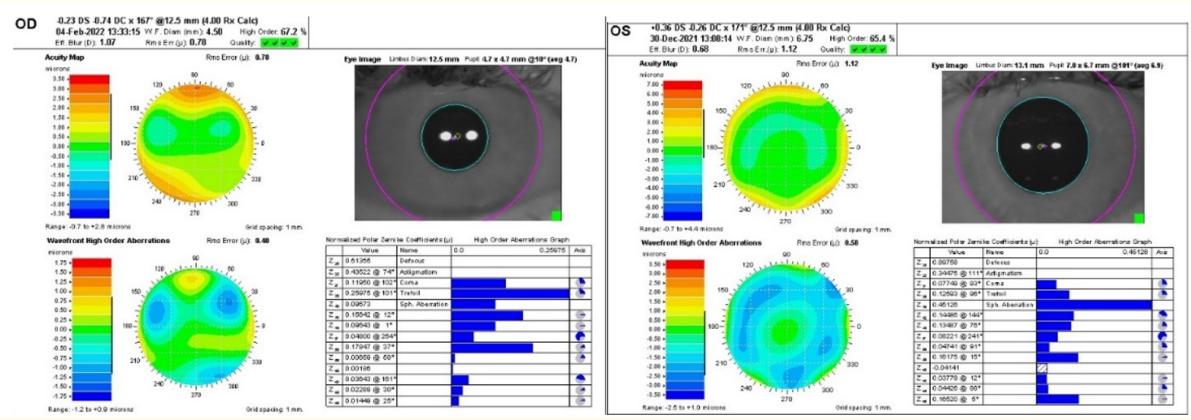

Figure 1: *Preoperative CustomVue: (A) OD (B) OS.*

Three months later the referring doctor was concerned because the right eye is now 20/40 UCVA and the left eye is 20/20-2 UCVA. The patient says her vision is much worse than immediately after surgery. The vision did not improve with manifest refraction. The referring physician note shows the IOP OD is 17 mmHg and 18 mmHg. The doctor reported haze in the right eye more than the left eye which they are treating with Sodium Chloride 5% (Bausch Health, Bridgewater, NJ) solution OU four times per day and loteprednol ophthalmic gel 0.38% (Bausch Health, Bridgewater, NJ) four times per day OU without resolution or improvement. No other complaints of symptoms or subjective findings are reported by the referring doctor or patient.

The first diagnostics we looked at are seen in figure 2. We wanted to compare preoperative Pentacam images with the postoperative appearance upon referral. Figure 3 shows the postoperative appearance of the flap and it is noticeably thickened.

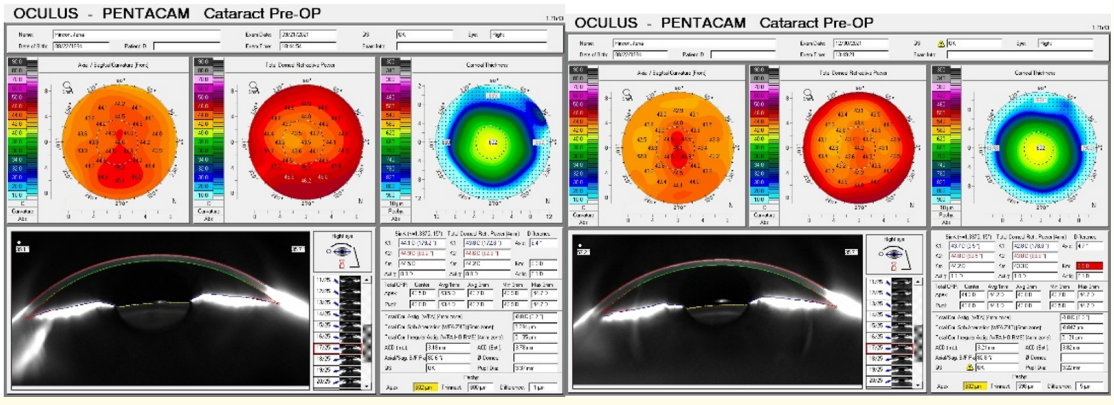

Figure 2: *Preoperative (A) versus postoperative (B) Pentacam analysis of the right eye shows increased astigmatism and no change in the overall corneal thickness despite having had LASIK.*

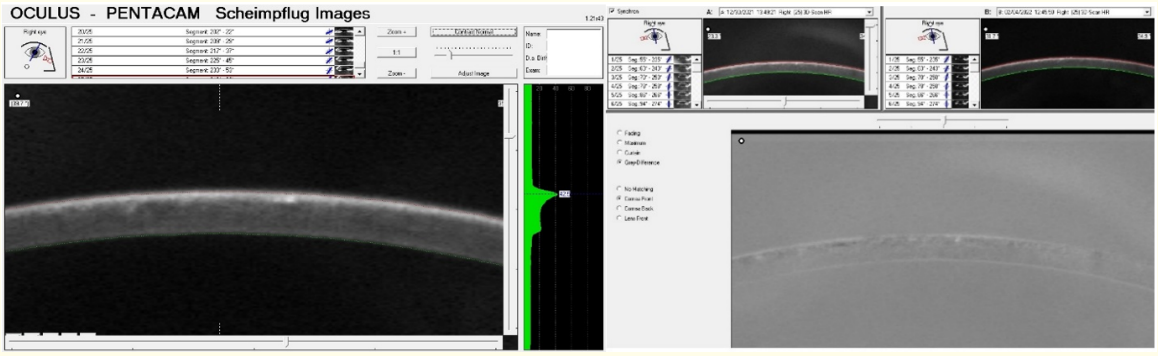

Figure 3: *Pentacam image at higher magnification showing thickening of the flap (A). In Figure (B) the negative shows interface fluid.*

We did an off flap IOP measurement with the ICare (Icare, Raleigh, NC, USA) device and the off flap IOP registered 40 mmHg OD and 32 mmHg OS. The cornea had a "peau d' orange" appearance to it and no other significant systemic findings other than new onset daily headaches with no previous history of headaches or headache disorders familial or otherwise. Immediately, we stopped the corticosteroids and the sodium chloride treatments and started brimonidine/timolol ophthalmic 0.2%/0.5% (Allergan/AbbVie, North Chicago, IL, USA) twice per day and latanoprostene bunod ophthalmic (Bausch Health, Bridgewater, NJ, USA) at bedtime. She was seen by her local physician who followed her off-axis pressures diligently and after two months of treatment her vision returned to a clear 20/20 OU with manifest refraction -0.25+0.25 x 047 OD and Plano OS. Her off-axis pressures were 18 mmHg OU. She returned six months from the initial visit and maintained intraocular pressures of 20 mmHg OU off-axis and 20/20 uncorrected vision OU off her previous medications and happy with her vision and clarity of her vision. Figure 4 shows the topographic changes side by side and the patient reported markedly improved vision. Slit lamp examination showed resolution of the previous findings.

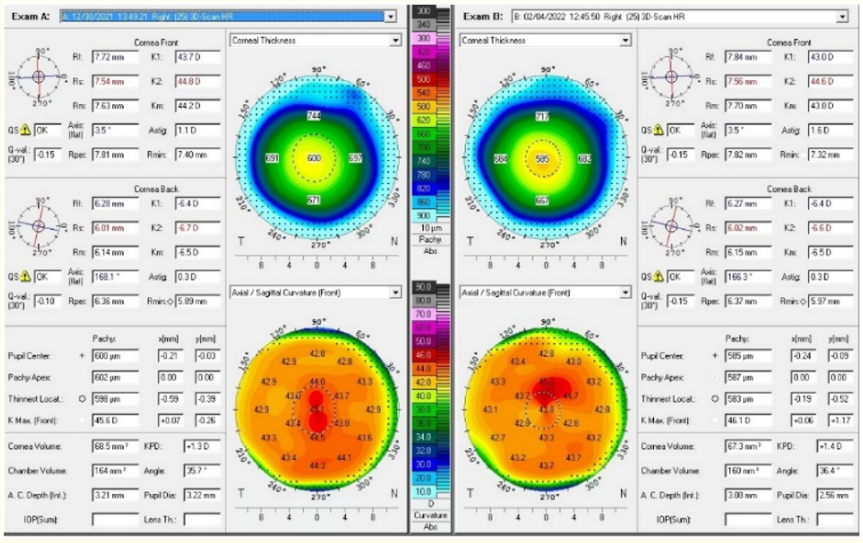

Figure 4: *In this figure we see the resolution of the corneal thickening and a change in the overall topography.*

Discussion and Conclusion

PISK or IFS usually results from increased intraocular pressure (IOP) that is triggered from postoperative steroid use [7,8]. However, any condition that increases IOP is a potential cause of PISK or IFS in patients with prior LASIK or SMILE surgery. The incidence has been reported to be as high as 2.9% (102/3489) [9,10].

The author did a complete chart review and have had thirty-one cases in 80,147 cases of LASIK by a single surgeon (KGS) for an incidence of 0.039% or 1/2500. The main issue for delayed diagnosis is related to on flap pressure measurements being inaccurate as it was in this case. Either tactile or off flap IOP measurements can help with the diagnosis. With high resolution OCT you can pick up the interface fluid in some cases but not all. Many of the patients have a history of steroid induced IOP rise and or a family history of glaucoma as was in this case. In all cases we have diagnosed and treated the issues resolved with treatment of the increased pressure with topical drops. The treatment should be continued until total resolution of the signs and symptoms.

Consents

Patient consents to publish personal information and case details.

Disclosures

No funding or grant support.

Conflicts of Interest

None.

Authorship

All authors attest that they meet the current ICMJE criteria for authorship.

Bibliography

1. Portellinha W., *et al*. "Interface fluid and diffuse corneal edema after laser *in situ* keratomileusis". *Journal of Refractive Surgery* 17.2 (2001): S192-S195.
2. Lyle WA., *et al*. "Interface fluid after laser *in situ* keratomileusis". *Journal of Refractive Surgery* 19.4 (2003): 455-459.
3. Belin MW., *et al*. "Elevated intraocular pressure-induced stromal keratitis". *Ophthalmology* 109.10 (2002): 1929-1933.
4. Galal A., *et al*. "Interface corneal edema secondary to steroid-induced elevation of intraocular pressure simulating diffuse lamellar keratitis". *Journal of Refractive Surgery* 22.5 (2006): 441-447.
5. Tourtas T and Cursiefen C. "PISK-itis or PISK-opathy?" *Cornea* 31.2 (2012): 107.
6. Galvis V., *et al*. "LASIK interface complications: What is the appropriate term for PISK?" *Journal of Refractive Surgery* 29.2 (2013): 81.
7. Randleman JB and Shah RD. "LASIK interface complications: etiology, management, and outcomes". *Journal of Refractive Surgery* 28 (2012): 575-586.

8. Bamashmus MA and Saleh MF. "Post-LASIK interface fluid syndrome caused by steroid drops". *Saudi Journal of Ophthalmology* 27.2 (2013): 125-128.

9. Gab-Alla AA. "Incidence of interface fluid syndrome after laser in situ keratomileusis in Egyptian patients". *Clinical Ophthalmology* 11 (2017): 613-618.

10. https://eyewiki.aao.org/Interface_Fluid_Syndrome

Volume 13 Issue 7 July 2022