

Suture of a Plate-Type Intraocular Lens in the Absence of a Capsular Bag. A Case Report

Meza-Anguiano Alonso*, Romo-García Efraín, Paz-Camacho Silvia, Gutiérrez-Ruiz Gilberto Noé and Quiñonez-Quiñonez Wilehaldo

Hospital Oftalmológico de Sinaloa "Dr. Efraín Romo Santos", Fundación Buena Vista I.A.P, México

***Corresponding Author:** Meza-Anguiano Alonso, Hospital Oftalmológico de Sinaloa "Dr. Efraín Romo Santos", Fundación Buena Vista I.A.P, México.

Received: December 03, 2021; **Published:** January 28, 2022

Abstract

The management of lens subluxation has changed over time. We present a novel technique for plate-type folding intraocular lens suture such as the CT Spheris 204 (Carl Zeiss, Germany) for patients where there is no capsular bag.

Keywords: *Marfan Syndrome; Subluxation Lens; Iol Suture; Intraocular Lens*

Abbreviations

IOL: Intraocular Lens; MS: Marfan Syndrome; BCVA: Best Corrected Visual Acuity; RE: Right Eye; LE: Left Eye; CA: Anterior chamber; M: Meridians; D: Diopters

Introduction

The management of lens subluxation has changed over time, options such as limbus[1,2], transciliary [3], and pars plana [4-8] lensectomy have been explored. In addition, contact lenses [9], open loop anterior chamber lens [5,7], retro pupillary fixation lens [10], pre-pupillary fixation lens "Artisan" [11,12], and also have been used in optical correction non-folding [6] and silicone [9] type scleral sutured lenses. We present a novel technique for plate-type folding intraocular lens (IOL) suture such as the CT Spheris 204 (Carl Zeiss, Germany) for patients where there is no capsular bag.

Presentation of the case

23-year-old female patient, reason for consultation under visual right eye of 13 years of evolution, without significant inherited-family history, diagnosis of Marfan syndrome (MS) 15 years ago. Best Corrected Visual Acuity (BCVA): Right Eye (RE): 20/800 Left Eye (LE): 20/20.

RE: Transparent cornea without alterations, wide anterior chamber (CA), central round pupil brown iris with non-reactive midris, lens subluxed towards M9 temporal region (Figure 1.A), funduscopy without alterations.

LE: transparent cornea, formed AC, brown iris with normoreactive central pupil, transparent central lens, funduscopy: no alterations.

Materials and Methods

Lens suturing technique

Under retro-bulbar block, placement of iris hooks, lensectomy and anterior-posterior vitrectomy via pars plana with 23 g caliber was performed, endolaser was applied to the peripheral retina at 360°. Upper and lower conjunctival peritomy is performed, scleral tunnels at 2 mm from the limbus in meridians (M) 12 and 6, with a Crescent type knife, a 2.8 mm corneal port is performed, accessory ports with a 15 knife in M12 and M6, it is filled anterior chamber with viscoelastic, IOL implant type CT Spheris 204 leaving it in CA. A 10-0s prolene-type suture is introduced through the M6 sclerotomy with a straight needle, passing it between the opening of the plate guided by a 30G needle, leaving via the clear cornea and returning through the same corneal orifice towards the initial sclerotomy, anchoring the suture to the sclera and knotting it. He repeated the procedure with the other end of the IOL, suturing it to the sclera at M12. Knots are tightened and the IOL is centered, leaving it in the posterior chamber (Figure 1.B-J)

Results and Discussion

The BCVA in the postoperative period 1 month after surgery was 20/150, with a spherical equivalent of -0.87 Diopters (D), a lens of +12.00 D was placed, corroborating its position and aligned by Optical Coherence Tomography of the anterior segment. (Figure 2) The little visual improvement is due to the amblyopia that developed secondary to the years that the eye remained with the lens subluxed.

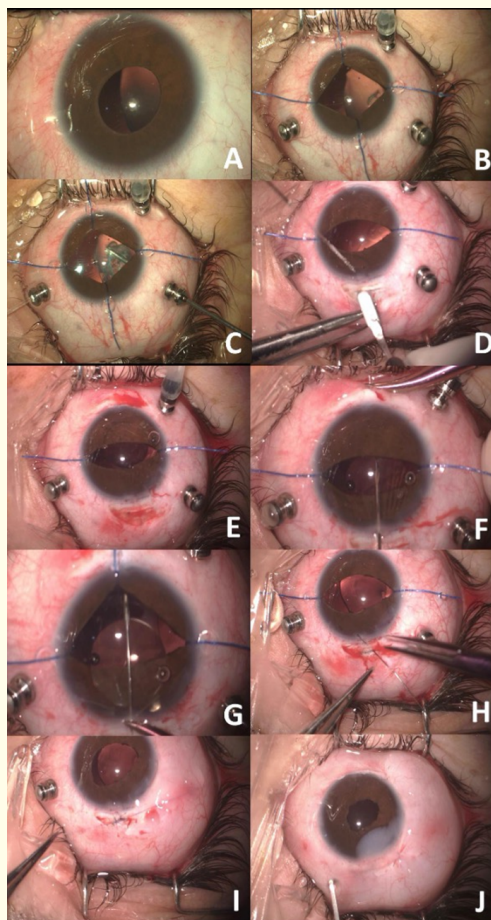


Figure 1: Pre-surgical appearance seen by the surgeon (A), prior to the start of vitrectomy (B), pars plana lensectomy (C), scleral tunnel in meridian 12 (D), implantation of intraocular lens in anterior chamber (E), lens suture initiation, passing M6 needle through lens holes, guided with 30G needle (F), needle return via clear cornea through lens hole to scleral tunnel (G), suture anchored to sclera (H), scleral tunnel suture (I), final aspect (J).




Figure 1: Optical Coherence Tomography of the anterior segment, a lens is observed in a retro-iridinal position.

Conclusion

Intraocular lens suture has been described in patients with MS, in whom there is no capsular bag, but the suture of foldable lenses in a hydrophilic acrylic plate type monoblock is a novel technique and represents a theoretical advantage in a decrease in the endothelial cell loss compared to anterior chamber lenses.

Conflict of Interest

The authors declare that we have no conflict of interest.

Bibliography

1. Behki R., *et al.* "Limbal lensectomy in the management of ectopia lentis in children". *Archives of Ophthalmology* 108 (1990): 809-811.
2. Manning S., *et al.* "Outcomes after lensectomy for children with Marfan syndrome". *Journal of AAPOS* 20 (2016): 247-251.
3. Glinchuk I and Kiselev AV. "The results of removing a transparent lens in Marfan's syndrome". *Oftalmol Zh* (1988): 142-144.
4. Guo XM., *et al.* "Pars plana lensectomy and anterior vitrectomy for the treatment of congenital subluxated lenses". *Zhonghua Yan Ke Za Zhi* 30 (1994): 271-273.
5. Koenig SB and Mieler WF. "Management of ectopia lentis in a family with Marfan syndrome". *Archives of Ophthalmology* 114 (1996): 1058-1061.
6. Omulecki W., *et al.* "Pars plana vitrectomy, lensectomy, or extraction in transscleral intraocular lens fixation for the management of dislocated lenses in a family with Marfan's syndrome". *Ophthalmic Surgery, Lasers and Imaging Retina* 29 (1998): 375-379.

7. Morrison D., *et al.* "Anterior chamber intraocular lens (ACIOL) placement after pars plana lensectomy in pediatric Marfan syndrome". *Journal of AAPOS* 9 (2005): 240-242.
8. Fan F., *et al.* "Risk factors for postoperative complications in lensectomy–vitrectomy with or without intraocular lens placement in ectopia lentis associated with Marfan syndrome". *British Journal of Ophthalmology* 98 (2014): 1338-1342.
9. Tsai YY and Tseng SH. "Transscleral fixation of foldable intraocular lens after pars plana lensectomy in eyes with a subluxated lens". *Journal of Cataract and Refractive Surgery* 25 (1999): 722-724.
10. Faria MY., *et al.* "Retropupillary iris-claw intraocular lens in ectopia lentis in Marfan syndrome". *International Medical Case Reports Journal* 9 (2016): 149.
11. Malekifar P., *et al.* "Visual Outcomes after Lensectomy and Iris Claw Artisan intraocular Lens Implantation in Patients with Marfan syndrome". *Bina Journal of Ophthalmology* 21 (2016): 243-248.
12. Rabie HM. "Visual outcomes after lensectomy and iris claw artisan intraocular lens implantation in patients with Marfan syndrome". *International Ophthalmology* 37 (2017): 1025-1030.

Volume 13 Issue 2 February 2022

© All rights reserved by Meza-Anguiano Alonso, *et al.*