ECRONICON OPEN ACCESS

EC OPHTHALMOLOGY
Case Report

Successful Conservative Treatment of Epiretinal Membrane in an Elderly Patient

SA Ignatiev[1], MB Ro[2], SV Simonova[3] and AI Listratov[4]*

[1]Consulting Department, City Clinical Hospital Named by S. P. Botkin, Department of Health, Moscow, Russian Federation

[2]Moscow City Ophthalmological Center, City Clinical Hospital Named by S. P. Botkin, Department of Health, Moscow, Russian Federation

[3]State Budgetary Institution of Moscow "Research Institute of Healthcare Organization and Medical Management of the Moscow Department of Health"

[4]Federal State Budgetary Educational Institution of Further Professional Education Russian Medical Academy of Continuous Professional Education, Ministry of Healthcare of the Russian Federation, Moscow, Russian Federation

***Corresponding Author:** AI Listratov, Federal State Budgetary Educational Institution of Further Professional Education Russian Medical Academy of Continuous Professional Education, Ministry of Healthcare of the Russian Federation, Moscow, Russian Federation.

Received: October 10, 2021; **Published:** October 29, 2021

Abstract

The epiretinal membrane is a widespread disease that which is an active proliferation of cellular elements. This disease may result in decreased visual acuity and vision distortion. Currently, many researchers are turning their attention to the role of inflammation in the formation of epiretinal fibrosis. Surgical treatment is not always indicated, as it can lead to complications. We present a case of successful conservative treatment of the epiretinal membrane using a peptide bioregulator and a non-steroidal anti-inflammatory drug in the form of eye drops.

Keywords: *Epiretinal Fibrosis of the Eye; Epiretinal Membrane; Conservative Treatment*

Introduction

Epiretinal membrane (ERM) is a commonly occurring disease, affecting the posterior pole of the retina over the macula. ERM is a widespread disorder of the posterior pole of the eye. It looks like a translucent formation in which there are no vessels and it is located above the internal limiting membrane (ILM). ERMs consist of proliferation of the fibroblasts on the surface of the retina, with or without affecting it. They contain reactive cellular elements, vitreous structures, and fibrotic components [1]. ERM has many terms, one of the most used and pathogenetically reasonable is epiretinal fibrosis or epiretinal gliosis [2]. It may result in decreased visual acuity and vision distortion.

Etiology

The etiology of ERM is not completely established, it is believed that the most common form is idiopathic. Secondary epiretinal fibrosis results from various causes. These include mechanical damage to the eye, surgical and laser procedures, occlusion of the central retinal vein, diabetes, inflammatory and malignant intraocular processes [3].

Epidemiology

About 1/5 of all elderly patients suffer from ERM [2]. Cases are believed to be around 30 million in the entire US population over 43 years old [4].

Pathogenesis

It is believed that the pathogenesis of epiretinal fibrosis is based on cell migration and proliferation of the inner surface of the retina [5].

The processes that form the basis of secondary ERM, as well as their launching factors, are unknown. These processes have been studied in many studies, several theories have been proposed to explain them [5]. Several theories about the role of glial cells, fibroblasts, hyalocytes is discussed. The main theories include migration or proliferation of these cells. According to these theories, idiopathic epiretinal fibrosis is a consequence of superficial lesions that form in the ILM. As a result, glial cells, as well as other cells, move through these lesions, and then they proliferate on the internal membrane [6]. Furthermore, various cytokines of vitreous fluid are important in the pathogenesis of the disease. However, the types of cells involved in the formation of ERM, as well as the processes by which these cells migrate, are still being studied. Also noteworthy is the fact that collagen deposition is observed in the ERM, therefore, fibrosis also plays a role.

Some theories speculate that pathogenesis of iERM involve inflammation [6]. According to C. Gilbert., *et al.* [7], there is compelling clinical, histological and experimental signs that inflammatory processes are important in the formation of ERM. Other studies have shown that cytokines and growth factors play a leading role in the formation of epiretinal fibrosis. This is due to their functions required for signal transmission between cells and for tissue changes [8]. A number of growth factors are involved in the pathogenesis of epiretinal fibrosis. According to Iannetti., *et al*. [8], TGFβ2 (Transforming growth factor-beta 2) plays a significant role in the pathogenesis of ERM. This growth factor promotes ERM contraction due to the differentiation of hyalocytes into fibroblasts. Results by Kohno., *et al.* [9] also contribute to these observations. Another growth factor, VEGF (Vascular endothelial growth factor) is one of the key in many processes. Its role in the formation of epiretinal fibrosis is also supported by several studies [10,11].

Posterior Vitreous Detachment (PVD) and epiretinal fibrosis of the other eye are significant predictors of ERM development. According to a systematic review, the risk of developing this disease is increased in the female population as well as in the elderly [12].

Complications of ERM

The consequences of ERM can be conditions such as cataract, retina and macula lesions, bleeding complications and some others [2].

The main strategies for managing patients with this disease are monitoring and surgery [2]. Surgical management includes vitrectomy with ERM and ILM peeling [2]. This treatment can lead to various complications. Many patients experienced progression of cataracts after surgery [13]. In some cases, there was a decrease in visual acuity. Retinal breaks and detachments may also occur [14]. Sometimes complications are endophthalmitis, and macular hole formation [15,16]. Consequently, due to the complications encountered in surgical treatment, it is necessary to search for new methods of conservative treatment. New therapies should be based on the pathogenesis of the disease. According to the literature, one of the main pathophysiological processes leading to the formation of ERF is inflammation. Therefore, non-steroidal anti-inflammatory drugs (NSAID) can be effective in treating this disease.

Case Presentation

A 59-year-old female patient was admitted to our hospital with complaints of decreased vision in her right eye in November 2018. The week before, she had suffered from herpes simplex with rashes on her lips.

Visual acuity

- Visus OD = 20/63 co sph +1,5D = 20/32.
- Visus OS = 20/50 co sph +1,5D = 20/20.

Examination of the fundus of the right eye revealed retinal edema in the macular zone, coarse maculofibrosis with retinal folding, vitreoretinal adhesions, mild hemorrhages at the optic nerve head, along the superior temporal vascular bundle (Picture 1).

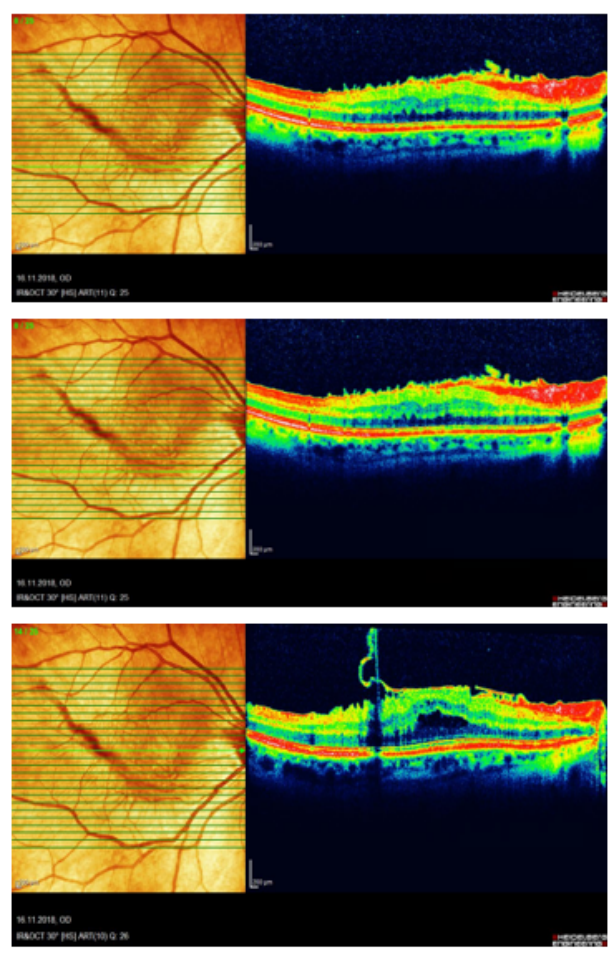

Picture 1: *Optical coherence tomography (OCT) scans before treatment initialization. There are coarse retinal folds, a fibrinous cord running obliquely in the paramacular region.*

Prescribed drug treatment

NSAID in the form of eye drops Nevanac® (Alcon-Couvreur n.v) 1 drop 3 times a day in the right eye for 2 months.

Peptide bioregulator Normoftal®, capsules, 1 caps. 2 times a day 1 for 1 month.

Vitamin complex Retinorm® 1 caps. 3 times a day for 3 months.

Three months after conservative therapy and monitoring:

- Visus OD = 20/40 sph +1,5D= 20/20.
- Visus OS = 20/40 sph +1,5 D= 20/20.

Funduscopic examination of the right eye: Vitreophoveolar adhesion was resolved, there is residual cystic retinal edema in the paramacular zone, detachment of the posterior vitreous membrane as a result of resolution of preretinal fibrosis.

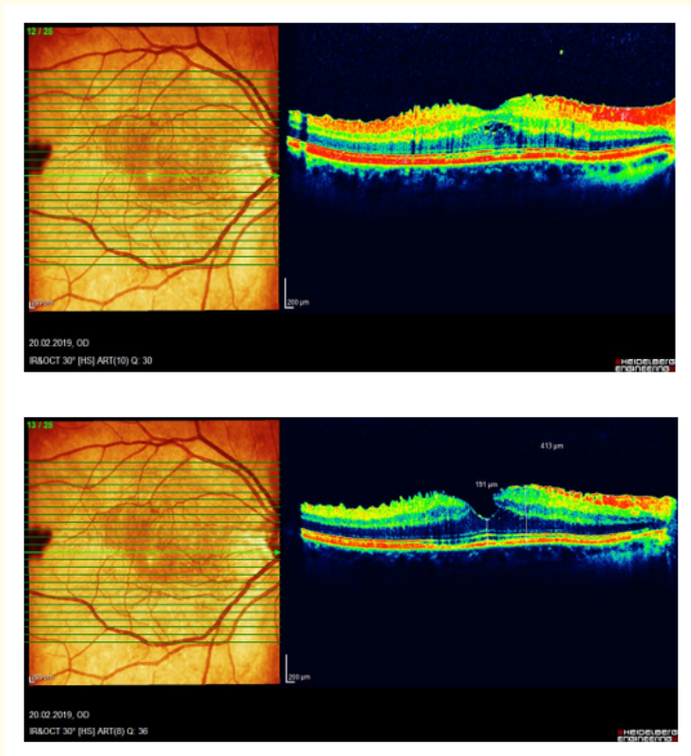

Picture 2: *OCT scans three months later. The fibrosis was significantly reduced. A blind hole was formed in the.*

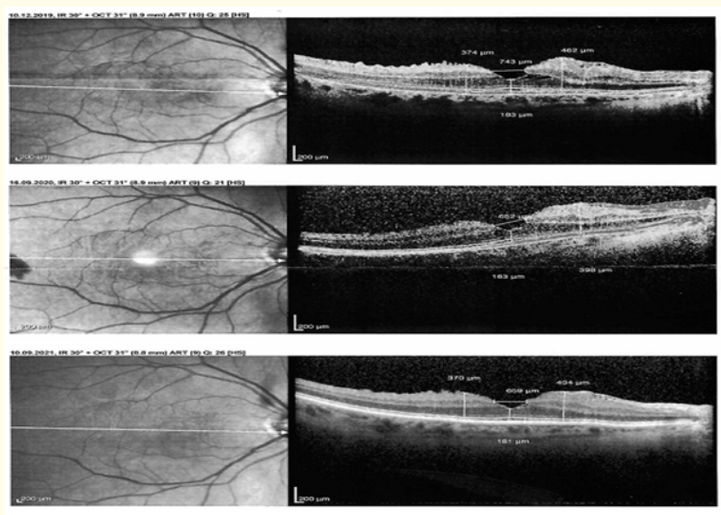

Picture 3: *OCT scans after three years with long-term observation. There is a positive trend. There is no fibrosis. A decrease in the thickness of the blind hole of the macular region is observed.*

Further, the patient was monitored with a frequency of visits 1 time in 6 months. The visits were in August 2019, February 2020, August 2020 and September 2021. No negative dynamics was found, the visual acuity of the right eye remains at the same level.

Conclusion

Thus, this case presentation demonstrates the possibilities of conservative treatment using a peptide bioregulator and NSAIDs. Nepafenac® in the form of eye drops with a long course of treatment and a vitamin complex helps to achieve a positive result without surgical treatment. This method will be of particular clinical significance in the elderly population. This is due to the fact that surgical treatment on the retina is not always possible due to a number of concomitant diseases in this group of patients (diseases of the cardiovascular system, previous vascular diseases of the brain, endocrine diseases, etc.).

In addition, the role of the inflammatory factor in the development of this disease was confirmed, which is consistent with the results in the literature.

Bibliography

1. Steel DHW., *et al*. "Idiopathic vitreomacular traction and macular hole: a comprehensive review of pathophysiology, diagnosis, and treatment". *Eye* 27.1-1 (2013): S1-21.
2. Kanukollu VM., *et al*. "Epiretinal Membrane". In: StatPearls. Treasure Island (FL): StatPearls Publishing (2021).
3. Flaxel CJ., *et al*. "Idiopathic Epiretinal Membrane and Vitreomacular Traction Preferred Practice Pattern®". *Ophthalmology* 127.2 (2020): P145-P183.
4. Klein R., *et al*. "The epidemiology of epiretinal membranes". *Transactions of the American Ophthalmological Society* 92 (1994): 403-425.
5. Tsotridou E., *et al*. "A Review of Last Decade Developments on Epiretinal Membrane Pathogenesis". *Medical Hypothesis, Discovery and Innovation Ophthalmology Journal* 9.2 (2020): 91-110.
6. Mandal N., *et al*. "Proteomic analysis of human vitreous associated with idiopathic epiretinal membrane". *Acta Ophthalmologica* 91.4 (2013): e333-e334.
7. Gilbert C., *et al*. "Inflammation and the formation of epiretinal membranes". *Eye* 2 (1988): S140-156.
8. Iannetti L., *et al*. "Role of the intravitreal growth factors in the pathogenesis of idiopathic epiretinal membrane". *Investigative Ophthalmology and Visual Science* 52.8 (2011): 5786-5789.
9. Kohno R., *et al*. "Possible contribution of hyalocytes to idiopathic epiretinal membrane formation and its contraction". *The British Journal of Ophthalmology* 93.8 (2009): 1020-1026.
10. Mandelcorn E., *et al*. "Idiopathic epiretinal membranes: cell type, growth factor expression, and fluorescein angiographic and retinal photographic correlations". *Canadian Journal of Ophthalmology Journal Canadien D'ophtalmologie* 38.6 (2003): 457-463.
11. Chen YS., *et al*. "Localisation of vascular endothelial growth factor and its receptors to cells of vascular and avascular epiretinal membranes". *The British Journal of Ophthalmology* 81.10 (1997): 919-926.
12. Xiao W., *et al*. "Prevalence and risk factors of epiretinal membranes: a systematic review and meta-analysis of population-based studies". *BMJ open* 7.9 (2017): e014644.
13. De Bustros S., *et al*. "Vitrectomy for idiopathic epiretinal membranes causing macular pucker". *The British Journal of Ophthalmology* 72.9 (1988): 692-695.

14. Tarantola RM., *et al*. "Intraoperative sclerotomy-related retinal breaks during 23-gauge pars plana vitrectomy". *Retina* 33.1 (2013): 136-142.

15. Park SS., *et al*. "Posterior segment complications after vitrectomy for macular hole". *Ophthalmology* 102.5 (1995): 775-781.

16. Rush RB., *et al*. "Postoperative macular hole formation after vitrectomy with internal limiting membrane peeling for the treatment of epiretinal membrane". *Retina* 34.5 (2014): 890-896.

Volume 12 Issue 11 November 2021