ECRONICON OPEN ACCESS

EC OPHTHALMOLOGY
Research Article

OCT Findings in Patients with COVID-19 in a Third Level Hospital

José R Mier-Bolio[1]*, Jhovan E López-Camacho[2], Juan D De la Torre-Tovar[3], Elizabeth Baques-Guillén[4], José M Arroyo-González[4] and Gerardo Rivera-Arroyo[5]

[1]*Second-Year Retina and Vitreous Fellow of the Central Military Hospital, Miguel Hidalgo, Mexico City, Mexico*

[2]*Ophthalmology Resident of the Military Graduate School of Health, University of the Army and Air Force, Mexico City, Mexico*

[3]*Head of the Ophthalmology Service of the Central Military Hospital, Miguel Hidalgo, Mexico City, Mexico*

[4]*A Physician Attached to the Retina and Vitreous Service of the Central Military Hospital, Miguel Hidalgo, Mexico City, Mexico*

[5]*Head of the Retina and Vitreous Service of the Central Military Hospital, Miguel Hidalgo, Mexico City, Mexico*

***Corresponding Author:** José R Mier-Bolio, Second-Year Retina and Vitreous Fellow of the Central Military Hospital, Miguel Hidalgo, Mexico City, Mexico.

Received: September 24, 2021; **Published:** October 27, 2021

Abstract

Objective: To determine the findings using OCT in patients diagnosed with COVID-19, at the Central Military Hospital in Mexico City.

Material and Methods: Observational, descriptive, transversal and prospective study, in which spectral domain OCT was performed on patients diagnosed with SARS-CoV-2 to obtain the thicknesses of: nerve fiber layer, macular thickness, ganglion cell complex and choroidal thickness.

Results: 64 eyes from 32 people were studied, 26 (81%) male and 6 (19%) female. The average age was 44±12 years. Near visual acuity in 75% of the population was 0.0 in logMAR units. The average thicknesses measured in (SD) that were obtained by OCT were the following: ganglion cell complex 79 µm ± 9 µm, macular thickness 246 µm ± 21 µm, choroidal thickness 69 µm ± 18 µm and nerve fiber thickness 97 µm ± 12 µm. In 57% of the eyes assessed, hyperreflective images were observed, which are located between the layer of nerve fibers and ganglion cells. The frequency of ocular symptoms in the whole population was 16%. Data were collected from prognostic markers of the disease, which were based on C-reactive protein, D-dimer and lymphocyte count.

Conclusion: In this study, no OCT alterations secondary to SARS-CoV-2 were found.

Keywords: *COVID-19; Tomographic Findings; Hyperreflective Lesions; Optical Coherence Tomography*

Introduction

More than a year after the first case of atypical pneumonia secondary to the new SARS-CoV-2 virus, the cause of the current COVID-19 pandemic, which has been strongly linked to the area of ophthalmology [1-3]. Starting with his first reports by the ophthalmologist, Dr. Li Wenliang in Hubei province, China [1].

Currently, the possibility of multi-organ involvement by COVID-19 is known, in which the ocular involvement is not the exception [4]. The virus has recently been isolated by means of conjunctival swabs and the ocular route has been described as a possible route of systemic infection [5,6]. Some of the ocular manifestations that have been documented are: conjunctivitis, epiphora, chemosis and a case of central retinal artery occlusion [7-9].

Optical coherence tomography (OCT) is an auxiliary ophthalmological study with important characteristics and properties: it is a non-contact, non-invasive study, quick to perform, with high diagnostic potential thanks to its excellent penetration and high resolution, which are comparable with histological sections. OCT has previously been used for the diagnosis of eye diseases such as: alterations of the vitreoretinal interface, glaucoma, diabetes, pathologies of the macula, Alzheimer's, various retinal viral infections among many other pathologies [10-15].

Purpose of the Study

The purpose of the study is to describe the findings in optical coherence tomography in patients affected by COVID-19.

Materials and Methods

An observational, descriptive, cross-sectional and prospective study was carried out in 33 hospitalized patients with a diagnosis of COVID-19, who met the selection criteria, at the "Central Military Hospital" in July 2020 in Mexico City.

The inclusion criteria established were: both sexes, diagnosis of COVID-19 by nasopharyngeal swab technique (RT-PCR), hemodynamically stable, older than 18 years, clear ocular media, quality of OCT ≥ 7, being hospitalized in the Hospital Military Central and previously sign the informed consent.

Patients with a diagnosis of diabetes mellitus and/or systemic arterial hypertension, who had previously received treatment with intravitreal injections and/or vitreoretinal surgery, were excluded. One patient was eliminated for having an OCT quality below the pre-established parameter.

The primary objective of the study was to describe the OCT findings in patients diagnosed with COVID-19, assessing the thickness of: the nerve fiber layer, the ganglion cell layer, the thickness of the macular area and the choroidal thickness. As secondary objectives, their ophthalmological characteristics were described in terms of: important findings in the previously mentioned layers, near vision, the presence or absence of ocular symptoms, and the systemic inflammatory status of the patients was determined through laboratory studies.

The spectral domain tomograph (Cirrus HD-OCT model 4000; Carl Zeiss Meditec, Inc.) was used. To obtain the results of the thickness values, we used the following OCT modules: to assess the nerve fiber layer and its symmetry, the "ONH and RNFL OU" analysis module was used, for the macular thickness the "Macular Cube 512 x 128 "whose anatomical segmentation in its innermost portion includes the inner limiting membrane (MLI) and the outermost layer included in the segmentation is the retinal pigment epithelium (RPE) and the tracking was evaluated with vertical and horizontal slices, for ganglion cells, the "Ganglion Cell OU Analysis" analysis module was used with the segmentation of the ganglion cell (CGL) and internal plexiform (IPL) layers and for choroidal thickness we selected the EN-FACE mode specifying the choroidal layer and he manually measured the total thickness of the choroidal layers.

OCT was performed by an ophthalmologist who previously selected patients who were bedridden cardio/respiratory stable when entering the COVID hospitalization room. The ophthalmologist put on the complete personal protective equipment and personally and separately transferred the patients in a wheelchair to avoid the risk of falls and/or hemodynamic alterations.

The study was carried out as follows: upon reaching the area where the optical coherence tomography was located, they were given informed consent, which was explained in detail and the patient signed if they agreed; Subsequently, near vision was assessed with a Rosenbaum chart at 30 cm, OCT was performed, the patients in the wheelchair were returned to their room and at the end, the chair was cleaned with chlorine-based products. wheels and the optical coherence tomograph.

Results

General characteristics of the sample

The total sample consisted of 64 eyes from 32 patients. 81% were male. The mean age of the patients was 44 ± 12 years, with an age range that ranged from 21 to 69 years, such that half of the patients were under 44 years of age. Represented in graph 1.

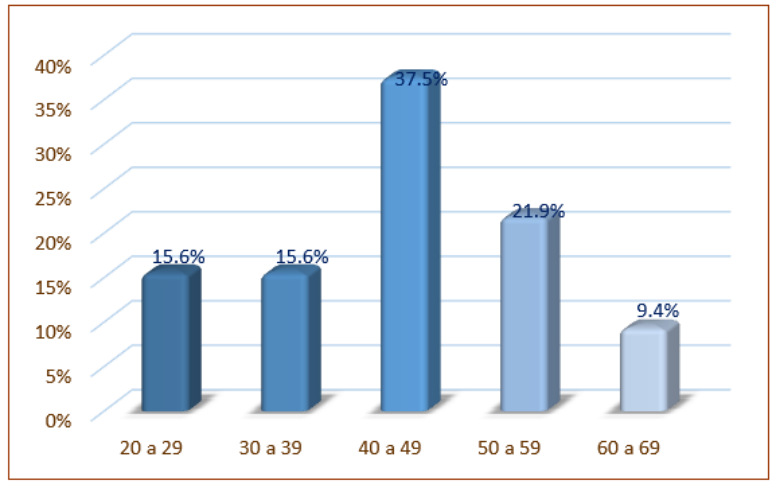

Graph 1: *Distribution of patients by 10-year age group.*

Ophthalmological characteristics of the patients

Visual acuity (VA), which was assessed using the "Rosenbaum" type near vision chart at a distance of 30 cm, ranged in a range converted in logMAR units from 0.0 to 1.6. With 75% of patients presenting a vision of 0.0.

Findings by spectral domain optical coherence tomography

The average thickness values measured in (µm) of the different evaluated layers are represented in table 1.

Characteristic	Average ± DS	Range (min /max)
Ganglion cells	79 ± 9 µm	28, 93
Central macular thicknes	246 ± 21 µm	202, 296
Choroidal	69 ± 18 µm	25, 117
Nerve fiber layer	97 ± 12 µm	53, 124

Table 1: *Average values of retinal layers.*

In 57% of the eyes evaluated, hyperreflectic areas were observed, which are located between the layer of nerve fibers and ganglion cells with characteristics of being rectangular, hyperreflective and generating a posterior shadow. 72% were men, with an average age of 44 years. Represented in graph 2.

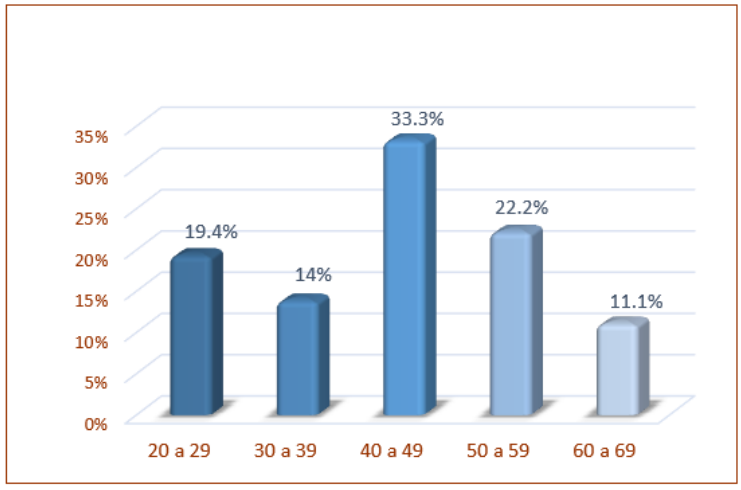

Graph 2: *Distribution by age group of patients with hyperreflective images.*

The frequency of ocular symptoms in the entire population was 16%. 60% of these presented conjunctivitis and 20% blurred vision. Represented in graph 3.

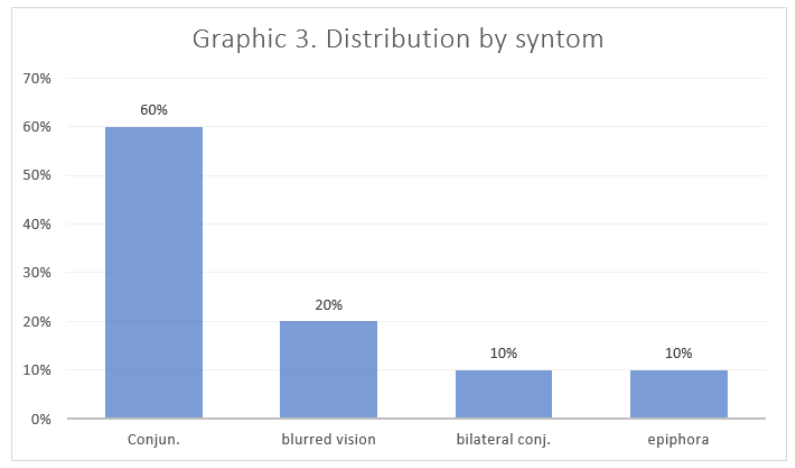

Graph 3: *Distribution by symptom.*

COVID-19 prognostic markers

These were assessed in all patients from: CRP, D-dimer and lymphocytes. Represented in table 2.

Value	Average	Range (Min/Max)
C-reactive protein	62 +/- 67 mg/L	5 - 270 mg/L
D Dimer	813 +/- 1262 ng/ml	93 - 7000 ng/ml
Lymphocytes	1400 +/- 800 ul	200 - 3600 ul

Table 2: *Prognostic values.*

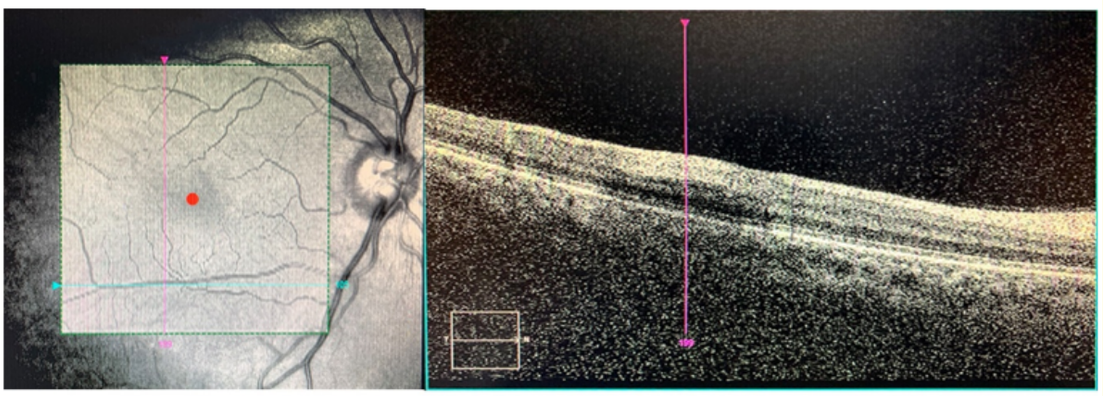

Figure 1: *Horizontal hyper-reflective band generating posterior shadow, located in the ganglion cell layer. It is represented over an inferior temporal blood vessel, in the image of the posterior pole.*

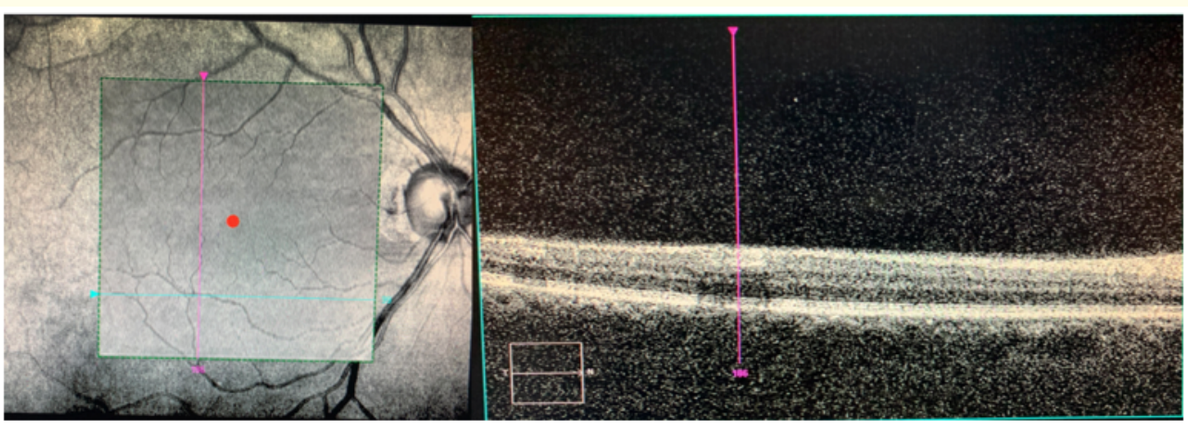

Figure 2: *Square-shaped hyperreflective band generating posterior shadow. Which is located on a blood vessel in a lower temporal bifurcation, in the posterior pole image.*

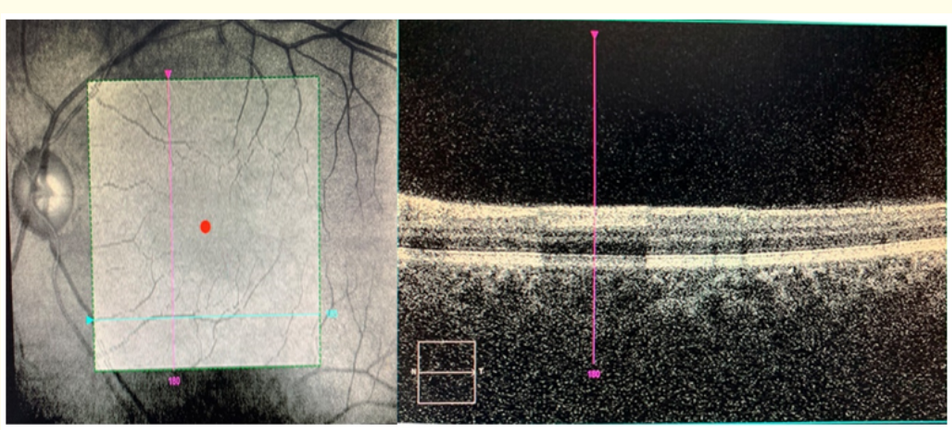

Figure 3: *Hyper-reflective band of rectangular shape generating posterior shadow, located in the ganglion cell layer. It is represented over a temporal blood vessel, in the image of the posterior pole.*

Discussion

There are few articles published in the world literature that speak of the findings in the optical coherence tomography secondary to the new SARS-CoV-2 virus, this investigation is the first carried out in the Mexican population, which speaks of the tomographic findings during the period of hospitalization.

Marinho., *et al*. Published in the Lancet on May 12, 2020, that they studied 12 patients (6 men and 6 women) who had recently suffered from COVID-19, in which all patients had hyperreflective lesions between the ganglion cell layer and the Inner plexiform layer more predominant in the papillo-macular bundle in both eyes. They also performed an evaluation of the ganglion cell complex and angio-OCT, the latter being normal [16].

Subsequently, on July 1, 2020, Vavvas and collaborators, in order to further expand on the scientific knowledge of hyperreflectic lesions, opined that said "lesions" could be normal hyperreflectic changes corresponding to retinal blood vessels, due to their morphology, reflectivity, location and the subsequent shadow they generate [17].

In our study, 57% of the eyes assessed presented "hyperreflective images" with characteristics of being of different sizes in their extension, hyperreflective in their entirety, horizontal in shape and generating a posterior shadow Image 1 and 2. 72% being men whose average age was 44 years. In order to increase the scientific knowledge of these lesions, we used the EN-FACE imaging modality and did a scan both from superior to inferior and horizontal and documented that these images manifested exactly where the normal retinal vessel was located, coinciding with what Vavvas., *et al*. conclude that hyperreflectic lesions are not pathological, but reflect the retinal vessel with normal morphological characteristics.

Burgos., *et al*. in Spain studied 8 eyes of patients who had OCT of nerve fibers prior to SARS-CoV-2 disease and after having suffered the disease, detecting a generalized increase in thickness of an average of 4.3 microns [18] in 7 eyes. Unlike them, in this research, although a pre and post COVID OCT was not performed, the observed patients did not present a generalized increase in the thickness of the nerve fiber layer according to the OCT normative basis.

In the present study, the thickness of the macular region, of ganglion cells and choroidal thickness were evaluated, finding no involvement of said thickness in the different layers, only 1 59-year-old male reported involvement of the thickness of the ganglion cell complex in both eyes. In contrast to what Abrishami and collaborators affirm, who reported a decrease in the density of the vascular plexus of the superficial and deep capillaries, however, they were able to affirm it through the use of the OCT-A modality, which was a limitation in this study [19].

On the other hand, the near visual acuity that was assessed in the patients with the Rosenbaum chart, resulted in that 75% of the patients had a vision in units of logMAR of 0.0. Likewise, the frequency of ocular symptoms in the entire sample was 16%, which is lower than the 31.6% reported by Wu., *et al.* in China [20].

To date, it is the first study carried out in a Mexican population in a tertiary hospital to document the findings by optical coherence tomography secondary to the new SARS-CoV-2 virus in patients during their hospitalization. However, the sample may not be large enough to generalize the results obtained to other populations with SARS-CoV-2.

Conclusion

Therefore, we consider the need for more research on the manifestations of SARS-CoV-2 in OCT in order to obtain more precise conclusions in this population group regarding their ophthalmological characteristics secondary to the disease.

Conflict of Interests

The authors have no conflict of interest.

Financing Support

This article was self-financed.

Protection of People and Animals

The authors declare that no experiments were performed on humans or animals for this research.

Confidentiality of the Data

The authors declare that they have followed the protocols of their work center on the publication of patient data.

Right to Privacy and Informed Consent

The authors have obtained the informed consent of the patients and/or subjects referred to in the article. This document is in the possession of the corresponding author.

Bibliography

1. Ii RKP., *et al.* "DITORIAL Ophthalmologists Are More Than Eye Doctors—In Memoriam Li Wenliang (2020): 2-3.
2. Emparan JPO., *et al.* "Recomendaciones para el manejo de pacientes que requieren atención oftalmológica durante la pandemia de SARS-CoV-2 Recommendations for the management of patients that require eye care during the SARS-CoV-2 pandemic" (2020).
3. Mier-Bolio JR., *et al.* "COVID-19 y ansiedad en oftalmólogos". *Revista Mexicana de Oftalmología* 94.6 (2020): 247-251.
4. Casagrande M., *et al.* "Detection of SARS-CoV-2 in Human Retinal Biopsies of Deceased COVID-19 Patients". *Ocular Immunology and Inflammation* 28.5 (2020): 721-725.
5. Chen X., *et al.* "SARS-CoV-2 on the ocular surface: is it truly a novel transmission route?" *British Journal of Ophthalmology* (2020).
6. Lu C wei., *et al.* "2019-nCoV transmission through the ocular surface must not be ignored". *Lancet* 395.10224 (2020): e39.
7. Chen L., *et al.* "Ocular manifestations and clinical characteristics of 535 cases of COVID-19 in Wuhan, China: a cross-sectional study". *Acta Ophthalmology* (2020).
8. Pirraglia MP., *et al.* "Retinal involvement and ocular findings in COVID-19 pneumonia patients". *Scientific Reports* 10.1 (2020): 1-7.
9. Acharya S., *et al.* "Unique case of central retinal artery occlusion secondary to COVID-19 disease". *IDCases* 21 (2020): 19-21.
10. Staurenghi G., *et al.* "Proposed lexicon for anatomic landmarks in normal posterior segment spectral-domain optical coherence tomography: The IN•OCT consensus". *Ophthalmology* 121.8 (2014): 1572-1578.
11. Chan VTT., *et al.* "Spectral-Domain OCT Measurements in Alzheimer's Disease: A Systematic Review and Meta-analysis". *Ophthalmology* 126.4 (2019): 497-510.

12. Cetin EN., *et al.* "The thicknesses of choroid, macular segments, peripapillary retinal nerve fiber layer, and retinal vascular caliber in HIV-1-infected patients without infectious retinitis". *Retina* 39.7 (2019): 1416-1423.

13. Kurup SP., *et al.* "Spectral domain optical coherence tomography in the evaluation and management of infectious retinitis". *Retina* 34.11 (2014): 2233-2241.

14. Duker JS., *et al.* "The international vitreomacular traction study group classification of vitreomacular adhesion, traction, and macular hole". *Ophthalmology* 120.12 (2013): 2611-2619.

15. Ioannides A., *et al.* "Isolated cotton-wool spots of unknown etiology: Management and sequential spectral domain optical coherence tomography documentation". *Clinical Ophthalmology* 5.1 (2011): 1431-1433.

16. Marinho PM., *et al.* "Retinal findings in patients with COVID-19". *Lancet* 395.10237 (2020): 1610.

17. Vavvas DG., *et al.* "Concerns about the interpretation of OCT and fundus findings in COVID-19 patients in recent Lancet publication". *Eye* (2020): 8-9.

18. Burgos-Blasco B., *et al.* "Optic nerve analysis in COVID-19 patients". *Journal of Medical Virology* (2020): 1-2.

19. Abrishami M., *et al.* "Optical Coherence Tomography Angiography Analysis of the Retina in Patients Recovered from COVID19: A Case Control Study". *Canadian Journal of Ophthalmology* (2020): 1-7.

20. Wu P., *et al.* "Characteristics of Ocular Findings of Patients with Coronavirus Disease 2019 (COVID-19) in Hubei Province, China". *JAMA Ophthalmology* 138.5 (2020): 575-578.

Volume 12 Issue 11 November 2021