

## Systemic Acetazolamide with Topical Non-Steroidal Anti-Inflammatory Therapy for Bilateral Cystoid Macular Edema Induced by Paclitaxel

Abdallah K Hassouna<sup>1</sup>, Fady W Fahmy<sup>2\*</sup>, Rami A Hassouna<sup>3</sup> and Sherine S Wahba<sup>4</sup>

<sup>1</sup>Professor of Ophthalmology Ain Shams University, Watany Eye Hospital, Cairo, Egypt

<sup>2</sup>Ophthalmology Specialist, Ain Shams General Hospital, Watany Eye Hospital, Cairo, Egypt

<sup>3</sup>Ophthalmology Specialist, Watany Eye Hospital, Cairo, Egypt

<sup>4</sup>Professor of Ophthalmology Ain Shams University, Watany Eye Hospital, Cairo, Egypt

**\*Corresponding Author:** Fady W Fahmy, Ophthalmology Specialist, Ain Shams General Hospital, Watany Eye Hospital, Cairo, Egypt.

**Received:** April 03, 2021; **Published:** May 29, 2021

### Abstract

**Background:** Paclitaxel is one of the Taxane family of antitumor drug. Cystoid macular edema (CME) can occur secondary to paclitaxel treatment.

**Case Presentation:** We report a case of 63 years female with metastatic breast cancer who developed bilateral non-leaking cystoid macular edema after paclitaxel treatment. The decision was made to stop this medication after consultation of her oncologist and to start systemic acetazolamide and topical non-steroidal anti-inflammatory eye drops for 4 weeks. Visual acuity improved in both eyes and OCT showed complete resolution of CME.

**Conclusion:** Paclitaxel could induce non-leaking CME. Cessation of the drug with the use of combined systemic acetazolamide and topical non-steroidal anti-inflammatory give good results. Good history taking is the clue to proper diagnosis and, consequently, good management.

**Keywords:** Cystoid Macular Edema; Chemotherapy; Paclitaxel; Systemic Acetazolamide; Topical Non-Steroidal Anti-Inflammatory

### Abbreviations

CME: Cystoid Macular Edema; FFA: Fundus Fluorescein Angiography; OCT: Optical Coherence Tomography; CMT: Central Macular Thickness; BCVA: Best-Corrected Visual Acuity; Anti-VEGF: Anti-Vascular Endothelial Growth Factor

### Introduction

Paclitaxel is known to be the prototype of the Taxane family of antitumor drug. Its efficacy comes from its microtubule-stabilizing effect which leads to mitotic arrest. Paclitaxel approved by the Food and Drug Administration for the treatment of many cancers including breast cancer [1].

**Citation:** Fady W Fahmy, et al. "Systemic Acetazolamide with Topical Non-Steroidal Anti-Inflammatory Therapy for Bilateral Cystoid Macular Edema Induced by Paclitaxel". *EC Ophthalmology* 12.6 (2021): 81-84.

Paclitaxel is known to produce multiple ocular side effects including visual impairment, photopsia and ischemic optic neuropathy [2].

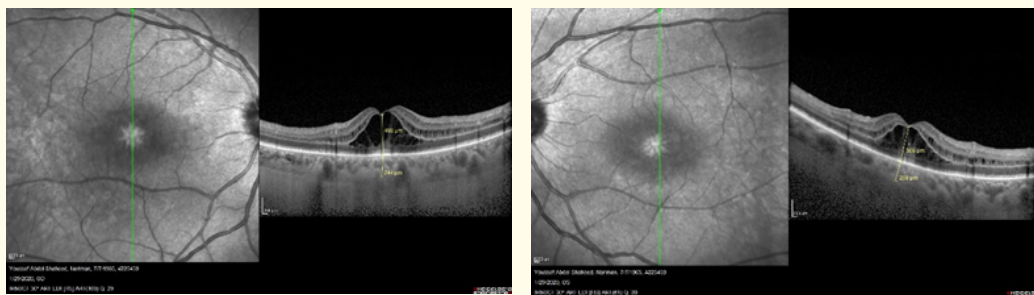
Fluorescein non-leaking cystoid macular edema (CME) is a rare side effect of Paclitaxel with unclear pathogenesis [3].

This article presents a female patient who complained of decreased vision after Paclitaxel treatment.

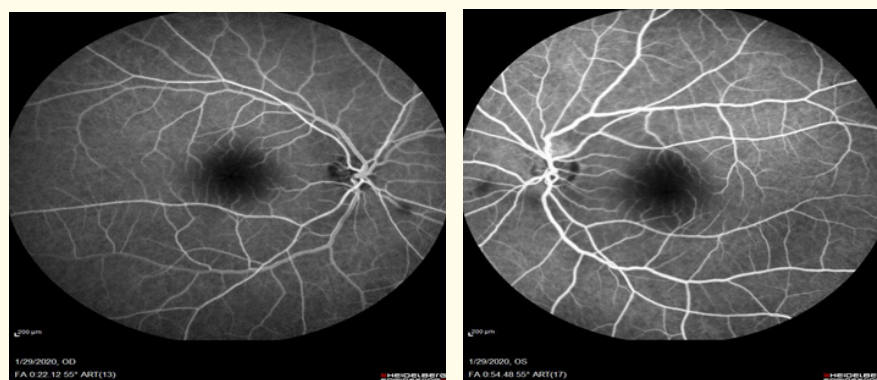### Case Description

A 63-year-old female, with history of hypertension of 20 years duration and breast cancer of two years duration which was diagnosed to be metastatic and started combined chemotherapy regimen including mitotic inhibitor (paclitaxel for two months) and other treatment regimens such as monoclonal antibodies (trastuzumab and pertuzumab) and alkylating agent of the platinum complex group (carboplatin). She started this entire regimen at the same time with systemic beta blockers as treatment of her hypertension. She had bilateral cataract surgery 3 years ago.

She presented to us with bilateral simultaneous diminution of vision of recent onset. On examination, best-corrected visual acuity (BCVA) was 0.4 (decimal) in the right eye and 0.16 in the left eye. Anterior segment examination showed bilateral pseudophakia. Fundus examination revealed bilateral cystoid macular edema. This was confirmed by spectral-domain optical coherence tomography (OCT) where central macular thickness (CMT) was 488  $\mu\text{m}$  in the right eye and 506  $\mu\text{m}$  in the left eye (Figure 1). It is confirmed also by fundus fluorescein angiography (FFA) which revealed cystic macular changes with no vascular leakage (Figure 2).



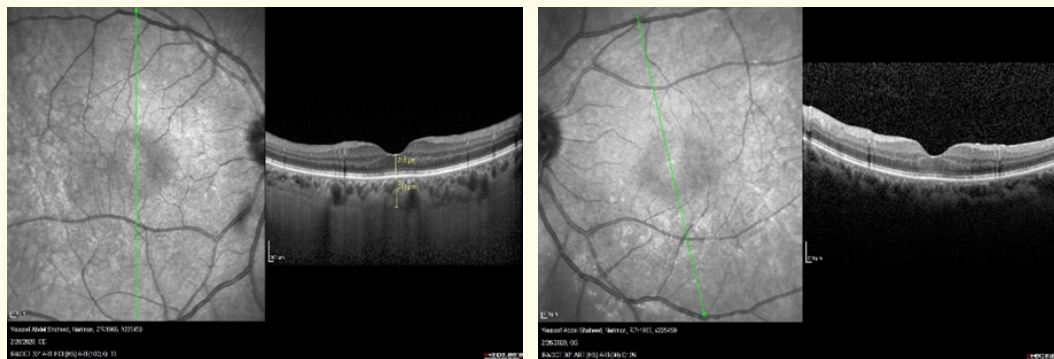**Figure 1:** OCT scan of the macula of both eyes.



**Figure 2:** Fundus fluorescein angiography of both eyes.

The patient was diagnosed as bilateral CME and considered to be secondary to the mitotic inhibitor paclitaxel. The decision was made to stop this medication, after consultation of her oncologist, and to start combined therapy of systemic acetazolamide 250 mg tablet every 12 hours and topical non-steroidal anti-inflammatory eye drops (Nepafenac 0.1%) three times per day.

After four weeks, the patient BCVA improved to her baseline after the cataract surgery (0.7) in both eyes. The OCT showed complete resolution of foveal-involving cystoid changes with complete restoration of the foveal contour and dry retinal layers with CMT of 263  $\mu\text{m}$  in the right eye and 256  $\mu\text{m}$  in the left eye (Figure 3).



**Figure 3:** OCT scans of both eyes after treatment with systemic acetazolamide and topical non-steroidal anti-inflammatory eye drops.

## Discussion

Paclitaxel is a common anticancer drug with a known, but rare, complication of induced CME without fluorescein leakage [3].

The pathogenesis of this non-leaking maculopathy still unclear but there are many hypotheses for explanation including the expansion of the intracellular fluid spaces [4], increased capillary fluid filtration and retention [5], dysfunction of retinal pigment epithelium with its effect on microtubules function [6] and toxicity of Muller cells with intracellular fluid accumulation and subclinical leakage of extracellular fluid [7].

Because of this unclear pathology of maculopathy, there is no specific treatment of these cases. However, discontinuation of paclitaxel is widely accepted as the first choice of treatment but sometimes cessation of the drug is inappropriate [8].

In our case, in addition to paclitaxel discontinuation we started a combined therapy of systemic acetazolamide and topical non-steroidal anti-inflammatory eye drops. After 4 weeks a complete regression of the CME, restoration of the macular contour and dryness of the retinal layer occurred. Our results were comparable to Meyer, *et al.* [8] who used acetazolamide as a co-medication with paclitaxel because of the inappropriate discontinuation of the drug in a case of malignant melanoma of the skin in which complete recovery of macular edema occurred after 8 weeks. In contradiction with this study we had more rapid recovery with the combined therapy of topical non-steroidal with the systemic acetazolamide.

Other options of treatment like the injection of anti-vascular endothelial growth factor (anti-VEGF) reported being ineffective in these cases [9].

To the best of our knowledge, this is the first case report that uses a combined topical non-steroidal anti-inflammatory drug and systemic acetazolamide with the cessation of the paclitaxel drug to treat maculopathy in these cases. This combination gives a rapid recovery

of the macular edema within 4 weeks and improvement of the visual acuity. Enzsoly, *et al.* [10] showed comparable results as regard using topical non-steroidal anti-inflammatory with the cessation of the drug but without the use of systemic acetazolamide. Visual recovery occurred after 5 weeks. Still the combined therapy in our case gives more rapid recovery and improvement of visual acuity after 4 weeks.

### **Conclusion**

This case report highlights the importance of good history taking as it will be a clue to reach our proper diagnosis and for the ophthalmologists not to rush for intravitreal injections in cases of CME without knowing the etiology. Also, we reached to a conclusion that the combined therapy of systemic acetazolamide and topical non-steroidal anti-inflammatory give very good results with rapid recovery of the macular edema and improvement of visual acuity.

### **Disclosure**

No financial interests or any conflict of interest exist.

### **Bibliography**

1. Weaver BA. "How Taxol/paclitaxel kills cancer cells". *Molecular Biology of the Cell* 25.18 (2014): 2677-2681.
2. Singh P, *et al.* "Ocular adverse effects of anti-cancer chemotherapy and targeted therapy". *Journal of Cancer Therapeutics and Research* 1 (2012): 5.
3. Modi D, *et al.* "Non-leaking Cystoid Maculopathy Secondary to Systemic Paclitaxel". *Ophthalmic Surgery, Lasers and Imaging Retina* 44.2 (2013): 183-186.
4. Wolter JR. "The histopathology of cystoid macular edema". *Albrecht Von Graefes Archiv für Klinische Und Experimentelle Ophthalmologie* 216.2 (1981): 85-101.
5. Semb KA, *et al.* "Capillary protein leak syndrome appears to explain fluid retention in cancer patients who receive docetaxel treatment". *Journal of Clinical Oncology* 16.10 (1998): 3426-3432.
6. Shintaro Nakao, *et al.* "Possibility of Müller Cell Dysfunction as the Pathogenesis of Paclitaxel Maculopathy". *Ophthalmic Surgery, Lasers and Imaging Retina* 47.1 (2016): 81-84.
7. Kuznetcova TI, *et al.* "The mystery of angiographically silent macular oedema due to taxanes". *International Ophthalmology* 32.3 (2012): 299-304.
8. Meyer, *et al.* "Regression of paclitaxel-induced maculopathy with oral acetazolamide". *Graefe's Archive for Clinical and Experimental Ophthalmology* 250.3 (2012): 463-464.
9. Rahman HT, *et al.* "Cystoid macular edema without leakage secondary to nab-Paclitaxel (Abraxane): clinical experience with intravitreal bevacizumab". *Journal of Ocular Pharmacology and Therapeutics* 29.3 (2013): 360-362.
10. Enzsoly, *et al.* "Bilateral cystoid macular edema following docetaxel chemotherapy in a patient with retinitis pigmentosa: a case report". *BMC Ophthalmology* 15 (2015): 32.

**Volume 12 Issue 5 May 2021**

**© All rights reserved by Fady W Fahmy, *et al.***