

Biofeedback in Treatment of Eye Ailments

Ved Prakash Banga*

Acupuncture Practitioner, India

***Corresponding Author:** Ved Prakash Banga, Acupuncture Practitioner, India.

Received: April 28, 2021; **Published:** April 29, 2021

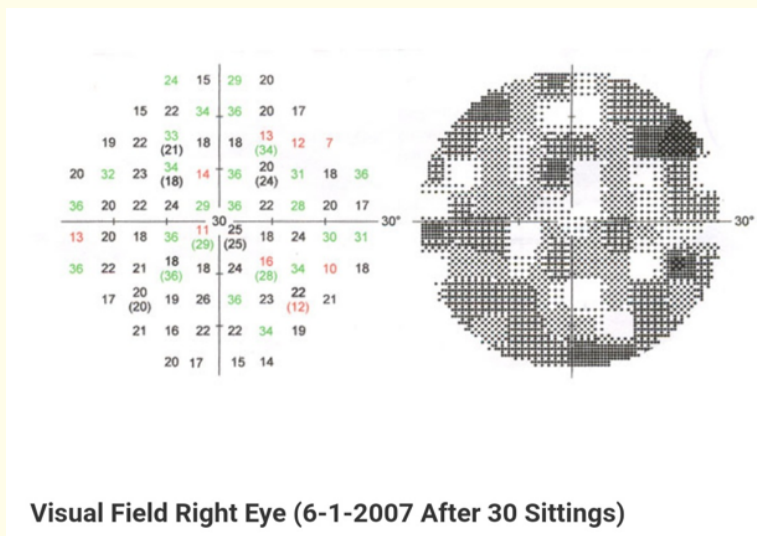
More than four thousands years back, in the traditional Chinese Medicine, it is clearly mentioned that an acupuncture point exists near the corner of nail of little finger of feet. In today nomenclature of this point is named as UB 67 or urinary bladder 67.

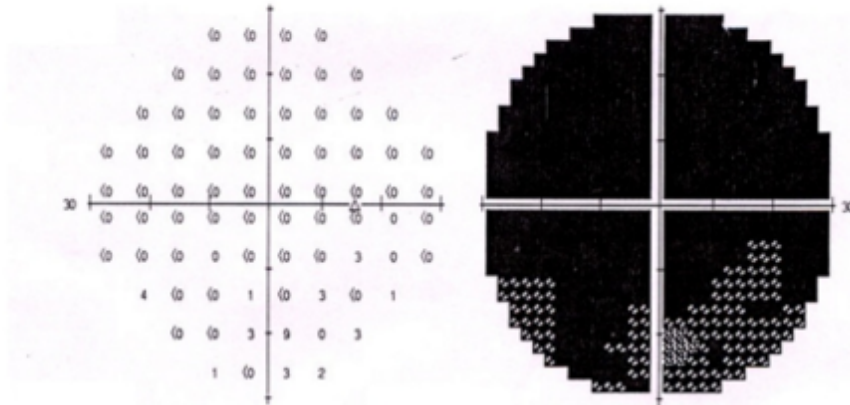
What is more important in ancient literature it is categorically mentioned that this point affects vision.

Seems to be laughable as per standards of modern ophthalmology, because in today's world, ophthalmology revolves around the eyes only, usually every ailment's treatment is sought in manipulating at the eyes except some diseases as diabetic retinopathy or as in hypertension. Here also treatment is applied locally besides treatment of systemic ailments.


But a few years back it was revealed by technique developed by the modern medicine of MRI that as we stimulate UB 67 there is increased activity at the visual cortex in the brain, thus validating claims of ancient Chinese medicine.

With this submission I again emphasize that why not in this era we can assimilate this ancient knowledge from traditional medicine be it ayurveda or acupuncture with the modern medicine, at least for those ailments where modern hospitals do not offer any solution to the patient. According to the concept of quantum physics, it is proved, even if we move a finger then distant part of universe (planets or even remote galaxies) gets affected, irrespective of that fact that it is measurable or not. So why can't the stimulation of UB67 could not affect the visual area. Why not this fact is accepted? At least these acupuncture points are on the patient's body itself!





Visual Field Right Eye Before Treatment



Visual Field Right Eye (25-11-2006 After 15 Sitzings)

These three images of perimetry are of patient Mr Ansuman who suffered from optic nerve injury.

Resulting from road side injury in the year in the year 2004, he tried treatment at various hospitals but there was no response.

He came to me in the year 2006, examined on the lines of modern medicine, he had MRI scan.

Area was mapped on lines of acupuncture channels to ascertain which channel of acupuncture is involved, mainly gall bladder and urinary bladder acupuncture channels were used. After that treatment was planned and administered acupuncture along with regenerative traditional treatment.

Patient responded well with the first sitting and total 30 sittings were administered.

Perimetry was examined after 15 sittings and repeated after 30 sittings.

Patient got vision which he can use very well.

On follow up he is stable in all these years.

This is one such patient, it does not mean that every patient can be treated on the same lines, in this system of treatment every time planning of treatment is done individually.

At least we can offer help to regain vision which is very vital for the patient.

Volume 12 Issue 5 May 2021

©All rights reserved by Ved Prakash Banga.