

Stabilization of the Sinking Lamina Cribrosa with Adhesives in Chronic Glaucoma: A Potential Standard of Care

Syed S Hasnain* and Aziz Hasnain

General Ophthalmology, Porterville, CA, USA

*Corresponding Author: Syed S Hasnain, General Ophthalmology, Porterville, CA, USA.

Received: December 25, 2020; Published: February 26, 2021

Abstract

The most salient feature of chronic glaucoma is the orderly loss of nerve fibers starting with the most peripheral nerve fibers and ending with the most central. It never occurs randomly. Based on the orderly loss, the lamina cribrosa may be sinking, not cupping, in glaucoma. Due to sinking of the lamina cribrosa, the nerve fibers are being stretched and severed at the scleral edge starting with the most peripheral nerve fibers and ending with the most central in an orderly sequence. It is hypothesized that application of a glue to the optic nerve head may stabilize the sinking lamina cribrosa and halt the progression of glaucoma.

Keywords: Glaucoma; Peripheral Nerve Fibers; Sinking Lamina Cribrosa

Introduction

Chronic glaucoma, commonly known as glaucoma, is the leading cause of irreversible blindness in the world. With a current global estimate of nearly 80 million people in 2020, it continues to remain an epidemic of significant magnitude and a public health challenge [1].

Since chronic glaucoma was classified as a separate entity in the 1850s, there has been a continuous search to find the pathogenesis and preventive treatment for this disease. As of today, there remains no established standard for screening individuals with glaucoma [2]. Identifying the pathogenic mechanism of this disease would bring to foundation an effective standard of screening in order to establish prevention methods.

The search for identifying the pathogenesis of glaucoma has gradually branched into a multitude of theories over the past 160 years. These theories are commonly applied in glaucoma research and practice. Some of the theoretical approaches applied to explain glaucoma today include apoptosis, autoimmune, neurodegeneration, increased sensitivity of the nerve fibers to intraocular pressure (IOP) and the phenomenon of cupping.

Despite their prevalence, none of these theories focus on the most important feature in chronic glaucoma: the orderly loss of nerve fibers. For any investigator or institution to carry out glaucoma research without providing how their research also explains the hallmark feature of the orderly loss of nerve fibers, would be conducting glaucoma research without a foundation.

This orderly loss of nerve fibers is the most salient feature of this disease. In summary, orderly loss refers to the peripheral-to-central visual field loss which occurs as the disease progresses. This peripheral-to-central visual field loss leads to tunnel vision, followed by the total loss of vision. Visual field loss never occurs randomly, otherwise the role of perimetry in glaucoma would be of no value. The other notable feature present along with the orderly loss is the sharply-defined arcuate field defects at the beginning stage of this disease (Figure 1).

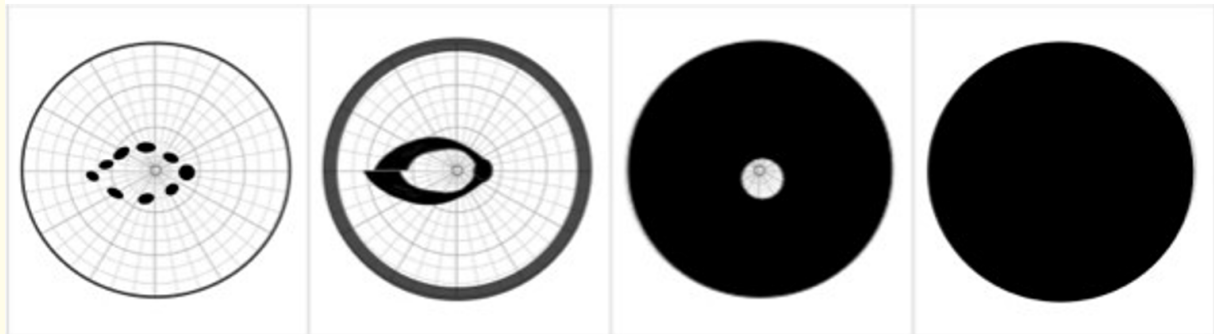


Figure 1: The orderly loss of the visual field in chronic glaucoma.

Schematic diagram: In chronic glaucoma, there is initial peripheral field loss followed by isolated scotomas in the paracentral area which coalesce to form double arcuate scotomas. The central vision is retained until the end stage.

Glaucoma is currently defined as an optic neuropathy that results in the progressive cupping of the optic nerve head. However, established hallmark features of the disease such as the orderly loss of nerve fibers, disc excavation and splinter hemorrhages suggest that glaucoma is not an optic neuropathy, but an optic axotomy.

Glaucoma optic disc axotomy

The hypothesis of chronic glaucoma as an optic axotomy presents a shift to the 160 year-old cupping paradigm and a promising approach to future glaucoma research [3].

According to the hypothesis, the retinal nerve fibers are being severed (or axotomized) at the scleral edge, similar to how water breaks at the crest of a waterfall (Figure 2). The severance of nerve fibers results from sinking of the lamina cribrosa.



Figure 2: The waterfall analogy to glaucoma optic disc axotomy.

This image of an inverted water fountain attempts to explain the theory of the axotomy of nerve fibers in glaucoma. Similar to how water flow breaks at the crest of a waterfall, the retinal nerve fibers are being axotomized at the scleral edge.

The hypothesis also presents chronic glaucoma as a two-stage disease [4]. The first stage, referred to as the biological stage, involves degeneration of the border tissue of Elschnig. This border tissue lies between the sclera and the lamina cribrosa and keeps the lamina cribrosa firmly in place like an ‘O’ ring seal. However, under circumstances of high or low-tension glaucoma, the IOP will become higher than the systemic pressure of the border tissue and compress the ciliary circulation of this border tissue. The slow and prolonged compression of the ciliary circulation will then result in chronic ischemia and degeneration of the border tissue.

The second stage, referred to as the mechanical stage, involves sinking of the lamina cribrosa and the orderly axotomy (loss) of nerve fibers. As the lamina cribrosa sinks, the peripheral nerve fibers (being closest to the scleral edge), become stretched and severed first, creating an empty space. Subsequently, the next-in-line fiber will then move peripherally towards the scleral edge and become stretched and severed resulting in the orderly axotomy of nerve fibers (Figure 3).

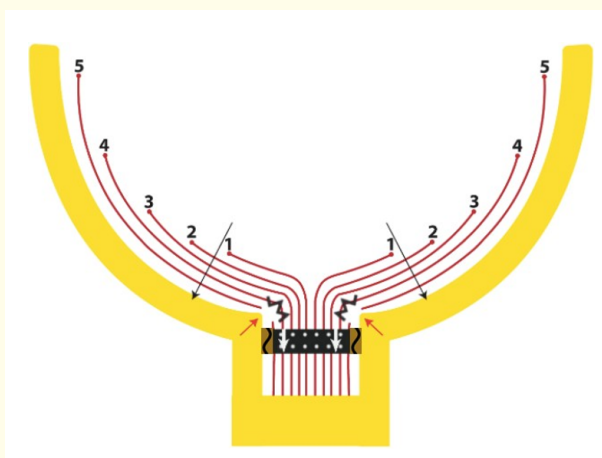


Figure 3: The orderly loss of retinal nerve fibers in chronic glaucoma.

Schematic diagram: Due to the sinking lamina cribrosa (white arrows), the most peripheral nerve fibers (5) become stretched and axotomized first against the scleral edge. The process continues until the most central nerve fibers (1) have axotomized at the scleral edge. Note the brown areas representing the degenerated border tissue.

The continuous axotomy of nerve fibers further accelerates the sinking of the lamina cribrosa due to the loss of anchorage provided by the nerve fibers as roots do to a tree. Sinking of the lamina cribrosa will self-propagate and continue until all the nerve fibers have moved in an orderly fashion to the scleral edge and become axotomized. Axotomy can logically explain the orderly loss of nerve fibers in glaucoma. If confirmed by further studies, nerve fiber axotomy would offer a new criteria in the diagnosis and treatment of chronic glaucoma [3-5].

Potential standard of care: Stabilization of the lamina cribrosa

According to the hypothesis, the further the lamina cribrosa sinks, the more the orderly loss of retinal nerve fibers. Continuous axotomy of nerve fibers at the scleral edge will inevitably lead to the formation of visual field defects, peripheral-to-central visual field loss and irreversible blindness.

Developing approaches to prevent glaucoma may lie upon stabilization of the lamina cribrosa. More specifically, the junctional area surrounding the optic disc where the border tissue meets the lamina cribrosa. This compromised junctional area would become the target area for stabilization therapy in order to prevent sinking of the lamina cribrosa (Figure 4).

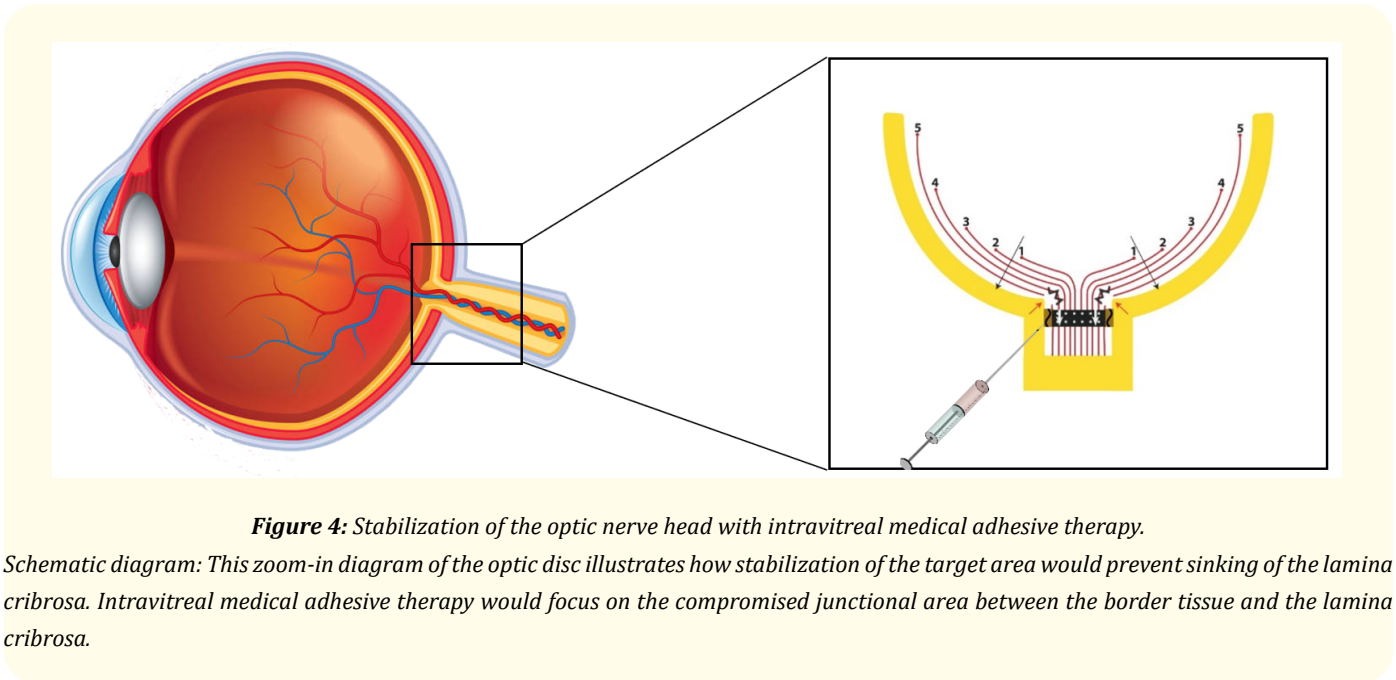


Figure 4: Stabilization of the optic nerve head with intravitreal medical adhesive therapy.

Schematic diagram: This zoom-in diagram of the optic disc illustrates how stabilization of the target area would prevent sinking of the lamina cribrosa. Intravitreal medical adhesive therapy would focus on the compromised junctional area between the border tissue and the lamina cribrosa.

Retinal nerve fibers are an extension of the central nervous system [6]. Once they become severed at the scleral edge, it is unlikely the severed portions will reunite. Thus, focus will be on preventive therapy to halt axotomy of nerve fibers in order to prevent further blindness.

Stabilization as a form of therapy is paramount in preventing progression of glaucoma. The physical anchorage provided with stabilization must be equivalent to that of a healthy optic disc before becoming compromised by the sinking lamina cribrosa. Stabilization of the lamina cribrosa would stagnate formation of visual field defects. If this proves to be successful, stabilization of the lamina cribrosa would be a promising standard of care for individuals with chronic glaucoma.

Medical adhesive therapy

The concept of medical adhesion has been around for many years. Its advent arised as a standard technique for medical procedures as sutures and staples were considered not necessarily as effective. Such techniques also led to issues such as post-surgical infections, cosmetic tissue damage (e.g. scars) and an overall delayed healing time for patients [7].

Medical adhesives are already used in the medical setting today (e.g. Masterbond, 3M). They assist in wound closure from surgical incisions, reattaching tooth fragments, and for implanting medical devices (e.g. pacemakers, ultrasound catheters). Many forms of adhesives

used in the human body provide adequate strength for the attachment of devices, reducing the likelihood of infection and improving the quality of lives for patients.

There are two types of medical adhesives in the medical industry today: synthetic and natural, both of which are used in external and internal applications. Synthetic adhesives are usually composed of materials not found in nature (e.g. acrylic, silicone). Natural adhesives are composed of bio-based raw materials (e.g. fibrinogen, collagen). Medical adhesives are already being used in the field of ophthalmology today. In individuals with persistent retinal detachment, synthetic adhesives known as cyanoacrylates (N-butyl- Cyanoacrylate) have been used with success in retinal reattachment surgeries for chorio-retinal colobomas [8]. Cyanoacrylates are also used in corneal perforation [9].

With respect to the environment surrounding the optic nerve head, including the ocular tissues and microcirculation, stabilization procedures would require medical adhesion through means of internal application. These adhesives would then bind to the existing biological surfaces through the process of bioadhesion [9]. Despite whether they are synthetic or natural adhesives, the process of bioadhesion onto the biological surface would provide the same end result - a permanent bond.

In addition to adhesives, sealants and coatings are also deserving of discussion. Although derivative in use to adhesives, they may be used in collaboration with adhesives at different points and time periods, such as during the preparation or finalization stages of a stabilization procedure. These applications may aid in making certain that the bond (cured adhesive) conforms with the surrounding environment. For example, ensuring that the bond is biocompatible with pressure in the posterior segment, the surrounding tissues and microcirculation, and that the bond is dimensionally intact at the target area.

The drug delivery system

A drug delivery system is a functional way to introduce a therapeutic substance into a target area of the body. The clinical efficacy of the system depends on certain factors such as the rate, time and release of a substance. Several types of drug delivery systems come into play in the administration of medical adhesives today. The ocular drug delivery system, which is able to overcome tissue barriers, would be the preferred system for delivery for a stabilization procedure. In addition, the preferred route of administration of the medical adhesive into the target area of the posterior segment, would be through intravitreal injections.

Intravitreal injections are the most common and widely recommended route of drug administration to treat posterior ocular diseases. Although the need of repeated eye punctures with intravitreal injections can cause side effects such as endophthalmitis, hemorrhage, retinal detachment and poor patient tolerance, it is still considered an effective method of delivery today. On balance, the benefits provide a means to an end of stabilizing the lamina cribrosa to halt the progression of glaucoma. This will strongly weigh it in favor as a standardized technique for drug delivery.

Upon intravitreal injection into the target area, a medical adhesive will dry, polymerize and begin to act as a bond. The interdiffusion and interpenetration of the adhesive into target area would create a bond that would secure the lamina cribrosa, thus acting as a 'permanent weld' to the area where the border tissue was compromised. This bond would then stay in place for the remainder of the patient's lifetime.

In order to provide accurate delivery to the target area, the injection therapies would be guided by optical coherence tomography (OCT). This would assist an ophthalmologist performing a stabilization procedure to control certain parameters such as applying the minimum effective dose for proper bonding, maximizing effective 'spot welds', and preventing adhesive runoff into unintended areas.

Depending on the severity of a patient's glaucoma, stabilization procedures may spread over intervals with the possibility of more than one procedure, especially if glaucoma becomes very progressive. The stabilized target area would be monitored periodically by an ophthalmologist by means of OCT, perimetry and digital fundus photography.

For example, by establishing a baseline reference point on a patient's OCT scan before their first stabilization procedure, an ophthalmologist can periodically monitor and observe for any subsequent changes. Periodic monitoring would primarily focus on the position of the lamina cribrosa with respect to the reference point on post-procedural OCT scans. If the scans indicate that the lamina cribrosa continues to be sinking, this may indicate the need for more stabilization to the target area.

Conclusion

In summary, the theory of axotomy of nerve fibers would open new avenues for diagnosis and treatment for this irreversible disease. It would also shift the paradigm of glaucoma research [10]. Further, it would support stabilization of the lamina cribrosa as a promising method of treatment in halting the progression of chronic glaucoma. Lastly, intravitreal medical adhesive therapy to the optic nerve head may be a promising way to stabilize the sinking lamina cribrosa. This may prevent further axotomy of nerve fibers and irreversible blindness for individuals with chronic glaucoma.

Bibliography

1. Glaucoma Research Foundation. "What is the definition of glaucoma?"
2. Moyer VA and US. "Preventive Services Task Force. Screening for Glaucoma: U.S. Preventive Services Task Force Recommendation Statement". *Annals of Internal Medicine* 159 (2013): 484-489.
3. Hasnain SS. "Scleral edge, Not Optic Disc or Retina, is the Primary Site of Injury in Chronic Glaucoma". *Medical Hypotheses* 67 (2006): 1320-1325.
4. Hasnain SS and Hasnain A. "Pathogenesis of Chronic Glaucoma: A Two-Stage Disease". *EC Ophthalmology* 10.5 (2019).
5. Zeried FM and Osuagwu UL. "Changes in retinal nerve fiber layer and optic disc algorithms by optical coherence tomography in glaucomatous Arab subjects". *Clinical Ophthalmology* 7 (2013): 1941-1949.
6. Leiman AL, et al. "Biological Psychology: An Introduction to Behavioral, Cognitive, and Clinical Neuroscience". United Kingdom: Sinauer Associates (1999).
7. Suárez JC. "Bioadhesives". In: da Silva L.F.M., Öchsner A., Adams R.D. (eds) *Handbook of Adhesion Technology*. Springer, Berlin, Heidelberg (2011).
8. Khatri Anadi MD, et al. "Re-inventing Cyanoacrylate Retinopexy in the 21st century". *Retinal Cases and Brief Reports* (2020).
9. Guhan S, et al. "Surgical Adhesives in Ophthalmology: History and Current Trends". *British Journal of Ophthalmology* 102 (2018): 1328-1335.
10. Kuhn Thomas. "The Structure of Scientific Revolutions (2nd, enlarged edition). University of Chicago Press (1970).

Volume 12 Issue 3 March 2021

© All rights reserved by Syed S Hasnain and Aziz Hasnain.