

Neonatal Rubeosis and Fibrovascular Membrane

Kenan R Rajjoub¹, Osama Sabbagh^{2*}, Andrew F Kolker³ and Heather de Beaufort⁴

¹Neurosurgery, University of Buffalo, Buffalo, NY, United States

²Ophthalmology, University of Kentucky/Retina Associates of Kentucky, Lexington, KY, United States

³Ophthalmology, The George Washington University, Washington, DC, United States

⁴Ophthalmology, Children's National, Washington, DC, United States

***Corresponding Author:** Osama Sabbagh, Ophthalmology, University of Kentucky/Retina Associates of Kentucky, Lexington, KY, United States.

Received: September 30, 2020; **Published:** October 30, 2020

Abstract

Purpose: To report a unique case of bilateral, asymmetric, neonatal rubeosis and fibrovascular membrane in a full-term newborn with no known birth trauma or family history of eye disease.

Methods: This is a case report.

Results: A two-day old newborn was referred to our department by a neonatologist who noticed the absence of a red reflex in the child's left eye. Upon examination, engorged radial iris vessels with an anterior chamber fibrovascular membrane were observed in the child's left eye. Engorged iris vessels were also seen in the patient's right eye to a lesser degree. External photographs, color fundus photographs, and B-scan ultrasonography of the anterior chamber and globe were obtained. After treatment with topical prednisolone acetate 1% (Predforte) and topical cyclopentolate hydrochloride 0.2%/phenylephrine hydrochloride 1% (Cyclomydril), the clot resolved and the engorged vessels and membrane regressed over a five-month period.

Conclusion: We report a case of neonatal rubeosis and fibrovascular membrane that, to our knowledge, has not been previously described.

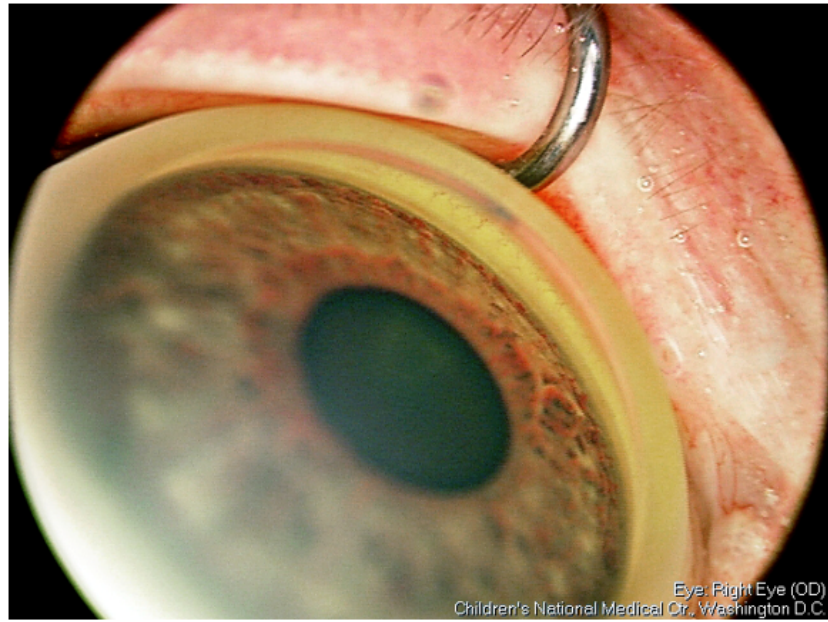
Keywords: Neonatal Rubeosis; Fibrovascular Membrane; Birth Trauma

Introduction and Case Description

A two-day-old neonate was referred to our department due to a lack of red reflex in the child's left eye. The newborn had an unremarkable prenatal course and was induced at 40 weeks and 4 days via vaginal delivery. There was no known birth trauma. The child's birth weight was 6 lbs 14 ounces. The mother was healthy and there was no family history of eye disease.

Upon examination, visual acuity was blink to light in each eye. The external examination was normal. While the right pupil was round and reactive to light, the left was sluggish and minimally reactive. The cornea of each eye was clear. The right iris vessels were slightly engorged (Figure 1) and the anterior chamber was clear.

The left iris vessels were significantly engorged, and there was a fibrovascular membrane overlying the lens and extending into the anterior chamber (Figure 2 and 3).



Eye: Right Eye (OD)
Children's National Medical Ctr., Washington D.C.

Figure 1

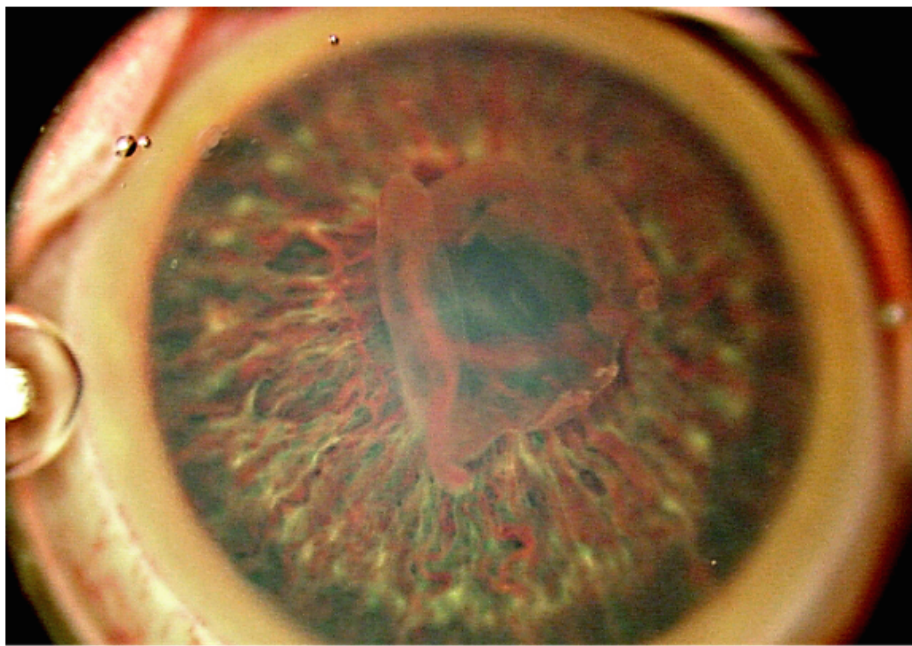


Figure 2

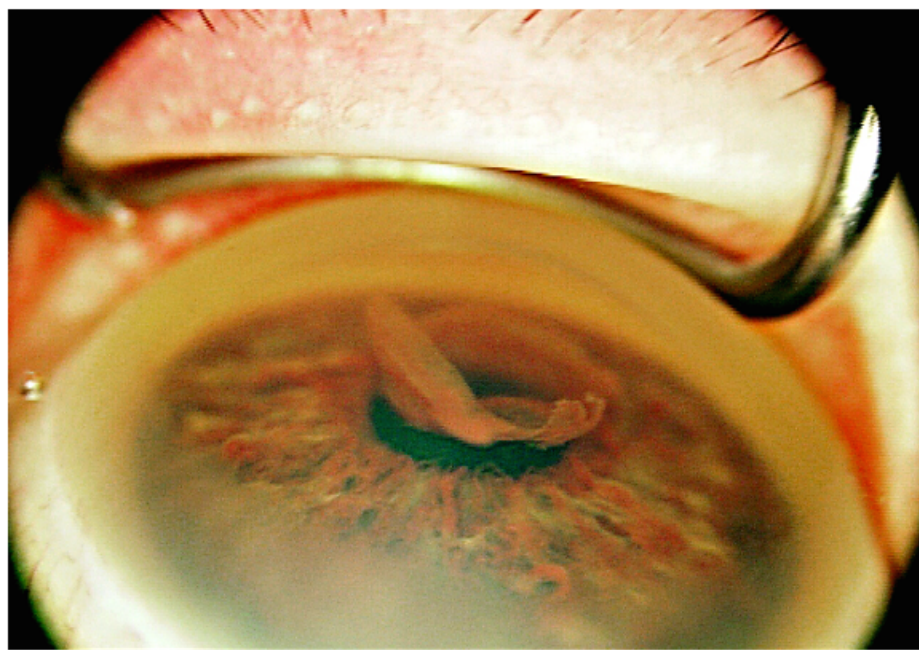


Figure 3

A true hyphema was not observed. The intraocular pressure was within normal limits in each eye. The dilated fundus examination was normal in the right eye with a cup to disk ratio of 0.1. There was no view of the posterior pole of the left eye, but the retina was flat on B-Scan ultrasound with no masses or lesions visualized (Figure 4).

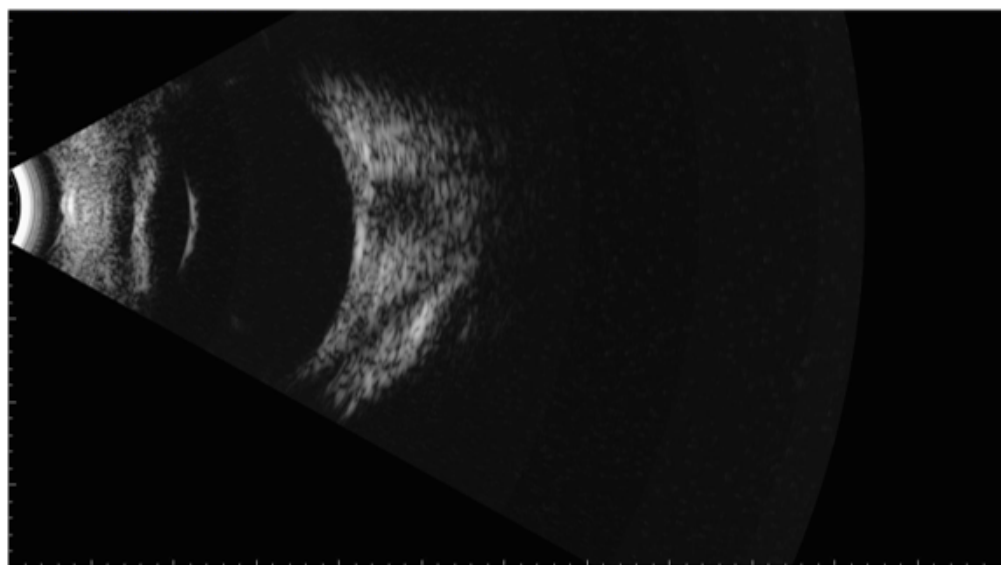


Figure 4

The patient was seen two days later, at which time the anterior chamber membrane was slightly decreased. The left posterior pole could be viewed, and the retina appeared flat without neovascularization or any lesions. At this visit, an ultrasound of the anterior chamber showed condensed membrane overlying the lens that extended into the anterior chamber (Figure 5).

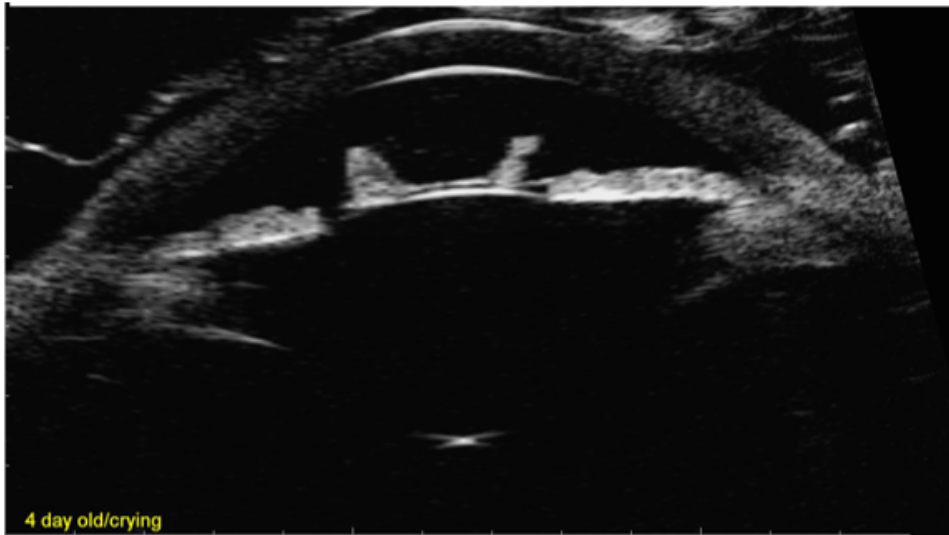


Figure 5

Angle structures were not visualized on examination but appeared to be open on ultrasound bilaterally. The patient was started on a course of Predforte 1% and cyclomydril 1%, both in the left eye only. This treatment regimen was continued with the addition of Atropine 1% that was added at day 17 of treatment. At this visit, the fibrovascular membrane had resolved and the iris vessels were significantly decreased in size. Posterior synechiae in the left eye were present at 6 and 10 o'clock. The treatment regimen was continued, and a taper of the topical medications was initiated. At week 12, the synechiae had completely resolved. The vision was now fix and follow in each eye. At week 15, all topical medications were discontinued. At five months the patient's vision was central, steady, and maintained in each eye on 12 base down prism testing, and the anterior chamber, as well as the iris vasculature, was completely normal. The patient was followed until the age of seven months with no recurrence of the fibrovascular membrane or findings of amblyopia.

Discussion

The engorged iris vessels, in combination with the anterior chamber fibrovascular growth, seen in our patient has not, to our knowledge, been previously described. Other known entities share some features, but none explain the unique constellation of findings in our patient. In persistent tunica vasculosa lentis, a retrolental network of capillaries can be seen [1]. No retrolental material was present in our patient. Juvenile Xanthogranuloma (JXG) may cause a spontaneous hyphema [2]. Our patient, however, had none of the typical skin or ocular granulomatous lesions and did not present with a true hyphema. A hyphema seen at birth may also be the result of birth trauma [3]. Our patient, however, was born via non-traumatic vaginal delivery following an uncomplicated labor. Lastly, it is always important to rule out retinoblastoma when evaluating an abnormal anterior chamber [4]. Our patient did not have a retinoblastoma, nor were any vascular abnormalities of the fundus seen. We hope that reporting this case will help to elucidate and provide context for future anterior chamber

anomalies that do not fit into a known clinical disease. Furthermore, conservative treatment with topical steroids and a cycloplegic agent brought about rapid resolution of this pupil covering membrane, preventing the development of deprivation amblyopia.

Conclusion

We report a case of neonatal rubeosis and fibrovascular membrane that, to our knowledge, has not been previously described.

Bibliography

1. Gulati N., *et al.* "Unoperated eyes with persistent fetal vasculature". *Transactions of the American Ophthalmological Society* 101 (2003): 59-64.
2. Zeynel A Karcioğlu and Paul B Mullaney.
3. Jain IS., *et al.* "Ocular Hazards during birth". *The Journal of Pediatric Ophthalmology and Strabismus* 17.1 (1980): 14-16.
4. Walton DS and Grant WM. "Retinoblastoma and iris neovascularization". *American Journal of Ophthalmology* 65.4 (1968): 598-599.

Volume 11 Issue 11 November 2020

© All rights reserved by Osama Sabbagh., *et al.*