

Complete Clinical Spectrum of Retinoblastoma

Rui Guilherme Castela¹ and Zélia M Corrêa^{2*}

¹Department of Ophthalmology, Centro Hospitalar e Universitário de Coimbra, University of Coimbra, Coimbra, Portugal

²Departments of Ophthalmology and Oncology, Johns Hopkins Medicine, Baltimore, MD and University of Cincinnati College of Medicine, Cincinnati Children's Hospital Medical Center, Cincinnati, Ohio, USA

***Corresponding Author:** Zelia M Correa, Departments of Ophthalmology and Oncology, Johns Hopkins Medicine, Baltimore, MD and University of Cincinnati College of Medicine, Cincinnati Children's Hospital Medical Center, Cincinnati, Ohio, USA.

Received: May 14, 2020; **Published:** June 30, 2020

Abstract

Early diagnosis and treatment of retinoblastoma are essential because the probability of cure is high while the tumor is still intraocular. However, this prognosis gets significantly worse when it spreads outside the eye ultimately leading to death.

The most common presenting sign of this tumor in developed countries is leukocoria (60%) followed by strabismus (20%). The remainder 20% shows atypical presentations that can masquerade as other ocular or orbital pathology. Although these presentations are less common, they pose a diagnostic challenge and are often associated with delayed diagnosis and consequently advanced disease that impacts the outcome and patient survival of patients.

The purpose of this manuscript is to review and emphasize atypical clinical presentations simulating orbital cellulitis, uveitis and endophthalmitis among others that encompass the clinical spectrum of retinoblastoma and comment on current management recommendations.

In order to accomplish such charge, the authors performed a comprehensive search in PubMed and Web of science of English language publications that described atypical presentations of retinoblastoma between 1960 and the present time. The distinct atypical clinical presentations encountered are revised in detail in this manuscript.

Keywords: Eye Cancer; Retinoblastoma Unilateral; Retinoblastoma Bilateral; Leukocoria; Strabismus; Chemotherapy/Intra-Venous; Chemotherapy/Intra-Arterial; Cancer Treatment

Introduction

It is known that retinoblastoma is the most common primary intraocular malignant neoplasm in the pediatric population accounting for 3% of all tumors in children less than 15 years of age [1]. Curiously, the incidence varies depending on geographic location, with higher rates observed in Central and South America, Asia and Africa, suggesting that environmental factors, nutrition, and/or differential genetic susceptibility may play a role in the development of this disease [2]. Retinoblastoma occurs primarily in children under the age of 5 years. In unilateral cases, the medium age of diagnosis is 24 months of age, in bilateral cases its 9 - 12 months-old [3]. This neoplasm has no preference for gender or laterality [4].

Moreover, retinoblastoma is a genetic disease and can occur in two forms, germinal or non-germinal. In germinal cases, both eyes are usually affected, and inheritance usually follows an autosomal dominant pattern, with 90% penetrance. All patients with bilateral retinoblastoma have a germinal mutation on chromosome 13, although only 8% have a prior family history of the disease. About 15% of patients with germinal retinoblastoma have only one eye involved, and it is almost always multi-focal. Non-germinal retinoblastoma is always unilateral and usually unifocal [5].

Early diagnosis and recently developed treatments allows over 95% of children with retinoblastoma to survive in the developed world. Unfortunately, only 50% of children with retinoblastoma survive worldwide. This difference is explained by early versus delayed diagnosis and state-of-the art treatments versus fewer options and lack of resources consequently a greater number of patients with extraocular disease are seen in developing countries [6,7].

Previous peer-reviewed publications from renowned retinoblastoma treatment centers have for the most part been in agreement about the relative frequency of different presenting signs. In all of them leukocoria and strabismus are the most frequent clinical presentations reaching up to 60% and 20% respectively. Leukocoria was associate to more advanced disease and strabismus is always associated with macular involvement [8-12]. The remaining patients (20%) have what are called atypical presentations that usually carry worse prognosis for survival and globe salvage [13]. These atypical presentations are responsible for delayed diagnosis and treatment and consequently associated with advanced disease.

In short, early diagnosis is key to a successful outcome and tumor control. It normally depends on detection by family members and/or the pediatrician and quick referral to an ophthalmologist. The atypical presentations simulating other ocular or orbital pathology pose a diagnostic challenge and should be considered whenever an infant has an unusual clinical presentation that is unresponsive to treatment [7,14].

The aim of this article is to describe and discuss atypical clinical presentations of retinoblastoma that are often associated with delayed diagnosis and thus significantly impacting patient survival and visual outcome, and comment on current management recommendations.

Atypical clinical presentations in retinoblastoma

Proptosis

Proptosis associated with retinoblastoma invading the orbit is a rare clinical finding in developed countries but is relatively frequent clinical presentation (18% - 40%) in developing countries [15-17]. This presentation is usually seen in advanced stages of the disease and carries a higher risk of metastasis [15,18,19]. While the survival of children with orbital retinoblastoma is high in developed countries reaching 88 to 93% [20,21] the mortality among similar cases in developing countries can be as high as 50 to 90% [17].

Retinoblastoma may invade the orbit by direct extension through the optic nerve or sclera or by hematogenous spread [22]. Orbital retinoblastoma can be classified as primary when diagnosed as an initial presentation and secondary when an orbital recurrence occurs after an enucleation (i.e. following accidental perforation during biopsy procedures or intraocular surgery or overt orbital retinoblastoma with extrascleral and optic nerve extension discovered during enucleation and/or microscopic orbital retinoblastoma found on histopathologic evaluation) [18].

Proptosis is the most characteristic clinical sign in this presentation [23] but leukocoria has also been described as the first presenting sign of orbital retinoblastoma [18,24]. Orbital retinoblastoma is typically a late presentation with an average age at diagnosis between 18 and 38 months (Figure 1). Although silent proptosis is the most frequently presenting sign, other possible clinical presentations include proptosis with inflammation (orbital cellulitis), palpable orbital mass, eyelid swelling and an exuberant fungating orbital mass [19].

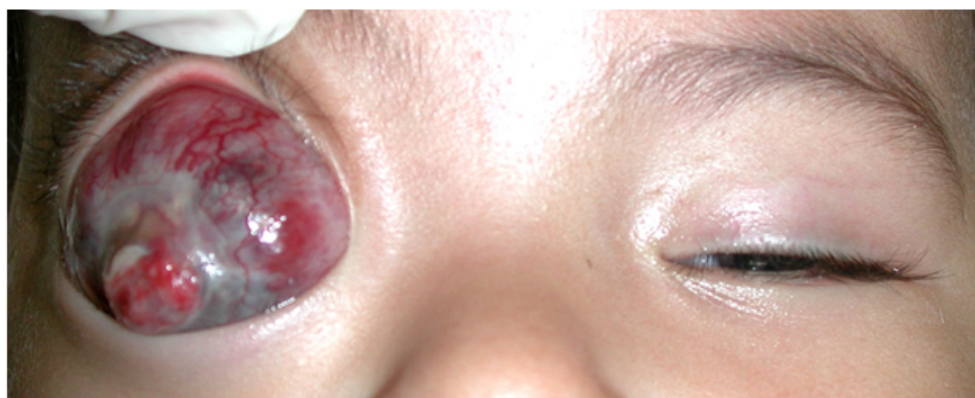

Figure 1: External photograph shows a 24 month-old child with advanced unilateral retinoblastoma (right eye) that included extraocular tumor extension, proptosis and orbital invasion.

Patients with orbital retinoblastoma should have a systemic evaluation to identify other sites of metastasis. Additionally, regional lymph nodes should be palpated and biopsied if suspected to be involved [18].

Treatment of orbital retinoblastoma is a challenge and there is not a definite proven treatment protocol [24]. A multimodal therapy with systemic chemotherapy, orbital exenteration, and external beam radiotherapy (EBRT) is probably the best approach [18,24]. Multimodal therapy is likely the reason why survival has increased in the last few years at least in developed countries. There is still a lot to be done in developing countries regarding access and improvement of medical care, population awareness and education, in order to prevent delayed diagnosis.

Orbital cellulitis

It is also very uncommon to see retinoblastoma presenting as orbital cellulitis (Figure 2). However, some series showed that it may be the case in up to 15 % of all clinical presentations [25]. The pathogenesis surrounding the development of cellulitis is unknown but possible explanations include immune response, generated by a contralateral affected eye or by necrotic tumor byproducts. Interestingly, bacteria does not seem to be implicated [26].

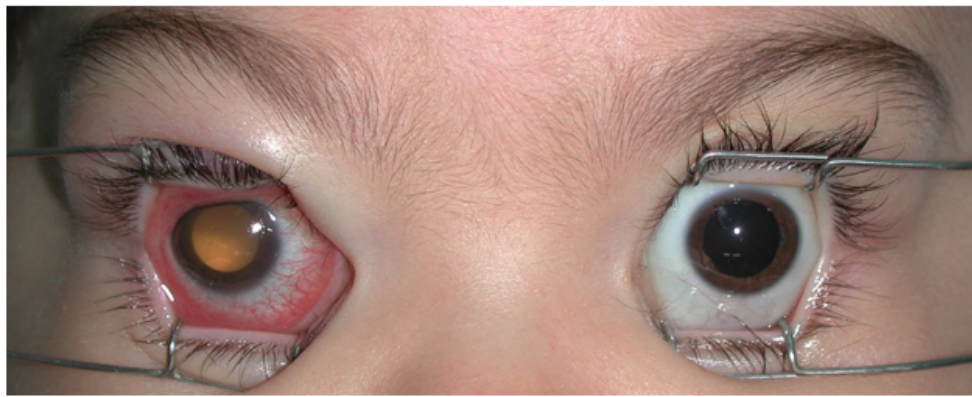

Figure 2: External photograph shows a 20 month-old child with unilateral retinoblastoma and signs of orbital cellulitis that include eyelid swelling and hyperemia; conjunctival hyperemia and chemosis presentation; and pain. There is an associated xanthocoria that is evident when the pupil is dilated.

Clinically, this presentation is almost always associated with large necrotic intraocular tumors although the presence of a large necrotic intraocular tumor does not necessarily imply orbital involvement [26]. Anterior segment involvement has also been suggested as a cause of orbital inflammation [27].

Orbital imaging is mandatory to exclude extraocular extension. The sclera however, may be indistinct on imaging tests making it difficult to exclude tumor extension into the orbit [26].

Management of orbital cellulitis associated with retinoblastoma is based on intravenous steroids. Enucleation frequently follows as most of the times a big intraocular necrotic mass occupying 80 to 100% of the globe is present, with anterior segment involvement [27]. This is an important differential diagnosis in young children presenting with orbital inflammation [27,28].

Phthisis bulbi

Phthisis bulbi is an uncommon presenting sign of retinoblastoma that often occurs after an episode of ocular inflammation possibly related to intraocular tumor infarction [26] (Figure 3). Phthisis bulbi as initial presentation accounts for 0,5% to 3,5% of retinoblastomas

[14,25,26]. The age of diagnosis can vary from 2 to 72 months, and such cases may be unilateral or bilateral [26,29] with a high prevalence of bilateral cases [29,30]. The diagnosis may be more challenging in unilateral cases because frequently the intraocular tumor is unidentifiable. However, in bilateral retinoblastoma, the tumor in the contralateral eye provides the necessary information. This form of presentation is usually associated with advanced intraocular disease [26,29]. The association of phthisis bulbi and buphthalmos in the contralateral eye of a child with bilateral retinoblastoma has been described in the literature [31].

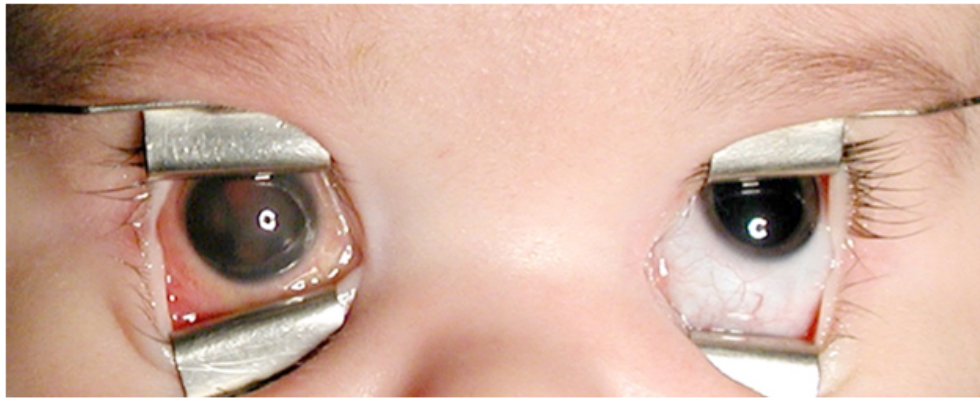

Figure 3: External photograph shows an 11 month-old child with bilateral retinoblastoma and unilateral phthisis bulbi at presentation. Due to the inflammatory signs, epiphora and mucous discharge, this child was initially diagnosed with unilateral conjunctivitis and had been followed for 2 months by a pediatrician.

The physiopathology of phthisis bulbi in eyes with retinoblastoma is not completely understood but the potential explanations include occlusion of the central retinal vessels causing infarction, tumor necrosis, and inflammation; prior ocular trauma; and infection such as endophthalmitis, panophthalmitis [26,31,32].

Clinically, these eyes have been described as small hypotonous globes usually associated with corneal and lens opacity making it impossible to identify the intraocular tumor [26,29]. CT scans are important to identify the intraocular mass and calcification that is frequently associated with this presentation [26,29,33]. Optic nerve and extrascleral involvement may be present in these cases [26,29].

Enucleation is the treatment of choice since these eyes lack visual potential and usually harbor advanced disease [26,29,31,32]. This type of presentation must be suspected when a young child presents with inexplicable phthisis bulbi.

Pseudohypopion and iris abnormalities

Anterior segment presentations of retinoblastoma are atypical, infrequent and described scarcely in the literature. Variable percentage frequencies are encountered depending on the case series [10,11,14,25,34,35]. Different anterior presenting signs can be challenging to distinguish and have the potential to delay diagnosis of retinoblastoma. Such presenting signs include pseudo-hypopion, hyphema, buphthalmos, anterior chamber cells, iris nodules, cataract, iris neovascularization, corneal opacity due to exposure keratopathy, band keratopathy, cornea edema and corneal blood staining [10,14,34,35] (Figure 4). A case series from Taiwan describes Buphthalmos the second most frequent presenting sign reaching 35,4% of cases [16]. Anterior segment presentations are generally associated with advanced disease precluding the view of the posterior segment and making it difficult to identify the intraocular tumor. Ocular ultrasound and CT scan are important to identify the posterior tumor and calcifications. Fine needle aspiration biopsy (FNAB) through clear cornea may be used in selected cases to confirm the diagnosis. Differential diagnosis in these cases include a variety of inflammatory (sarcoidosis, Idiopathic uveitis, pars planitis, juvenile rheumatoid arthritis), infectious (toxocara, fungus) and neoplastic (leukemia, lymphoma, metastatic neuroblastoma tumor) conditions.

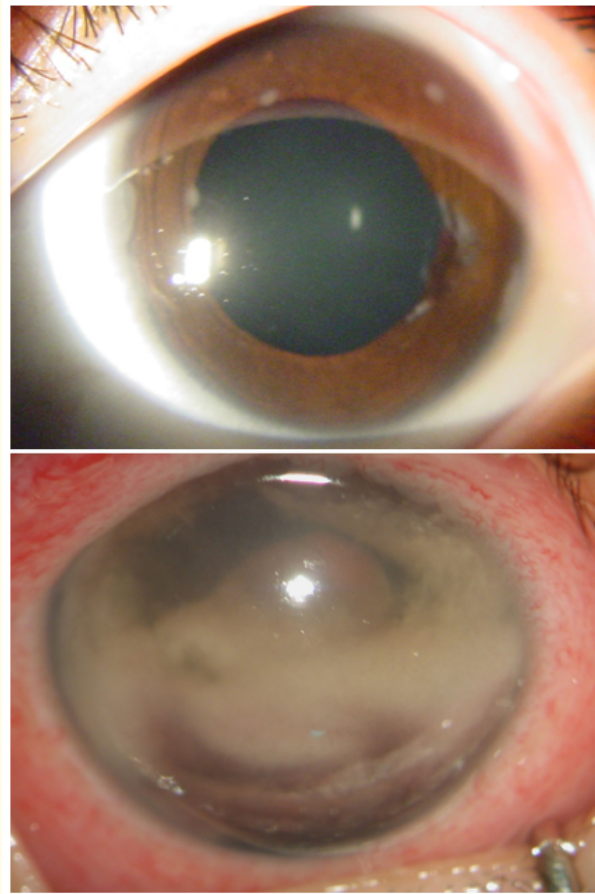


Figure 4: External photographs of 2 children with anterior segment presentation of retinoblastoma. Top photograph shows tumor seeds in the anterior chamber that may be easily mistaken as iris nodules. Bottom photograph shows dense seeding of the anterior chamber causing a pseudo-hypopyon and associated iris neovascularization with secondary hyphema. In this case, media opacity precluded any view of the posterior segment.

Enucleation is the treatment of choice for most retinoblastoma eyes with anterior segment invasion. However, such management may change with the progress of intravitreal/intracameral chemotherapy. Interestingly, it seems that anterior segment invasion does not increase the risk of extraocular relapse [36]. Because this form of presentation even more unusual, a great degree of suspicion is important when evaluating young children with anterior segment anomalies.

Diffuse anterior presentation

The term diffuse anterior retinoblastoma was first described in 1998, in a case report of a 6 years old girl with unilateral anterior segment inflammation and elevated intraocular pressure misdiagnosed as *Toxocara* endophthalmitis. In this case, the tumor was involving the anterior vitreous, lens, ciliary body, iris and anterior chamber. Only a small focus of intraretinal tumor was found on histopathological examination of the enucleated eye [37]. This presentation is an uncommon variant of diffuse infiltrating retinoblastoma in which a small focus of intraretinal tumor is usually present in the peripheral retina that is seeding the aqueous humor, resulting in an anterior segment presentation [38]. Sometimes retinal involvement is not evident on dilated fundus exam and even on histopathological examination [39]. Different explanations for the absence of a prominent retinal tumor include tumor self-arrest, tumor genesis from a heterotopic retinal stem cell in the anterior segment, and very small retinal tumor that may be missed in the clinical and pathology examinations [39]. This clinical presentation of retinoblastoma is mostly sporadic but a hereditary case as been published in the literature [38].

Diffuse anterior retinoblastoma is usually unilateral and occurs in older children between 3 and 12 years of age [38,40]. The anterior segment signs include cells in the anterior chamber (and occasionally posterior chamber) and keratic precipitates mimicking uveitis [40], pseudohypopyon mimicking endophthalmitis [38,40] and elevated intraocular pressure [39,40]. Fundus examination may be normal or a small retinal tumor can be found. Although FNAB carries a risk of extraocular dissemination, it may be indicated to confirm the diagnosis in suspicious cases. Such procedure should be performed through clear cornea to minimize the risk of orbital spread.

The treatment of diffuse anterior retinoblastoma is almost always enucleation followed in some cases by systemic chemotherapy and external beam radiation (EBRT) [40].

Diffuse infiltrative involvement

The concept of diffuse infiltrative clinical presentation of retinoblastoma was introduced in 1958, although such cases had been described before [41]. The first series of diffuse infiltrative retinoblastoma published in 1960 included 4 patients presenting with hypopyon and 3 of them had elevated intraocular pressure [42]. Subsequently, the largest series published, to our knowledge, included 34 cases by Shields and coworkers in 2008 [43-49].

This particular presentation is characterized by a diffuse growth pattern with minimal vertical component and ill-defined margins that can extend to the anterior chamber, trabecular meshwork, iris, ciliary body and vitreous. Invasion of the choroid or optic nerve can also occur [41-43]. Calcification is not as common as in other growth patterns of retinoblastoma [43,45]. Because only 1.4 to 2% of all retinoblastomas present a diffuse growth pattern, diagnosis is frequently delayed. Presenting signs are usually related to anterior chamber involvement, pseudohypopyon, uveitis, iris neovascularization, tumor seeds in the iris and corneal endothelium, hyphema, vitreous hemorrhage, retinal detachment and elevated intraocular pressure although leukocoria can be the first sign detected [43-48].

Anterior chamber biopsy is referred by some authors as being essential in the differential diagnosis [41,42,45] although the risk of tumor seeding should not be excluded [43]. In the majority of cases clinical observation is sufficient to make the diagnosis.

The mean age of diagnosis of diffuse retinoblastoma is 4 years of age [44,50]. The majority of cases are unilateral but bilateral cases have been reported [43].

Histopathology of eyes with this growth pattern shows poorly differentiated cells associated with scarce rosette formation. There is low malignant potential related to diffuse retinoblastoma and good prognosis, however, patients are usually diagnosed in advanced stages (ICIR groups D and E) [41,50].

Because this retinoblastoma presentation is usually diagnosed in advanced stages, enucleation associated or not with systemic chemotherapy has shown to be the only effective management option for these patients [41-43].

Conclusion

Although retinoblastoma has been extensively studied and documented, its diagnosis is more challenging than most clinicians acknowledge. This malignancy can masquerade as various ocular or orbital diseases leading to delayed diagnosis that impacts the patient's prognosis significantly. Detailed knowledge of such atypical presentations is likely to be a helpful tool for ophthalmologists and pediatric care providers.

Method of Literature Search

- PubMed and Web of science search of the English language literature using the following terms:
 - Retinoblastoma, clinical presentations
 - Retinoblastoma, atypical presentations

- Retinoblastoma and orbital/proptosis/cellulitis/endophthalmitis/panophthalmitis/hypopyon/uveitis/glaucoma/buphthalmus/ocular hyperemia/Iris neovascularization/Hyphema/phthisis bulbi/microphthalmos/diffuse infiltrating/diffuse anterior/anterior segment
- Search interval: 1960 to present.

The first author reviewed all manuscripts and the selection of references used was based on detailed reports of atypical clinical presentations of retinoblastoma and lack of redundancy.

Disclosures

Neither of the authors has any relevant financial interests to disclose.

Bibliography

1. Institute NC. "PDQ® Retinoblastoma Treatment". Bethesda, MD (2015).
2. Abramson DH and Scheffler AC. "Update on retinoblastoma". *Retina* 24.6 (2004): 828-848.
3. Butros LJ, et al. "Delayed diagnosis of retinoblastoma: analysis of degree, cause, and potential consequences". *Pediatrics* 109.3 (2002): E45.
4. Abramson DH, et al. "Retinoblastoma: survival, age at detection and comparison 1914-1958, 1958-1983". *The Journal of Pediatric Ophthalmology and Strabismus* 22.6 (1985): 246-250.
5. Sarafzadeh S, et al. "Familial retinoblastoma with unilateral and unifocal involvement in 2 families". *Archives of Ophthalmology* 126.9 (2008): 1308-1309.
6. Meel R, et al. "Current therapy and recent advances in the management of retinoblastoma". *Indian Journal of Medical and Paediatric Oncology* 33.2 (2012): 80-88.
7. Sah KP, et al. "Retinoblastoma: ten years experience at Kanti Children's Hospital". *JNMA Journal of Nepal Medical Association* 52.192 (2013): 576-579.
8. Ellsworth RM. "The practical management of retinoblastoma". *Transactions of the American Ophthalmological Society* 67 (1969): 462-534.
9. Tarkkanen A and Tuovinen E. "Retinoblastoma in Finland 1912-1964". *Acta Ophthalmologica* 49.2 (1971): 293-300.
10. Bedford MA, et al. "Retinoblastoma. A study of 139 cases". *British Journal of Ophthalmology* 55.1 (1971): 19-27.
11. Abramson DH and Frank CM. "Second nonocular tumors in survivors of bilateral retinoblastoma: a possible age effect on radiation-related risk". *Ophthalmology* 105.4 (1998): 573-579.
12. Balmer A, et al. "[Unusual presentation of retinoblastoma]". *Klinische Monatsblätter für Augenheilkunde* 204.5 (1994): 313-315.
13. Balmer A, et al. "Diagnosis and current management of retinoblastoma". *Oncogene* 25.38 (2006): 5341-5349.
14. Balasubramanya R, et al. "Atypical presentations of retinoblastoma". *The Journal of Pediatric Ophthalmology and Strabismus* 41.1 (2004): 18-24.
15. Leal-Leal C, et al. "A multicentre report from the Mexican Retinoblastoma Group". *British Journal of Ophthalmology* 88.8 (2004): 1074-1077.
16. Kao LY, et al. "Retinoblastoma in Taiwan: survival and clinical characteristics 1978-2000". *Japanese Journal of Ophthalmology* 46.5 (2002): 577-580.

17. Badhu B., *et al.* "Clinical presentation of retinoblastoma in Eastern Nepal". *Clinical and Experimental Ophthalmology* 33.4 (2005): 386-389.
18. Ali MJ., *et al.* "Orbital retinoblastoma: Present status and future challenges - A review". *Saudi Journal of Ophthalmology* 25.2 (2011):159-167.
19. Singh AD., *et al.* "Prognostic factors in retinoblastoma". *Journal of Pediatric Ophthalmology and Strabismus* 37.3 (2000): 134-141.
20. Sanders BM., *et al.* "Retinoblastoma in Great Britain 1969-80: incidence, treatment, and survival". *British Journal of Ophthalmology* 72.8 (1988): 576-583.
21. Abramson DH., *et al.* "Changing trends in the management of retinoblastoma: 1951-1965 vs 1966-1980". *Journal of Pediatric Ophthalmology and Strabismus* 31.1 (1994): 32-37.
22. Ellsworth RM. "Orbital retinoblastoma". *Transactions of the American Ophthalmological Society* 72 (1974): 79-88.
23. Leal-Leal CA., *et al.* "Survival in extra-orbital metastatic retinoblastoma: treatment results". *Clinical and Translational Oncology* 8.1 (2006): 39-44.
24. Ali MJ., *et al.* "Orbital retinoblastoma: where do we go from here?" *Journal of Cancer Research and Therapeutics* 7.1 (2011): 11-14.
25. Noorani SAJ and Shaikh ZA. "Retinoblastoma: clinical picture and grouping at the time of first presentation". *Pakistan Journal of Medical Sciences* 27.5 (2011): 5.
26. Mullaney PB., *et al.* "Retinoblastoma associated orbital cellulitis". *British Journal of Ophthalmology* 82.5 (1998): 517-521.
27. Walinjar J., *et al.* "Retinoblastoma presenting with orbital cellulitis". *Journal of AAPOS* 17.3 (2013): 282-286.
28. Shinder R., *et al.* "Retinoblastoma associated orbital cellulitis". *Ophthalmic Plastic and Reconstructive Surgery* 28.3 (2012): 235-237.
29. Kashyap S., *et al.* "Phthisis bulbi in retinoblastoma". *Clinical and Experimental Ophthalmology* 39.2 (2011):105-110.
30. Maka E., *et al.* "Bilateral Retinoblastoma Presenting with Unilateral Phthisis". *Journal of Pediatric Ophthalmology and Strabismus* (2009).
31. Harrison D., *et al.* "Bilateral retinoblastoma presenting with simultaneous phthisis bulbi and buphthalmos". *Journal of Pediatric Ophthalmology and Strabismus* 40.3 (2003): 161-163.
32. Wolter JR. "Thrombosis of the central retinal artery in retinoblastoma". *The Journal of Pediatric Ophthalmology* 13.2 (1976): 99-102.
33. Jain IS and Singh K. "Retinoblastoma in phthisis bulbi". *All India Ophthalmological Society* 16.2 (1968): 76-78.
34. Chraibi F., *et al.* "Hyphema revealing retinoblastoma in childhood. A case report". *Bulletin of the Belgian Societies of Ophthalmology* 318 (2011): 41-43.
35. Catala-Mora J., *et al.* "[Uveitis masquerade syndrome as a presenting form of diffuse retinoblastoma]". *Archivos de la Sociedad Española de Oftalmología* 84.9 (2009): 477-480.
36. Baroni LV., *et al.* "Anterior segment invasion in retinoblastoma: is it a risk factor for extraocular relapse?" *Journal of Pediatric Hematology/Oncology* 36.8 (2014): e509-e512.
37. Grossniklaus HE., *et al.* "Diffuse anterior retinoblastoma". *Retina* 18.3 (1998): 238-241.
38. Crosby MB., *et al.* "Anterior diffuse retinoblastoma: mutational analysis and immunofluorescence staining". *Archives of Pathology and Laboratory Medicine* 133.8 (2009): 1215-1218.
39. Longmuir SQ., *et al.* "Diffuse anterior retinoblastoma without retinal involvement". *Ophthalmology* 117.10 (2010): 2034-2038.

40. Jijelava KP and Grossniklaus HE. "Diffuse anterior retinoblastoma: A review". *Saudi Journal of Ophthalmology* 27.3 (2013): 135-139.
41. Morgan G. "Diffuse infiltrating retinoblastoma". *British Journal of Ophthalmology* 55.9 (1971): 600-606.
42. Schofield PB. "Diffuse infiltrating retinoblastoma". *British Journal of Ophthalmology* 44 (1960): 35-41.
43. Shields CL., et al. "Clinical spectrum of diffuse infiltrating retinoblastoma in 34 consecutive eyes". *Ophthalmology* 115.12 (2008): 2253-2258.
44. Girard B., et al. "[Diffuse infiltrating retinoblastoma]". *Journal Français D'Ophthalmologie* 12.5 (1989): 369-381.
45. Bhatnagar R and Vine AK. "Diffuse infiltrating retinoblastoma". *Ophthalmology* 98.11 (1991): 1657-1661.
46. Mansour AM., et al. "Diffuse infiltrating retinoblastoma". *The Journal of Pediatric Ophthalmology and Strabismus* 26.3 (1989): 152-154.
47. Liang JC., et al. "Diffuse infiltrating retinoblastoma associated with persistent primary vitreous". *The Journal of Pediatric Ophthalmology and Strabismus* 22.1 (1985): 31-33.
48. Kase S., et al. "Diffuse infiltrating retinoblastoma invading subarachnoid space". *Clinical Ophthalmology* 5 (2011): 861-863.
49. Ghassemi F., et al. "Diffuse infiltrating retinoblastoma coexisting with ocular toxoplasmosis". *International Ophthalmology* 34.1 (2014): 137-140.
50. Sharifzadeh M., et al. "Retinoblastoma in adults: a case report and literature review". *Journal of Ophthalmic and Vision Research (JOVR)* 9.3 (2014): 388-391.

Volume 11 Issue 7 July 2020

© All rights reserved by Rui Guilherme Castela and Zélia M Corrêa.