

## Femtosecond Laser Assisted Deep Anterior Lamellar Keratoplasty for Keratoconus: Technique and Results

Malyugin B, Pashtaev A\* and Izmailova S

FGAU "MNTK" Eye Microsurgery" Named. Acad. S.N. Fedorova, Ministry of Health of the Russian Federation, Russia

**\*Corresponding Author:** Pashtaev A, FGAU "MNTK" Eye Microsurgery" Named. Acad. S.N. Fedorova, Ministry of Health of the Russian Federation, Russia.

**Received:** March 16, 2020; **Published:** May 12, 2020

### Abstract

**Purpose:** To analyze and compare the results of treating keratoconus by femtosecond laser-assisted deep anterior lamellar keratoplasty with optimized cutting algorithm (FS-DALK) with traditional deep anterior lamellar keratoplasty (DALK).

**Methods:** It was a randomized prospective study with parallel control. An original technique of FS-DALK with optimized cutting algorithm (AMO IntraLase 60 kHz) allowing to result "mushroom-shape" transplant and recipient's bed edge and avoid using sharp instruments for making big-bubble, was developed. FS-DALK was performed for 34 keratoconic eyes (main group). Control group was compiled of 35 keratoconic eyes, treated by deep anterior lamellar keratoplasty (DALK). The 2 groups were compared in terms of uncorrected visual acuity (UCVA), best spectacle-corrected visual acuity (BSCVA), postoperative astigmatism, endothelial cell loss, central graft thickness and residual recipient's tissue thickness. Also, corneal hysteresis (CH) and corneal resistance factor (CRF) were evaluated before and after surgery in the main group.

**Results:** At 6 months observation UCVA was  $0.21 \pm 0.17$  and  $0.12 \pm 0.13$  ( $p = 0.031$ ), BSCVA was  $0.54 \pm 0.15$ , and  $0.42 \pm 0.14$  ( $p = 0.023$ ) in main and control group, respectively. At 12 months observation UCVA was  $0.29 \pm 0.19$  and  $0.26 \pm 0.2$  ( $p > 0.05$ ), BSCVA was  $0.66 \pm 0.15$  and  $0.54 \pm 0.18$  ( $p > 0.05$ ) in main and control group, respectively. Part of patients achieved BSCVA equal or higher than 0.5 was 97.1% in the main group and 71.4% in the control one ( $p = 0.013$ ). Postoperative astigmatism at 12 months observation was equal to  $3.7 \pm 1.4$  dioptres in the main group and was higher ( $p = 0.04$ ) in the control one ( $4.8 \pm 1.9$  dioptres). Endothelial cell loss (7.4 and 6.1%,  $p > 0.05$ ), central graft thickness ( $506 \pm 20$  and  $521 \pm 28$   $\mu\text{m}$ ,  $p > 0.05$ ) and residual recipient's tissue thickness ( $25 \pm 4$  and  $25 \pm 5$   $\mu\text{m}$ ,  $p > 0.05$ ) were comparable in 2 groups. CH and CRF had improved from  $6.6 \pm 1$  and  $4.8 \pm 1.1$  mm Hg, preoperatively, to  $9.9 \pm 0.7$  and  $9.3 \pm 0.8$  mm Hg ( $p < 0.001$ ) at 1-year observation in the main group.

**Conclusion:** Introducing FS-DALK with optimized cutting algorithm resulted in faster visual recovery, lesser postoperative astigmatism and larger part of patients, achieved BSCVA equal or higher than 0.5. The method also showed improving CH and CRF.

**Keywords:** Keratoconus; Femtosecond Laser; Deep Anterior Lamellar Keratoplasty; Femto-Keratoplasty; Big-Bubble Technique

### Introduction

Keratoconus is a genetically determined progressive dystrophic disease of the cornea, characterized by a violation of its structure due to disorganization of collagen fibers, which leads to a change in the curvature of the front and back surfaces, thinning, optical heterogeneity and a violation of transparency [4,17].

For many years, penetrating keratoplasty (PKP) has been the "gold standard" for radical surgical treatment of keratoconus [5,7]. However, the difficulties of postoperative rehabilitation of patients (long-term visual adaptation, the nature of postoperative ametropia)

[6,19], the risk of transplant rejection, and the low postoperative scar strength [14] have identified trends in the development of deep anterior layered keratoplasty (DALK) technique. The use of the DALK method allows replacing the stroma affected by donor tissue with almost the entire thickness, preserving its own Descemet's membrane (DM) of the recipient and endothelium, which eliminates the potential for endothelial transplant rejection, and also avoids intraoperative complications characteristic of open-sky surgery"; the use of this technique involves faster rehabilitation of patients, including through earlier removal of the corneal suture [2,9]. The indisputable advantage of this technique should also include the expansion of opportunities in the choice of donor material, since endothelial cells density (ECD) of the donor loses its significance.

DALK operation allows achieving high functional results, however, its implementation is associated with technical difficulties associated primarily with a high risk of perforation of the DM at the stage of its separation from the residual posterior stroma [13]. The use of femtosecond (FS) lasers for trepanation of the cornea of the recipient and the preparation of the graft is an actual direction in the development of ophthalmic surgery. FS lasers allow vertical and horizontal slices in the deep layers of the cornea at a precisely specified distance from its front surface and form a transplant and a recipient bed with a complex edge profile and are successfully used for PKP[12,16,18].

The indicated properties of FS lasers make them promising for use in DALKs. There are several techniques that make it possible to partially standardize the DALK procedure [10,11]; however, their description is not exhaustive, and the methods themselves require 4 FS laser launches, which significantly complicates their application in connection with the economic component.

### Aim of the Study

Analysis of the results of deep anterior lamellar femto-keratoplasty with an optimized section formation algorithm (F-DALK) in a comparative aspect with manual deep anterior layer-by-layer keratoplasty (DALK).

### Materials and Methods

We used an IntraLase FS 60 kHz FS laser (AMO, USA) with the following characteristics: wavelength 1053 nm, pulse duration 600-800 femtoseconds, energy 0.5 - 2.5  $\mu$ J.

The clinical study is based on the analysis of treatment results for 69 eyes (69 patients) with stage III-IV keratoconus, according to the classification of M. Amsler. Patients were divided into 2 groups (experimental and control), based on the type of surgical treatment. The experimental group consisted of patients who underwent F-HPPK (34 eyes), the control group consisted of patients who underwent F-HPPK (35 eyes).

The age of patients ranged from 16 to 60 years, on average was equal to  $30 \pm 8$  years.

In the preoperative and postoperative period, the following indicators were assessed: UCVA, best spectacle corrected visual acuity (BSCVA), the magnitude of postoperative astigmatism, loss of endothelial cells (EC), the thickness of the cornea-transplant (host-donor) complex in the central zone, the thickness of the residual posterior layers of the recipient cornea (OCT "Optovue", USA). The viscoelastic properties of the cornea (ORA, USA) were also determined in the main group with the measurement of corneal hysteresis (CH) and corneal resistance factor (CRF).

The results of the study were presented as mean  $\pm$  standard deviation ( $M \pm \sigma$ ). The reliability of the data was evaluated by t-student test for independent cases. The results were considered reliable at  $p < 0.05$ .

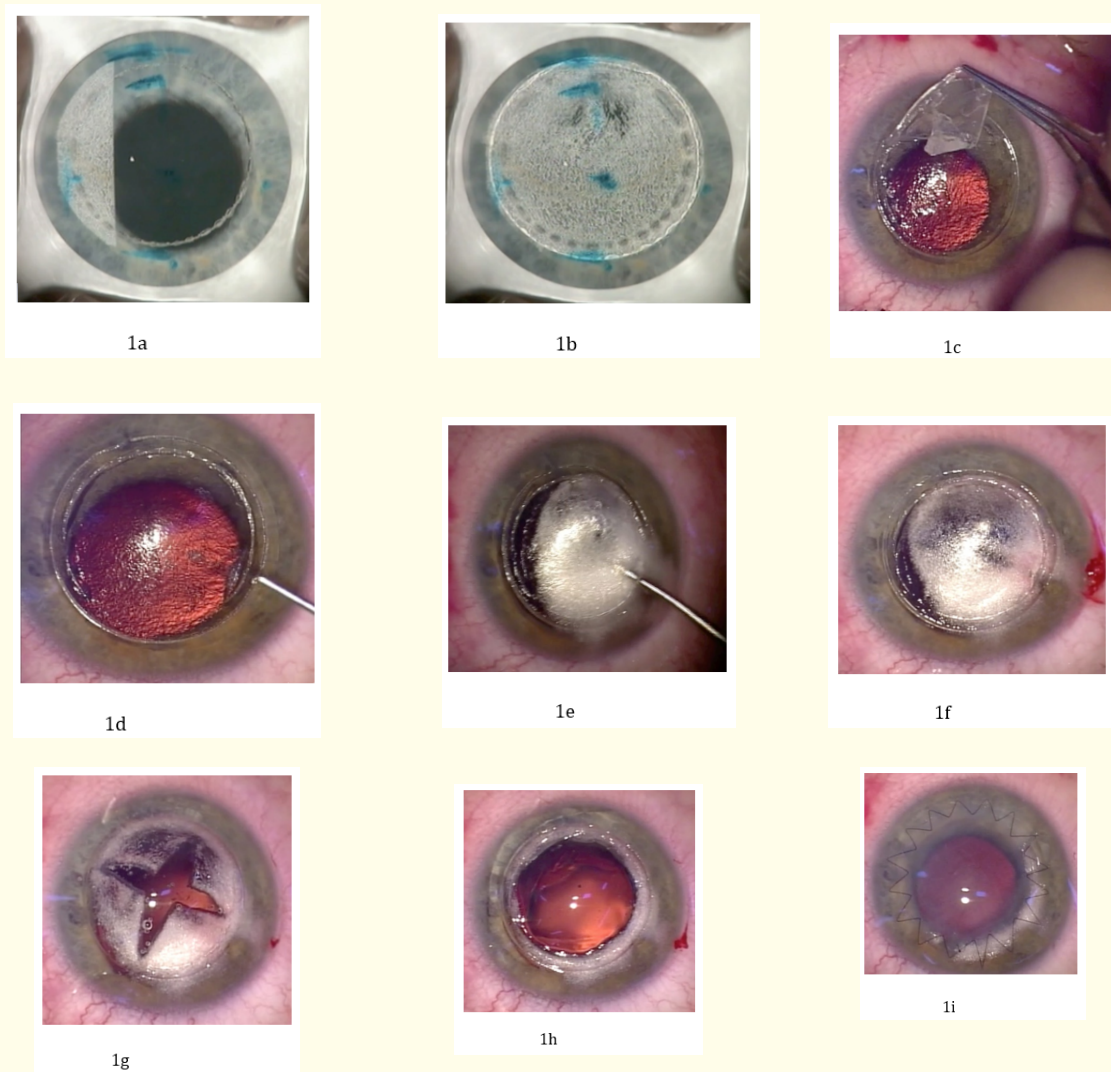
### Operation technique

From the corneal-scleral ring of the donor eye, prepared in the Borzenka-Moroz preservation medium, a graft with an edge profile of the "mushroom cap" type was cut out. The diameter of the graft was 0.1 mm higher than the planned diameter of the recipient's bed. The following parameters of the FS laser !!!!!!!!!!!!! = Femto Laser!!!!!!!! = Femtosecond Laser were used: for the back slice, the distance

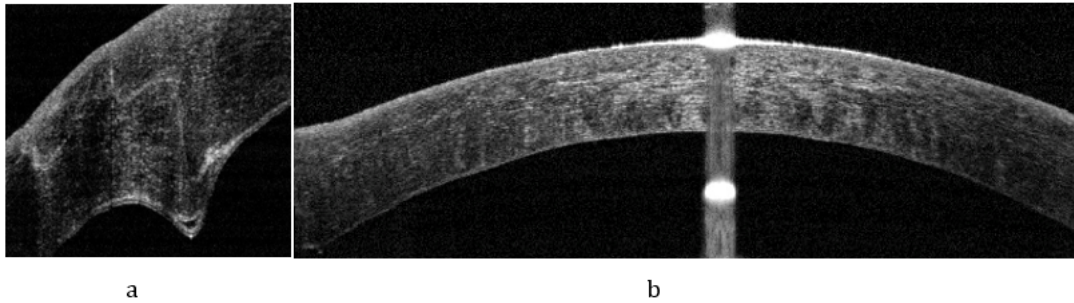
between pulses was 2  $\mu\text{m}$ , the energy was 2.0  $\mu\text{J}$ , and the angle was 90°; for the horizontal component of the trepanation slice, the distance between the pulses is 8  $\mu\text{m}$ , the energy is 2  $\mu\text{J}$ ; for the front cut, the distance between the pulses is 2  $\mu\text{m}$ , the energy is 1.5  $\mu\text{J}$ , the angle is 90°.

The depth of the horizontal component of the trepanation slice in the cornea of the donor (the thickness of the "hat") was calculated by multiplying the depth of the horizontal slice planned for the cornea of the recipient by the hydration coefficient, which was determined after intraoperative ultrasound pachymetry of the graft. For example, if a horizontal section was made in the cornea of the recipient at a depth of 300  $\mu\text{m}$ , and the thickness of the graft in the central zone was 750  $\mu\text{m}$  versus 500  $\mu\text{m}$ , taken as the average value for a de-epithelialized healthy cornea, then the hydration coefficient was 1.5 (750/500) and a horizontal section should be carried out in the cornea of the donor at a depth of  $300 * 1.5 = 450$  microns.

For F-HPPK, a non-through back section with a diameter of 7 mm (1a), a full horizontal section with a diameter of 8.1 mm (1a, 1b) and a front vertical section with a diameter of 8 mm (1b) were formed in the cornea of the recipient. The depth of the back non-through incision was calculated according to the data of optical coherence tomography (OCT) in such a way as to leave no less than 70 microns of tissue in the zone of diameter 7.0 mm. The depth of the horizontal section was calculated as the value of the minimum thickness of the cornea minus 150 microns. The following parameters of the FS laser were used: for the back cut, the distance between pulses was 2  $\mu\text{m}$ , the energy was 1.5  $\mu\text{J}$ , and the angle was 90°; for a horizontal cut, the distance between pulses is 8  $\mu\text{m}$ , the energy is 2  $\mu\text{J}$ ; for the front cut, the distance between the pulses is 2  $\mu\text{m}$ , the energy is 1.5  $\mu\text{J}$ , the angle is 90°. The resulting corneal disc was removed with tweezers (1c). Further, starting from the bottom of a non-through posterior incision, an intrastromal tunnel 3 mm (1e) in length was formed using a spatula towards the center of the cornea. A blunt cannula was inserted into the tunnel with an opening facing the DM, through which sterile air was supplied until the formation of a "big bubble" that separates the DM from the residual stroma (1d, 1f). A cohesive viscoelastic was introduced into the formed bubble. Further, using the corneal scissors, the posterior stroma was excised (1g) and the vertical incision was a continuation of the backless incision formed by the FS laser. After the successful formation of a bed in the cornea of the recipient (1h), DM was removed from the graft with tweezers. The graft was fixed to the bed with a continuous suture according to the standard method (1i).



**Figure 1:** Technique of the operation of the deep anterior layer-by-layer femto-keratoplasty: a - back non-through incision formed in the cornea of the recipient of the FS laser, the beginning of the formation of the lamellar slice; b - a complete lamellar and anterior sections are formed; c - the corneal disk is removed with tweezers; d - the tunnel is formed in the posterior stroma; e - introduction of "air into the tunnel"; f - formed a "big bubble"; g - cruciform dissection of the posterior stroma; h - view of the recipient's eye before the transplant is placed (the edge of the incision is formed as a "mushroom head", there is no visible residual tissue on the DM); and i - view of the eye at the end of the operation.

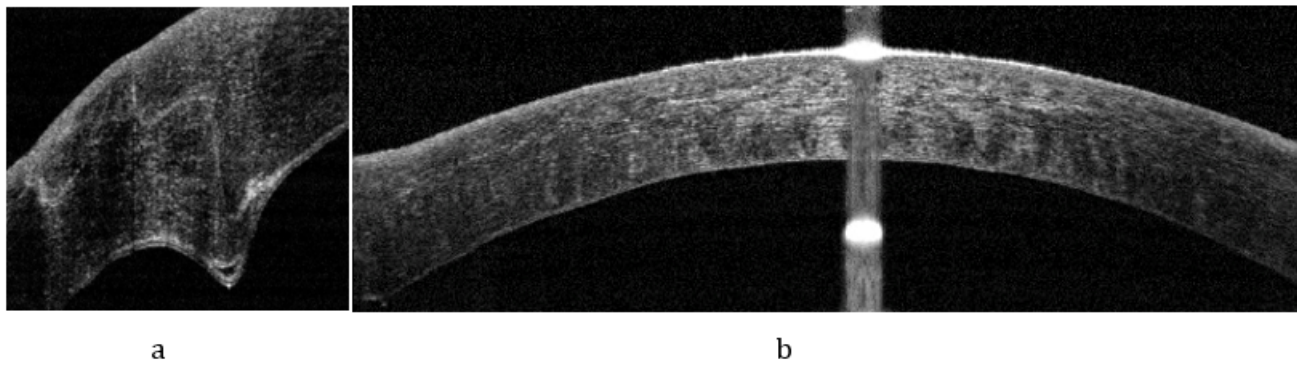


**Figure 2:** Schematic representation of the residual tissue of the cornea of the recipient before the transplant.

## Results

In the group of femto-keratoplasty, the “big bubble” was able to form in 29 (85.3%) cases, in the control - in 26 (74.3%). In the main group, the use of the manual method of cleaning DM from residual stroma was required in 5 cases (14.7%), in the control group in 9 (25.7%).

In the early postoperative period, in all cases, the eye was calm, the anterior chamber was deep and uniform. A completely transparent epithelium-coated transplant was observed. DM adjoined to the latter over the entire area; the donor - recipient interface zone was not visualized. The complete adaptation of DM to the graft was determined by OCT (Figure 3b), in the femto-keratoplasty group, the section profile was visualized according to the “mushroom head” type (Figure 3a), the interface area could not be identified (Figure 3b).



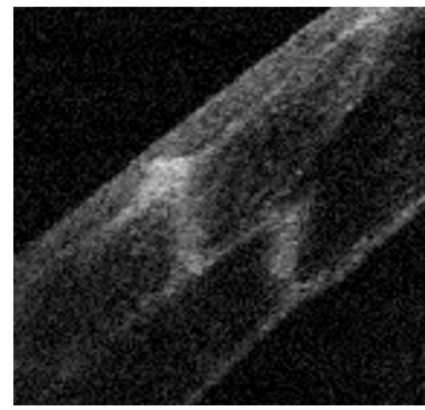
**Figure 3:** OCT of the cornea 7 days after f-DALK. a) The profile of the cut is visualized according to the type of “mushroom cap”. b) DM is adjacent to the transplant throughout the area; the interface area is not visualized.

In both clinical groups there was a gradual increase in visual acuity depending on the duration of observation.

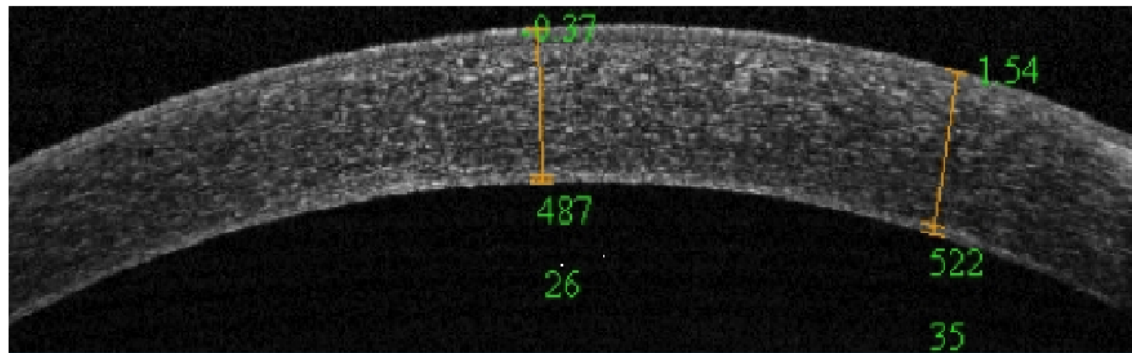
6 months after the operation, the average value of NKOZ and KOZ in the main group was  $0.21 \pm 0.17$  and  $0.54 \pm 0.15$  and in the control group  $0.12 \pm 0.13$  and  $0.42 \pm 0.15$ , respectively. Statistical analysis of the data showed that the difference in the values of uncorrected ( $p = 0.031$ ) and corrected ( $p = 0.023$ ) visual acuity at this observation period is significant.



By year 1, in all cases, transparent graft engraftment was observed. Using OCT, we determined the complete adaptation of DM to the latter (Figure 4b), in the femto-keratoplasty group, a scar was visualized according to the type of “mushroom cap” (Figure 4a), the interface area could not be identified (Figure 4b).



a



b

**Figure 4:** OCT of the cornea 1 year after F-DALK. a) A scar with a profile like “mushroom caps” is visualized b) DM is adjacent to the transplant throughout the cornea; the interface area is not visualized.

After 1 year of observation in the experimental group, the rates of NKOZ and KOZ were  $0.29 \pm 0.19$  and  $0.66 \pm 0.15$ , respectively. The maximum KOZ that was achieved as a result of F-HPPK was 1.0 in 2 patients. In the control group, after 1 year of follow-up, the values of NKOZ and KOZ were  $0.26 \pm 0.2$  and  $0.54 \pm 0.18$ , respectively. The maximum KOZ that was achieved as a result of DALK was 1.0 in 2 patients. A statistical analysis of the postoperative values of NKOZ and KOZ at the follow-up period of 1 year revealed the absence of a significant difference between these indicators in the main and control groups ( $p > 0.05$ ).

A SCR of 0.5 and above for a period of 1 year was achieved in 97.1% of cases in the main group and 71.4% in the control group ( $p = 0.013$ ).

At a period of 1 year, the value of postoperative astigmatism in the main group corresponded to  $3.7 \pm 1.4$  Dptr. The corneal suture was removed in 28 (82%) cases for a period of 6 months after surgery, in 6 (18%) - for a period of 12 months. In choosing the period of removal of the suture, we were guided by the value of the magnitude of astigmatism. If it exceeded 3 diopters, the seam was removed earlier, if it was lower, then the seam remained for up to 1 year.

At a period of 1 year in the control group, the value of postoperative astigmatism corresponded to  $4.8 \pm 1.9$  Dptr. Removal of the corneal suture was carried out in all cases for a period of 8 - 9 months.

A statistical analysis of postoperative astigmatism revealed a significantly lower value in the main group compared with the control group ( $p = 0.04$ ).

PEC in the main group was  $2703 \pm 361$ , in the control group -  $2778 \pm 236$  cells/mm<sup>2</sup>. One year after surgery, these values corresponded to  $2501 \pm 267$  and  $2609 \pm 203$  cells/mm<sup>2</sup>. The loss of EC at 1 year was 7.4% in the main group and 6.1% in the control group ( $p > 0.05$ ).

Before surgery, the pachymetric data corresponded to nosology and amounted to  $377 \pm 31$   $\mu$ m and  $366 \pm 27$   $\mu$ m in the thinnest area in the main and control groups. In the main group, by 1 year after the operation, the minimum OCT of pachymetry corresponding to the thickness of the DM-transplant complex was  $506 \pm 20$   $\mu$ m, in the control group -  $521 \pm 28$   $\mu$ m ( $p > 0.05$ ).

The thickness of the residual tissues of the recipient, measured by the OCT method, in the femto-keratoplasty group was  $25 \pm 4$   $\mu$ m, in the control group -  $25 \pm 5$   $\mu$ m ( $p > 0.05$ ).

The main group also evaluated endothelial status using confocal scanning microscopy, in which parameters such as polymegatism and pleomorphism were calculated, which, before surgery, averaged  $38.9 \pm 3.7\%$  and  $46.5 \pm 9.4\%$ , and one year after -  $39.6 \pm 3.4\%$  and  $44.7 \pm 9.1\%$ , respectively. Statistical analysis of the data showed the absence of a significant difference between before and postoperative indicators ( $p > 0.05$ ).

In the main group, according to the ORA corneal biomechanical properties analyzer, the corneal hysteresis (CH) was  $6.6 \pm 1$  mm Hg. senior, corneal resistance factor (CRF) -  $4.8 \pm 1.1$ . 1 year after the F-HPPK, the values of CH and CRF increased to  $9.9 \pm 0.7$  and  $9.3 \pm 0.8$  mm Hg. st ( $p < 0.001$ ).

## Discussion

As recent studies show, the use of a FS laser makes it possible to partially standardize the layered keratoplasty procedure due to the possibility of reconfiguration and accurate prediction of the depth of cuts [10,11]. In this study, we used a unique scheme of their formation, which allows only in 2 starts of the FS laser to carve out a bed in the cornea of the recipient and a graft with a complex profile of the "mushroom head" type. The proposed algorithm involves the formation of a non-through posterior incision in the cornea of the recipient below the horizontal plane, which makes it possible, after removal of the superficial corneal disc, to obtain a non-through notch in the residual stroma of the recipient to the pre-DM layers. This approach minimizes the risk of perforation of the DM at the stage of introducing air into the posterior stroma, as excludes the use of sharp tools, and the position of the cuts made using the FS laser is calculated according to OCT data [3].

The proposed algorithm made it possible to successfully form an air bubble in a larger percentage of cases compared to the standard DALK. This can be attributed to the fact that the section calculated according to OCT allows the formation of a tunnel for introducing air closer to the DM, as well as the fact that the through back section limits the air outlet to the periphery of the cornea. The difference between the groups is not statistically significant, because the number of cases was not sufficient. However, in accordance with the calculations, if the sample was increased by 2.5 times, the difference of 11% would be statistically significant, which allows us to consider this result as clinically significant.

The complex profile of trepanation, in addition to the above advantages, is a "reserve parachute", if necessary, to convert the operation into UPC, because with the through technique, the suturing is facilitated, and a more durable postoperative scar is obtained, compared to the manual technique [1].

As the study showed, DALK and F-DALK technologies can restore the physiological parameters of the cornea in the transplantation zone. Indicators of the thickness of the residual posterior stroma for a period of 1 year after surgery ( $25 \pm 4$   $\mu$ m in the main group and  $25 \pm 5$   $\mu$ m in the control) indicate almost complete replacement of the affected tissue with donor material.

An important factor affecting the success of surgical treatment is the effect of laser energy on the endothelium of the cornea of the patient during dissection in the deep layers of the stroma. The study demonstrated the safety of using FS 60 FS laser at the indicated settings for the formation of lamellar incisions in the cornea of the recipient, as evidenced by the loss of EC, comparable to that with manual stratification (7.4% in the main group and 6.1% in the control one year after surgery,  $p > 0.05$ ).

It should be noted the high functional results of the treatment. In both clinical groups, there was a gradual increase in postoperative visometry indicators depending on the follow-up time to a maximum SCR of 1.0 by 1 year. Faster visual rehabilitation, however, was observed in the femto-keratoplasty group, as evidenced by higher values of NKOZ ( $p = 0.031$ ) and KOZ ( $p = 0.023$ ) at the follow-up period of 6 months.

The rate of visual rehabilitation and the magnitude of postoperative astigmatism is significantly affected by the period of removal of the corneal suture. The complex configuration of the laser incision allows to significantly increase the area of contacting surfaces, and, accordingly, accelerate healing and increase the strength of the scar, which allows you to remove the seams at an earlier date [1,8,15]. The perfectly even cut, as well as the perfectly round shape of the recipient's bed and transplant, and their high congruence can also be factors that reduce the magnitude of postoperative astigmatism during femto-keratoplasty [12,16,18].

A qualitative result of treatment with a KOZ of 0.5 and higher for a period of 1 year in the femto-keratoplasty group was achieved in 97.1% of cases, which gives us reason to recommend the described technology for wide clinical use.

## Conclusion

The introduction of F-DALK technology with an optimized section formation algorithm allowed increasing the speed of patients' visual rehabilitation, reducing the magnitude of postoperative astigmatism, and increasing the proportion of qualitatively treated patients with a KOZ of 0.5 and higher.

The safety and relative simplicity of the method, ensured by the use of modern diagnostic and surgical equipment, coupled with an increase in the equipment of the clinics, will contribute to its popularization and improve the quality of treatment for patients with keratoconus.

## Bibliography

1. Swan LV and Pozdeeva HA. "Evaluation of the biomechanical strength of the postoperative scar after femtosecond pass-through keratoplasty". *Ophthalmic Surgery* 4 (2012): 18-19.
2. Malyugin BE., *et al.* "Comparative analysis of the clinical and functional results of anterior deep layer-by-layer and through keratoplasty regarding keratoconus". *Ophthalmosurgery* (2013): 4.
3. Malyugin BE., *et al.* "Deep front layer-by-layer keratoplasty using an IntraLase 60 kHz femtosecond laser: first experiment". *Practical Medicine* 4.59 (2012): 100-103.
4. Puchkovskaya NA. "Keratoconus". D. Titarenko. Chisinau: Timlul (1990): 72.
5. Slonimsky AYu. "Possibilities of end-to-end corneal transplantation for various pathologies of the anterior eye segment". *Klin Ophthalmology* 3 (2001): 102-105.
6. Slonimsky YuB., *et al.* "Refractive status and its dynamics after a through corneal transplant. Analysis of long-term observations". In the collection of 4 Russian symposium on refractive and plastic eye surgery, Moscow (2002): 27-29.
7. Al-Mohaimed MM. "Penetrating keratoplasty for keratoconus: visual and graft survival outcomes". *International Journal of Health Sciences* 7.1 (2013): 67-74.
8. Bahar I., *et al.* "Femtosecond laser-assisted penetrating keratoplasty: stability evaluation of different wound configurations". *Cornea* 27.2 (2008): 209-211.

9. Borderie VM, *et al.* "Long-term Results of Deep Anterior Lamellar versus Penetrating Keratoplasty". *Ophthalmology* 119.2 (2011): 249-255.
10. Buzzonetti L, *et al.* "Standardized big-bubble technique in deep anterior lamellar keratoplasty assisted by the femtosecond laser". *Journal Citation Reports* (2010): 1631-1636.
11. Buzzonetti L, *et al.* "Refractive Outcomes of Keratoconus Treated by Combined Femtosecond Laser and Big-bubble Deep Anterior Lamellar Keratoplasty". *Journal Citation Reports* 27.3 (2011): 189-194.
12. Farid M, *et al.* "Comparison of penetrating keratoplasty performed with a femtosecond laser zig-zag incision versus conventional blade trephination". *Ophthalmology* 116.9 (2009): 1638-1643.
13. Janji V, *et al.* "Intraoperative perforation of Descemet's membrane during "big bubble" deep anterior lamellar keratoplasty". *International Ophthalmology Clinics* 30.3 (2010): 291-295.
14. Javadi MA, *et al.* "Deep anterior lamellar keratoplasty versus penetrating keratoplasty for keratoconus: a clinical trial". *Cornea* 29.4 (2010): 365-371.
15. Levinger E, *et al.* "Outcome of "mushroom" pattern femtosecond laser-assisted keratoplasty versus conventional penetrating keratoplasty in patients with keratoconus". *Cornea* 33.5 (2014): 481-485.
16. Price FW and Price MO. "Femtosecond laser shaped penetrating keratoplasty: one-year results utilizing a top-hat configuration". *American Journal of Ophthalmology* 145.2 (2008): 210-214.
17. Rabinowitz YS. "Keratoconus". *Survey of Ophthalmology* 42.4 (1998): 297-319.
18. Steinert RF, *et al.* "Top hat-"shaped penetrating keratoplasty using the femtosecond laser". *American Journal of Ophthalmology* 143.4 (2007): 689-691.
19. Tuft SJ. "Long-term refraction and keratometry after penetrating keratoplasty for keratoconus". *Cornea* 14.6 (1995): 614-617.

**Volume 11 Issue 6 June 2020**

**© All rights reserved by Pashtaev A., *et al.***