

Mooren's Ulcer: Bringing You Down, Down, Down. A Case Report

Faschinger Christoph*

Ophthalmology, Medical University Graz, Austria

***Corresponding Author:** Faschinger Christoph, Ophthalmology, Medical University Graz, Austria.

Received: March 26, 2020; **Published:** April 30, 2020

Abstract

Receiving a satisfying result in difficult cataract surgeries (e.g. advanced pseudoexfoliation, traumatic zonulolysis, red brown nucleus) mainly depends on your skills and your experience. In patients with Mooren's ulcer your knowledge about this (rare) disease will support the quality of your treatment, but you are strongly depended on the reaction of the patient's "body". How does she/he react to your therapeutic measures? We present a patient with Mooren's ulcer on both eyes (not simultaneously) with an unfavorable outcome despite all well-meaning interventions.

Keywords: *Mooren's Ulcer; Pseudoexfoliation; Traumatic Zonulolysis*

Introduction

We as anterior segment surgeons are so spoiled. Almost all of our patients are happy and grateful due to 1) functional improvements (normal far and near visual acuity, brighter colors, more contrast, reduced glare and halos) after cataract surgery or due to 2) cosmetic improvements after squint surgery, plastic lid surgery or botulinum injections. They give us doctors so much positive feedback and input, much easier gained in contrast to colleagues in intensive care units or oncology departments. But sometimes, very rarely, we have to deal with sad courses of diseases, like going blind after an endophthalmitis despite a totally eventless phacoemulsification, or in cases of an aggressive corneal disease like Mooren's ulcer.

Case Report and Discussion

Let me describe a patient we were treating during the last years. In 2012, a 30-year old Caucasian man, truck driver, visited our clinic due to a painful corneal erosion in his left eye. He received antibiotic eye drops, but nevertheless he developed quite quickly a peripheral ulceration in the nasal half, typical for a Mooren's ulcer. The ulcers melted several times in different parts of the cornea or grafts despite the maximum therapies. These treatments consisted of locally administered antibiotics, steroids, artificial tears, Cyclosporin A drops and orally administered steroids (high dose), mycophenolate-mofetil, eventually cyclophosphamid infusions [5]. Application of an amniotic membrane, a penetrating keratoplasty, excision of conjunctiva and Tenon's and a corneal protection procedure according to Putschowskaja [1] were the surgeries performed. Successful within the first weeks only. Should we proceed with further surgeries? Together with the patient we decided to stop all interventions. Finally, a dense white scar of the cornea with anterior synechiae was the sad and discouraging final end-stage. His right eye was normal and healthy.

Five years later, 2018, he presented with painful peripheral epithelial defects in the temporal superior quadrant. Due to the knowledge of the course of his left eye we started with an aggressive local and systemic immunosuppressive therapy (steroids, mycophenolate-

mofetil, Cyclosporin A, cyclophosphamide). Unfortunately, he developed a perforation of his sigma colon, got immediate surgery with a stoma. Was this perforation in association to the immunosuppressive therapy? Again, despite maximum local and systemic therapies he suffered from several melting periods (cornea and grafts) after short-time successful surgeries. These were an amniotic patch, conjunctival resection, 2 lamellar keratoplasties and 2 penetrating keratoplasties (a lot, but this was his "only eye"!). According to a publication with a successful use of an antibody (rituximab) [2] in a few cases we even tried this, without improvements. And again, together with the patient we - both desperate - decided to stop all interventions (and so their adverse advents as well). A corneal scar developed. The uncomfortable stoma was surgically removed. The only happy-making event.

Mooren's ulcer is described as an aggressive inflammatory corneal disease, starting in the periphery and progressing circumferentially and centrally. It is with high probability an autoimmune disease, an association with HLA-DR17 and -DQ2 [3], requiring immunosuppressive treatments. Not all of the patients go well, some of them will show a deleterious outcome [4-6]. And these courses make us - as surgeons used to transfer success and healing - humble. We have to learn how to deal with this situations, to find the right and comforting words to these poor patients (young ones, losing their jobs, losing their independence, minimizing their dignity). Despite all the efforts, despite the highest quality of medicine support: what a sad status in the 21st century. Fortunately, only once within 3 years here.

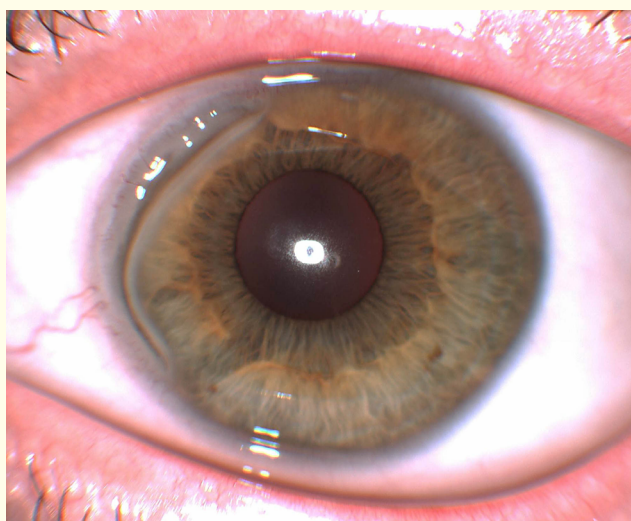


Figure 1: Left eye 2 months after first presentation: crescent shaped ulcer nasally.

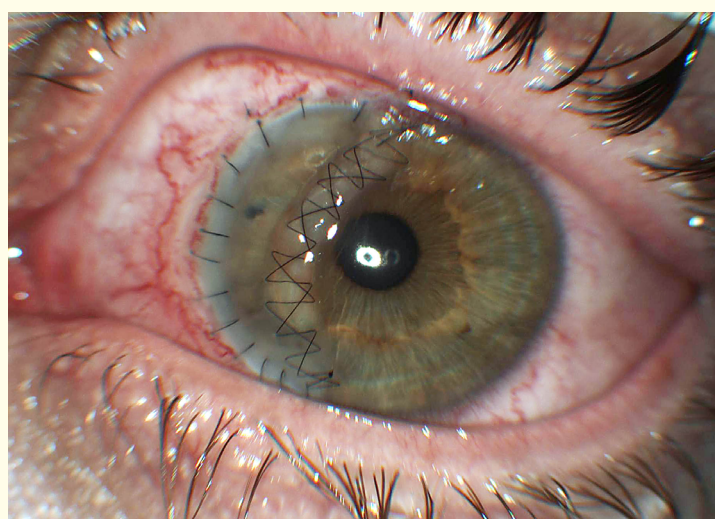


Figure 2: LE: One week after first crescent keratoplasty.

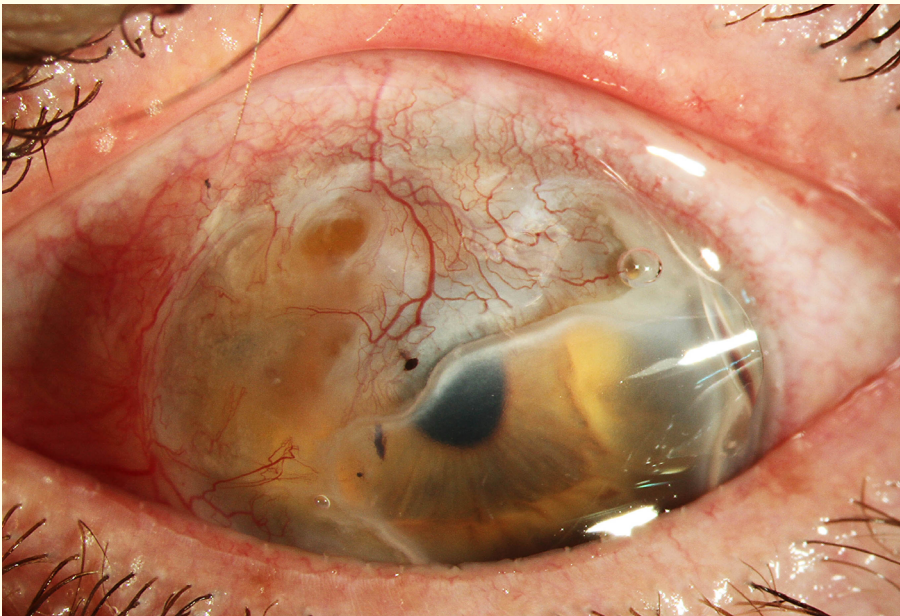


Figure 3: LE: Melting and progression of ulcer one year after first presentation.

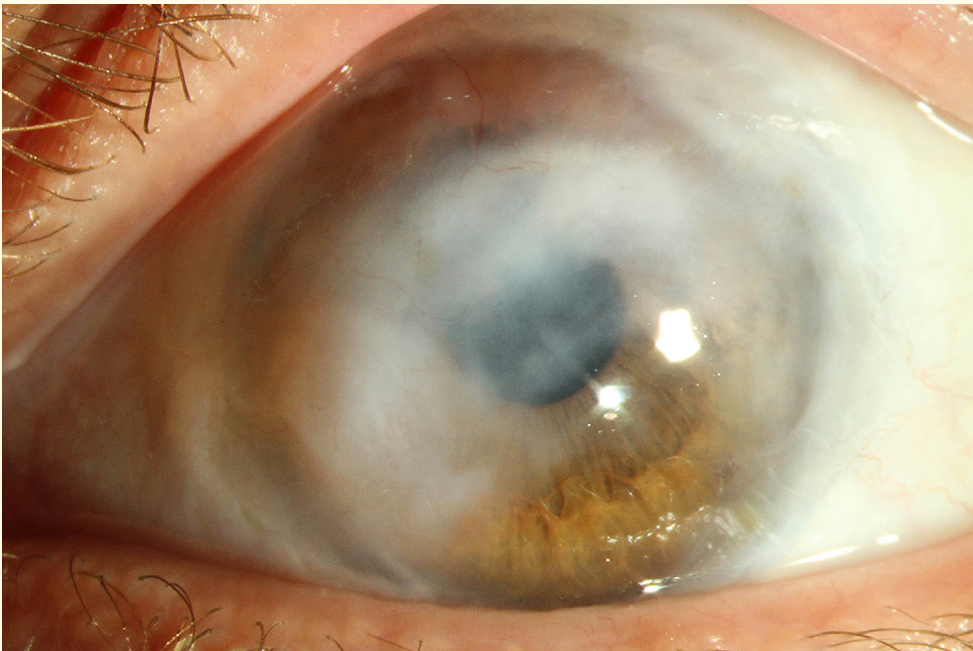

Figure 4: LE: White scar 6 years later.

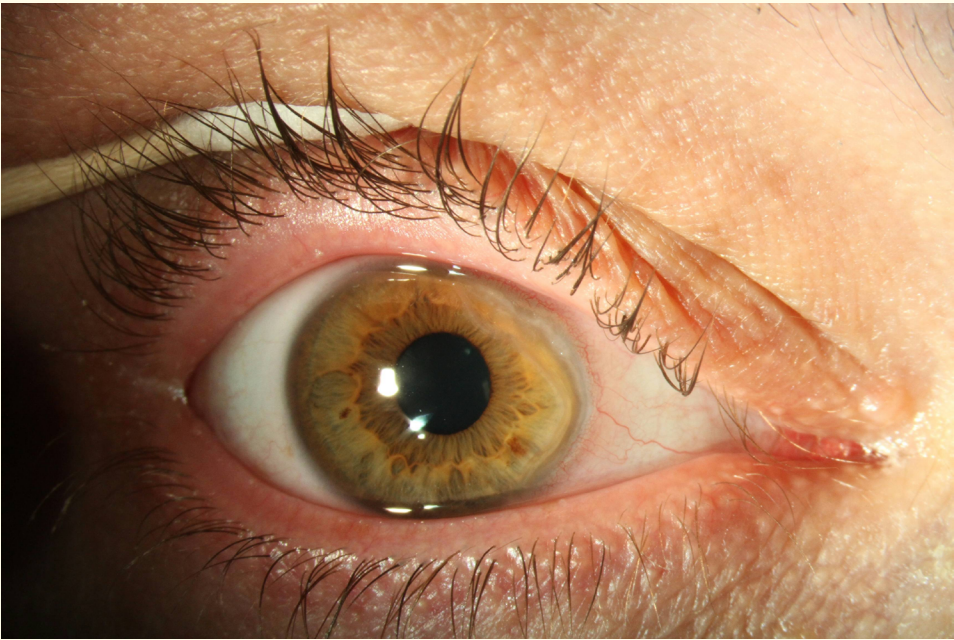


Figure 5: Right eye 3 months after first presentation: crescent shaped ulcer nasally.

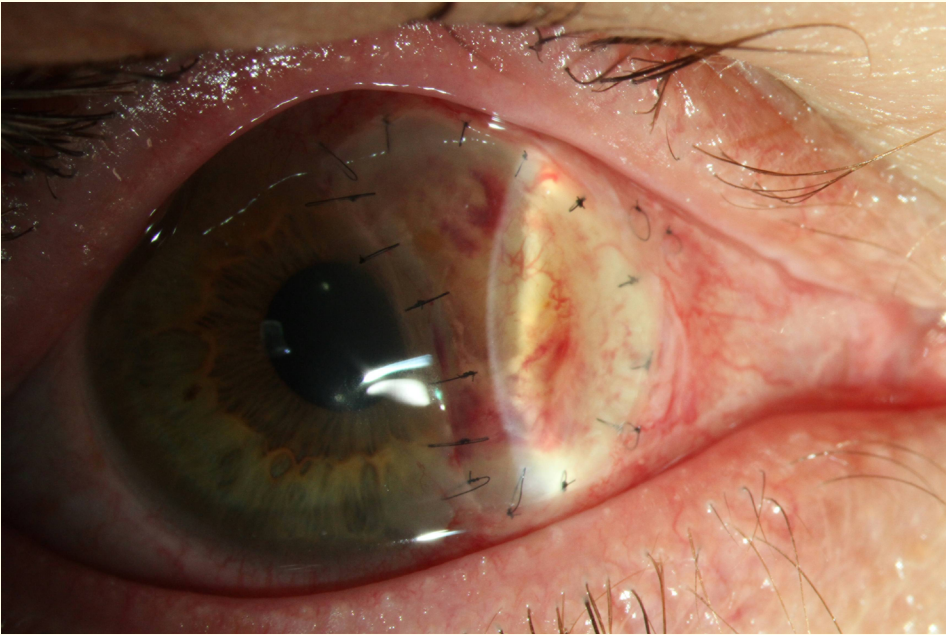


Figure 6: RE: After lamellar keratoplasty.

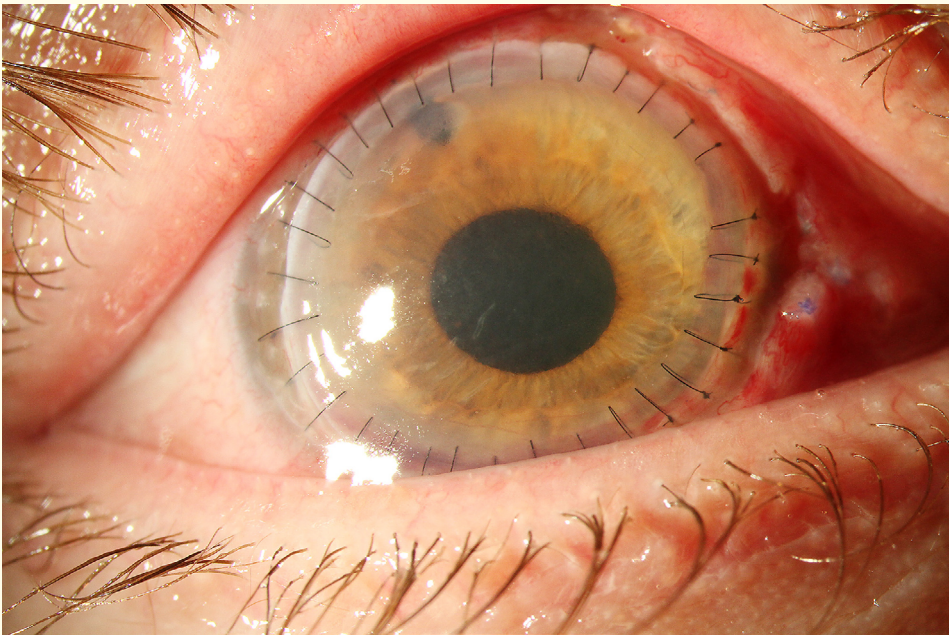


Figure 7: RE: 4 days after 2nd penetrating keratoplasty.

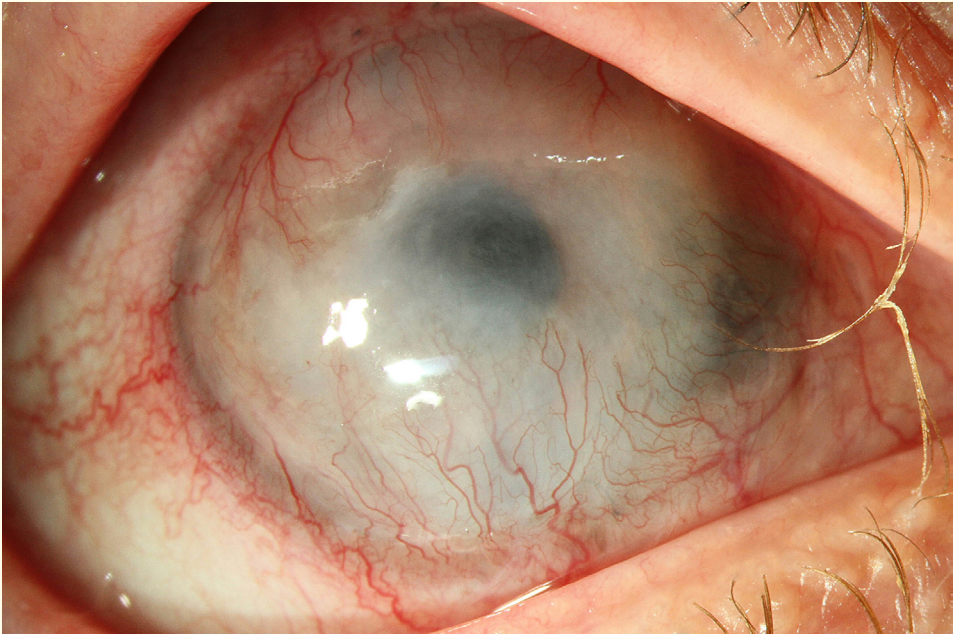


Figure 8: RE: Vascularisation and central thinning 4 months after keratoplasty.

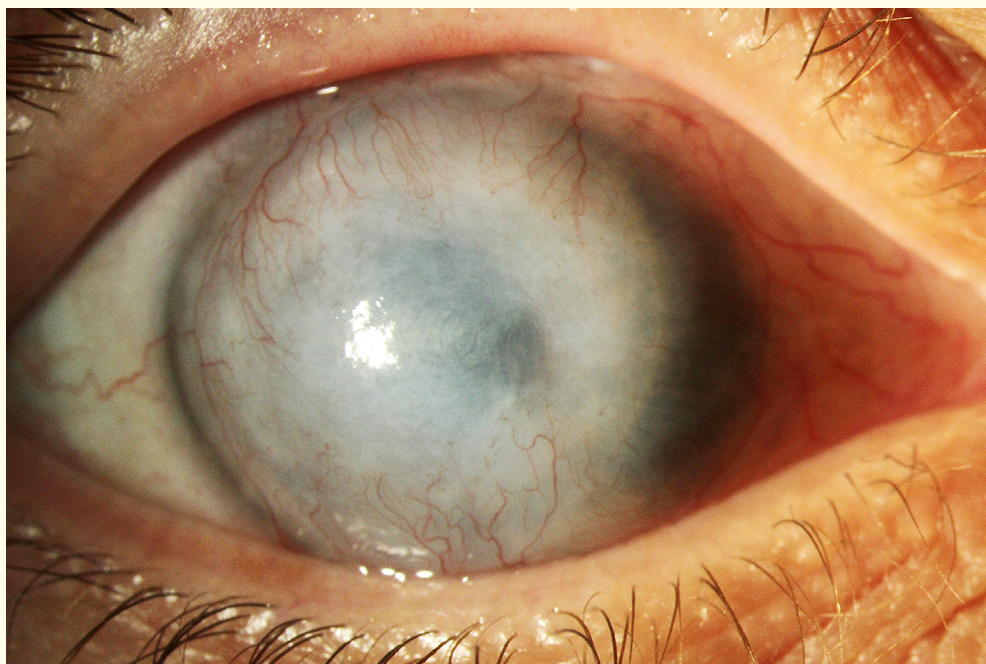


Figure 9: RE: 6 months after keratoplasty, white cornea.

Conclusion

Despite all efforts in locally and systemically administered conservative therapy (with plenty of possible severe adverse events) and several surgeries (with suboptimal prognosis) in the hope of stabilisation or improvement of this progressive disease we were not successful - our patient went almost blind on both eyes. This scenario is quite uncommon in our "over-successful - world of anterior segment surgeries. We are not used to it and have to find the proper way and words to deal with the oncoming consequences for these poor patients. Mooren's ulcer still remains a therapeutic challenge with uncertain outcome.

Disclosure

No financial interests in any products mentioned.

Bibliography

1. Krause A., et al. "Corneal protection according to Putschkowskaja". *Klinische Monatsblätter für Augenheilkunde* 206.3 (1995): 161-164.
2. Guindolet D., et al. "Management of severe and refractory Mooren's ulcers with rituximab". *British Journal of Ophthalmology* 101.4 (2017): 418-422.
3. Taylor GJ., et al. "HLA and Mooren's ulceration". *British Journal of Ophthalmology* 84.1 (2000): 72-75.
4. Stammen J., et al. "Mooren's ulcer: Four severe bilateral courses treated with systemic Cyclosporin A". *Klinische Monatsblätter für Augenheilkunde* 211.5 (1997): 306-311.

5. Dong J., *et al.* "Risk factors, clinical features, and treatment outcomes in recurrent Mooren ulcers in China". *Cornea* 36.2 (2017): 202-209.
6. Sangwan VS., *et al.* "Mooren's ulcer: Current concept in management". *Indian Journal of Ophthalmology* 45.1 (1997): 7-17.

Volume 11 Issue 5 May 2020

© All rights reserved by Faschinger Christoph.