

## Refractive and Biometric Changes after Ahmed Valve Implantation

**Dmitrii Belov\***

*Ophthalmologist, Saint-Petersburg Multifield Hospital, Russian Federation*

**\*Corresponding Author:** Dmitrii Belov, Ophthalmologist, Saint-Petersburg Multifield Hospital, Russian Federation.

**Received:** January 13, 2020; **Published:** January 29, 2020

### Abstract

**Aim:** To assess refractive and biometric changes: spherical equivalent (SE) of refraction, keratometric values, axial length (AL), anterior chamber depth (ACD), intraocular pressure (IOP), visual acuity (VA) after Ahmed glaucoma valve (AGV) implantation.

**Materials and Methods:** In total, 54 eyes of 54 glaucoma patients (21 male and 33 female, middle age  $73,35 \pm 6,9$  years, 44 of 54 cases were pseudophakic patients) undergoing AGV implantation (model FP7, New World Medical Inc., CA, USA). Observation time: from April 2017 to October 2017 (6 months). Refractometry, keratometry, AL measurement, IOP, routine ophthalmological examination (Topcon KR - 8800, IOL-Master 500 Carl Zeiss, iCare) were performed for each patient before tube implantation, on the 1st postsurgical day 1 month and 6 months after surgery.

**Results:** AGV implantation causes mild hyperopic shift of refraction (SE) (from  $-0,26 \pm 1,07$  D to  $-0,13 \pm 1,16$ ,  $p > 0,05$ ) 6 months after tube surgery. There was insignificant AL shortening (from  $23,65 \pm 0,98$  mm to  $23,57 \pm 1,02$  mm,  $p = 0,07$ ) due to IOP lowering (from  $24,40 \pm 2,84$  mmHg to  $16,06 \pm 3,30$  mmHg,  $p < 0,0001$ ). AL and IOP changes have mild but statistically significant positive correlation ( $R = 0,339$ ,  $p = 0,03$ ). There were no significant changes in corneal power (from  $44,08 \pm 1,06$  D to  $43,94 \pm 1,21$  D 6 months after surgery,  $p > 0,05$ ) like no appearance of induced corneal astigmatism (from  $0,98 \pm 0,51$  D to  $1,00 \pm 0,54$  D 6 months after Ahmed valve implantation). Nevertheless, corneal astigmatism axis has significant bias from  $88,62 \pm 39,59$  deg to  $71,38 \pm 41,52$  deg ( $p = 0,03$ ) 6 months after valve implantation. There was certain VA deterioration on the 1<sup>st</sup> postsurgical day from  $0,4 \pm 0,15$  to  $0,23 \pm 0,21$ . Nevertheless, VA came back to baseline level ( $0,38 \pm 0,15$ ) 6 months after surgery.

**Conclusion:** In our study we found significant regress of most altered biometrical parameters to baseline only after 6 months after Ahmed valve implantation. Thus, intraocular lens (IOL) power calculation for patients who requires phacoemulsification (PE) should be performed only 6 months after tube surgery.

**Keywords:** Spherical Equivalent (SE); Axial Length (AL); Anterior Chamber Depth (ACD); Intraocular Pressure (IOP); Visual Acuity (VA); Ahmed Glaucoma Valve (AGV)

### Introduction

Glaucoma is the leading cause of global irreversible blindness. The global prevalence of glaucoma for population aged 40 - 80 years is 3,54%. In 2013, the number of people (aged 40 - 80 years) with glaucoma worldwide was estimated to be 64,3 million, increasing to 76,0 million in 2020 and 111,8 million in 2040 [10].

History of glaucoma surgery has rich background. Trabeculectomy (TE) as "gold standard" of filtering procedure was introduced by J Cairns in 1968 [1]. First glaucoma drainage device (GDDs) was offered by A Molteno in 1969 [8]. In our days both procedures TE and GDDs

actively applied for successful control of IOP. However, application area of GDDs is refractory glaucoma (patient with prior unsuccessful TE, neovascular glaucoma, secondary glaucoma).

There are many studies dedicated to biometrical changes after TE, but there is only one article about refractive changes after AGV implantation. A Miraftabi, *et al.* (2019) found out that AGV implantation leads to statistically significant AL shortening (from baseline  $23,69 \pm 1,95$  mm to  $23,47 \pm 1,91$  mm 3 months after the surgery) due to IOP lowering (from  $33,40 \pm 12,34$  mmHg to  $13,53 \pm 4,33$  mmHg) [7]. B Francis, *et al.* (2005) compared impact of Baerveldt tube shunt implantation and TE on AL values. They found out significant AL reduction in both groups ( $-0,15$  mm for GDD and  $-0,16$  mm for TE) [5].

Understanding of biometrical changes after AGV implantation could reveal cause of temporary vision decline of patients. Precise assessment of biometric parameters as keratometry, AL and ACD is a crucial key factor of successful IOL power calculation in patients who requires PE.

### Aim of the Study

Aim of this study is assessment of refractive and biometric changes: refraction (SE), keratometric values, AL, ACD, IOP, VA after Ahmed valve implantation.

### Materials and Methods

In total, 54 eyes of 54 glaucoma patient (21 male and 33 female, middle age  $73,35 \pm 6,9$  years, 44 of 54 cases were pseudophakic patients) undergoing Ahmed glaucoma valve implantation (model FP7, New World Medical Inc., CA, USA). Observation time: from April 2017 to October 2017 (6 months). Refractometry, keratometry, AL measurement, IOP, routine ophthalmological examination (Topcon KR - 8800, IOL-Master 500 Carl Zeiss, iCare) was performed for each patient before tube implantation, on the 1st postsurgical day 1 month and 6 months after surgery.

Informed consent and ethics committee approval was obtained. This study adhered to the tenets of the Declaration of Helsinki.

Excluding criteria were: low VA (lack of fixation), previous vitreoretinal intervention or buckling, corneal opacity or previous corneal refraction surgery.

### Statistical analysis

Statistical analyses were performed using the SPSS software package version 20,0 (SPSS Inc., Chicago, IL, USA). The relationship between IOP lowering and AL shortening on the 1<sup>st</sup> postsurgical day, at 1 month and 6 months after Ahmed valve implantation was determined by Spearman correlation. A p-value of less than 0,05 was considered statistically significant.

### Results

Changes of refraction (SE), keratometric values, AL, ACD, IOP, VA after AGV implantation are presented in table 1.

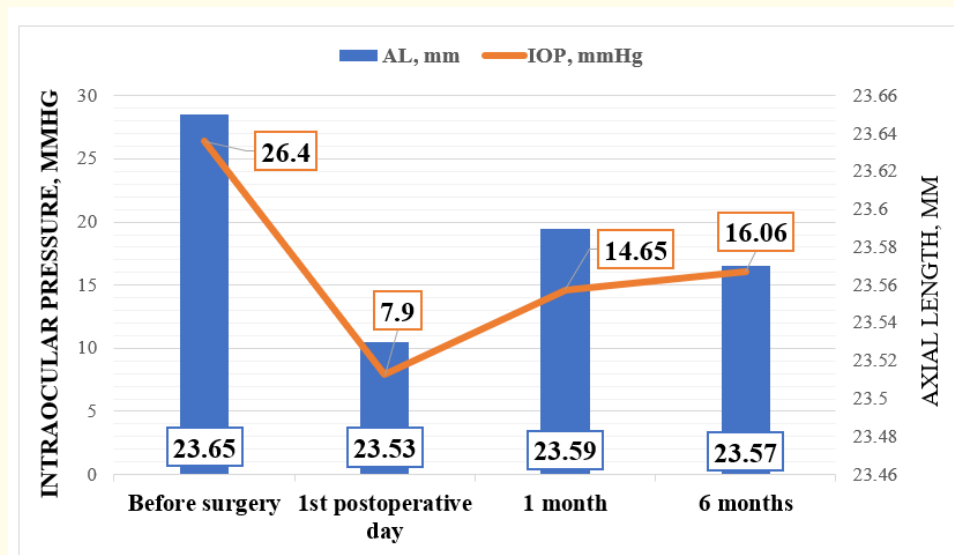
Ahmed valve implantation induced mild hyperopic refractive (SE) shift 6 months after tube surgery (from  $-0,26 \pm 1,07$  D to  $-0,13 \pm 1,16$ ,  $p > 0,05$ ). We found out significant AL shortening on the 1<sup>st</sup> postsurgical day (from  $23,65 \pm 0,98$  mm to  $23,53 \pm 0,99$  mm,  $p = 0,04$ ). Nevertheless, AL values returns to baseline 6 months after AGV implantation (from  $23,65 \pm 0,98$  mm to  $23,57 \pm 1,02$  mm,  $p = 0,07$ ). Shallowing of anterior chamber (AC) was observed in all time points. These changes were statistically significant, 1 month after surgery. ACD almost back to preoperative values 6 months after AGV implantation (from  $3,14 \pm 0,20$  mm to  $3,00 \pm 0,09$  mm). There was significant decrease of IOP in all research checkpoints (from baseline elevated level  $26,40 \pm 2,84$  mmHg to  $7,90 \pm 1,97$  mmHg,  $p < 0,0001$  on the 1<sup>st</sup> postsurgical day, to  $14,65 \pm 3,92$  mm Hg,  $p < 0,0001$  1 month after surgery, and to  $16,06 \pm 3,30$  mmHg,  $p < 0,0001$  6 months after tube implantation). Also, mild but statistically significant positive correlation between IOP lowering and AL shortening was found ( $R = 0,339$ ,  $p = 0,03$ ) (Figure 1).

	Before surgery	1 <sup>st</sup> postoperative day	1 month	6 months
Refraction (spherical equivalent), D	-0,26 ± 1,07	-0,23 ± 1,41	-0,15 ± 1,23	-0,13 ± 1,16
Keratometry, D	44,08 ± 1,06	44,23 ± 1,04	43,99 ± 1,20	43,94 ± 1,21
Corneal astigmatism, D	0,98 ± 0,51	1,4 ± 0,76*	1,04 ± 0,52	1,00 ± 0,54
Corneal astigmatism axis, deg	88,62 ± 39,59	54,35 ± 30,98*	79,04 ± 43,31	71,38 ± 41,52*
Axial length, mm	23,65 ± 0,98	23,53 ± 0,99*	23,59 ± 1,01	23,57 ± 1,02
Anterior chamber depth, mm**	3,14 ± 0,20	2,94 ± 0,12	2,95 ± 0,09*	3,00 ± 0,09
IOP, mmHg	26,40 ± 2,84	7,90 ± 1,97*	14,65 ± 3,92*	16,06 ± 3,30*
BCVA	0,4 ± 0,15	0,23 ± 0,21	0,37 ± 0,15	0,38 ± 0,15

**Table 1:** M ± SD of refraction (SE), keratometric values, AL, ACD, IOP, VA after AGV implantation.

\*: Statistically significant difference was found, p < 0,05.

\*\* : 10 cases for phakic patients.



**Figure 1:** Positive correlation between IOP lowering and AL shortening.

There were no significant changes of corneal curvature after AGV implantation (baseline 44,08 ± 1,06 D versus 43,94 ± 1,21 D 6 months after surgery, p > 0,05). Corneal astigmatism power was stable 6 months after surgery (baseline 0,98 ± 0,51 D and 1,00 ± 0,54 D 6 months after GDDs implantation) except the 1<sup>st</sup> postsurgical day (1,4 ± 0,76 D, p = 0,04). We revealed significant bias of corneal astigmatism axis from 88,62 ± 39,59 deg to 71,38 ± 41,52 deg (p = 0,03) 6 months after valve implantation.

There was certain VA deterioration on the 1<sup>st</sup> postsurgical day from 0,4 ± 0,15 to 0,23 ± 0,21. Nevertheless, VA came back to baseline level (0,38 ± 0,15) 6 months after AGV implantation.

## Discussion

Probably all glaucoma procedures lead to same ocular biometric changes. As TE AGV implantation induce AL shortening due to IOP lowering. First J Nemeth, *et al.* (1992) reported about AL shortening after TE on the 4<sup>th</sup> postsurgical day [9]. Uretmen O, *et al.* (2003) assessed impact of non-penetrating deep sclerotomy (NPDS) on AL values. Mean reduction of AL was  $-0,15 \pm 0,27$  mm (in range from  $-1,37$  to  $+0,12$  mm) 1 month after NPDS. Nevertheless, AL parameters almost back to baseline 12 months after surgery [11]. M Kook, *et al.* (2001) revealed expressed AL shortening ( $-0,83 \pm 1,0$  mm) 3 months after TE with mitomycin C (MMC) application due to intense IOP lowering effect. In our study we found out mild AL decreasing (from  $23,65 \pm 0,98$  mm to  $23,57 \pm 1,02$  mm,  $p = 0,07$ ) which has significant positive correlation with IOP lowering [6]. AL shortening due to IOP lowering most likely associated with increasing of choroidal vessels diameter after glaucoma surgery. X Zhang, *et al.* (2017) assessed relationship between the change in size of the choroidal vasculature and IOP lowering after glaucoma procedures. There was regularity found: mean choroidal vessel thickness increases  $1,5 \mu\text{m}$  for every 1 mmHg decrease in IOP and choroidal interstitial thickness increases  $1,3 \mu\text{m}$  for every 1 mm Hg change in IOP [12].

Shallowing of AC is frequent condition after glaucoma procedures. In our study we found out mild shallowing of ACD in all time points. Nevertheless, this changes almost regressed to baseline level 6 months after AGV implantation. A Diagourtas, *et al.* (2018) assessed ACD after TE. There was same finding expressed in AC shallowing (from  $3,04 \pm 0,39$  mm to  $2,91 \pm 0,47$  mm 8 months after TE) [3].

Unlike TE AGV implantation did not lead to increase of corneal power. P Dietze, *et al.* (1997) assumed that tight suturing of scleral flap leads to local corneal steepening and respectively increased corneal power [4]. In our study AGV implantation has no expressed effect on corneal astigmatism. Nevertheless, induced corneal astigmatism (ICA) is quite frequent finding in early postoperative period after TE. K Claridge, *et al.* (1995) assumed that overhanging filtering bleb, tight suturing of scleral flap and excess cauterizing of sclera leads to appearance of ICA [2].

Probably implantation of a such massive device like Ahmed valve (explant surface area:  $184 \text{ mm}^2$  for FP7 model) and suturing it plate to sclera could lead to mechanical changes in fibrous membrane of eye and result in bias of corneal astigmatism axis (from  $88,62 \pm 39,59$  deg to  $71,38 \pm 41,52$  deg,  $p = 0,03$ ) even after 6 months.

## Conclusion

Ahmed valve implantation causes mild hyperopic shift (from  $-0,26 \pm 1,07$  D to  $-0,13 \pm 1,16$ ,  $p > 0,05$ ) 6 months after tube surgery. There was insignificant AL shortening (from  $23,65 \pm 0,98$  mm to  $23,57 \pm 1,02$  mm,  $p = 0,07$ ) due to IOP lowering (from  $24,40 \pm 2,84$  mmHg to  $16,06 \pm 3,30$  mmHg,  $p < 0,0001$ ). AL and IOP has mild but statistically significant positive correlation ( $R = 0,339$ ,  $p = 0,03$ ). There were no significant changes in corneal power (from  $44,08 \pm 1,06$  D to  $43,94 \pm 1,21$  D 6 months after surgery,  $p > 0,05$ ) like no appearance of ICA (from  $0,98 \pm 0,51$  D to  $1,00 \pm 0,54$  D 6 months after GDDs implantation). Nevertheless, corneal astigmatism axis has significant bias from  $88,62 \pm 39,59$  deg to  $71,38 \pm 41,52$  deg ( $p = 0,03$ ) 6 months after valve implantation.

Glaucoma and cataract are commonly coexisting eye diseases and patients are also at a higher risk of cataract formation or progression following glaucoma surgery. Many glaucoma patients require cataract surgery simultaneously or soon after glaucoma surgery. IOP fluctuation can cause biometrical changes which makes difficult to predict refractive outcomes after cataract surgery. In our study we found significant regress of most altered biometrical parameters to baseline only after 6 months after AGV implantation. Thus, IOL power calculation for patients who requires PE should be performed only 6 months after tube surgery.

## Declaration of Conflicting Interests

The author(s) declared no potential conflicts of interest with respect to the research, authorship, and/or publication of this article.

## Funding

The author(s) received no financial support for the research, authorship, and/or publication of this article.

### Bibliography

1. Cairns JE. "Trabeculectomy. Preliminary report of a new method". *American Journal of Ophthalmology* 66.4 (1968): 673-679.
2. Claridge KG, et al. "The effect of trabeculectomy on refraction, keratometry and corneal topography". *Eye (London)* 9.3 (1995): 292-298.
3. Diagourtas A, et al. "Objective documentation of anterior chamber depth following trabeculectomy and its correlation with intraocular pressure and bleb functionality". *Medicine (Baltimore)* 97.34 (2018): e11824.
4. Dietze PJ, et al. "Visual function following trabeculectomy: effect on corneal topography and contrast sensitivity". *Journal of Glaucoma* 6 (1997): 99-103.
5. Francis BA, et al. "Changes in axial length following trabeculectomy and glaucoma drainage device surgery". *British Journal of Ophthalmology* 89.1 (2005): 17-20.
6. Kook MS, et al. "Short-term effect of mitomycin-C augmented trabeculectomy on axial length and corneal astigmatism". *Journal of Cataract and Refractive Surgery* 27 (2001): 518-523.
7. Miraftebi A, et al. "Ocular biometric changes after Ahmed glaucoma valve implantation". *European Journal of Ophthalmology* (2019).
8. Molteno A. "New implant for drainage in glaucoma. Animal trial". *British Journal of Ophthalmology* 53.3 (1969): 161-168.
9. Nemeth J and Horoczki Z. "Changes in the ocular dimensions after trabeculectomy". *International Ophthalmology* 16 (1992): 355-357.
10. Tham YC, et al. "Global Prevalence of Glaucoma and Projections of Glaucoma Burden through 2040". *American Academy of Ophthalmology* 121.11 (2014): 2081-2090.
11. Uretmen O, et al. "Axial length changes accompanying successful nonpenetrating glaucoma filtration surgery". *Ophthalmologica* 217.3 (2003): 199-203.
12. Zhang X, et al. "The Effect of Change in Intraocular Pressure on Choroidal Structure in Glaucomatous Eyes". *Investigative Ophthalmology and Visual Science* 58.7 (2017): 3278-3285.

**Volume 11 Issue 2 February 2020**

**©All rights reserved by Dmitrii Belov.**