

Bilateral Reduction of Diabetic Macular Edema Following Unilateral Injection of Aflibercept

Sarah N Manz and Roger A Goldberg*

Ophthalmology, Bay Area Retina Associates, Walnut Creek, CA, USA

***Corresponding Author:** Roger A Goldberg, Ophthalmology, Bay Area Retina Associates, Walnut Creek, CA, USA.

Received: January 20, 2020; **Published:** January 29, 2020

Abstract

We report a case in which intravitreal aflibercept appeared to have effects in the contralateral, untreated eye in a patient with bilateral diabetic macular edema. A 55-year-old man with poorly-controlled insulin-dependent type II diabetes received an intravitreal injection of aflibercept in the left eye, with a plan to return the following week for treatment of the right eye. Optical coherence tomography images taken at follow-up one week later showed a marked reduction in intraretinal fluid and central retinal thickness in both eyes.

Keywords: *Anti-Vascular Endothelial Growth Factor (anti-VEGF), Diabetic Macular Edema (DME), Non-Proliferative Diabetic Retinopathy (NPDR), Proliferative Diabetic Retinopathy (PDR), Aflibercept, Eylea, Bilateral, Ophthalmology, Retina, Case Report*

Abbreviations

AMD: Age-Related Macular Degeneration; DME: Diabetic Macular Edema; SD-OCT: Spectral-Domain Optical Coherence Tomography; OD: Right Eye; OS: Left Eye; OU: Both Eyes; VEGF: Vascular Endothelial Growth Factor

Introduction

Vascular endothelial growth factor (VEGF) is a naturally occurring cell-signaling protein that promotes angiogenesis and enhances vascular permeability. Additionally, VEGF serves as an important mediator in the pathogenesis of various retinal vascular diseases including diabetic macular edema (DME). Anti-VEGF therapies are widely used to treat patients with DME. By blocking VEGF activity, vascular permeability is reduced, helping to slow the progress of macular edema and improve visual acuity [1].

Currently, three anti-VEGF agents are widely used to treat DME: bevacizumab (Avastin, Genentech), aflibercept (Eylea, Regeneron), and ranibizumab (Lucentis, Genentech). Many reports of bilateral effects following unilateral bevacizumab and ranibizumab injections can be found in the literature [2-7]. Few reports, however, have shown bilateral therapeutic effects following intravitreal aflibercept injection [8,9].

Here, we report a case in which unilateral injection of aflibercept resulted in bilateral reduction of DME as documented by spectral-domain optical coherence tomography (SD-OCT).

Case Presentation

A 55-year-old male with bilateral DME was referred to a tertiary care retinal clinic for a new vitreous hemorrhage in the left eye. Corrected visual acuity was 20/300 OD and 20/300 OS. Slit lamp exam revealed early nuclear sclerotic cataracts OU, and dilated funduscopy exam was notable for clinically-significant macular edema OU, with severe non-proliferative diabetic retinopathy in the right eye, and proliferative diabetic retinopathy in the left eye with a mild vitreous hemorrhage. OCT confirmed the presence of center-involving DME OU (Figure 1a). The patient was treated with aflibercept 2 mg/0.05 mL OS that day and seen back in clinic four days later. Repeat exam and OCT showed marked improvement in the DME in both the treated left eye, and untreated right eye (Figure 1b). Visual acuity had improved to 20/200 OD and 20/250 OS.

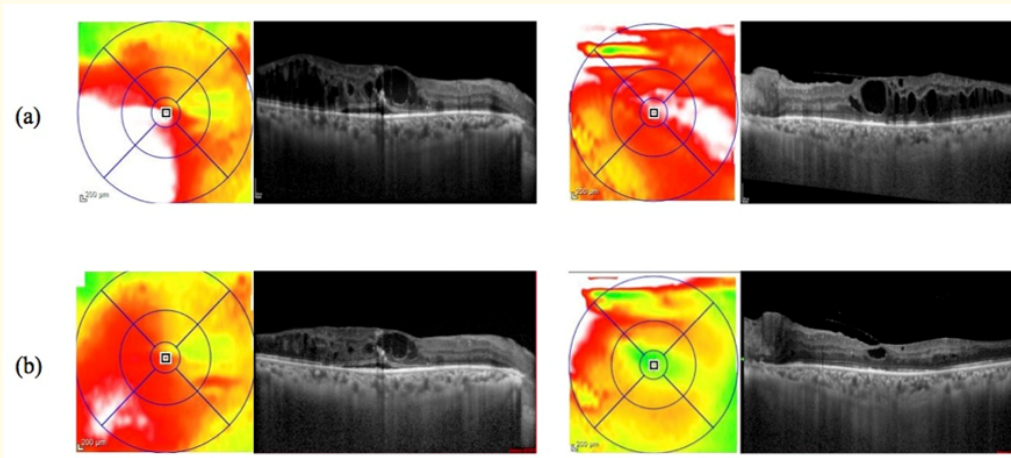


Figure 1: A 55-year-old male with DME OU. Spectral-domain optical coherence tomography (SD-OCT) shows prominent intraretinal fluid OU (a), which improves in both eyes 4 days after treating the left eye with intravitreal aflibercept injection (b).

Discussion

Intravitreal injections enable the delivery of a relatively high dose of VEGF inhibition, with a corresponding low-dose of systemic exposure to these medications. This low systemic exposure contributes to the excellent safety profile of these medications when delivered directly into the vitreous cavity [10-12].

Though bilateral responses have been reported following both bevacizumab and ranibizumab treatment for patients with neovascular age-related macular degeneration (AMD), there appear to be more reports in DME patients [2-6,9]. This may be related to alterations in the blood-retinal barrier in diabetic retinopathy that are greater than what is seen in other retinal vascular diseases like AMD [13].

Bakbak, *et al.* compared unilateral intravitreal bevacizumab and ranibizumab injections and found that administration of bevacizumab resulted in a greater decrease in macular thickness in the untreated eye of patients with bilateral DME [14].

This result suggests that the longer systemic half-life of bevacizumab versus ranibizumab may be causing the greater reduction in fellow eye retinal thickness [15]. However, aflibercept has a similar systemic half-life as that of bevacizumab and both are reported to cause significant reduction of plasma VEGF for transient windows as long as 4 weeks after intravitreal delivery, and longer than the effect exerted by ranibizumab [16-18]. Despite this, markedly fewer reports of fellow eye response to unilateral aflibercept have been reported [8,9].

Conclusion

This case serves as an important reminder, in particular as newer agents with even greater VEGF-inhibitory capacity and/or half-life are developed, to remain vigilant of the systemic effects of our “local” treatment.

Conflict of Interest

The authors declare that they do not have any financial interest or conflict of interest.

Bibliography

1. Semeraro F, *et al.* “Aflibercept in wet AMD: specific role and optimal use”. *Drug Design, Development and Therapy* 7 (2013): 711.
2. Hanhart J, *et al.* “Fellow eye effect of unilateral intravitreal bevacizumab injection in eyes with diabetic macular edema”. *Eye* 28.6 (2014): 646-651.
3. Michalska-Małecka Katarzyna, *et al.* “Effects of intravitreal ranibizumab on the untreated eye and systemic gene expression profile in age-related macular degeneration”. *Clinical Interventions in Aging* 11 (2016): 357.
4. Rotsos Tryfon, *et al.* “Significant reduction of diabetic macular edema following intravitreal ranibizumab injection in the fellow eye”. *International Ophthalmology* 34.6 (2014): 1271-1274.
5. Scartozzi R, *et al.* “Bilateral improvement of persistent diffuse diabetic macular oedema after unilateral intravitreal bevacizumab (Avastin) injection”. *Eye* 23.5 (2009): 1229.
6. Velez-Montoya Raul, *et al.* “The effect of unilateral intravitreal bevacizumab (avastin), in the treatment of diffuse bilateral diabetic macular edema: a pilot study”. *Retina* 29.1 (2009): 20-26.
7. Wu Ziqiang and Srinivas R Sadda. “Effects on the contralateral eye after intravitreal bevacizumab and ranibizumab injections: a case report”. *Annals Academy of Medicine Singapore* 37.7 (2008): 591.
8. Calvo Charles M, *et al.* “Reduction of diabetic macular edema in the untreated fellow eye following intravitreal injection of aflibercept”. *Ophthalmic Surgery, Lasers and Imaging Retina* 47.5 (2016): 474-476.
9. Isildak Hacer, *et al.* “Therapeutic Effect of Anti-VEGF for Age-Related Macular Degeneration in the Untreated Fellow Eye”. *Case Reports in Ophthalmological Medicine* (2018).
10. Cai Sophie and Neil M Bressler. “Aflibercept, bevacizumab or ranibizumab for diabetic macular oedema: recent clinically relevant findings from DRCR. net Protocol T”. *Current Opinion in Ophthalmology* 28.6 (2017): 636-643.
11. Heier Jeffrey S, *et al.* “Intravitreal aflibercept for diabetic macular edema: 148-week results from the VISTA and VIVID studies”. *Ophthalmology* 123.11 (2016): 2376-2385.
12. Nguyen Quan Dong, *et al.* “Ranibizumab for diabetic macular edema: results from 2 phase III randomized trials: RISE and RIDE”. *Ophthalmology* 119.4 (2012): 789-801.
13. Cunha-Vaz JOSE, *et al.* “Early breakdown of the blood-retinal barrier in diabetes”. *British Journal of Ophthalmology* 59.11 (1975): 649-656.
14. Bakbak Berker, *et al.* “Comparison of the effect of unilateral intravitreal bevacizumab and ranibizumab injection on diabetic macular edema of the fellow eye”. *Journal of Ocular Pharmacology and Therapeutics* 29.8 (2013): 728-732.

15. Avery Robert L., *et al.* "Systemic pharmacokinetics following intravitreal injections of ranibizumab, bevacizumab or aflibercept in patients with neovascular AMD". *British Journal of Ophthalmology* 98.12 (2014): 1636-1641.
16. Hirano Takao., *et al.* "Changes in plasma vascular endothelial growth factor level after intravitreal injection of bevacizumab, aflibercept, or ranibizumab for diabetic macular edema". *Retina (Philadelphia, Pa.)* 38.9 (2018): 1801.
17. Huang Chung-Ying., *et al.* "Changes in systemic vascular endothelial growth factor levels after intravitreal injection of aflibercept in infants with retinopathy of prematurity". *Graefe's Archive for Clinical and Experimental Ophthalmology* 256.3 (2018): 479-487.
18. Zehetner Claus., *et al.* "Systemic levels of vascular endothelial growth factor before and after intravitreal injection of aflibercept or ranibizumab in patients with age-related macular degeneration: a randomised, prospective trial". *Acta Ophthalmologica* 93.2 (2015): e154-e159.

Volume 11 Issue 2 February 2020

©All rights reserved by Sarah N Manz and Roger A Goldberg.