ECRONICON OPEN ACCESS

EC OPHTHALMOLOGY
Research Article

The First Experience of Using Anti-VEGF Therapy Prior to Cataract Surgery in Patients with Diabetic Macular Edema

NA Malysheva*

Head of Ophthalmology Department, VIP Center for Diagnostics and Treatment, Nizhny Novgorod, Russia

***Corresponding Author:** NA Malysheva, Head of Ophthalmology Department, VIP Center for Diagnostics and Treatment, Nizhny Novgorod, Russia.

Received: December 19, 2019; **Published:** January 27, 2020

Abstract

Purpose: Assess the effectiveness of anti-VEGF therapy given prior to cataract phacoemulsification in preventing the progression of diabetic macular edema.

Materials and Methods: The retrospective study enrolled 15 patients (15 eyes) with type 2 diabetes who underwent cataract surgery. Group 1 included 8 patients who received anti-VEGF therapy before the surgical treatment. The last injection of aflibercept was performed at least 2 weeks before the surgery, regardless of the central retinal thickness (CRT) increase. Group 2 included 7 patients who did not receive anti-VEGF therapy prior to the surgery. All patients received standard presurgical preparation. The changes in visual acuity and CRT were assessed on days 5 and 14 after cataract extraction.

Results: On day 5, the mean increase of visual acuity was 0.34 ± 0.05 in Group 1 and 0.275 ± 0.07 in Group 2. The mean CRT decrease was 47 μm in Group 1, while Group 2 showed a mean CRT increase of 135 μm. On day 14, the visual acuity was 0.49 ± 0.1 higher than the baseline value in Group 1, while in Group 2 it was 0.21 ± 0.07 lower than on day 5. The mean CRT decrease was 80 μm in Group 1, while Group 2 revealed a 165 μm increase of CRT.

Conclusion: Anti-VEGF therapy prior to cataract surgery on patients with diabetic macular edema should become mandatory for an increased CRT, regardless of visual acuity, since visual acuity measurement is impossible due to cloudy lens environments. The use of aflibercept in patients with clinically insignificant diabetic macular edema 1 month before the planned cataract surgery ensures a positive result of visual acuity increase and improvement of anatomical parameters.

Keywords: *Diabetic Macular Edema; Phacoemulsification of Cataract; Aflibercept*

Introduction

Diabetic macular edema (DME) is a serious complication of diabetes, which, if left untreated, leads to blindness. With the disease duration of 15 years, the DME detection rate is 15% among patients with type 1 diabetes, and 25% among patients with type 2 diabetes [1].

The predominant cause of DME development is microcirculation disorders in the retinal macular zone, accompanied by ischemia and the dysregulation of vascular endothelial growth factor. VEGF is not the only participant of DME development, however, it is the best stud-

ied pathogenesis element which is possible to have effect on and, thus, effectively influence the pathological process. There has been reported an increasing number of data about the involvement of diabetic retinopathy (DRP) and DME of placental growth factor (PIGF) [2,3] into the pathogenesis. PIGF can mediate the development of pathological angiogenesis by direct interaction with its receptor (VEGFR) as well as by increased VEGF-A activity due to competitive binding [4].

Prior to anti-VEGF therapy, retinal laser coagulation remained the standard of DME therapy for a long time. G Meyer-Schwickerath first applied retinal laser coagulation to treat severe DRP in the 50s of the XXth century [5]. In 1968 L Aiello., *et al*. used a ruby laser to achieve DRP regression [6]. In the 70s the argon laser coagulator gained wide distribution which, unlike the xenon laser, possessed dosed exposure which allowed reducing the quantity of postsurgical complications [7]. The subsequent large-scale study by Early Treatment Diabetic Retinopathy Study Research Group (ETDRS, 1985 - 1997) revealed the possibility to reduce the risk of severe vision loss (≥ 15 letters) by performing early focal laser coagulation as a part of DME therapy [8]. Adverse effects of laser treatment (loss of visual acuity, poor color vision, central and peripheral scotomas, serpiginous atrophy) on the retina enabled the search of more sparing methods which would not damage its whole thickness [9]. In 2004 G.F. Kachalina and E.S. Pavlova [10] of S.N. Fyodorov MNTK Eye Microsurgery developed a method of subthreshold retinal laser coagulation for focal and diffuse DME. The therapeutic effect of such treatment includes the production stimulation of proper factors by pigment epithelium cells the most important of which is PEDF (pigment epithelium derived factor) [11,12].

According to the results provided by large randomized clinical trials, laser coagulation in DME patients presently allows only preventing further loss of vision acuity whereas anti-VEGF therapy is able to restore the lost vision [8,13]. At present moment, there are two anti-DME preparations registered on the territory of the Russian Federation: Ranibizumab and Aflibercept. Aflibercept is characterized by a more explicit affinity to VEGF, a prolonged biological activity as well as the ability to bind PIGF which distinguishes it from other anti-VEGF preparations present on the territory of the Russian Federation at this stage [14,15]. Efficacy and safety of aflibercept for DME patients was studied in the course of two Phase III randomized clinical trials similar in their design: VIVID and VISTA. The studies revealed that, compared to retinal laser coagulation, statistically and clinically aflibercept is significantly more efficient for increasing the best corrected vision acuity (BCVA) and inhibiting DME [13]. The increase in visually functional and anatomic parameters after the aflibercept therapy remained up to week 148 of the study [16].

The regimen of the preparation remains, however, an essential issue especially for those patients who only started undergoing the anti-angiogenic DME therapy. Protocol I sub-analysis of the trial performed by DRCR (Diabetic Retinopathy Clinical Research network, USA) showed that anatomic parameters of the macula as well as the vision acuity continue to improve after the 5th and the 6th monthly injections of ranibizumab in 17 and 15% of the patients, respectively. F Ziemssen., *et al.* [17] in a similar manner, when performing the sub-analysis of VIVID and VISTA, showed the importance of having 5 monthly aflibercept injections as part of the anti-DME therapy to minimize the risk of insufficient treatment.

The existing treatment regimens are intended for patients with transparent optical environments. The matter of treating DME patients prior to surgical treatment of cataract is not very well dealt with in the literature.

It is known that the body response to surgical intervention manifests itself in increased activity of the sympathicoadrenal system which can cause acute hyperglycemia, lipolysis, ketogenesis and proteolysis. Advances in the surgical method allowed reducing significantly postsurgical complications. However, the risk of exudative-inflammatory reactions in DM patients increases greatly due to the initially present lesion of the blood-ocular barrier. One of the most severe complications which affects early rehabilitation and causes visual acuity to decrease during the postsurgical period is the cystoid macular edema (CME). As it is known, by traumatizing the eye bulb surgical treatment causes the prostaglandins to release which is especially relevant for the DM patients. Besides, the hydrostatic pressure in the retinal intestitium during the surgery decreases. According to the Frank-Starling law, the intraocular pressure variation during the surgery increases the probability of fluid leakage from the retinal capillaries. This presents a risk factor for the aggravation of the present DME.

According to the literature, the frequency of postsurgical macular edema (ME) in DM patients amounts to 32-81% and is directly dependent on the severity of diabetic manifestations [19], while presence and advance of DRP affect the visual outcome of the operation [20,21]. According to U Eriksson., *et al.* [22], the detection frequency of clinically significant CME in DM patients with non-proliferative DRP having no signs of DME prior to the surgery amounts to 12%. The DRCR.net study established that DME presence prior to the surgery and its history can affect CME advance after the cataract surgery. For instance, 21% of the DM patients with the DME history developed ME involving the macular center after phacoemulsification of cataract while patients having no initial DME did not develop ME involving the macular center [23]. ME in DM Patients after cataract surgery can have two clinical forms: DME and CME. According to the DRCR.net data, fluorescent angiography detected DME in 44% of DM patients after a non-complicated phacoemulsification of cataract, the combination of the two forms appeared in 42% of the cases, whereas the true CME developed only in 14% of the patients [23]. Consequently, the diagnostics as well as the therapy of postsurgical edemas present a number of difficulties.

Given the increased number of cataract surgeries on DM patients, there have presently been an active discussion of efficient ways of postsurgical ME prevention and treatment [24]. Any surgeries on DM patients have a high risk of postsurgical complications caused by DM decompensation or the development of severe hypoglycemic conditions. Cataract surgery on DM patients can only be performed if the parameters of the carbohydrate metabolism are satisfactory (HbAlc less than 7.5%, fasting hypoglycemia less than 7.5 mmol/l, fed hypoglycemia less than 9 mmol/l) [25,26]. It is often the case, however, that the patients do not show sufficient carbohydrate metabolism results due to severe primary condition, and the known literature does not deal well with the tactics of DME patients preparation.

There have been reports on prevention of postsurgical ME development by using the anti-inflammatory effect of non-steroidal anti-inflammatory drugs (NSAIDs), in particular, combined with corticosteroids [27]. American Academy of Ophthalmology (2016) claims the use of NSAIDs to be the most efficient regimen of preventing and treating non-specific inflammation and ME after cataract surgery in high risk groups (including DM patients) [28].

Accumulated data on VEGF involvement into the breakdown of the blood-retina barrier as well as angiogenesis inhibitors development promoted the rise of the pathogenic approach to DME treatment. It allowed concluding on the possible use of anti-VEGF preparation to prevent DME advance after cataract surgery. Up to date, there is no clearly defined algorithm of treating such patients due to the absence of randomized controlled studies which contrast the efficacy of the known methods. The possibility of pre-surgical use of aflibercept in DME patients to reduce the damaging effect of the surgery and consequently, postsurgical DME advance is not well covered. Perfecting the DME advance prevention methods after cataract surgery including the development of an optimal regimen of drug therapy to prevent it in DM patients is considered to be of utmost importance.

Purpose of the Study

Assess the effectiveness of anti-VEGF therapy given prior to cataract phacoemulsification in preventing the progression of diabetic macular edema in DM patients.

Materials and Methods

The present retrospective study includes 15 type 2 DM patients (15 eyes) with DME who underwent cataract surgery. The state of the patients concerning the primary disease (type 2 DM) approximated the compensated one in all the patients which allowed performing cataract phacoemulsification.

The patients were distributed into 2 groups. Group 1 patients (8 participants: 4 men and 4 women), average age of 68.5 ± 2.8 years, received anti-VEGF therapy prior to the surgery. The last injection was administered at least 2 weeks before the surgery regardless of the central retinal thickness (CRT) increase. BCVA prior to the surgery was 0.26 ± 0.05.

Group 2 patients (7 participants: 2 men and 5 women), average age of 70.6 ± 4.9 years, did not receive anti-VEGF therapy prior to the surgery. BCVA prior to the surgery was 0.015 ± 0.200.

Type 2 DM experience in both groups was from 17 to 25 years, glycated hemoglobin level amounted to 8.5-10.2%.

The comorbidities included: hypertonic disease and diabetic nephropathy in one group 2 patient and in two group 1 patients, diabetic polyneuropathy in all group 1 and group 2 patients, bronchial asthma in one group 2 patient.

All the patients underwent a standard pre-surgery examination which included visometry, refractokeratometry, tonometry (the Glautest-60 tonographer), biometry and ultrasound examination of the eye bulb (B-scan Tomey-2000). The macular changes were monitored by optical coherent tomography (OCT) using Cirrus HD-OCT (Carl Zeiss Meditec Inc., Germany) on the Macular thickness analysis program using Macular thickness volume scanning protocols.

The source data of the groups are summarized in table 1.

Groups	Age, years (μ ± σ)	Patients number	Best corrected visual acuity (μ ± σ)	CRP, μm (μ ± σ)	Cataract Density by LOCS III	Duration of diabetes, years (μ ± σ)	Glycated hemoglobin, % (μ ± σ)
1	68.5 ± 2.8	8	0.26 ± 0.05	404 ± 14	N 2-3/C2	19.5 ± 1.2	9.3 ± 0.5
2	70.6 ± 4.9	7	0.015 ± 0.200	388 ± 11	N2-6/C2-C5	22.5 ± 2.1	9.6 ± 0.6

Table 1: *Baseline characteristics of groups.*

All the patients underwent standard presurgical preparation (antibacterial and anti-inflammatory therapy 3 days prior to the surgery). The surgery followed a standard cataract phacoemulsification method including IOL (hydrophobic acryl) implantation. Cataract phacoemulsification was performed in all cases according to the standard technology without any complications. The cataract density was quantified according to the LOCS III classification.

Prior to the surgery group 1 patients received anti-VEGF therapy with 2 mg aflibercept (recommended dosing) as a fixed-dose regimen. By the moment of cataract phacoemulsification, patients of this group received no more than 3 aflibercept injections. 4 out of these patients received 3 uploading doses of anti-VEGF therapy due to marked DME (more than 400 μm thick). Three patients with the average CRT of 356 ± 36 μm received single doses of the preparation a month before the surgery. Unlike our colleagues who used ranibizumab injections during cataract surgery [29], we made a decision to administer aflibercept to patients with a slightly increased CRT no later than 2 weeks before the cataract phacoemulsification because operating on the retina with a maximally compensated pathology leads to a better outcome [30].

The results of the treatment were assessed on day 5 and 15 following the cataract extraction. Vision acuity change and CRT were analyzed.

Statistical processing of the results for the quantitative criteria was conducted using Statistica 10.0 software for Windows. Descriptive statistics results are presented as μ ± σ, where μ is the mean and σ is the standard deviation.

Results and Discussion

On day 5 after the lens exchange the vision acuity of group 1 patients increased by 0.34 ± 0.05 while that of group 2 patients – by 0.275 ± 0.070. CRT in group 1 reduced by 47 μm on average, whereas group 2 patients showed the increase of CRT by 135 μm.14 days after, the

vision acuity of group 1 patients increased by 0.49 ± 0.10 against the baseline level. Group 2 patients' vision acuity, however, decreased on day 14 by 0.21 ± 0.07 against its level obtained by day 5.

On day 14, group 1 patients showed further reduction of CRT which became on average 80 μm less than initially. CRT of group 2 patients increased by 165 μm against the baseline value (Table 2, Figure 1 and 2).

Groups	Day 5 μ ± σ		Day 14 μ ± σ	
	Vis	CRT (μm)	Vis	CRT (μm)
1	0.6 ± 0.16	357 ± 37	0.75 ± 0.13	324 ± 47
2	0.29 ± 0.2	523 ± 30	0.08 ± 0.11	553 ± 13

Table 2: *Visual and anatomical outcomes in DME patients treated and not treated with aflibercept before cataract surgery.*

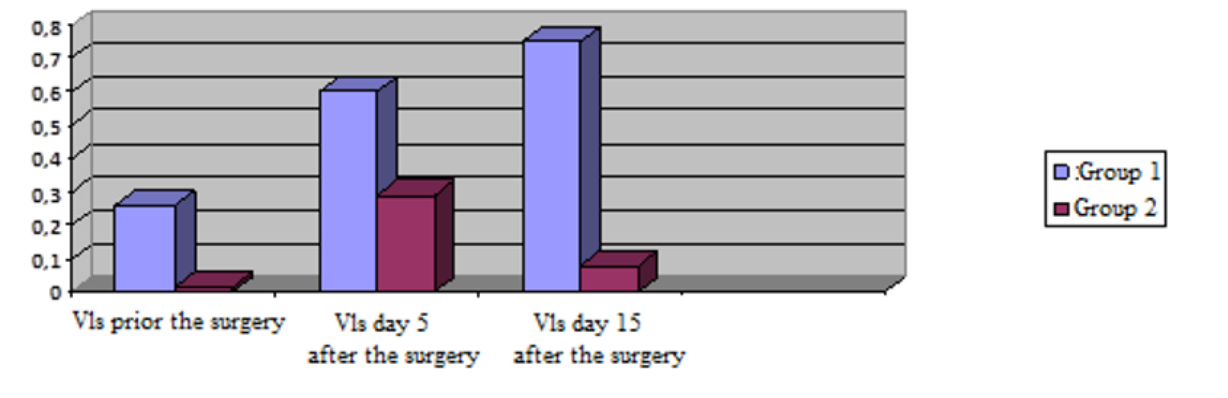

Figure 1: *Vision acuity before surgery and 5 and 14 days after it.*

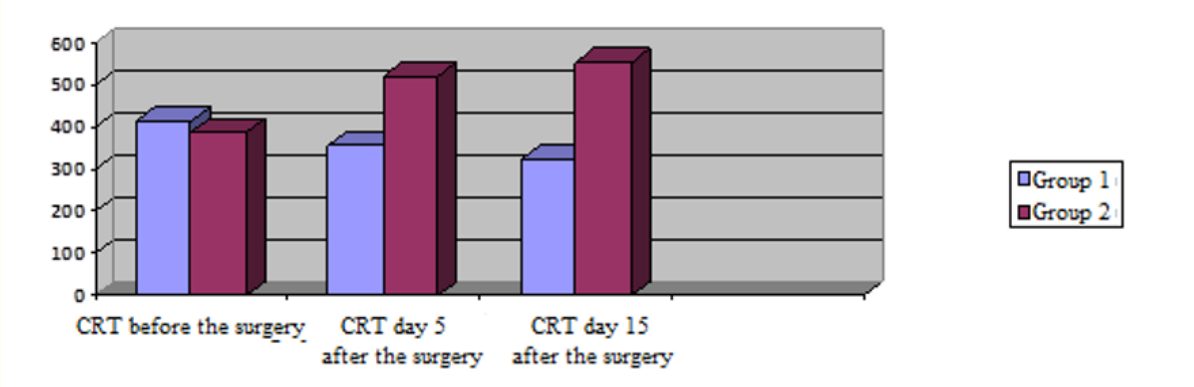

Figure 2: *Central retinal thickness before surgery and 5 and 14 days after it in patients of 1st and 2nd groups.*

Four group 1 participants who received the injection later on did not receive postsurgical anti-VEGF therapy due to the fact that their CRT on days 5 and 14 was on average 267 ± 52 and 257 ± 45 μm, respectively.

Patients who received aflibercept prior to the surgery showed positive dynamics of vision acuity change and CRT following the surgery as opposed to group 2 patients, who did not receive aflibercept injections. As a matter of fact, group 2 revealed a rapid growth of CRT and vision acuity reduction during 2 weeks. This speaks for the advantages of aflibercept use prior to the surgery.

Our data are consistent with the DRCR.net studies [23]. Use of the preparation in DME patients at least a month prior to the surgery shows a markedly positive result which might allow switching these patients to the regimen with fewer injections.

We are presenting a clinical case of treating a group 1 patient. A man, aged 67, with the duration of type 2 DM for about 15 years, was admitted for a planned cataract surgery. Diagnosis at admission: "A complicated cataract of the left eye (N2), open-angle Ia glaucoma of both eyes; a complicated cataract of the right eye (N1-2); non-proliferative DRP complicated by the ME of both eyes. Type 2 DM, diabetic polyneuropathy." General state: satisfactory, arterial pressure: 123/80 mm Hg. The left eye was noticed to be gradually losing visual acuity for the previous 8 months. At admission: Vis OD = 0.6 Vsc, Vis OS = 0.1 Vsc; Maklakov tonometry confirmed OD = 18 mm Hg., OS = 19 mm Hg. The OCT data are presented in figure 3.

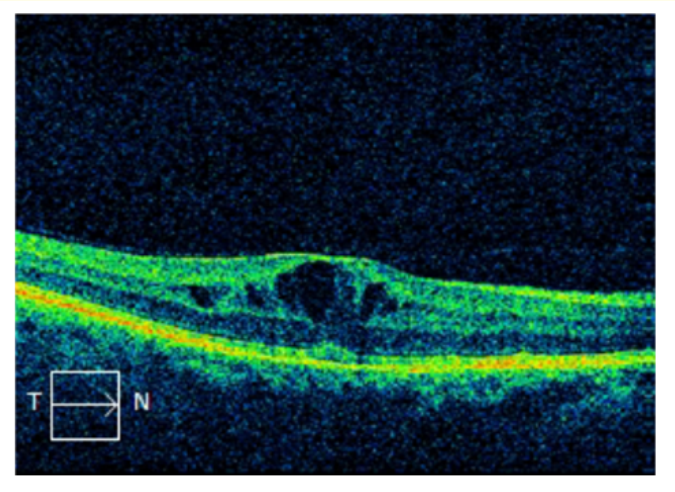

Figure 3: *Clinical case. Diabetic edema of the inner layer of the retina before the intravitreal administration of the drug aflibercept.*

The CRT increase up to 400 μm was detected. An intravitreal aflibercept injection was administered to the patient 2 weeks before the planned surgery. The cataract phacoemulsification with the implantation of intraocular lens (IOL) was conducted in a standard manner.

On day 5 after the surgery, vision acuity increased and CRT decreased down to normal parameters: Vis OS = 0.7 Vsc, CRT = 280 μm. On day 14 vision acuity increased against the day 5 values and was Vis OS = 0.85 Vsc, CRT = 280 μm. The OCT results are presented in figure 4.

The clinical case demonstrates the efficacy of aflibercept use prior to the surgery and a positive outcome obtained as the result.

The present study has a number of serious limitations related to the retrospective nature of data analysis, a small scope of the investigated population and a short follow-up period. It is necessary to conduct a randomized clinical study with a sufficient follow-up period which will allow establishing the tactics of DME patients' treatment and a planned cataract surgery.

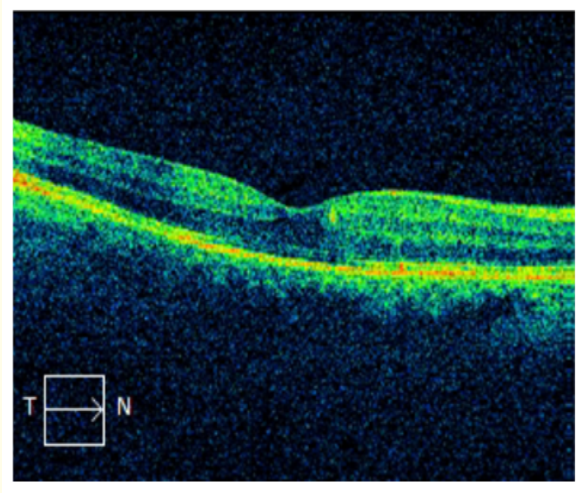

Figure 4: *Clinical case. Normalization of retinal layers architectonics after intravitreal aflibercept injection on day 14 after cataract phacoemulsification with the implantation of intraocular lens (IOL).*

Conclusion

Our first experiment of anti-VEGF therapy using aflibercept in DME patients at least a month prior to the surgery regardless of the visual acuity reveals a positive outcome: visual acuity increase and reduced CRT in the early postsurgical period.

Conflict of Interests

there is no conflict of interests.

Financial Disclosure

No author has a financial or property interest in any material or method mentioned.

Bibliography

1. Moss SE., *et al*. "The 14-year incidence of visual loss in a diabetic population". *Ophthalmology* 105.6 (1998): 998-1003.
2. Ando R., *et al*. "Aqueous humour levels of placental growth factor in diabetic retinopathy". *Acta Ophthalmologica* 92 (2014): e245-e246.
3. Miyamoto N., *et al*. "Placental growth factor-1 and epithelial haemato-retinal barrier breakdown: potential implication in the pathogenesis of diabetic retinopathy". *Diabetologia* 50 (2007): 461-470.
4. Bry M., *et al*. "Vascular endothelial growth factor-B in physiology and disease". *Physiological Reviews* 94.3 (2014): 779-794.
5. Meyer-Schwickerath GRE and Schott K. "Diabetic Retinopathy and Photocoagulation". *American Journal of Ophthalmology* 66.4 (1968): 597-603.
6. Aiello LM., *et al*. "Ruby laser photocoagulation in treatment of diabetic proliferating retinopathy. Preliminary report". Goldberg MF, Fine SL, eds. Symposium on the treatment of diabetic retinopathy. US Government printing office. Washington (1968): 437-465.

7. Riaskoff S. "Light Coagulation Treatment of Diabetic Retinopathy in the Eye Hospital Rotterdam". *Ophthalmologica* 165 (1972): 548-550.

8. ETDRS Research Group. "Photocoagulation for Diabetic Macular Edema. Early Treatment Diabetic Retinopathy Study Report Number 1". *Archives of Ophthalmology* 103 (1985): 1796-1806.

9. Roider J., *et al*. "Subthreshold (retinal pigment epithelium) photocoagulation in macular diseases: a pilot study". *British Journal of Ophthalmology* 84.1 (2000): 40-47.

10. Kachalina GF and Pavlova ES. "Subporogovaya argonovaya koagulyatsiya setchatki v lechenii ochagovoi diabeticheskoi makulopatii". *Oftal'mokhirurgiya* 3 (2004): 43-46.

11. Gao X and Xing D. "Molecular mechanisms of cell proliferation induced by low power laser irradiation". *Journal of Biomedical Science* 16 (2009): 4.

12. Roider J., *et al*. "Response of the retinal pigment epithelium to selective photocoagulation". *Archives of Ophthalmology* 110.12 (1992): 1786-1792.

13. Korobelnik JF., *et al*. "Intravitreal Aflibercept for diabetic macular edema". *Ophthalmology* 121 (2014): 2247-2254.

14. Fauser S and Muether PS. "Clinical correlation to differences in ranibizumab and aflibercept vascular endothelial growth factor suppression times". *British Journal of Ophthalmology* 100.11 (2016): 1494-1498.

15. Papadopoulos N., *et al*. "Binding and neutralization of vascular endothelial growth factor (VEGF) and related ligands by VEGF Trap, ranibizumab and bevacizumab". *Angiogenesis* 15.2 (2012): 171-185.

16. Heier JS., *et al*. "Intravitreal aflibercept for diabetic macular edema: 148-week results from the VISTA and VIVID studies". *Ophthalmology* 123.11 (2016): 2376-2385.

17. Ziemssen F., *et al*. "Initiation of intravitreal aflibercept injection treatment in patients with diabetic macular edema: a review of VIVID DME and VISTA DME data". *International Journal of Retina and Vitreous* 2 (2016): 16.

18. Belousova NYu. "Ekssudativno-vospalitel'naya reaktsiya glaza v khirurgii katarakty: sovremennyi vzglyad na problem". *Sovremennye tekhnologii v meditsine* 3 (2011): 134-141.

19. Pollak A., *et al*. "Cystoid macular oedema following cataract extraction in patients with diabetes". *British Journal of Ophthalmology* 76.4 (1992): 221-224.

20. Henricsson M., *et al*. "Diabetic retinopathy before and after cataract surgery". *British Journal of Ophthalmology* 80.9 (1996): 789-793.

21. Kim SJ., *et al*. "Analysis of macular edema after cataract surgery in patients with diabetes using optical coherence tomography". *Ophthalmology* 114.5 (2007): 881-889.

22. Eriksson U., *et al*. "Macular edema and visual outcome following cataract surgery in patients with diabetic retinopathy and controls". *Graefe's Archive for Clinical and Experimental Ophthalmology* 249.3 (2011): 349-359.

23. Diabetic Retinopathy Clinical Research Network Authors/Writing Committee., *et al*. "Macular edema after cataract surgery in eyes without preoperative central-involved diabetic macular edema". *JAMA Ophthalmology* 131.7 (2013): 870-879.

24. Laura HP., *et al*. "Prevention of CME after cataract surgery". *Cataract and Refractive Surgery Today Europe* 7 (2013): 53-55.

25. Balabolkin MI., *et al*. "Lechenie sakharnogo diabeta i ego oslozhnenii". Moskva: Meditsina (2005).

26. Dedov II and Shestakova MV. "Sakharnyi diabet. Algoritmy spetsializirovannoi meditsinskoi pomoshchi bol'nym sakharnym diabetom". 5-e izd. Prilozhenie k zhurnalu Sakharnyi diabet. 3 (2011).

27. Mathys KC and Cohen KL. "Impact of nepafenac 0.1% on macular thickness and postoperative visual acuity after cataract surgery in patients at low risk for cystoid macular oedema". *Eye (London)* 24.1 (2010): 90-96.

28. American Academy of Ophthalmology. Cataract and Anterior Segment Panel. Cataract in the Adult Eye. San Francisco: American Academy of Ophthalmology (2011).

29. Chae JB., *et al*. "Effect of combined cataract surgery and ranibizumab injection in postoperative macular edema in nonproliferative diabetic retinopathy". *Retina* 34.1 (2014): 149-156.

30. Fine J., *et al*. "Clear corneal cataract surgery and topical anesthesia". Thorofare: Slack Inc., (1993).

Volume 11 Issue 2 February 2020