

A Case Report of Asteroid Hyalosis that had Spontaneous Reduction after 4 Years

Ming Chen* and Mindy Chen

University of Hawaii, John A Burns School of Medicine, USA

*Corresponding Author: Ming Chen, University of Hawaii, John A Burns School of Medicine, USA.

Received: September 05, 2019; Published: September 23, 2019

Abstract

Purpose: To present an unusual case of spontaneous partial dissipation of asteroid hyalosis 4 years after diagnosis

Method: An elderly male patient's chart was reviewed. The photographs from a fundus camera and Optical Coherence Tomography were compared 4 years apart. Literature review was done to elucidate asteroid hyalosis and the significance of the spontaneous change.

Result: The spontaneous partial dissipation of asteroid hyalosis was demonstrated in the more recent photos when compared to the photos taken four years previously. No previous similar report was found in the literature review.

Conclusion: A spontaneous partial reduction of asteroid hyalosis in the central media can occur as age increases as documented in this case. This may mimic a spontaneous disappearance of asteroid hyalosis. This case report contradicts a study done by UCLA by Fawzi AA., *et al.* In this study asteroid hyalosis was observed in an autopsy population, which showed that prevalence dramatically increases in each advancing decade of life as asteroid hyalosis has never been documented to spontaneously disappear.

Keywords: Asteroid Hyalosis (AH); Optical Coherence Tomography

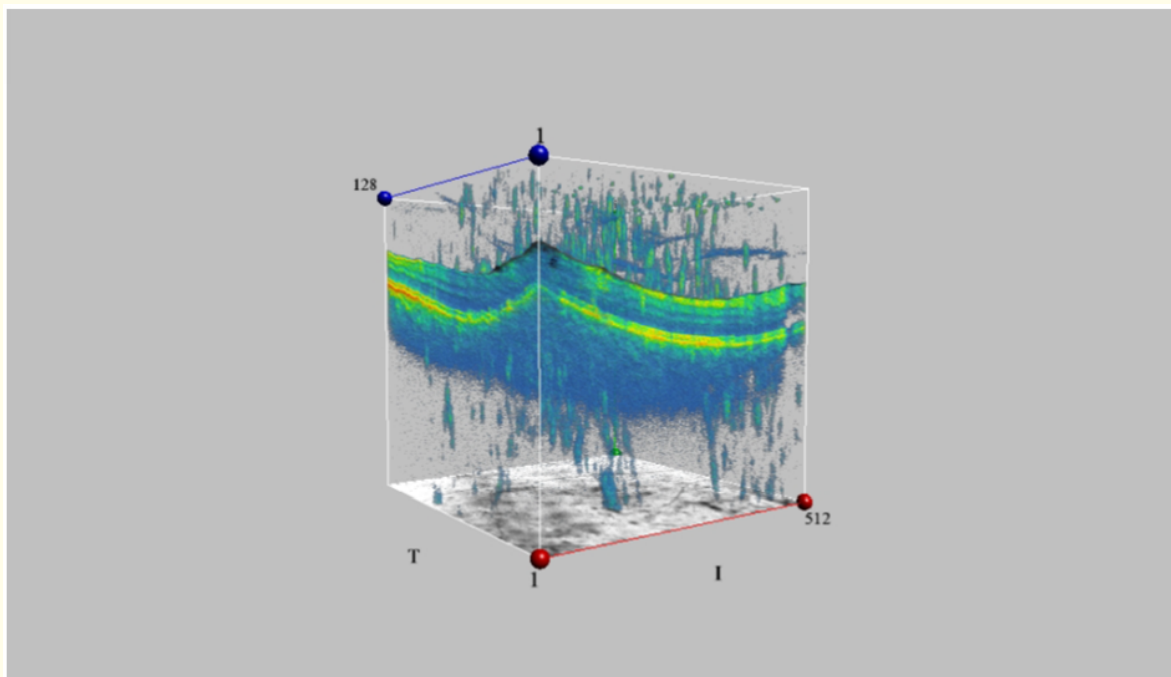
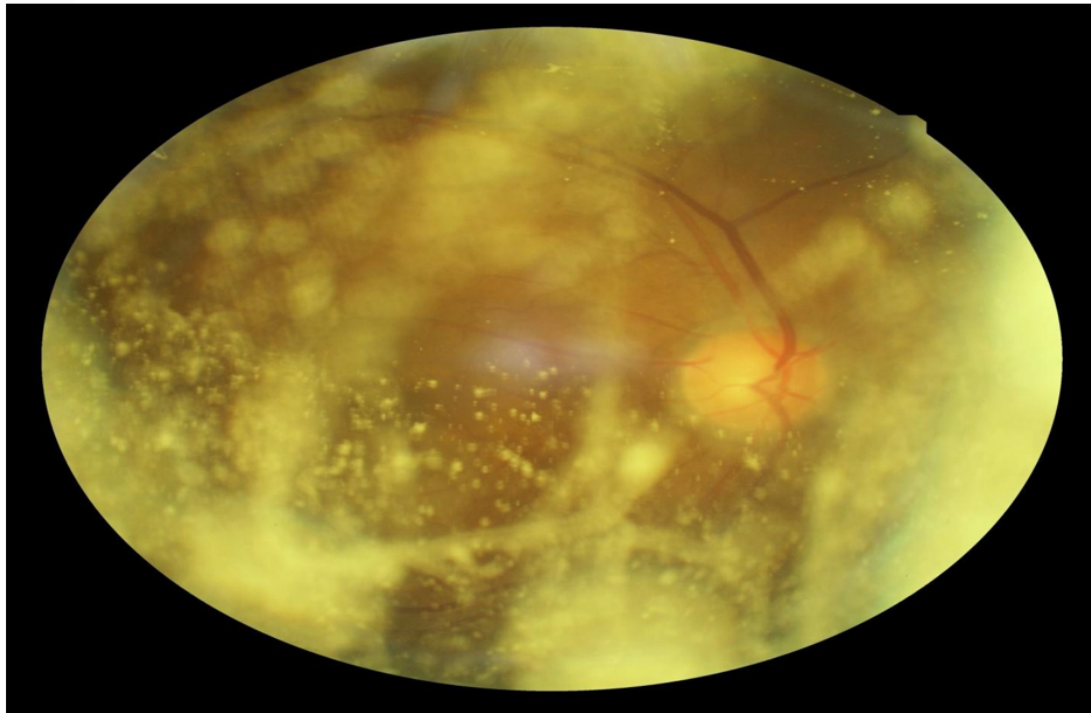
Introduction

The author indicated in his paper "To our knowledge, Asteroid Hyalosis (AH) has never been documented to spontaneously disappear, consistent with the observation that prevalence dramatically increases in each advancing decade of life".

Case Report

Patient history and the first examination in 2015

A 69 year old male, who is a dentist from Maui, Hawaii, USA, was first examined on 1/16/2015. He was otherwise healthy, with the only past ocular history of bilateral Lasik surgery done 15 years ago. His chief complaint was seeing floaters in the right eye for a "long time." His best corrected vision with refraction was 20/25 in both eyes, with the refraction as follows: OD: -0.50 + 2.00 x 6, OS: -1.25 + 1.25 x 10. Intraocular pressures were 9/10 mmHG. He was found to have bilateral incipient cataract. Fundus photo and OCT of the right eye as shown in figure 1 and figure 2.



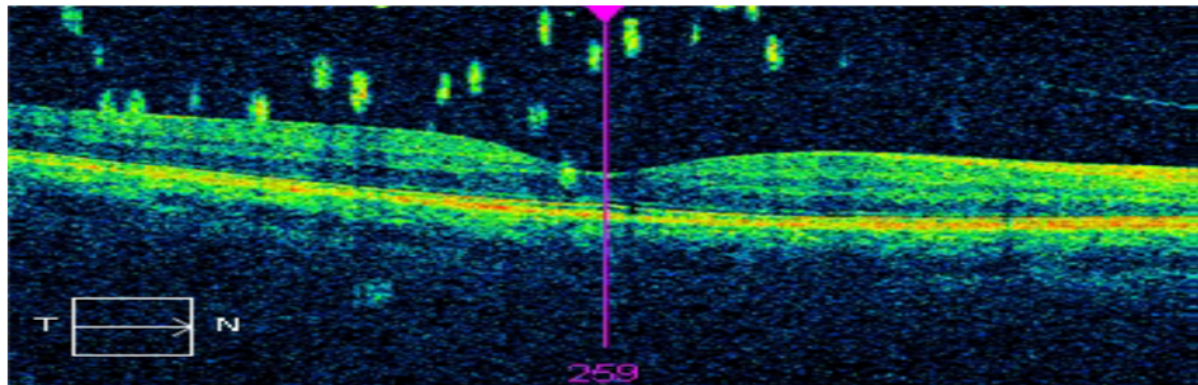


Figure 1 and 2: Asteroid Hyalosis can be seen on OCT with posterior vitreous detachment.

The second examination after 4 years: On 4/4/19 after loss to follow up since 1/16/2015 he returned for a follow up exam. He is now 73 years old and still practicing dentistry. His chief complaint was blurred vision in the right eye, but this time he did not complain of seeing any floaters.

Eye examination showed bilateral 2+ nuclear sclerotic cataracts, with the right eye being worse than the left. Best corrected vision was 20/40 in the right eye and 20/30 for the left eye. Intraocular pressure was 10mmHg for both eyes. The asteroid at the center of the posterior pole of the right eye had dramatically disappeared without any procedures in this examination as figure 3 and 4 demonstrated. However, after dilation some asteroid showed in the peripheral and mostly in the inferior retina.

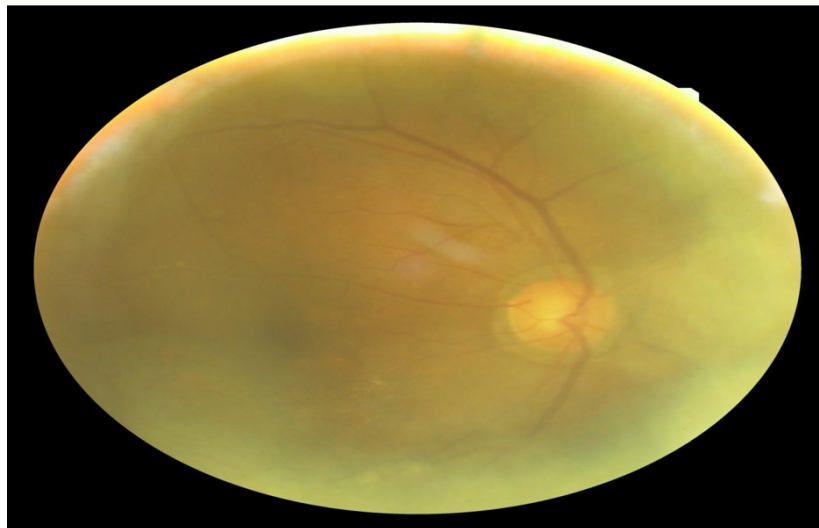


Figure 3: Lower fundus can see some asteroid but central is clear compare to 4 years ago photo, figure 1.

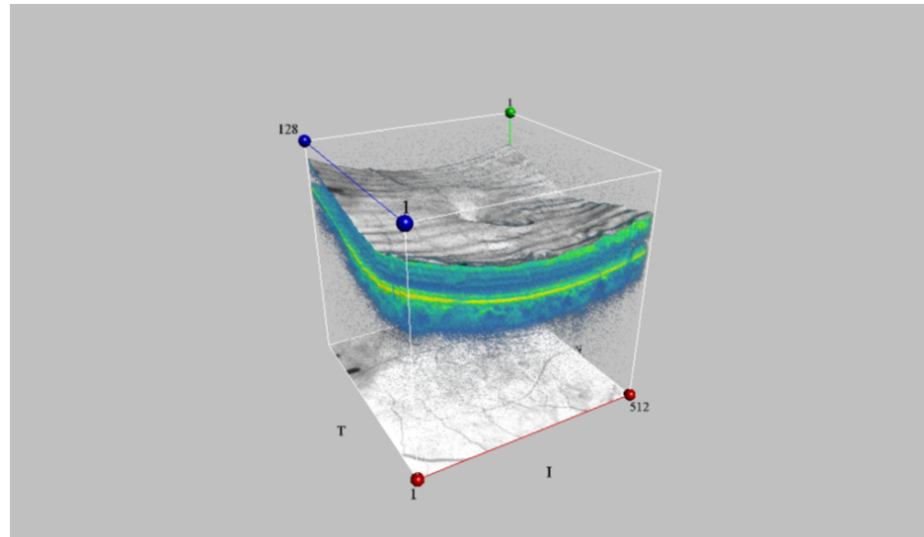
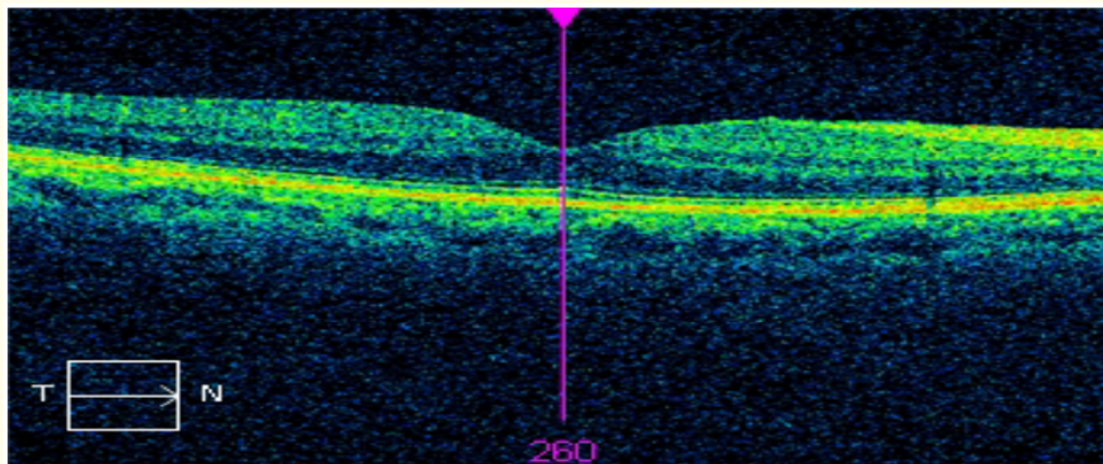


Figure 4: No asteroid seen in OCT Macula compare to four years ago on figure 2.

Figure 5 fundus photo of right eye.



No asteroid seen on OCT macula

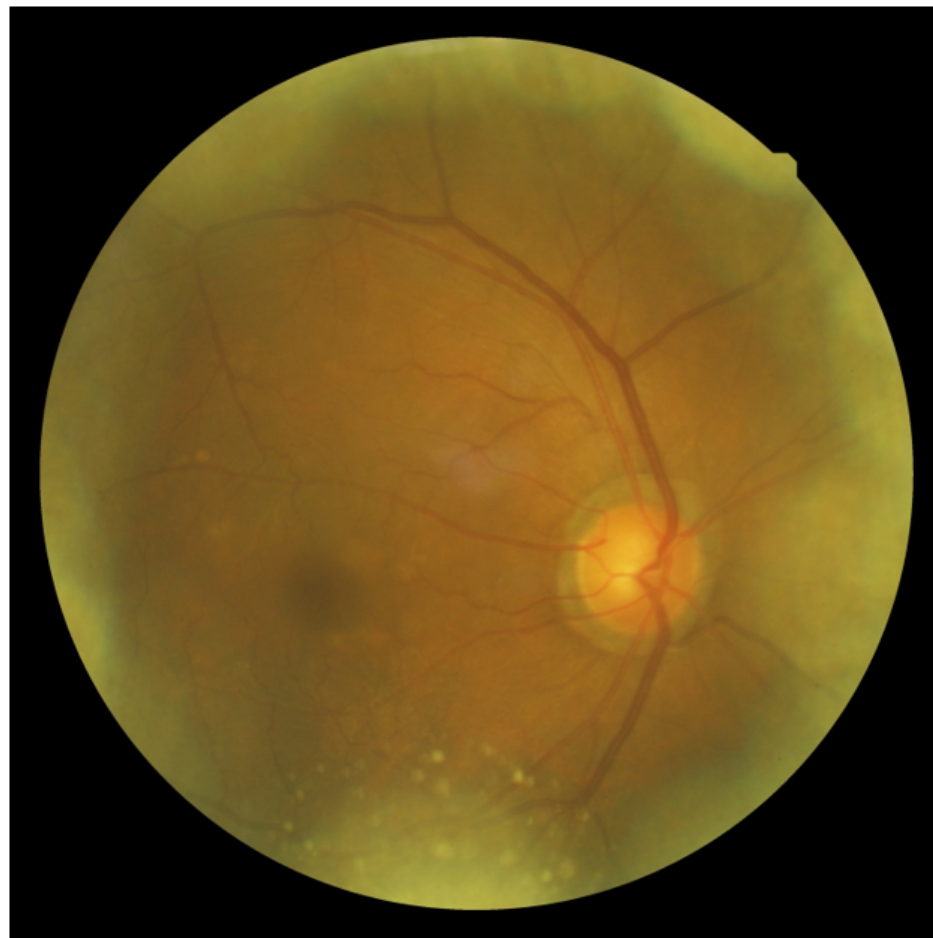


Figure 5: Lower fundus and peripheral showing asteroid but the central is clear.

Discussion

Review of literature about Asteroid Hyalosis (AH)

The Beaver Dam eye study [1]

In 4747 subjects, Asteroid hyalosis was present in 1.2% (95% confidence interval, 0.9, 1.5%). In subjects in whom it was present, asteroid hyalosis was bilateral in 9%. Prevalence increased significantly ($P < .001$) with age from 0.2% in subjects 43 to 54 years to 2.9% in subjects 75 to 86 years. After adjusting for age, men were more likely (1.8%) to have asteroid hyalosis than women (0.8%). After adjusting for age and sex, asteroid hyalosis was significantly more likely to be found in subjects with greater body mass ($P = .02$) and higher alcohol consumption ($P = .03$).

The population of Beaver Dam, Wisconsin, that was 43 to 86 years of age were examined from 1988 to 1990 ($n = 4926$). The population was predominantly white (99.4%)

From Columbia University [2]

Asteroid Hyalosis is a form of vitreous degeneration in which calcium soaps aggregate in the vitreous body. It is more prevalent in older patients with a male to female ratio 2:1. The etiology is not clearly understood. Clinical features: Symptoms rarely affects patient's visual acuity even in cases of severe vitreous involvement. Signs: White to yellow-white small round to oval opacities suspended throughout the vitreous body. 75 - 90% is found unilaterally. Asteroid bodies move as the vitreous body moves and tend to return to their original positions. Differential diagnoses include amyloidosis and cholesterolosis bulbi. No treatment is required. Vitrectomy may be indicated when poor visualization of the fundus causes retinal diseases.

From American Academy of Ophthalmology [3-17]

Benson, in 1894, was the first to describe accurately and to differentiate AH from synchysis scintillans. Histologically, asteroid bodies are rounded structures stain positively for neutral fats, phospholipids, and calcium. Asteroid hyalosis was strongly correlated with age and inversely correlated with posterior vitreous detachment.

UCLA study Fawzi AA., et al. Asteroid hyalosis in an autopsy population [8]

The author indicated in his paper "To our knowledge, Asteroid Hyalosis (AH) has never been documented to spontaneously disappear, consistent with the observation that prevalence dramatically increases in each advancing decade of life". This case happened to contradict to this statement. However, AH has been reported to disappear after vitrectomy. Dense asteroid hyalosis can obscure the fundus with a limited view. Optos ultra-wide field imaging also can be helpful in the diagnosis and management of retinal/choroidal lesions in these cases.

Conclusion

A spontaneous partial reduction of Asteroid Hyalosis as age increased in the central media can occur as documented in this case that may mimic a spontaneous disappearance of AH. Our thought was as further posterior vitreous detachment occurred and there was more liquefaction of the vitreous in this particular case, it was possible the asteroids can be dissipated to the peripheral and lower part of the vitreous cavity. As it is rare, this may be the first case report.

Bibliography

1. Moss SE., et al. "Asteroid hyalosis in a population: the Beaver Dam eye study". *American Journal of Ophthalmology* 132.1 (2001): 70-75.
2. Asteroid Hyalosis.
3. Ophthalmology AAO. "Section 12: Retina and Vitreous. Basic and Clinical Science Course". *American Academy of Ophthalmology* (2014-2015): 311-312.
4. Yazar Z., et al. "Asteroid hyalosis". *European Journal of Ophthalmology* 11.1 (2001): 57-61.
5. Shields CL., et al. "Vitreous asteroid hyalosis prolapse into the anterior chamber simulating iris metastasis". *Middle East African Journal of Ophthalmology* 19.3 (2012): 346-348.
6. Mitchell P., et al. "Asteroid hyalosis in an older population: the Blue Mountains Eye Study". *Ophthalmic Epidemiology* 10.5 (2003): 331-335.
7. Kim JH., et al. "Prevalence of and risk factors for asteroid hyalosis in Seoul, Korea". *Retina* 28.10 (2008): 1515-1521.

8. Fawzi AA, *et al.* "Asteroid hyalosis in an autopsy population: The University of California at Los Angeles (UCLA) experience". *Archives of Ophthalmology* 123.4 (2005): 486-490.
9. Galveia J, *et al.* "Asteroid hyalosis: clinical review of 58 cases". *Revista Brasileira de Oftalmologia* 72.5 (2013): 312-315.
10. Ophthalmology AAO. "Section 04: Ophthalmic Pathology and Intraocular Tumors. Basic and Clinical Science Course". American Academy of Ophthalmology (2014-2015): 138-139.
11. Kador PF and M Wyman. "Asteroid hyalosis: pathogenesis and prospects for prevention". *Eye* 22.10 (2008): 1278-1285.
12. Hwang JC, *et al.* "Optical coherence tomography in asteroid hyalosis". *Retina* 26.6 (2006): 661-665.
13. Wright AD, *et al.* "Asteroid hyalosis and photographic diabetic retinopathy screening". *Diabetic Medicine* 27.9 (2010): 1093-1093.
14. Mochizuki Y, *et al.* "Anatomical findings of vitreoretinal interface in eyes with asteroid hyalosis". *Graefe's Archive for Clinical and Experimental Ophthalmology* 247.9 (2009): 1173-1177.
15. Motiani MV, *et al.* "Diagnosis of Choroidal Melanoma in Dense Asteroid Hyalosis". *Seminars in Ophthalmology* 32.2 (2016): 257-259.
16. Ikeda Y, *et al.* "Retinitis pigmentosa associated with asteroid hyalosis". *Retina* 30.8 (2010): 1278-1281.
17. Heagley D, *et al.* "Asteroid hyalosis of the vitreous humor: an uncommon finding". *Diagnostic Cytopathology* 41.10 (2013): 926-927.

Volume 10 Issue 10 October 2019

©All rights reserved by Ming Chen and Mindy Chen.