

## Nystagmus Secondary to Metabolic Disease: Review of Six Cases

InSim Ng<sup>1</sup> and Jorge Sales Marques<sup>2\*</sup>

<sup>1</sup>Ophthalmology Department, Centro Hospitalar Conde S. Januário, Macau, China

<sup>2</sup>Pediatric Department, Centro Hospitalar Conde S. Januário, Macau, China

\*Corresponding Author: Jorge Sales Marques, Pediatric Department, Centro Hospitalar Conde S. Januário, Macau, China.

Received: July 29, 2019; Published: August 22, 2019

### Abstract

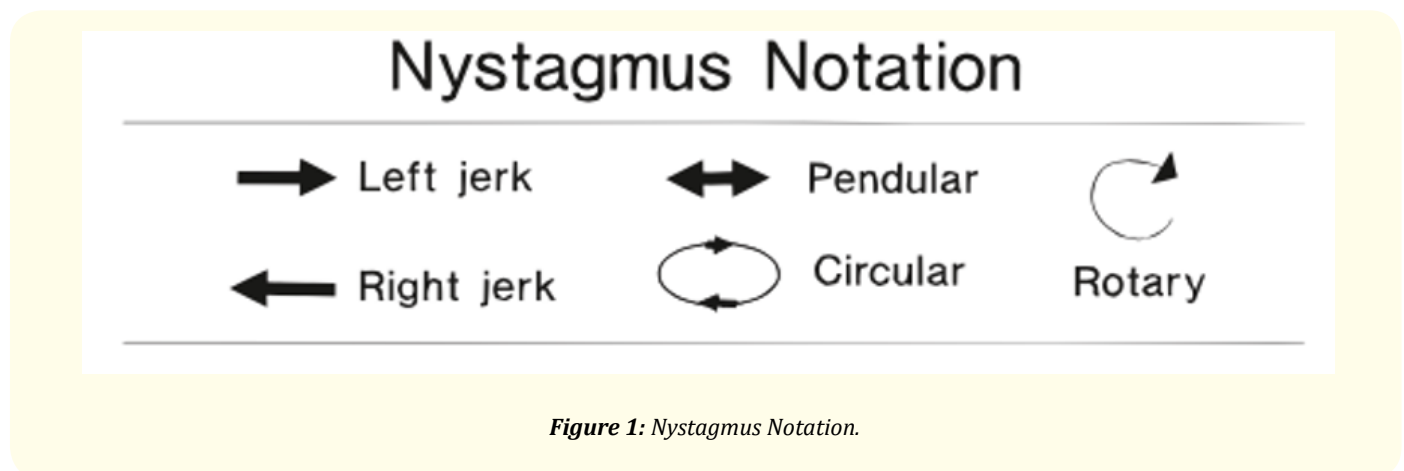
Nystagmus is an involuntary, rhythmic to-and-fro oscillation of the eyes. The movements can be described as either pendular or jerk. Nystagmus is one of the characteristic features which can be noted during external examination and we need to consider metabolic disease as a cause.

We reviewed six cases of nystagmus secondary to metabolic diseases. Four of them was caused by Mitochondrial disorder; one by Metachromatic leukodystrophy and the another one, a Mucopolysaccharidosis type III B case.

**Keywords:** Nystagmus; Metabolic Disorders; Mitochondrial Disorder; Metachromatic Leukodystrophy; Mucopolysaccharidosis

### Introduction

Nystagmus is an involuntary, rhythmic to-and-fro oscillation of the eyes [1]. The movements can be described as either pendular or jerk. Pendular nystagmus occurs when the movements have equal velocity in each direction, whereas jerk nystagmus is defined by a fast eye movement in one direction and a slow eye movement in the opposite direction. The direction of movement can be horizontal (side-ways movement), vertical (up-and-down movement), or rotary (twisting of the eye or torsion) [2] (Figure 1).



Metabolic disease is commonly associated with ocular pathology and all parts of the eye can be involved [3]. Nystagmus is one of the characteristic features which can be noted during external examination. Other abnormal findings include cornea opacities, cataracts, retinitis pigmentosa, cherry-red spots, and optic atrophy, etc. The combination of these signs can provide important clues to the diagnosis. A list of the common ocular manifestations concomitant with nystagmus presenting in different metabolic diseases is given in table 1 [4].

Nystagmus concomitant finding	Metabolic disease
With cornea opacities, cataract	<ul style="list-style-type: none"> <li>• Fabry disease</li> <li>• Homocystinurias</li> <li>• Lowe syndrome (infancy)</li> <li>• Mucopolysaccharidosis (childhood)</li> <li>• Wilson disease</li> </ul>
With retinitis pigmentosa	<ul style="list-style-type: none"> <li>• Abetalipoproteinemia</li> <li>• Ceroid lipofuscinosis (CLN1, CLN2, CLN3, CLN4)</li> <li>• LCHAD</li> <li>• Mitochondrial cytopathies (Kearns-Sayre etc.)</li> <li>• Peroxisomal defects (infantile to childhood)</li> <li>• Sjögren-Larsson (fatty acid alcohol oxido-reductase)</li> <li>• All causes of severe retinitis pigmentosa</li> </ul>
With optic atrophy	<ul style="list-style-type: none"> <li>• All causes of optic atrophy in adulthood</li> <li>• Canavan disease (early sign)</li> <li>• Ceroid lipofuscinosis (CLN3, CLN4)</li> <li>• Krabbe disease (infantile)</li> <li>• Leber due to mitochondrial DNA deletions</li> <li>• Leigh syndrome (all causes)</li> <li>• Metachromatic leucodystrophy</li> <li>• Mitochondrial cytopathies</li> <li>• Neuroaxonal dystrophy – Schindler (infantile)</li> <li>• Pelizaeus-Merzbacher (presenting sign early in infancy)</li> <li>• Peroxisomal biogenesis defects</li> <li>• Pyruvate dehydrogenase deficiency</li> <li>• Ribose-5-phosphate isomerase</li> <li>• Sulfite oxidase (infantile)</li> <li>• X-ALD</li> <li>• 3-methylglutaconic aciduria</li> </ul>

**Table 1:** Common ocular manifestations concomitant with nystagmus presenting in different metabolic diseases.

## Case Reports

### Case 1

A 4.5 years old boy was found in cardiac arrest at the kindergarten while having a nap. After CPR in the nearest Health Center, was sent to hospital for further treatment. He has bilateral nystagmus, bradycardia, myoclonic jerks and hypotonia. ECG showed premature ventricular contraction. Heart ultrasound detected dilated cardiomyopathy. Muscle biopsy revealed a severe deficiency of complex IV: 3.1 mmol/min/mg NCP/CS (normal: 11.5 - 34.5) with 13% of residual activity and defect of complex II: 8.7 mmol/min/mg NCP/CS (normal: 12.0 - 35.0) with 37% of residual activity. The mtDNA mutations was negative.

### Case 2

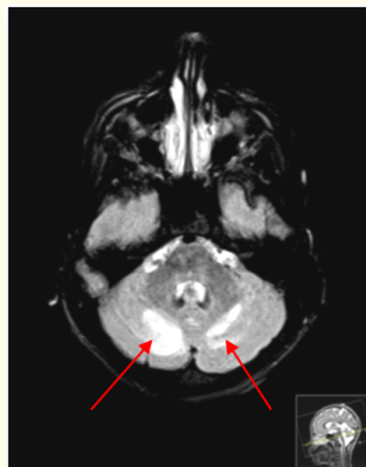
A 2 years old girl with hypotonia, nystagmus and hypoglycemia, showed lactic acid high in blood, with high relation lactate/pyruvate. Brain MRI revealed hypersignal focus with intensity and extension superior to the areas of late myelination in peritrigonal regions. Muscle biopsy revealed a deficiency of complex IV with 27% of residual activity. Mitochondrial DNA, MELAS, MERRF and NAPR/MILS were all negative.

### Case 3

A 6 years old boy was sent to pediatric outpatient department with hypotonia and Pierre Robin Sequence. He has retrognathism, axial hypotonia, bilateral strabismus, nystagmus, asymmetry palpebral slits (OE < OD), partial syndactyly of the 2 - 3 fingers and macrosomia. His lactic acid was increased. Brain MRI showed thin corpus callosum. PCR of muscle revealed 80% deletion of mitochondrial DN with uniparental isodisomic transmission (UPD) of the maternal chromosome 10, compatible with mitochondria DNA depletion syndrome.

### Case 4

A 10 years old girl showed global development delay and aggressive behavior. She has frequent falls, drowsiness and urinary incontinence and later became ataxic and hypotonic, loosing standing and seating ability. She has also nystagmus. Metabolic workup showed CSF with elevated lactate and pyruvate levels. Brain MRI and spectroscopy showed symmetrical hyperintense signal in TR and reduced water motion on both the striate nucleus and cerebellum, brainstem and cervical region of the spinal cord with elevated lactate peak (Figure 2). The mtDNA sequencing detected 8993T>C mutation, compatible with Leigh syndrome.



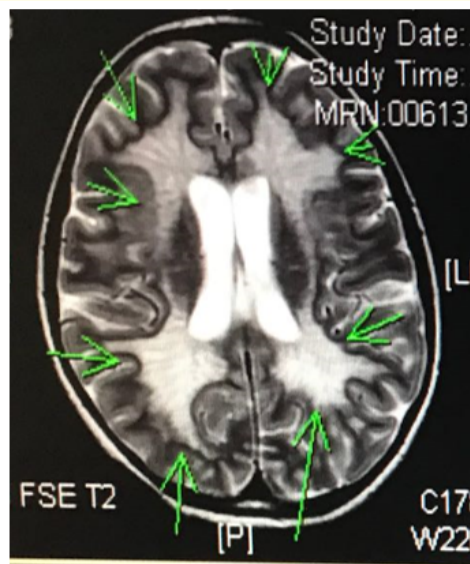
**Figure 2:** Brain MRI showed symmetrical hyperintense signal in TR and reduced water motion on both the striate nucleus and cerebellum, brainstem and cervical region of the spinal cord.

### Case 5

A 5 years old girl, with regression of her motor skills since 2 years old, is unable to concentrate/recognize pictures, vocalize unclear, and on physical examination showed coarse face, nystagmus, hepatomegaly 4 cm and tiptoeing walk. Brain Ct scan showed cortical and subcortical atrophy. Heart ultrasound revealed mitral valve incompetence. Abdominal ultrasound confirmed hepatomegaly. GAGS in urine was increased: 38 g/mol/creatinine (normal: < 14). Qualitative MPS pattern with high resolution electrophoresis showed: heparan sulphate - 62% and chondroitin sulphate - 38%. The leucocyte alpha acetyl glucosaminidase was reduced in blood: 0.02; 0.04 pmol/min/mg protein (normal: 0.4 - 3.4) and plasma: not detectable (normal: 0.15 - 1.3 pmol/min/mL), confirming MPS type III B.

### Case 6

A 8 years old boy, was admitted in the pediatric ward because of dysphagia, ataxia, nystagmus, intellectual disability and recurrent urine retention. Since 2.5 years of age, he presented regression of motor skills. Brain MRI showed diffusely abnormal signal of white matter of the brain bilaterally, consisting with leukodystrophy (Figure 3). Using Sanger sequence, changes in exons 1 and 5 gene are detected. The Next Generation Sequence (NGS) detected the ARSA gene, exon 5/8. C.931G>A. P.Gly311Ser, pathogenic, compatible with metachromatic leukodystrophy.



**Figure 3:** Brain MRI showed diffusely abnormal signal of white matter of the brain bilaterally, consisting with leukodystrophy

### Discussion

Nystagmus is a rare clinical presentation secondary to many disorders. Metabolic diseases are one of the possible causes of this problem. When we find a patient with nystagmus, we need to consider is a congenital or acquired presentation. Most of the congenital forms, are horizontal type (pendular or jerk). In acquired forms, the patient can appear with other types of presentation (vertical, circular, rotary) [1,2].

In our index cases, we present 6 different kinds of clinical presentations, four of them secondary to mitochondrial diseases, one is a Mucopolysaccharidoses (MPS) type III B and the final case is a metachromatic leukodystrophy. All of them showed nystagmus during the evolution of the disease.

Mitochondrial diseases should be considered in patients with an unexplained combination of neuromuscular and/or non-neuromuscular symptoms, with a progressive course, even the lactic acid results are normal in plasma, cerebral spinal fluid or brain MRI with spectroscopy [5]. They are multisystem disorders [5-8] which can appear since infancy to adulthood and occur with an incidence of 1/10000 live births.

In our cases, they all presented with neurologic symptoms associated with other systemic problems.

Metachromatic Leukodystrophy and MPS III, are both lysosomal storage diseases. The inheritance is autosomal recessive pattern [9,10]. In the two cases, the main symptom was psychomotor regression. They both showed typical brain MRI images. When we have a patient with nystagmus, associated with personal history of regression of their motor skills, we need to consider these diseases as differential diagnosis.

In all our cases, the prognosis is poor. It is important to offer the parents a prenatal diagnosis and also do the genetic counselling for the next pregnancy [11].

### Conclusion

Nystagmus is rare but an important neurologic sign in the pediatric age. There are many causes for this clinical sign. In our cases, the multisystemic presentation or the psychomotor regressions were the main associated symptoms. The disorders were confirmed by muscle biopsy or DNA study. Genetic counselling and prenatal diagnosis can be offer to the future pregnancy.

### Bibliography

1. Raab EL, *et al.* "Basic and Clinical Science Course, Section 06: Pediatric Ophthalmology and Strabismus". San Francisco: The American Academy of Ophthalmology (2011): 317.
2. Kenneth WW. "Pediatric Ophthalmology for Primary Care". 3<sup>rd</sup> edition. Illinois: American Academy of Pediatrics (2008): 113.
3. Michalski A, *et al.* "The eye and inherited metabolic disease: a review". *Journal of the Royal Society of Medicine* 81.5 (1988): 286-290.
4. Fernandes J, *et al.* "Inborn Metabolic Diseases: Diagnosis and Treatment". 4<sup>th</sup> edition. Würzburg: Springer Medizin Verlag (2006): 37.
5. Finsterer J and Zarrouk-Mahjoub S. "Cerebral imaging in paediatric mitochondrial disorders". *Neuroradiology Journal* 31.6 (2018): 596-608.
6. Rocha V, *et al.* "Growth hormone deficiency in a patient with mitochondrial disease". *Journal of Pediatric Endocrinology and Metabolism* 28.9-10 (2015): 1003-1004.
7. Erdol S and Saglam H. "Outcomes of mitochondrial derived diseases: a single-center experience". *Journal of Pediatric Endocrinology and Metabolism* 31.4 (2018): 399-405.
8. Honzik T, *et al.* "Neonatal onset of mitochondrial disorders in 129 patients: clinical and laboratory characteristics and a new approach to diagnosis". *Journal of Inherited Metabolic Disease* 35.5 (2012): 749-759.

9. Mahmood A., *et al.* "Metachromatic leukodystrophy: a case of triplets with the late infantile variant and a systematic review of the literature". *Journal of Child Neurology* 25.5 (2010): 572-580.
10. Malm G and Månsson JE. "Mucopolysaccharidosis type III (Sanfilippo disease) in Sweden: clinical presentation of 22 children diagnosed during a 30-year period". *Acta Paediatrica* 99.8 (2010): 1253-1257.
11. Nogueira C., *et al.* "Identification of maternal uniparental isodisomy of chromosome 10 in a patient with mitochondrial DNA depletion syndrome". *Molecular Genetics and Metabolism* 110.4 (2013): 493-494.

**Volume 10 Issue 9 September 2019**

**©All rights reserved by InSim Ng and Jorge Sales Marques.**