

## Management of Retinoblastoma in Developing Country: A Study of 84 Cases

Riffat Rashid<sup>1\*</sup>, Md Nazmul Haque<sup>2</sup> and Sadia Sultana<sup>3</sup>

<sup>1</sup>Consultant Cum Assistant Professor, Department of Oculoplasty, Ispahani Islamia Eye Institute and Hospital, Dhaka, Bangladesh

<sup>2</sup>Senior Consultant Cum Associate Professor, Department of Oculoplasty, Ispahani Islamia Eye Institute and Hospital, Dhaka, Bangladesh

<sup>3</sup>Consultant Cum Associate Professor, Department of Oculoplasty, Ispahani Islamia Eye Institute and Hospital, Dhaka, Bangladesh

**\*Corresponding Author:** Riffat Rashid, Consultant Cum Assistant Professor, Department of Oculoplasty, Ispahani Islamia Eye Institute and Hospital, Dhaka, Bangladesh.

**Received:** November 22, 2018; **Published:** January 22, 2019

### Abstract

**Introduction:** Retinoblastoma is the most common primary intraocular malignancy in children and accounts for approximately 4% of all childhood cancers. In developing countries incidence of retinoblastoma is higher. Chemoreduction plus focal consolidation has an important role for treatment of retinoblastoma.

**Objectives:** To evaluate the incidence, clinical characteristics and management of retinoblastoma patients in developing country.

**Methods:** The prospective study was conducted in the Department of Oculoplasty, Ispahani Islamia Eye Institute and hospital, Dhaka, Bangladesh during the period from January 01, 2017 to December 30, 2017. We included all new patients of 1 month to 132 months, clinically diagnosed as retinoblastoma of either sex attended in the out-patient department during the study period. The patient treated in other hospital were excluded from the study. Primary treatment given to all patient included laser photocoagulation, enucleation, systemic chemotherapy and external beam radiotherapy. Patients were followed up 3 monthly for one year.

**Results:** A total of 84 patients diagnosed as retinoblastoma were included in this study from January 2017 to December 2017. 47 (55.95%) were male and 37 (44.04%) female. The age at diagnosis ranged from 1 month to 132 months. Most common clinical presentation was leukocoria found in 75 (89.28%) patients. Laser photocoagulation was done in 6 (7.14%) patients. Enucleation was performed in right eye 16 (19.05%) and left eye in 26 (30.95%) patients. Total 57 (67.85%) patient received systemic chemotherapy. External beam radiotherapy was given in 1 (1.19%) patient, had advance retinoblastoma with intracranial metastasis.

**Conclusion:** Management of retinoblastoma has been improved in the last decade and requires a multidisciplinary approach. Meticulous examination in the first few years and early detection of tumor can save life, globe and vision.

**Keywords:** Retinoblastoma; Hereditary; Chemotherapy; Enucleation

### Introduction

Retinoblastoma is the most common primary intraocular malignancy in children [1-13] and accounts for approximately 4% of all childhood cancers [3,5]. This rare disease affect 1 in 15,000 to 18,000 live births [1,3,5,7,12]. Retinoblastoma can be sporadic or familial, hereditary or non-hereditary and 6% of cases have a positive family history [2,5]. In hereditary retinoblastoma, one allele of the RB1 gene is mutated in all body cells and the further mutagenic event "second hit" affects the second allele on chromosome 13q14 [1,2,9]. The average age at diagnosis is 18 months, unilateral cases diagnosed at around 24 months and bilateral cases before 12 months [5,7,11].

Cure rates depends on the location of the tumor; whether it is endophytic or exophytic and whether or not it spreads systemically or intracranially [2]. In developing countries incidence of retinoblastoma is higher [3] and most of the cases are diagnosed at advanced stages [4]. Many factors like low socioeconomic status [2], illiteracy and lack of access to healthcare resources account for this high rate of advanced disease [3].

The recent advances for management of retinoblastoma including enucleation, radiotherapy, chemotherapy, and focal treatments with cryotherapy, transpupillary thermotherapy, and laser photocoagulation [2,5,7,15] contributes to better survival, salvage globe and then vision [7,15]. Chemoreduction plus focal consolidation has an important role for treatment of retinoblastoma and ensure permanent control [17,20].

The survival rate in children with retinoblastoma is 95% in the developed world, but in the developing countries it is 60% in Asia and 30% in Africa [13,15]. Only 50% children with retinoblastoma survive worldwide [3,14,16].

**Purpose of the Study**

The purpose of this study is to evaluate the incidence, clinical characteristics and management of retinoblastoma patients in developing country.

**Methods**

The prospective study was conducted in the Department of Oculoplasty, Ispahani Islamia Eye Institute and Hospital, Dhaka, Bangladesh, during the period from January 01, 2017 to December 30, 2017. This study was approved by the Institutional Review Board and the objectives of the study, the nature of the disease, the treatment modalities and the outcome of the disease were explained to the patient’s parents. Informed consent was obtained from patient’s legal guardian.

We included all new patients of 1 month to 132 months, clinically diagnosed as retinoblastoma of either sex attended in the out-patient department during the study period. The patient treated in other hospital were excluded from the study.

Demographic and clinical data include age, sex, laterality, family history, first symptom, clinical presentation and vision. All the children underwent examination under anaesthesia for diagnosis and classification of retinoblastoma. The new international classification of retinoblastoma was followed (Table 1) [1,15]. Ultrasonography was done in every patients and CT scan in selected cases. The location of distant metastasis was also observed.

Group A	Small tumor (< 3 mm) outside macula
Group B	Bigger tumors (> 3 mm) or any tumor in macula or any tumor with subretinal fluid
Group C	Localized seeds (subretinal or vitreous)
Group D	Diffuse seeds (subretinal or vitreous)
Group E	Tumor touching the lens, Neovascular glaucoma, Tumor anterior to anterior vitreous face involving ciliary body or anterior segment, Diffuse infiltrating retinoblastoma, Opaque media from hemorrhage, Tumor necrosis with aseptic orbital cellulitis and Phthisis bulbi

**Table 1:** International classification of intraocular retinoblastoma.

Primary treatment given to all patient include laser photocoagulation, enucleation, systemic chemotherapy and external beam radiotherapy. Patients were followed up 3 monthly for one year.

## Results

A total of 84 patients diagnosed as retinoblastoma were included in this study from January 2017 to December 2017. 47 (55.95%) were male and 37 (44.04%) female. The age at diagnosis ranged from 1 month to 132 months, with a mean of 29.48 months. Number of patients according to age were presented in table 2 and showed incidence of retinoblastoma is less after 5 years of age. Among the unilateral cases (59), right eyes were involved in 22 (26.19%) and left eyes in 37 (44.04%) patients. 25 (29.76%) patients had bilateral involvement. Positive family history was found in 4 (4.76%) patients.

Age	Number of patient
1 - 12 months	20 (23.80%)
13 - 24 months	29 (34.52%)
25 - 36 months	20 (23.80%)
37 - 48 months	5 (5.95%)
49 - 60 months	5 (5.95%)
61 - 132 months	5 (5.95%)

**Table 2:** Number of patient according to age.

Visual acuity was assessed, fixation and follow were present in right eye 37 (44.04%) and in left eye 29 (34.52%) patients. First symptom before presenting to retinoblastoma center noticed by the parents were leukocoria 72 (85.71%), squint 1 (1.19%), proptosis 5 (5.95%), Cellulitis 3 (3.57%), hyphaema 2 (2.38%) and phthisis bulbi in 3 (3.57%) patients. The clinical mode of presentation at retinoblastoma center were leukocoria 75 (89.28%), squint 3 (3.57%), proptosis 8 (9.52%), cellulitis 10 (11.90%), hyphaema 8 (9.52%), Phthisis bulbi 3 (3.57%), nystagmus 1 (1.19%), glaucoma 2 (2.38%) and staphyloma 1 (1.19%).

According to the international classification of retinoblastoma most of the patients were presented in advance stage showed in table 3. In right eye 43 (51.19%) and left eye 52 (61.90%) patients had advance disease. Lymph node metastasis were found in 2 (2.38%) and intracranial metastasis in 1 (1.19%) patient.

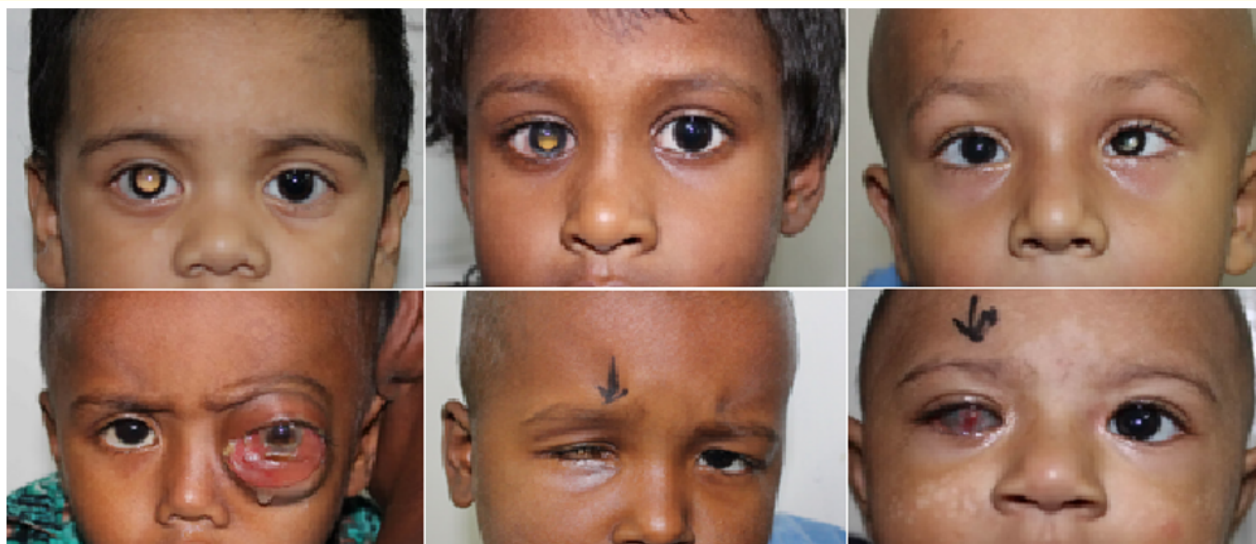Group	Right eye	Left eye
A	0	1 (1.19%)
B	2 (2.38%)	5 (5.95%)
C	0	4 (4.76%)
D	2 (2.38%)	0
E	43 (51.19)	52 (61.90%)

**Table 3:** Clinical diagnosis of retinoblastoma.

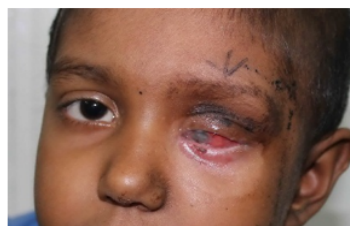The treatment modalities were laser photocoagulation, enucleation, systemic chemotherapy and external beam radiotherapy (EBRT) (Table 4). Laser photocoagulation was done in 6 (7.14%) patients. Enucleation was performed in right eye 16 (19.05%) and in left eye 26 (30.95%) patients. Total 57 (67.85%) patient received systemic chemotherapy, the standard chemotherapeutic agents used are vincristine, etoposide and carboplatin (VEC protocol). Standard 6 cycle chemotherapy was given in unilateral cases and 12 cycle in bilateral cases. External beam radiotherapy was given in 1 (1.19%) patient, had advance retinoblastoma with intracranial metastasis. Combined therapy (laser therapy, enucleation, chemotherapy and radiotherapy) was given in 35 (41.66%) patients. 18 patient refuse to receive treatment when they were advised for enucleation and chemotherapy.

No	Treatment	Right Eye	Left Eye
1	Laser Photocoagulation	2 (2.38%)	4 (4.76%)
2	Enucleation	16 (19.05%)	26 (30.95%)
3	Systemic Chemotherapy	32 (38.09%)	42 (50%)
4	Radiotherapy	1 (1.19%)	0
5	Treatment refusal	12 (14.28%)	13 (15.47%)

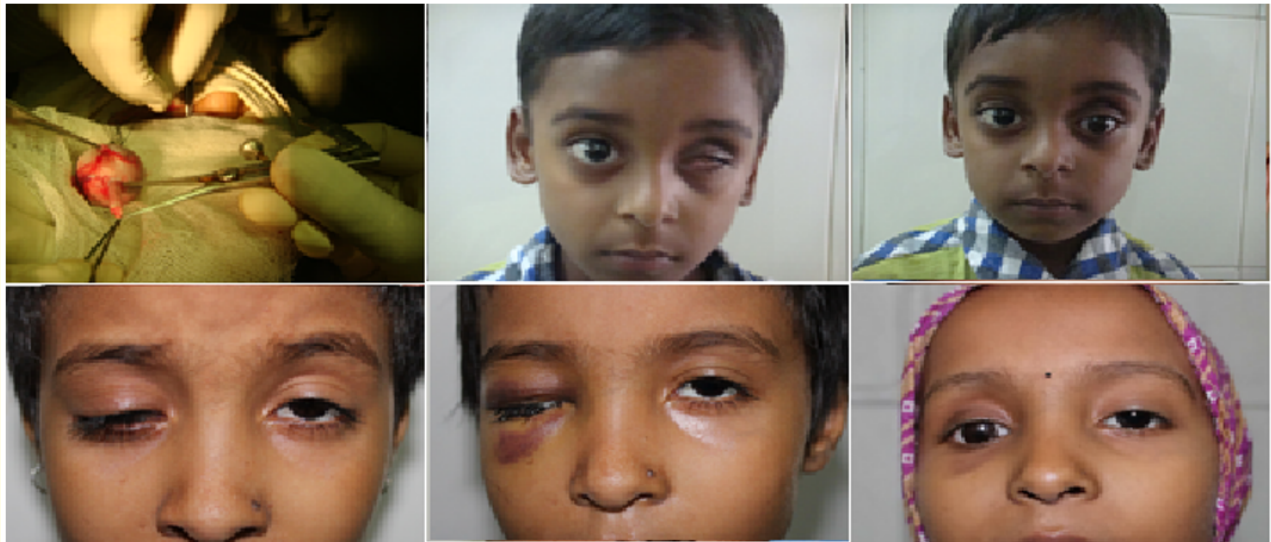**Table 4:** Primary treatment given.



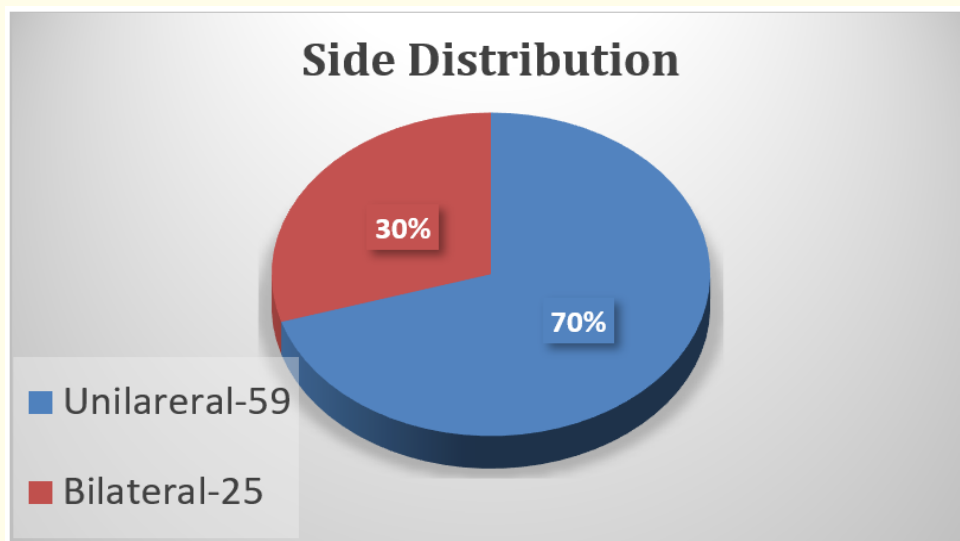
**Figure 1:** Clinical Presentation of Retinoblastoma (Left to right): a) Leukocoria, b) Leukocoria with Pseudohypopyon, c) Squint, d) Proptosis, e) Phthisis bulbi, f) Staphyloma.



**Figure 2:** Post EBRT in Advance Retinoblastoma.



**Figure 3:** (Left to right) a) Long Optic Nerve Section after Enucleation. b) Post-Operative Enucleation. c) After Prosthesis. d) Aseptic Cellulitis with Retinoblastoma. e) Post-Operative Enucleation. f) After Prosthesis.



**Figure 4:** Side distribution.

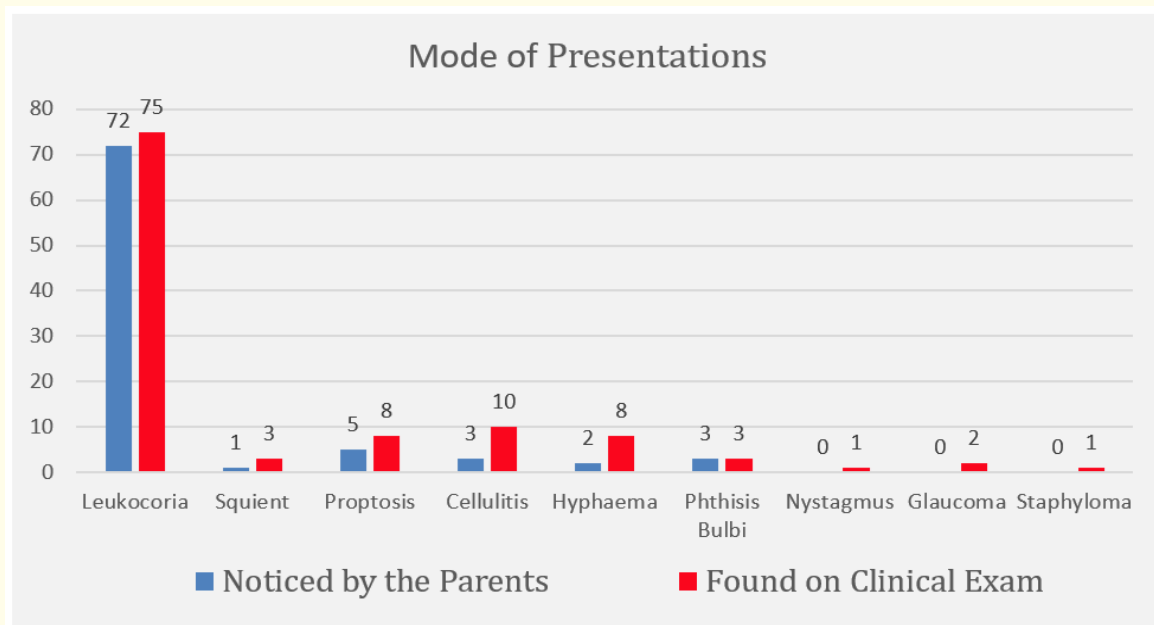


Figure 5: Mode of presentations.

### Discussion

Treatment of retinoblastoma depends on the unilateral or bilateral involvement, clinical presentation, stage of retinoblastoma and extension of the disease [1]. This intraocular malignancy if not treated on time can lead to death within one to two years [15]. Infants with family history should be examined repeatedly for the first few years of life [6]. Recurrent retinoblastoma in the only remaining eye is a distressing factor for both patient and physician [19].

In our study, the age at diagnosis was ranged from 1 - 132 months (mean 29.48 months). Leal-Leal C., *et al* (2004) in their study, showed age ranged from 1 day-182 months and mean 27.68 months. Menon., *et al*. (2000) reported average age at diagnosis 30 months, which is similar to our study. In another study, the mean age was  $3.10 \pm 1.66$  years [8]. About 80% of children are diagnosed before 3 years [2] and the incidence of retinoblastoma is less after 5 years of age.

Out of 84 patients, 59 (70.23%) unilateral and 25 (29.76%) bilateral involvement were found in this study. Leal-Leal C., *et al*. (2004) reported the unilateral disease in 72.8% and bilateral disease in 27.20% patients. Unilateral 86% and bilateral 14% involvement was reported by Roy P., *et al* (2018). In this study, 47 (55.95%) were male and 37 (44.04%) were female. Leal-Leal C., *et al*. showed out of 500 patients male were 262 and female were 238. Roy P., *et al*. reported 51.20% male and 48.80% female. There is no sex predilection for retinoblastoma. Positive family history was found in 4 (4.76%) patients in our study. Only 1 (1.33%) out of 43 patients had positive family history, in another study [8]. Chantada GL (2004) found only one patient of positive family history, out of 224 cases. Yanik O., *et al*. reported only 6% of familial cases. Sporadic cases are more common than familial cases.

The clinical mode of presentation were leukocoria 75 (89.28%), squint 3 (3.57%), proptosis 8 (9.52%), cellulitis 10 (11.90%), hyphaema 8 (9.52%), phthisis bulbi 3 (3.57%), nystagmus 1 (1.19%), glaucoma 2 (2.38%) and staphyloma 1 (1.19%) in our study. Roy P., *et al*.



in their study, showed that leukocoria 53.06%, squint 6.12%, proptosis 10.20% and cellulitis 6.12%. The most common presenting sign was leukocoria (68%) in another study [23]. But Menon BS., *et al.* in their study reported leukocoria 72% and proptosis 83% were the presenting sign. Leukocoria is one of the most common clinical presentation in patient with retinoblastoma.

According to the international classification of retinoblastoma, most of the patients in this study were presented in advance stage. In the right eye 43 (51.19%) and the left eye 52 (61.90%) patients had advance disease. Almost 30% of patients were diagnosed at advanced stage reported by Leal-Leal C., *et al.* (2004). Lymph node metastasis were found in 2 (2.38%) patients in our study. In contrast to this, Chantada GL., *et al.* reported that 1 patient had lymph node metastasis. Presentation in advance stage is mostly due to delayed diagnosis and lack of access to healthcare resources.

Enucleation was performed in the right eye among 16 (19.05%) and in the left eye among 26 (30.95%) of patients. Total 36 (42.85%) patients had enucleation due to advance retinoblastoma. Leal-Leal C., *et al.* (2004) in their study showed that enucleation was performed in 87.62% of the patients with advanced retinoblastoma and differs from ours may be due to late presentation at the retinoblastoma center. This was a multicenter study and many patients were from rural communities where prevalence of the disease was higher [4]. Enucleation was done in 65.11% of the patients in another study [8]. Shields CL., *et al.* (2004) study showed enucleation was done in 15% cases only because of early diagnosis followed by chemotherapy and focal therapy.

In our study, a total of 57 (67.85%) patients received systemic chemotherapy. Systemic chemotherapy was advised in patients with bilateral and advance disease to prevent orbital invasion and metastasis with good response. But 42.85% patients had enucleation due to advance retinoblastoma. Shields CL., *et al.* (2002), in their study 100% patients receive 6 cycle systemic chemotherapy and retina tumour, vitreous seeds, subretinal seeds showed favorable response of regression. Kim J., *et al.* reported 2 patients with unilateral intraocular retinoblastoma and persistent vitreous seeding treated with intra-arterial chemotherapy after failed systemic chemotherapy but failed to respond and so ultimately both eyes were enucleated [18]. Chemotherapy had limited effect in advanced retinoblastoma. Leal-Leal C., *et al.* applied chemotherapy in 74.4% patients for eye preservation, orbital and metastatic disease. Fifteen different regimens were used by participating centers and overall survival was 85% [4]. In another study, 125 patients were managed with 6 cycle chemotherapy and focal therapy and 82% patients had regression of tumour [17]. In our study, laser photocoagulation with systemic chemotherapy was given in 6 (7.14%) patients. Laser photocoagulation was done in eyes which were incidentally detected during examination with other eye advanced disease. So, vision salvage was possible in 6 patients.

External beam radiotherapy was given in 1 (1.19%) patient who had advance retinoblastoma with intracranial metastasis. Leal-Leal C., *et al.* study, applied EBRT in 26.2% patients with orbital and metastatic disease. Roy P., *et al.* reported EBRT in 6.12% patients. In our study, 18 (21.42%) patients refused to receive treatment when they were advised for enucleation and chemotherapy. Treatment refusal was mainly due to poor socioeconomic status. The overall outcome of treatment was good and none of our patient died during the follow-up period.

## **Conclusion**

Management of retinoblastoma has been improved in the last decade and requires a multidisciplinary approach. Ophthalmologists, pediatric oncologists, radiation oncologists, pathologists and genetic counselors plays an important role to cure the disease. The primary aim of treatment is to save the patient's life. Salvaging the globe and saving vision are the secondary aims. Meticulous examination in the first few years and early detection of tumor can save globe and vision. Long-term follow-up is advised for all cases of retinoblastoma.

## **Conflict of Interest**

No conflict of interest was declared by the authors in this article.

## Bibliography

1. Aerts I., et al. "Retinoblastoma". *Orphanet Journal of Rare Diseases* 1 (2006): 31.
2. Chintagumpala M., et al. "Retinoblastoma: Review of Current Management". *The Oncologist* 12.10 (2007): 1237-1246.
3. Meel R., et al. "Current therapy and recent advances in the management of retinoblastoma". *Indian Journal of Medical and Paediatric Oncology* 33.2 (2012): 80-88.
4. leal-leal C., et al. "A multicentre report from the Mexican Retinoblastoma Group". *British Journal of Ophthalmology* 88.8 (2004): 1074-1077.
5. Yanik O., et al. "Chemotherapy in Retinoblastoma: Current Approaches". *Turkish Journal of Ophthalmology* 45.6 (2015): 259-267.
6. Solaiman SE., et al. "Prenatal versus Postnatal Screening for Familial Retinoblastoma". *American Academy of Ophthalmology* 123.12 (2016): 2610-2617.
7. Ali MJ., et al. "Orbital retinoblastoma: Present status and future challenges – A review". *Saudi Journal of Ophthalmology* 25.2 (2011): 159-167.
8. Roy P., et al. "Clinical Presentation and Management of Retinoblastoma". *Journal of National Institute of Ophthalmology* 1.1 (2018): 12-15.
9. Kanski JJ. "Clinical Ophthalmology". 6<sup>th</sup> edition. Butterworth Heineman Elsevier (2007): 542-552.
10. Albert DM and Miller JW. "Principles and Practice of Ophthalmology". 3<sup>rd</sup> edition. Elsevier (2008): 3679-3723.
11. Stevenson KE., et al. "Local extraocular extension of retinoblastoma following intraocular surgery". *British Journal of Ophthalmology* 73.9 (1989): 739-742.
12. Kashyap S., et al. "A Histopathologic Analysis of Eyes Primarily Enucleated for Advanced Intraocular Retinoblastoma From a Developing Country". *Archives of Pathology and Laboratory Medicine* 136.2 (2012): 190-193.
13. Kaliki S., et al. "Postnucleation Adjuvant Chemotherapy with Vincristine, Etoposide, and Carboplatin for the treatment of High-Risk Retinoblastoma". *Archives of Ophthalmology* 129.11 (2011): 1422-1427.
14. Shields cl., et al. "Choroidal invasion of retinoblastoma: Metastatic potential and clinical risk factors". *British Journal of Ophthalmology* 77.9 (1993): 544-548.
15. Shields CL., et al. "Retinoblastoma frontiers with intravenous, intra-arterial, periocular, and intravitreal chemotherapy". *Eye* 27.2 (2013): 253-264.
16. Chantada GL., et al. "Retinoblastoma patients with high risk ocular pathological features: who needs adjuvant therapy?" *British Journal of Ophthalmology* 88.8 (2004): 1069-1073.
17. Shields Cl., et al. "Chemoreduction for Retinoblastoma: Analysis of Tumor Control and Risks for Recurrence in 457 tumors". *Transactions of the American Ophthalmological Society* 102 (2004): 35-45.
18. Kim J., et al. "Enucleated eyes after failed intra-arterial infusion of chemotherapy for unilateral retinoblastoma: histopathologic evaluation of vitreous seeding". *Clinical Ophthalmology* 5 (2011): 1655-1658.



19. Seregard S, *et al.* "Intravitreal chemotherapy for recurrent retinoblastoma in an only eye". *British Journal of Ophthalmology* 79.2 (1995): 194-195.
20. Shields CL, *et al.* "Practical Approach of Management of Retinoblastoma". *Archives of Ophthalmology* 122.5 (2004): 729-735.
21. Shields CL, *et al.* "Factors Predictive of Recurrence of Retinal Tumors, Vitreous Seeds, and Subretinal Seeds Following Chemoreduction for Retinoblastoma". *Archives of Ophthalmology* 120.4 (2002): 460-464.
22. Menon BS, *et al.* "Extra ocular retinoblastoma". *Pediatric Blood and Cancer* 35.1 (2000): 75-76.
23. Antoneli CB, *et al.* "Extra ocular retinoblastoma a 13-year experience". *Cancer* 98.6 (2003): 1292-1298.

**Volume 10 Issue 2 February 2019**

**©All rights reserved by Riffat Rashid, *et al.***