

## CyPass Withdrawal Root Cause Insight and Risk Mitigation Strategy: from Procedure-based Medicine to Biology-based Medicine

**Tina Guanting Qiu\***

*Ophthalmic Physician and Executive Consultant, Ophthalmic Therapeutic Innovation, MA, USA*

**\*Corresponding Author:** Tina Guanting Qiu, Ophthalmic Physician and Executive Consultant, Ophthalmic Therapeutic Innovation, MA, USA.

**Received:** November 16, 2018; **Published:** December 27, 2018

### Abstract

Harvard Precision Medicine -2018 Symposium in June was concluded with a wakening take-home message: bridge phenotype gaps in medicine: "Biology"; clinicians/surgeons and all parties involved in medicine development and practice must change from procedure-based medicine to biology-based medicine in the 21st century modern times. In ophthalmic therapeutic innovation, this topic becomes even more important in the new era of pharmacotherapy for ocular diseases and medicine precision. This editorial insights shed light on the root cause of CyPass safety recall (by Alcon/Novartis) and risk mitigation strategy, which helps deepen a better understanding of glaucoma disease biology in the surgical intervention for early and late stage of glaucoma. Specifically, emphasizing the role of metabolic inflammation and oxidative damage in glaucoma pathological processes opens a broader perspective on improvement of the disease management and therapeutic algorithm toward precision medicine.

**Keywords:** *CyPass; Cornea Endothelium Cells; Glaucoma; Metabolic Inflammation; Biologic Insults; Aqueous flow; Biology-based Medicine; Precision Medicine; Risk-Mitigation Strategy; ASCRS Taskforce*

### Background

The minimally invasive glaucoma surgery (MIGS) has brought a new paradigm shift to glaucoma disease management with benefits of improving patient compliance especially for early-mid stage glaucoma. There are four new MIGS devices approved by Food and Drug Administration (FDA): iStent (Glaukos Corp, 2012), CyPass (Transend/Alcon, 2016), iStent Inject (Glaukos Corp, 2018), and Hydrus (Ivan-tis Inc, 2018). XEN45 Gel Stent (Allergan) and Microshunt (InnFocus Inc. and Santen Inc) are designed for advanced stage glaucoma, as alternative to old tube shunt and trabeculectomy due to its aggressive aqueous drainage feature. On August 29, 2018, Alcon/Novartis announced voluntary withdrawal of CyPass due to significant cornea endothelium cell loss (ECL) at 5-year follow up, but ECL was not significant at 2-year endpoint in Phase 3 trials. In September 2018, American Society of Cataract and Refractive Surgeries (ASCRS) conveyed a taskforce committee with twelve glaucoma and cornea surgeons collectively to review data from the COMPASS-XT pivotal trials (Clinical Trial Identifier ID: NCT02700984), shortly published the preliminary consensus and guidelines, indicating that the position of retention rings seems causing cornea endothelium cell damage, further suggesting surgical trimming as needed [1]. Whilst most people are in the mist of not knowing what exactly happened in CyPass patients; some still hope that Alcon should bring CyPass back to the market [2,3]. I see a clear trend of deterioration of ECL: 27% patients with CyPass had > 30% ECL at year-5 [1] ([www.alcon.com/CyPass](http://www.alcon.com/CyPass)); the scale and severity will deteriorate (uncontrollable) over time due to heightened intraocular inflammation. It's imperative to intercept the ASCRS data plot and address the fundamental biologic root cause underpinning the significant ECL in patients with CyPass, further develop a detailed risk-mitigation strategy to prevent unnecessary "premature" vision loss.

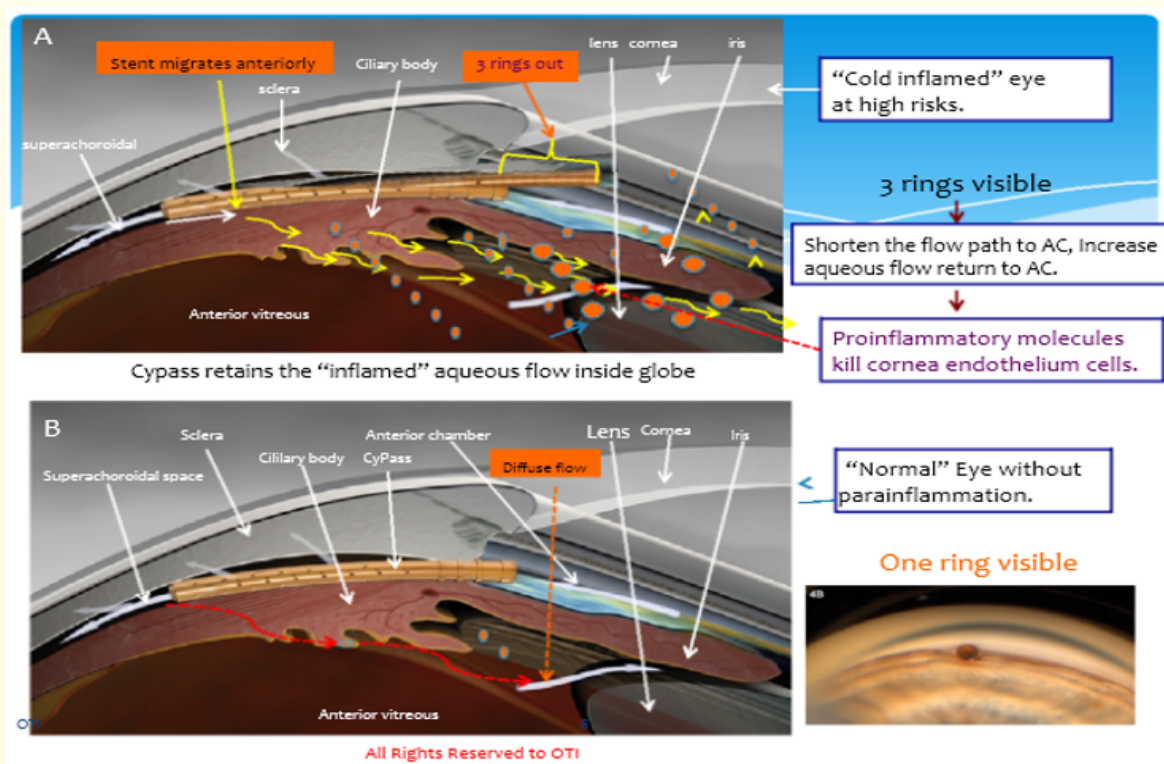
### Scientific and clinical evidences

In order to understand the long-term safety problem of CyPass, there are two basic facts that are essential for data interpretation. First, we all know that aqueous humor drainage is through the conventional outflow system via trabecular meshwork (TM) outlet and a non-conventional pathway via uveoscleral track, which accounts for 10 - 20% depending on age [4]. However, most people may not know aqueous flow circulation inside the globe, there is a diffuse path from superachoroid and ciliary body circulating back to the anterior chamber (AC), and backwards to the vitreous cavity in exchange [4]. In retina fluorescein angiography clinics, when blood-aqueous barriers breakdown (advanced retinitis pigmentosa is an example), we often see fluorescein dye filled in the vitreous cavity and anterior

chamber, which is an evidence of such internal aqueous circulation. Secondly, para-inflammation is a key IOP independent risk factor in glaucoma [5]. There are genetic and proteomic evidences suggesting proinflammatory cytokines in the aqueous humor in patients with glaucoma (e.g. TNFa, ILs, OPTN gene) [6-8]. About 20% glaucoma patients will need more aggressive drainage surgeries as they reach to an advanced stage when drugs become resistant or insensitive due to TM aging, secondary to aqueous humor para-inflammation and oxidative damage. Because of intricate proinflammatory molecules circulating in aqueous humor, cornea endothelium cell loss following a filtering surgery is very prominent at disease end-stage (e.g. 10 - 20% ECL at 24 months post-operation) [3] in refractory case. Filtering bleb failure is also associated with increased proinflammatory cytokines in aqueous humor that causes “bleb” scarring and angiogenesis (noted by Professor Sir Peng Khaw @ Moorfield Eye Hospital in London in 2016).

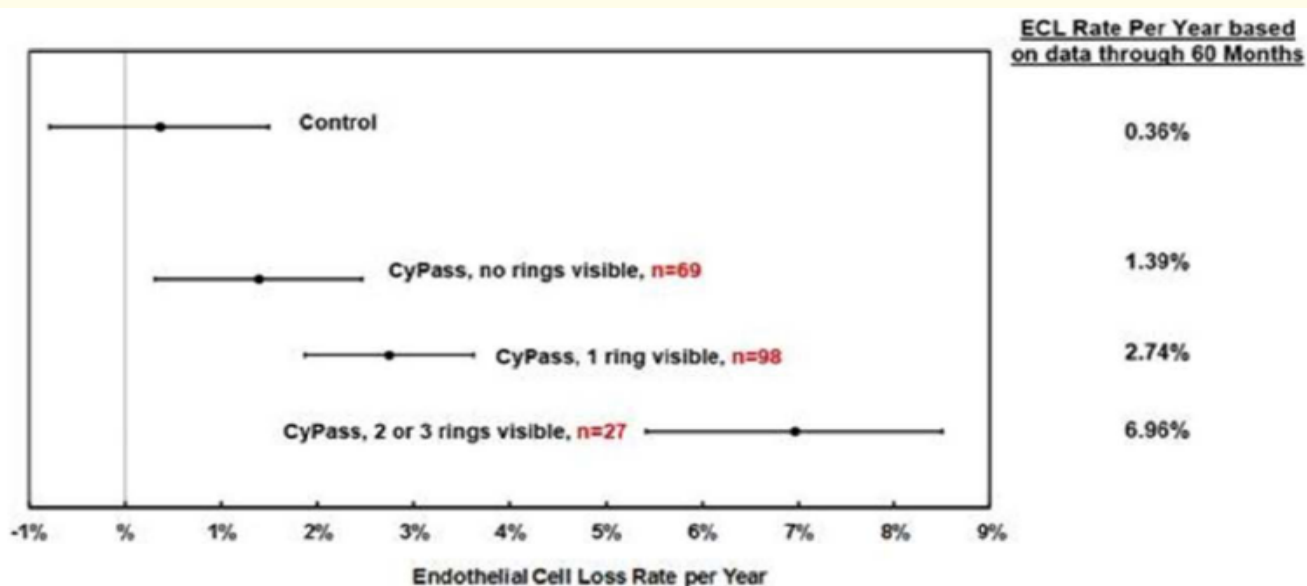
**CyPass: real problem and false impression**

The position of retention rings protruding anteriorly gives a false impression of mechanical damage to the cornea. The real problem lies at CyPass mechanistic drainage mode of outflow exit. The device drives the outflow disproportionally through a “long-corridor” in uveoscleral track before its exit through the vortex vein in surperachoroid space. There is a high probability that CyPass retains the “in-flamed” aqueous humor inside of globe (inward), thus increases its proportional return via diffuse path circulating back to the AC that kills the cornea endothelium cells (Figure 1). Figure 2 showed a correlation between the number of visible rings and the severity of ECL annually, which could easily mislead us to believe that was caused by mechanical damage. However, if we take the intricate inflammation into the context of how CyPass alters the inflamed aqueous circulation inside globe, one could easily see the real killer behind the curtain. The device protruding anteriorly shortens the diffuse flow path in return, while increasing the proportion of inflamed aqueous circulating back to AC, which renders constant biologic insults to cornea endothelium cells. It’s possible that high-risk patients with predisposition of inflammation may suffer more severe ECL in patients with visible rings compared to those without visible rings. Vice versa, the ring damage theory does not sustain. For example, the figure 3 showed that patients with 3 visible retention rings have significant variability of ECL annually, from normal range (< 0.5%) up to 10% ECL annually, which suggests that the severity of ECL has little to do with the position of retention rings [1].



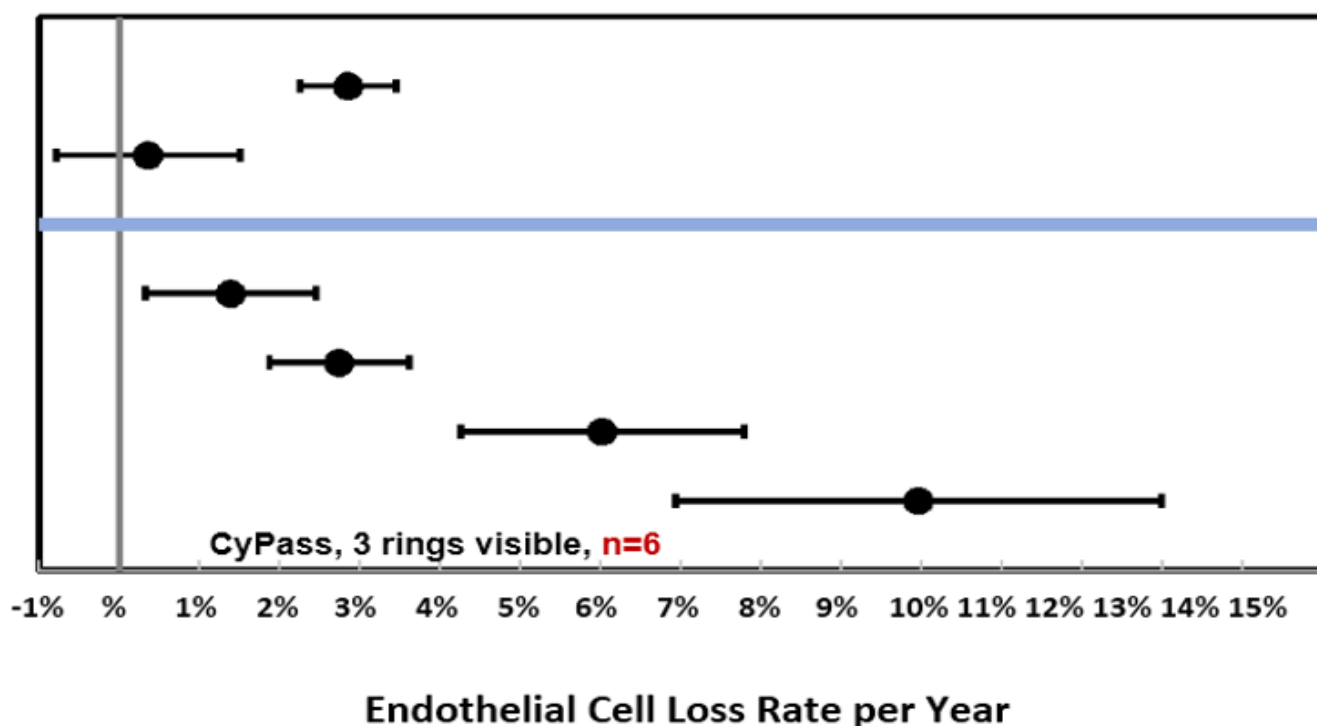
**Figure 1:** CyPass and Inflamed Aqueous Flow and Circulation.

Figure 1 illustrates how CyPass alters and retains an inflamed aqueous flow disproportionally via a long corridor from superaciliary and superachoroid space diffusing through posterior chamber returning to anterior chamber. The proinflammatory molecules were aggregated in AC that causes constant biologic insults to cornea endothelium cells. Picture A showed that eyes with para-inflammation, plus protruding rings are at high risk of ECL. Picture B showed normal eye without biologic insults by proinflammatory molecules, which is unlikely affected by CyPass, regardless of the device position.



**Figure 2:** The correlation between ECL annualized rate and the position of retention rings in patients with CyPass based on data through 60 months.

Figure 2 showed the percentage of ECL annualized rate by device position. The correlation between ECL and the position of the rings may give a false impression and mislead to the “theory” of mechanical damage by the protruding rings. This Data Plot was published by ASCRS CyPass Withdrawal Preliminary Guidelines, September 25, 2018 ([www.alcon.com/CyPass](http://www.alcon.com/CyPass)).



**Figure 3:** Cornea endothelium loss rate per year in patients with 3 visible rings.

Figure 3 showed the great variance of ECL from normal range (less than 0.5%) to 10% annually among patients with 3 visible rings suggesting that the cell loss had little to do with the device position. This data plot was published by ASCRS CyPass Withdrawal Preliminary Guidelines, September 25, 2018 1 ([www.alcon.com/CyPass](http://www.alcon.com/CyPass)).

Both CyPass and iStent (Glaukos Corp) are first generation MIGS for early-mid stage glaucoma [9], ideally they are excellent alternatives to eye drops for improving patient compliance (> 50% non-compliance in patients using eye drops). Unlike CyPass, the mechanistic mode on flow drainage in iStent is via a shot-cut path directing the aqueous outflow to subconjunctival space. If patient has pre-existing inflammation, iStent drives proinflammatory molecules outside, which does not aggregate intraocular inflammation causing tissue damage. The iStent has been implanted in over 10,000 glaucoma patients, and there is no report of significant ECL loss at 5-year or longer [3]. Theoretically, there is a possibility that patient's subconjunctiva tissue might be "inflamed" especially with multiple iStent implants, however, given the active and large lymphatic drainage systems surrounding the subconjunctiva and periocular space, the side-effects could be clinically negligible. Plus, problem outside the globe is always easier to manage than the ones inside the globe. If iStent patient needs trabeculectomy in the future, one could avoid the same clocks or hemisphere of iStent outlet, or use Microshunt (Santen Inc) as appropriate. Given the market competitiveness, to bring CyPass back to market will be very challenging, even though we may be able to identify and exclude patients with high-risk inflammatory profile. The priority task has to focus on existing patients with CyPass implant already.

#### Differentials: mechanical damage vs biological insults

The majority of cornea endothelium cell loss in CyPass patients are caused by biologic insults: para-inflammation, not mechanical injury, though we cannot exclude individuals, who may have the rings protruding forcefully to scratch the cornea or iris root. Mechanical damage occurs fast, in weeks or months, limited to local area, not pan cornea. A "gentle" touch or physical contact does not cause clinical problem. Allergan's Bimatoprost sustained release mini-rod in AC is an example (Phase 2). On the contrary, para-inflammation is a very slow and accumulative process from months to years before clinical symptoms or signs become significant; it affects the tissue or cells broadly [10]. The scale and speed of accumulative cell loss in CyPass patients reflects the nature of this type of biologic insults. Biologically, it occurs at intracellular level, often it's the mitochondrial metabolic dysfunction that triggers cell apoptosis and/or necrosis involving TNF $\alpha$  and NF-KappaB [11-13]. Such metabolic inflammation attacks the cells or tissues that has high oxygen demand and metabolic turnovers. Cornea endothelium cell is one of such, thus the most sensitive and vulnerable to oxidative damage and metabolic deprivation. Trabecular meshwork cells might be affected in a longer term, so do the retina ganglion cells in the back of the eye. This is the same type of inflammatory traits that causes late stage glaucoma trabeculectomy failure and filtering bleb scarring (refractory glaucoma) [14]. Unlike uveitic red eye with aqueous flare and iris and conjunctiva congestion, this type of sub threshold inflammation demonstrates a "cold" appearance in ocular manifestation, can sustain a long period time before reaching to the brink of loss in functionality. Complement factor triggered subretinal inflammation in dry age-related macular degeneration is another example of para-inflammation or metabolic inflammation [15].

#### Real world outcomes: "premature" sight loss in CyPass patients

Based on ASCRS Taskforce data report ([www.alcon.com/CyPass](http://www.alcon.com/CyPass)): the percentage of patients with accumulative cell loss of > 30% has increased from 16% to 27% between year-4 and year-5 [1], and will continue to increase as the glaucoma disease advances with heightened intraocular inflammation. At 5-year follow up, about 13% patients (27/206) had ECL at 7% annually (19x higher), and 48% patients (98/206) had ECL at 2.74% annually (7.6x higher) compared to the control group of ECL at 0.36% annually [1]. The highest ECL was found at 10% annually (27x higher) in individuals with 3 retention rings [1]. A clear trend shows that ECL is worsening over time by speed and scale. The high-risk patients are likely seen in those who carry inflammatory predisposition plus with visible rings protruding anteriorly (Figure 1). Based on the current speed of cell loss, CyPass could accelerate the disease nature course by half. Of note, early stage glaucoma patients have 15 - 20 years "safe window" before reaching to the "refractory" point, where drugs fail, more aggressive drainage surgeries become inevitable. Whereas in those high-risk populations, in another 5 years or less, their endothelium cells density could reach to the brink of cornea decompensation (500 - 600 cells/mm<sup>2</sup>) from baseline at 2300 - 2400 cells/mm<sup>2</sup>. F Murray, *et al.* reported about 10 - 20% ECL at 24 months following trabeculectomy and tube shunt, patients with tube shunt had higher ECL, partly due to the rigidity of the tube/tips causing cornea damage, partly due to intricate inflammation at end-stage glaucoma, which is uncontrollable (refractory) [3]. At 5-year, 27% CyPass patients have already reached to > 30% cell loss, suggesting the sign of late stage disease pathology in cornea functionality. These patients could enter a 'refractory' phase at much earlier than the disease nature progress.

So far, ASCRS taskforce committee only sampled for 206 patients from COMPASS-XT Ph3 clinical trials at 5-year follow up. We don't know yet how many implants were performed in real world. From registered clinical trials, it's estimated more than one thousands of implants before the device approved by FDA and EMA (Clinical Trial Identifiers: NCT02700984, NCT01166659, NCT01085357, NCT02448875, NCT01097174, NCT03273907, NCT02228577). Situation could be worse than it appears right now. Of note, cornea endothelium cells derive from neural crest. In some species, the endothelium can regenerate after injury, but in man, cellular enlargement is the primary mechanism of repair after cell loss [16].

### CyPass risk mitigation strategy: surgical criteria and medical management

The principle for early stage disease intervention is to halt all relevant pathological progresses and minimize sight loss. Most CyPass patients at risk can be managed by removing intraocular inflammation, either by surgical or medical treatment. ASCRS taskforce suggested surgical trimming the rings as needed, this may not help, as it does not change the outflow path. If there is a very clear mechanical damage causing local cornea edema or iris depigmentation, remove the device might be a better option. In general, for high-risk patients with visible rings, pushing the rings backwards (in) may offer some relief but not for cure, plus surgical complication such as bleeding or tissue laceration may occur. UBM-guided procedure is highly recommended. The detailed criteria for surgical removal or adjustment must be established in order to minimize the risks of undergoing unnecessary intraocular procedures with complications. One key question is “who and when”. For example, patient with less than 1000/mm<sup>2</sup> endothelium cell count, his/her ECL is at 7% annually, proteomics biomarker profile reaches to a certain level, surgical removal or surgical adjustment (if with visible rings) is recommended. To establish patient inclusion or exclusion criteria for surgery, the next step taskforce should take consideration on the following key parameters: 1) cornea endothelium cell account and current annualized rate of ECL, 2) RGC loss/NFL thickness and visual field stability, 3) position of the rings, 4) proteomic profile on aqueous humor, 5) preclinical histology on the implant (IND package), 6) Ultrasound Bio microscopy (UBM) image. AAO Registry and UK NHS Clinical Network should be great resources to further the totality data analysis.

Medical management of glaucoma disease remains challenging due to limitation of pharmacological agents that fail to address very complex biological root causes or non-IOP independent risk factors, such as para-inflammation and neurovascular problems etc [5]. So far, para-inflammation seems to have a clear link to glaucoma disease pathological processes with clinical evidence support. For example, Rescula or unoprostone is BK channel activator, and has a role in restoration of cell membrane homeostasis and inhibiting endothelium -1 (ET-1) that is a strong vascular constrictive molecule [14]. Clinically, Rescula is the only glaucoma eye drops that has demonstrated its therapeutic effects in refractory glaucoma and normal tension glaucoma as well as in ischemic retina conditions, such as retinitis pigmentosa and age-related macular degeneration [14,17,18]. This drug has excellent safety profile. If countries or regions have the access to Rescula eye drops (0.12% or 0.15%), which could be ultimate clinical solution. Unfortunately, this drug is not available in the US and UK, where majority of CyPass patients reside.

Add-on medication: IOP lowering effects in CyPass usually sustain 4 - 5 years, then will gradually lose its clinical benefit. Should patients need add-on eye drops, it's advisable to avoid old prostaglandin analogues, such as latanoprost, bimatoprost, travoprost because these IOP lowering agents are proinflammatory in nature [14,19]. The new lantanoprost bunod (B&L) is yet to be seen its clinical profile in its relation to inflammation. Rhopressa (Aerie Pharma) could be a better choice, though it does not show clear anti-inflammatory traits in patients, at least will not accelerate pre-existing inflammatory condition. Trabodenoson (Inotek Pharma) is another IOP lowering agent with unique TM rejuvenation and neural protection benefits, of which the TM rejuvenation is important to help clean up the extracellular matrix debris in TM, due to aging and oxidative damage, and prolong the “safe window” for TM tissue to be more responsive to IOP lowering agents, which could delay the disease pathological processes. Unfortunately Trabodenoson did not make to the market, failed at Phase 3 trials in 2017, due to problems of dosing strategy and Ph3 clinical study design.

### CyPass and social economic impact

Most patients receiving CyPass implant are at early-mid stage glaucoma. The ECL is not individual case. From registered US clinical trials, estimated > 200 patients at high risk as of today. More may enter into this “risk zone” in due course. Perhaps we are talking about thousands of implants including post-marketing sales. If we do nothing, simply wait to the stage where cornea transplant becomes inevitable, it will be too late to rescue. In severely inflamed eyes, cornea graft survival is very challenging, and multiple transplant surgeries add complexity to glaucoma disease managements. The economic and social impact to those CyPass patients and their families will be significant. It's the responsibility of physicians to their patients, ultimately the responsibility of Alcon/Novartis. At least physicians should provide a sound explanation, informing their patients about the condition and discussing risk mitigation strategy. In the era of patient centric healthcare and pay-by-performance, we should be mindful of potential lawsuit from patients and insurance payers, and social responsibility.

### Future Prospect and Conclusion

“It is the best of times, and it is the age of wisdom” (Charles Dickens). The 21st century is the era of biology evolution intersecting with technology innovation. Transforming from procedure-based medicine to biology-based medicine is more than a concept adoption but takes generations' efforts and multidisciplinary collaborative taskforces (noted by Dr Calum A MacRae, Chief of Cardiovascular Medicine, Brigham and Women's Hospital, 2018). 2016 and 2018 Antonio Champalimaud Vision Award were given to biologists and physicians, who have made breakthrough in vascular AMD [20] and retina gene therapies (www.arvo.org), respectively, which signify the hallmark of

this historical movement in surgical predominant medicine, like ophthalmology. Now CyPass patient rescue project provides a glimpse of the status on biology-based medicine: how far we have come to, how little we know, and what the future holds for us. Ophthalmic surgical innovation has to ground its feet to fundamental biology whilst implementing medical strategy and therapeutic algorithm for better patient care.

### Acknowledgments

I am very grateful for the encouraging support of Dr. Stephen Lane, Chief Medical Officer/EVP of Alcon/Novartis, Prof. John Marshall, MBE, Forest Professor of Ophthalmology at Institute of Ophthalmology UCL, and Dr. Marlene Moster at Wills Eye Hospital and ASCRS Taskforce Committee during the project initiations. Special thanks to Dr. Wiley Chambers, Supervisory Medical Officer at FDA for his valuable endpoint discussion on CyPass patient rescue taskforce, Prof. Andrew D Dick, Duke-Elder Chair of Ophthalmology, Director of Research at UCL Institute of Ophthalmology for his contribution to the concept of metabolic inflammation, and Dr. E. Randy Craven, Chief of Location at Wilmer Eye Institute, Johns Hopkins for his valuable experience and discussion on ophthalmic surgical complications. Also I would like to thank Kevin Hrusovsky, Chairman and CEO of Quanterix Inc. for his ardent support on ocular proteomic profiling mentioned in this article, and Leonide Saad, PhD, MBA, CEO, Alkeus Pharma Inc. for his business insight and valuable support on this project.

### Financial Interests

Former Executive Medical Scientific Consultant to Inotek Pharmaceuticals MA (merged with Rocket Pharma, NY). Sucampo Pharmaceuticals, DC (acquired by Mallinckrodt, UK).

### Bibliography

1. D Rhee., *et al.* "Preliminary ASCRS Cypass withdrawal consensus statement". ASCRS Taskforce Committee. ASCRS (2018).
2. CA Sng and K Barton. "Minimally invasive surgery -coming of age (Editorial)". *BIO* 102.10 (2018).
3. F Murray., *et al.* "The Role of Minimally Invasive Glaucoma Surgery Devices in the Management of Glaucoma". *Ophthalmology and Visual Science* 95 (2018): 155-162.
4. MP Fautsch and DH Johnson. "Second ARVO/Pfizer Research Institute Working Group. Aqueous Humor Outflow, What Do We Know? Where Will It Lead Us?". *Investigative Ophthalmology and Visual Science* 47.10 (2006): 4181-4187.
5. Tina Guanting Qiu. "New Frontiers of Retina Therapeutic Innovation and Strategic Insight". *EC Ophthalmology* (2015).
6. T Nakazawa., *et al.* "Tumor Necrosis Factor- $\alpha$  Mediates Oligodendrocyte Death and Delayed Retinal Ganglion Cell Loss in a Mouse Model of Glaucoma". *Journal of Neuroscience* 26.49 (2006): 12633-12641.
7. Rezaie., *et al.* "Adult-onset primary open-angle glaucoma caused by optineurin". *Science* 295.5557 (2002): 1077-1079.
8. Ileana Soto and Gareth R Howell. "The Complex Role of Neuroinflammation in Glaucoma". *Cold Spring Harbor Perspectives in Medicine* 4 (2014): a017269.
9. Myers JS., *et al.* "Prospective Evaluation of Two iStent<sup>®</sup> Trabecular Stents, One iStent Supra<sup>®</sup>Suprachoroidal Stent, and 13 Postoperative Prostaglandin in Refractory Glaucoma: 4-year Outcomes". *Advances in Therapy* 35 (2018): 395-407.
10. Xu H., *et al.* "Para-inflammation in the aging retina". *Progress in Retinal and Eye Research* 28 (2009): 348-368.
11. Y Yagi-Yaguchi., *et al.* "Association between corneal endothelial cell densities and elevated cytokine levels in the aqueous humor". *Scientific Reports* 7 (2017): 13603.
12. Ben J Janson., *et al.* "Glaucoma-associated corneal endothelial cell damage: A review". *Survey of Ophthalmology* 63 (2017): 500-506.
13. Eom Y., *et al.* "The effects of proinflammatory cytokines on the apoptosis of corneal endothelial cells following argon laser iridotomy". *Experimental Eye Research* 2016 145 (2016): 140-147.
14. Tina Guanting Qiu. "Rescula and refractory glaucoma and CME". *Journal Clinical and Experimental Ophthalmology* 6 (2015): 473.

15. Copland DA., *et al.* "A Perspective of AMD Through the Eyes of Immunology". *Investigative Ophthalmology and Visual Science* 2059.4 (2018).
16. SJ Tuft and DJ Coster. "The Corneal Endothelium". *Eye* 4 (1990): 389-424.
17. S Yamamoto., *et al.* "Topical Isopropyl Unoprostone for Retinitis Pigmentosa: Microperimetric Results of the Phase 2 Clinical Study". *Ophthalmology Therapy* 1 (2012): 5.
18. C Shiragami., *et al.* "Effect of topical isopropyl unoprostone on macular atrophy progression in eyes with exudative age-related macular degeneration". *Medicine (Baltimore)* 96 (2017): e6422.
19. Arcieri ES., *et al.* "Blood-Aqueous Barrier Changes After the Use of Prostaglandin Analogues in Patients". *JAMA Ophthalmology* 123 (2005): 186-192.
20. Miller JM. "VEGF: From Discovery to Therapy. The Champalimaud Award Lecture". *Translational Vision Science and Technology* 115.6 (2016): 9.

**Volume 10 Issue 1 January 2019**

**©All rights reserved by Tina Guanting Qiu.**