

Submacular Hemorrhage Plus Traumatic Macular Hole Managed with Pneumo-Displacement in a Child: Case Report

Miriam Guadalupe Arellano Ganem^{1*}, Quiroz-Velázquez Ricardo², Baques-Guillen Elizabeth³, Rivera-Arroyo Gerardo⁴ and Arroyo-González José María⁵

¹Specialist Ophthalmology Surgeon, Second Year Fellow of Retina and Vitreous, Central Military Hospital, Mexico

²Specialist Ophthalmology Surgeon, First Year Fellow of Retina and Vitreous, Central Military Hospital, Mexico

³Major Surgeon Specializing in Ophthalmology, Retina and Vitreous Service of the Central Military Hospital, Mexico

⁴Major Surgeon Specialist in Ophthalmology, Head of the Retina and Vitreous Subsection of the Central Military Hospital, Mexico

⁵Lieutenant Colonel Surgeon Specialist in Ophthalmology, Deputy to the Retina and Vitreous Subsection of the Central Military Hospital and Head of the Ophthalmology Section of the Central Military Hospital, Mexico

***Corresponding Author:** Miriam Guadalupe Arellano Ganem, Specialist Ophthalmology Surgeon, Second Year Fellow of Retina and Vitreous, Central Military Hospital, Mexico.

Received: July 24, 2018; **Published:** September 28, 2018

Abstract

Introduction: The worldwide incidence of visual disability caused by ocular trauma in children varies from 2% to 14% [1]. The incidence of macular hole due to blunt trauma is reported from 1 to 9%, and the spontaneous closure is 50% at 6 months. In the case of submacular hemorrhages, photoreceptor toxicity is known, so treatment should be given soon [4].

Objective: To present case of 8-year-old boy with submacular hemorrhage and traumatic macular hole treated with pneumo-displacement and good final visual result.

Case Report: We present the case of an 8-year-old boy with blunt ocular trauma in the left eye, who presented with submacular hemorrhage and the traumatic macular hole. That was treated with pneumo-displacement, a follow-up of 3 months was carried out and a final visual capacity of 20/50 was obtained.

Discussion: As found in the literature, the final result of our patient is good and is the first report of treatment of submacular hemorrhage and traumatic macular hole with pneumo-displacement in a pediatric patient in the literature.

Keywords: Blunt Trauma; Pediatric; Submacular Hemorrhage; Macular Hole; Pneumodisplacement

Abbreviations

OCT Macular: Macular Optic Coherence Tomography; SF6: Sulfur Hexafluoride Gas

Introduction

Eye injuries due to trauma are the most frequent cause of acquired monocular blindness in children. The rate of hospitalization for pediatric eye injuries in the United States in 2000 was 8.9 per 100,000 people aged 20 or younger. The worldwide incidence of visual disability or blindness caused by ocular trauma in children varies from 2% to 14% according to different studies [1].

The ocular traumas correspond approximately from 8 to 20% of all injuries in children. Children under 3 years old usually suffer injuries related by third parties (parents, caregivers or siblings). Older children have injuries related to dotted objects, toys, tree branches, pencils, sports and stones [2,3].

Most studies report a higher incidence of ocular trauma in men than in women, almost twice as many. Depending on the literature, the most frequent place of the accident is at home reporting up to 60.4%, followed by outdoors with 30.7% at school 5.2%, during sports 2.2%. The majority correspond to blunt trauma (40.3%), closed ocular trauma (53.4%), with a presentation of hyphema, secondary glaucoma, retinal edema, with reports of vitreous hemorrhage of 14% and retinal hemorrhages of 20% [1-3]. The incidence of macular hole due to contusive trauma is reported with an incidence of 1 to 9% [4].

Case Report

We present the case of an 8-year-old boy who, while playing at school, presented ocular trauma by object projected by another boy directly to the eye area; it is referred by visual loss of the left eye of one week of evolution, with a history of vitreous hemorrhage, which reabsorption started after 5 days of evolution and submacular hemorrhage in the left eye was evident. On admission, ophthalmologic exploration is performed with the following findings.

Right eye visual acuity of 20/25, intraocular pressure of 14 mmHg, pupillary reflexes present, biomicroscopy and fundus exploration without alterations. In the left eye, visual acuity of 20/400 with intraocular pressure of 9 mmHg, with weakness in the pupillary reflex without afferent pupillary defect, biomicroscopy with the presence of mild mydriasis, rest of exploration without alterations, in the examination of the fundus of the eye we found retina applied, round papilla with defined borders, 40% excavation, central emergence of vessels, preserved vein artery relation, macular area thickened by the presence of submacular hemorrhage of 4 disc diameters involving inferior temporal arcade and macular hole image, as well as presence of intraretinal hemorrhage outside of the inferior temporal arch. Macular optic coherence tomography (OCT) is performed (Heidelberg Engineering, Germany), where a solution of continuity of foveal internal and external layers is found, a submacular hyporeflective area with a central macular thickness of 414 microns.

According to the BETT classification, it corresponds to closed ocular trauma type A, grade C, zone III, negative pupil, left eye. Diagnosis of blunt ocular trauma with submacular hemorrhage + macular hole in the left eye was made (Figure 1-4).

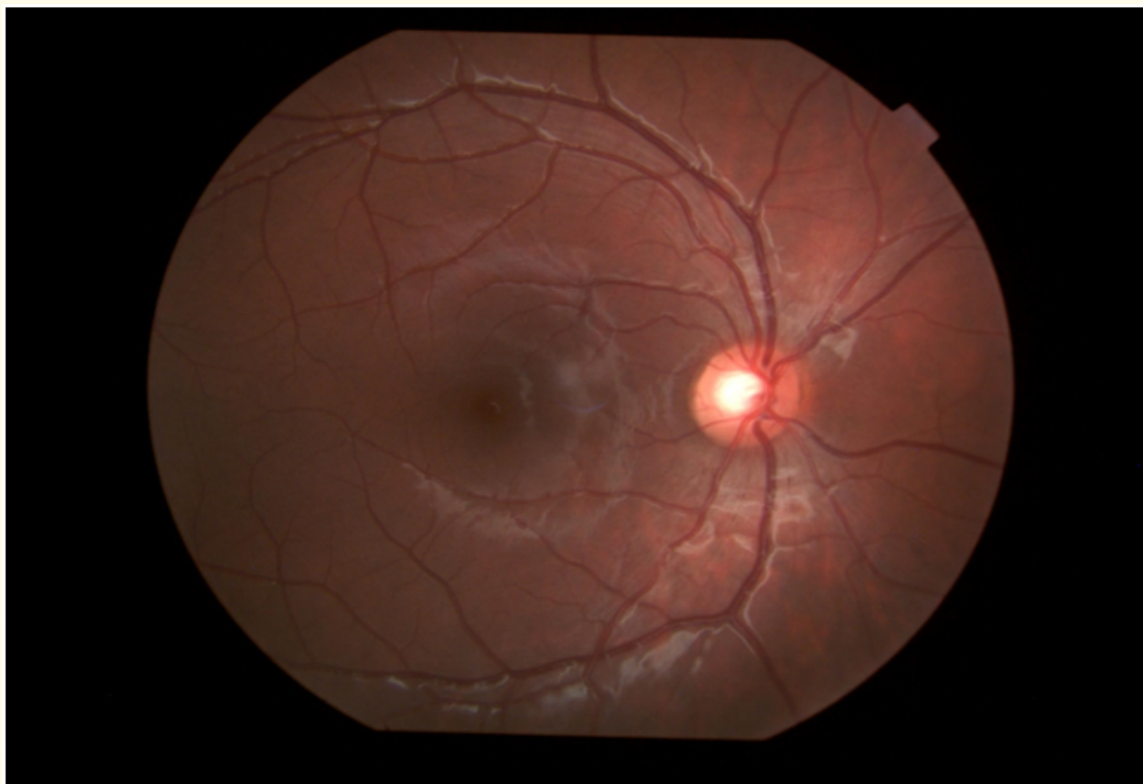

Figure 1: Clinical picture of the right eye fundus without alterations.

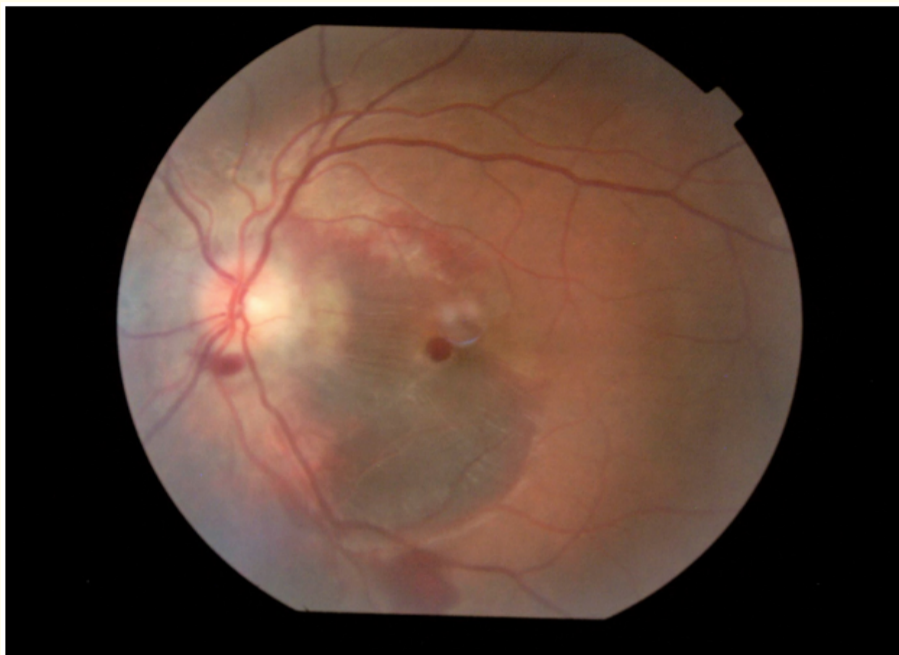

Figure 2: Clinical picture of the left eye fundus where submacular hemorrhage and macular hole can be seen, as well as intraretinal hemorrhage outside the inferior temporal arch and another one inferior parapapillary

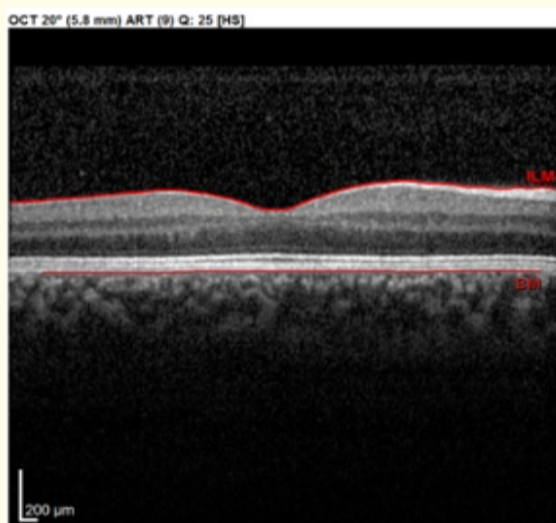


Figure 3: Macular OCT of the right eye without alterations.

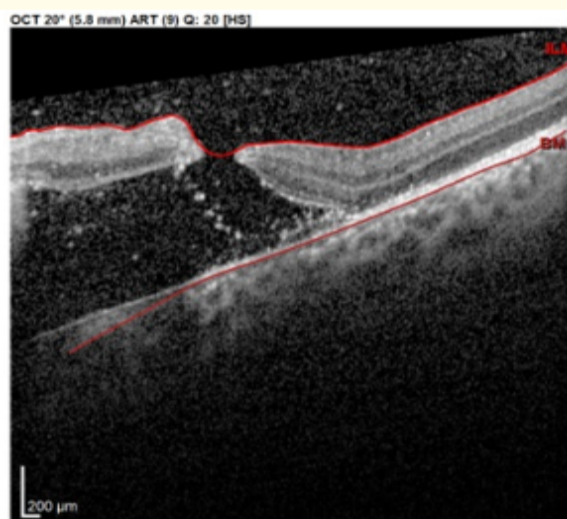


Figure 4: Macular OCT of the left eye with presence of thickening secondary to increased hyporeflectivity in subfoveal area and presence of full thickness macular hole, no data of vitreomacular traction.

Having these findings, preoperative studies for pneumo-displacement with sulfur hexafluoride gas (SF6) were performed.

The procedure is performed in the operating room under sedation, as usual with an injection of 4 cc at 3.5 mm from limbus of 100% SF6. Follow by the indication to keep the patient in a prone position for at least one week, and an antibiotic with steroid every 6 hours for 5 days.

It is reviewed next day and he didn't present data of infection. A week after the procedure, he's visual acuity in the left eye was 20/133, he had 30% gas bubble, applied retina, macular area with presence of pigmentary changes at nasal area and subretinal hemorrhage already displaced downwards outside the lower temporal arch, in OCT there is still a macular hole and presence of increased hyperreflectivity in the subretinal space, so it is indicated that it continues with prone position for at least one more week and evaluated at month of the procedure.

After 30 days he has visual acuity of 20/66 in left eye intraocular pressure of 15 mmHg, applied retina, in macular area presence of pigmentary changes, without image of macular hole. Macular OCT is again performed where it is confirmed that there is no longer a macular hole and a slight persistence of submacular hyporeflectivity, increased in thickness with the presence of macular central atrophy and alteration in external hyperreflective lines (Figure 5 and 6).

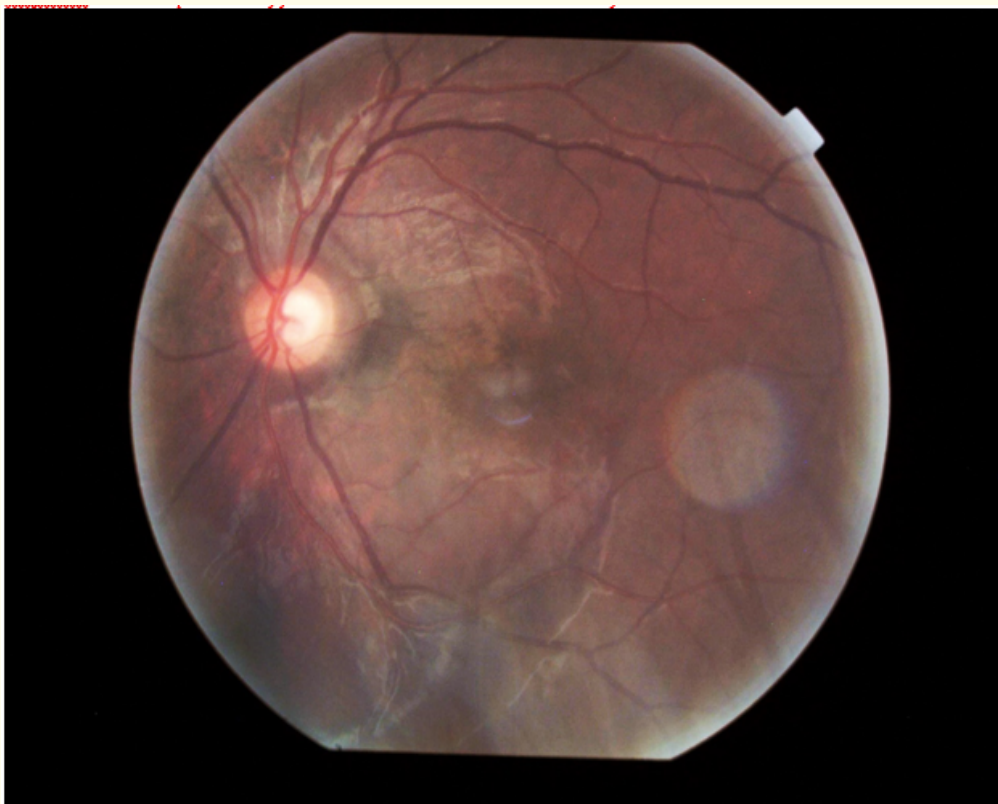


Figure 5: Clinical picture of the left eye fundus where you can see macular pigmentary changes, temporal parapillary presence of well-defined hyperpigmentation surrounding the area of hypopigmentation involving the papillomacular bundle.

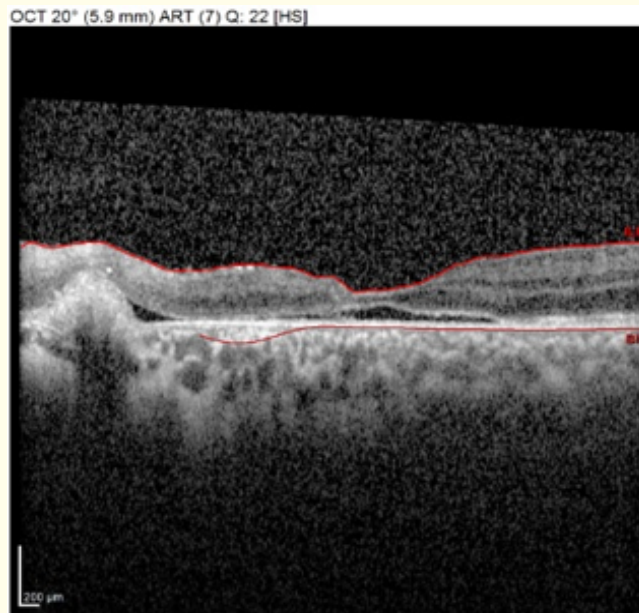


Figure 6: Macular OCT with little presence of subfoveal hyperreflectivity with alteration in the architecture of the external and internal retinal lines in the foveal area, with the presence of thinning of the layers of the retina

After 3 months of follow-up, he had visual capacity of 20/50, and he still had pigmentary changes in the macular area and he had no macular hole.

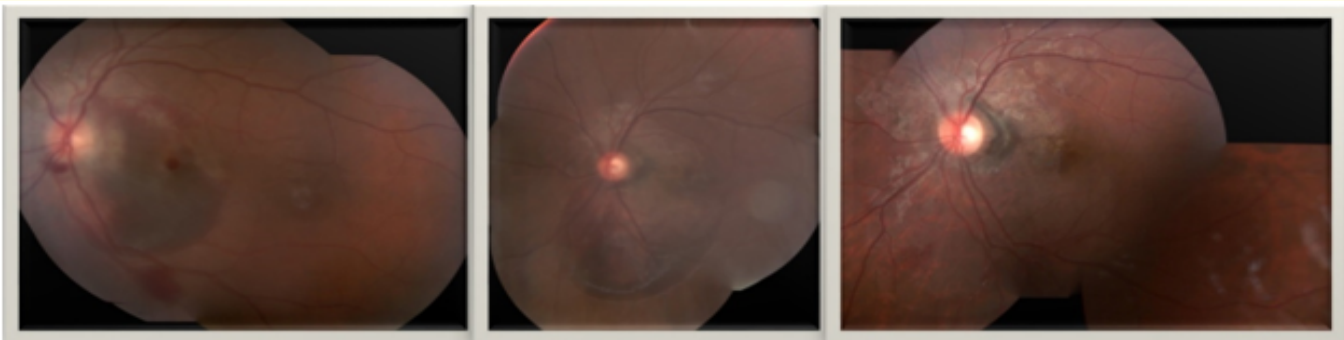


Figure 7: Comparison of composition clinical photographs of the initial left eye fundus with the presence of submacular hemorrhage and macular hole, a month later with displacement of submacular hemorrhage to the lower area and at 3 months with pigmentary changes in the macular area.

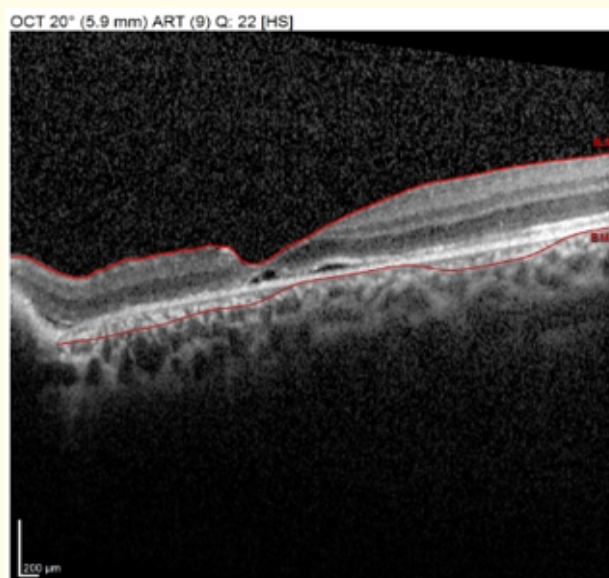


Figure 8: OCT macular left eye with foveal area thinned, presence of hyporeflectic spaces between RPE and external layers of the retina.

Discussion

In the literature it is reported that stones constitute 3.5% of the causes of ocular trauma in general and in children between 7 and 12 years old at 22.7%, the impact by any projected object, other than a ball, corresponds to the 17.4%. According to a study, patients with the characteristics comparable to the case of our patient presented a 25.9% with that initial visual acuity and end with a visual acuity between 20/50 to 20/200 3.3%, generally report better visual results in cases of blunt ocular trauma [3,4]. Given the characteristics of our patient and the time of evolution for the intervention, it was expected that the visual acuity would not improve to 20/20, although the longer term follow-up is pending [3,5].

Regarding the spontaneous closure of traumatic holes is reported up to 50% between 3 and 6 months, but it depends on certain characteristics of the macular hole, such as the presence of cysts and in some studies they refer to the presence of associated submacular fluid, in other studies they do not refer to characteristics of the hole that can predict spontaneous closure. Spontaneous closure has been reported in the first 5.7 weeks after the trauma by 40% [6,7].

For the therapeutic decision, we took into account the characteristics of our patient and the resources we had, although in the literature cases of early vitrectomy have been reported for macular holes, we try to remain conservative with the patient even though good results are described, we also know of the high rate of spontaneous closure and therefore, it was decided only to carry out the displacement of macular hemorrhage with SF6 gas, which is described since 1998 by Ohji, et al. knowing that submacular hemorrhages have consequences in visual acuity when they aren't displaced. There are reports that refer retinal damage after 24 hours of submacular hemorrhage in rabbits and cats, at 14 days atrophy is present. Similar results have been reported with the use of gas and posterior prone position, than with the use of tissue plasminogen activating factor [6-8].

Conclusion

In spite of the presentation and the time of evolution, we obtained an improvement of the visual capacity from 20/400 to 20/50, the displacement of the macular hemorrhage and closing of the traumatic macular hole was achieved at 4 weeks of the treatment. He will maintain follow up in our center, to monitor and if necessary take other therapeutic actions.

According to what is found in the bibliography, this is the first reported case of submacular hemorrhage + traumatic macular hole treated with SF6 gas in children.

Conflict of Interest

We declare no financial interest and no conflict of interest exists.

Bibliography

1. Edita Puodžiuvienė, *et al.* "A five-year retrospective study of the epidemiological characteristics and visual outcomes of pediatric ocular trauma". *BMC Ophthalmology* 18.1 (2018): 10.
2. Satendra Singh, *et al.* "Epidemiology, clinical profile and factors, predicting final visual outcome of pediatric ocular trauma in a tertiary eye care center of Central India". *Indian Journal of Ophthalmology* 65.11 (2017): 1192-1197.
3. Ebrahim Abdullah Yehia Al Wadei, *et al.* "Epidemiological Features of Pediatric Ocular Trauma in Egypt". *Journal of Ophthalmology* (2016): 7874084.
4. Pascual-Camps I, *et al.* "Spontaneous closure of traumatic macular hole in a pediatric patient". *Journal of AAPOS* 21.5 (2017): 414-416.e1.
5. Freda Sii, *et al.* "The UK Paediatric Ocular Trauma Study 2 (POTS2): demographics and mechanisms of injuries". *Clinical Ophthalmology* 12 (2018): 105-111.
6. Haoyu Chen, *et al.* "Prediction of spontaneous closure of traumatic macular hole with spectral domain optical coherence tomography". *Scientific Reports* 5 (2015): 12343.
7. Miller JB, *et al.* "Long-term Follow-up and Outcomes in Traumatic Macular Holes". *American Journal of Ophthalmology* 160.6 (2015): 1255-1258.e1.
8. Glenn Yiu and Tamer H Mahmoud. "Subretinal Hemorrhage". *Developments in Ophthalmology* 54 (2014): 213-222.

Volume 9 Issue 10 October 2018

©All rights reserved by Miriam Guadalupe Arellano Ganem, *et al.*