

Comparison between Retinal Nerve Fiber Layer Thickness in Diabetic Patients and Normal Control

Nagla Hassan Ali^{1*}, Noura Khalid Al Qassimi² and Maged Adly Naguib¹

¹Memorial Institute for Ophthalmic Researches Giza, Egypt

²Sheikh Khalifa Medical City, Abu Dhabi, UAE

***Corresponding Author:** Nagla Hassan Ali, Memorial Institute for Ophthalmic Researches Giza, Egypt.

Received: March 19, 2018; **Published:** April 27, 2018

Abstract

Purpose: To detect that retinal nerve fiber layer (RNFL) thickness in Diabetic patients with NPDR showed decrease thickness than normal control using optical coherence tomography (SD-OCT).

Patients and Methods: The individual RNFL parameters of OCT were obtained for 60 eyes, who were divided into two groups: Group 1 included 20 eyes of healthy individuals as control. Group 2 included 40 eyes of diabetics with mild non-proliferative diabetic retinopathy (NPDR) without maculopathy.

Results: RNFL thickness detected statistical significant decrease among patients in group (2) with mild NPDR than control.

Conclusion: Diabetic patients with mild NPDR have a quantitative discrepancy in RNFL thickness measurements, RNFL thickness have been observed to be decreased in thickness than normal subjects.

Keywords: Diabetic Retinopathy; Optical Coherent Tomography; Retinal Nerve Fiber Layer Thickness; Apoptosis; Type 2 Diabetes

Abbreviations

DR: Diabetic Retinopathy; NPDR: Non Proliferative Diabetic Retinopathy; OCT: Optical Coherence Tomography; RNFL: Retinal Nerve Fiber Layer; SLP: Scanning Laser Polarimetry; INL: Inner Nuclear Layer; OPL: Outer Plexiform Layer

Introduction

Diabetic retinopathy (DR) leads to direct damage to the nerve fiber layer, glial cells or neuronal metabolism which directly impact neurotransmission and may lead to apoptosis of retinal neurons, ischemia, reduced protein synthesis, depleted myoinositol, and high sorbitol levels have been demonstrated in patients with diabetes and may also result in nerve fiber loss in peripheral nerves [1].

Several studies have reported RNFL thinning or defects in people with diabetes that is not only caused by biochemical mechanisms that potentially cause neural cell degeneration but also by the laser photocoagulation that cause destruction of the retinal regions which leads to vascular abnormalities.

As this study discussing that Diabetic patients with mild NPDR showed decreased in thickness than normal subjects, also this decrease which is an early detection of RNFL thinning may help ophthalmologists to provide effective treatment of diabetic retinopathy and early prevention, thus reducing vision loss [2].

OCT performs, cross-sectional tomographic imaging in tissues, it is analogous to ultrasound B-mode imaging except that it uses light rather than sound. OCT performs imaging in biological tissues by directing an optical beam of infrared low coherence laser onto the tissue and measuring the reflected or backscattered intensity of light from microstructures within tissue as a function of depth [3].

Retinal nerve fiber layer (RNFL) measurements using optical coherence tomography (OCT) programs for nerve head indicate that the highest degree of variability can be attributed to interpatient differences. The recently developed OCT provides the ophthalmologist with the opportunity to customize scans and to tailor a single scan circle to examine RNFL thickness. Custom scans can be useful to help the ophthalmologist differentiate normal from early affected peripapillary RNFL.

Patients and Methods

This study analyzed 60 eyes of adult 80 patients whom their ages ranged from 45 - 55 years who attended the out patients clinics at the memorial institute for ophthalmic researches and where The study was approved by the ethical committee of the scientific research, Subjects were given full explanations about the purpose of the study and its consequences and all patients were informed about the steps of the examinations and investigations and accordingly the patients were divided into 2 groups.

- Group (1) 20 eyes of normal control.
- Group (2) 40 eyes of diabetics with mild non-proliferative diabetic retinopathy (without maculopathy or macular edema).

Patients were subjected to full ophthalmological examination including measurement of visual acuity aided and unaided, refraction, anterior segment examination using slit lamp biomicroscopy to detect any opacity or any other abnormality intraocular pressure measurement, and posterior segment examination using slit lamp with +90 lens.

Patients were selected based on the following criteria:

- (i) Type 2 Diabetes mellitus with mild NPDR.
- (ii) Age between 45 - 55 years old.
- (iii) Duration of diabetes more than 5 years.
- (iv) Clear view of the retina.

Exclusion criteria

Eyes with high myopia, optic neuropathy, advanced cataract and cloudy media were excluded from the study. We also excluded a cases of diabetic retinopathy with previous history of laser, previous history of vitreoretinal surgery, diabetic retinopathy with diabetic macular edema and other retinopathy due to hypertension or vascular diseases.

Exclusion criteria also included high refractive errors, cup disc ratio more than 0.3 intraocular pressure more than 21 mm or any other ocular or systemic diseases.

All the patient are staged as mild NPDR by colored fundus photography and FFA using Topcon fundus camera where mild NPDR showed presence of few dots of hemorrhages, microaneurysms and hard exudates without macular edema categorized as mild NPDR and the later phases of the test apart from the fovea excluding any macular edema.

Optical coherence tomography performed with SD OCT Topcon (3D SD OCT 2000 FA +) using retinal nerve fiber layer thickness through 3D disc protocol measuring strategy after pupil dilation with 1% tropicamide and each eye had circular scans around the optic disc with a diameter of 3.4 mm. average of three qualified circular scans was used to calculate the overall mean total RNFL thickness from this 3d disc strategy.

The software provides various summary statistics of the resulting RNFL thickness with a comparison to a normative data base. Values are compared to age appropriate normative data base and indicates whether they fall within the top 5% (coded white) top 95% (green) bottom 5% (yellow) or bottom 1% (red). Finally the mean total RNFL thickness were obtained by statistical analysis by T test with P value significant when it is below 0.05.

Results

This study was performed on 60 eyes of 80 patients divided into 2 groups with mean age 45 - 55 years.

- Group (1) 20 eyes of normal control.
- Group (2) 40 eyes of diabetics with mild non-proliferative diabetic retinopathy.

In group (1) control patients showed mean total RNFL thickness 116.82 \pm 9.5 and there were no significant decrease in any special quadrant (Figure 1).

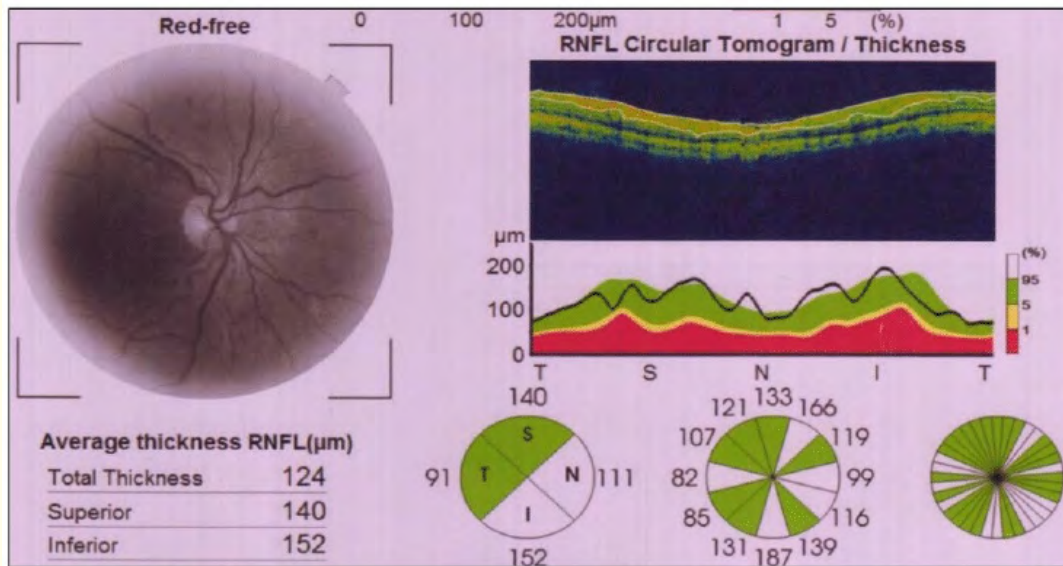


Figure 1: Mean total RNFL thickness in normal group (1).

In group (2) diabetics with diabetic retinopathy (mild) non-proliferative diabetic retinopathy showed significant decrease in mean total RNFL thickness 105.73 and SD \pm 8.3 compared to group (1) control (Figure 2).

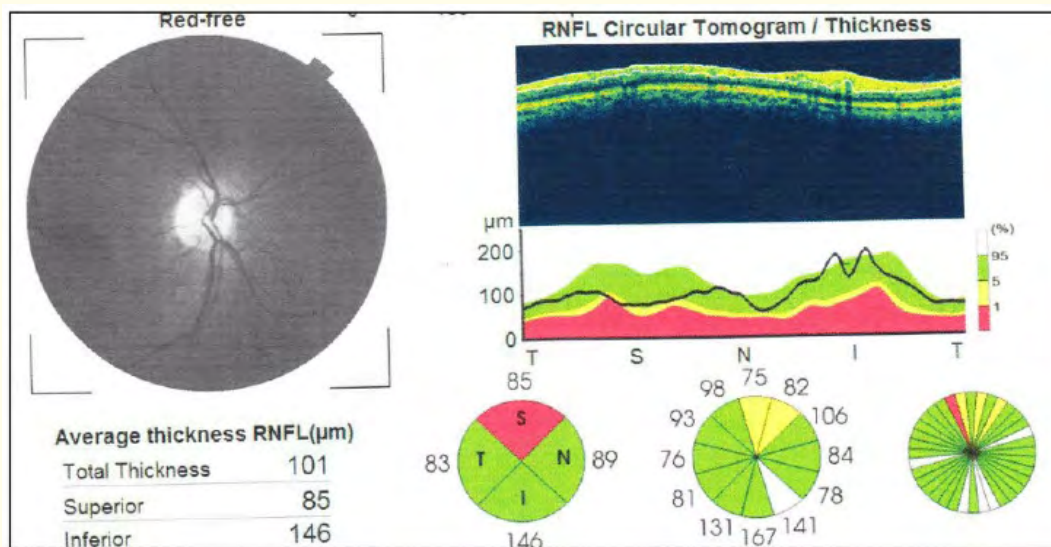


Figure 2: Mean total RNFL thickness in group (2).

The comparison study between two groups showed significant decrease in total mean RNFL thickness and SD in group (2) compared to control group (1) and this decrease was significant with p value 0.011 as seen in figure 3 and 4.

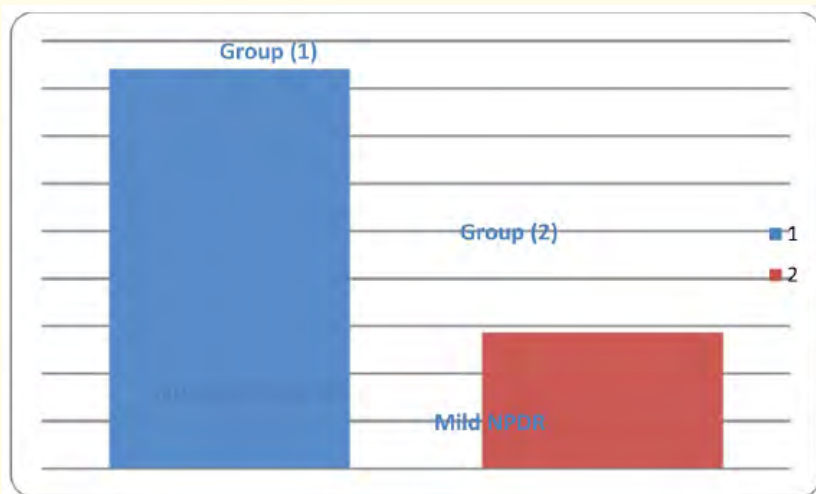


Figure 3: Comparison between the mean RNFL thickness in group (1) where the mean total RNFL thickness is 116.82 and SD is +/- 9.5 while in group (2) the mean total RNFL thickness is 105.73 and SD is +/- 8.3 with p value 0.011.

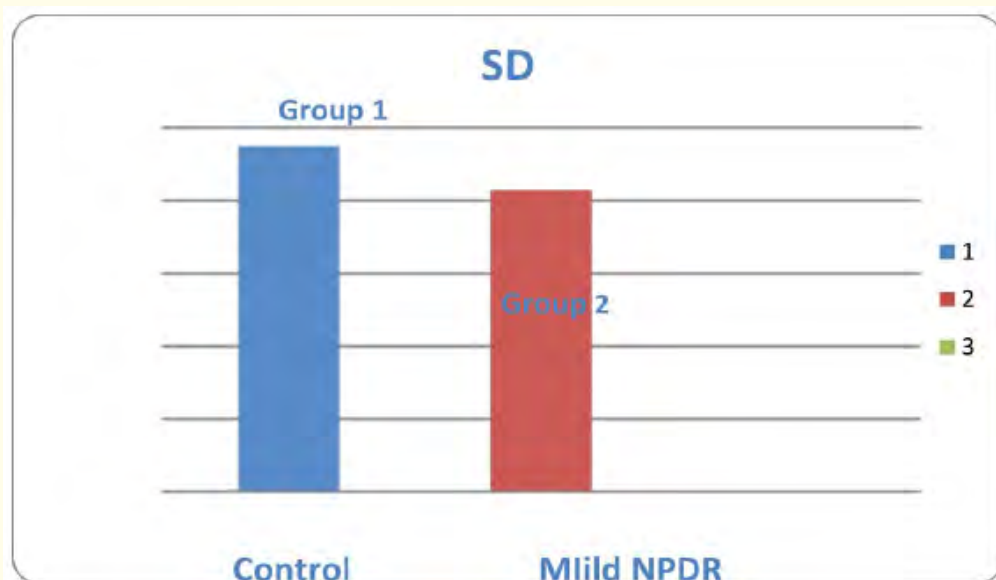


Figure 4: Comparison between the SD of RNFL thickness in group (1) where the SD is +/- 9.5 while in group (2) SD is +/- 8.3.

Discussion

Diabetic retinopathy causes impairment in retrograde axonal transport and a reduction in the cross-sectional size of large optic nerve fibers in diabetic rats were found [4]. The apoptosis-promoting factors in retinal ganglion cells (RGCs) are enhanced in the sensory retina in diabetes, and the death of the RGCs occurs early in diabetic eyes. Other morphologic studies using staining have reported that enhanced apoptosis of neuroglial elements may affect the early onset of diabetes-associated RNFL loss [5].

Obtained results are consistent with those using scanning laser polarimetry (SLP). However, SLP itself has a basic problem, as measurement may be influenced by anterior segment polarization, although this problem has recently been improved [6]. OCT provides a better sensitivity than other ocular imaging instruments including SLP [7]. So, OCT assessments of RNFL thickness are reliable enough, which indicates that OCT is a useful tool, not only for advanced retinopathy but also for early diabetic retinal changes [8].

Previous studies have reported that the RNFL thickness has been decreased in the all quadrants regions, however other reports suggested that the superior region is more susceptible to initial damage than the other regions and It is unclear if the structural changes in Diabetic retinopathy are caused by ischemic matters [9].

Accordingly OCT can be used to detect much earlier signs and structural changes of diabetic retinopathy not only in macular area as compared to fundoscopic or photographic examinations but also through RNFL thickness too [10].

Early detection of RNFL thickness changes caused by early diabetic retinopathy can leads to earlier treatments, although the existence of the first retinal changes does not have a therapeutic consequence [11], as we believe that OCT measurements may be one of the useful methods to elucidate the characterization of early structural changes of DR [12].

Some studies stated that the mean average thickness and nasal average thickness of RNFL in mild-moderate, and severe NPDR groups decreased compared with those of the other groups. There was an increase in the temporal average thickness of RNFL in the PDR group. As the duration of diabetes increased, the mean average and nasal average of RNFL thickness also decreased. The severity of diabetic retinopathy didn't show statistically significant differences in a topographic analysis of the optic nerve head [13].

Also future management for those patients and considerations about those changes especially in diabetic patients with glaucoma should be our future question as both glaucoma and diabetic retinopathy causes decrease in the RNFL thickness [14].

Conclusion

Diabetic patients with mild NPDR have a quantitative discrepancy in RNFL thickness measurements, RNFL thickness have been observed to be decreased in thickness than normal subjects.

Bibliography

1. Chihara E., *et al.* "Retinal nerve fiber layer defect as an early manifestation of diabetic retinopathy". *Ophthalmology* 100.8 (1993): 1147-1151.
2. Verma A., *et al.* "Does neuronal damage precede vascular damage in subjects with type 2 diabetes mellitus and having no clinical diabetic retinopathy?" *Ophthalmic Research* 47.4 (2012): 202-207.
3. Huang D., *et al.* "Optical coherence tomography". *Science* 254.5035 (1991): 1178-1181.
4. Zhang Lixin., *et al.* "Retrograde axonal transport impairment of large-and medium-sized retinal ganglion cells in diabetic rat". *Current Eye Research* 20.2 (2000): 131-136.
5. Fritsche P., *et al.* "Retinal thickness analysis (RTA): an objective method to assess and quantify the retinal thickness in healthy controls and in diabetics without diabetic retinopathy". *Retina* 22.6 (2002): 768-771.
6. Pires I., *et al.* "Retinal thickness in eyes with mild nonproliferative retinopathy in patients with type 2 diabetes mellitus: comparison of measurements obtained by retinal thickness analysis and optical coherence tomography". *Archives of Ophthalmology* 120 (2002): 1301-1306.
7. Villain MA and Greenfield S. "Peripapillary nerve fiber layer thickness measurement reproducibility using optical coherence tomography". *Ophthalmic Surgery, Lasers and Imaging Retina* 34.1 (2003): 33-37.

8. Goebel W and Kretzchmar-Gross T. "Retinal thickness in diabetic retinopathy: a study using optical coherence tomography (OCT)". *Retina* 22.6 (2002): 759-767.
9. Oshima Y, *et al.* "Quantitative assessment of macular thickness in normal subjects and patients with diabetic retinopathy by scanning retinal thickness analyser". *British Journal of Ophthalmology* 83.1 (1999): 54-61.
10. Schuman JS, *et al.* "Reproducibility of nerve fiber layer thickness measurements using optical coherence tomography". *Ophthalmology* 103.11 (1996): 1889-1898.
11. Lopes de Faria JM, *et al.* "Retinal nerve fiber layer loss in patients with type 1 diabetes mellitus without retinopathy". *British Journal of Ophthalmology* 86.7 (2002): 725-728.
12. Sanchez-Tocino H, *et al.* "Retinal thickness study with optical coherence tomography in patients with diabetes". *Investigative Ophthalmology and Visual Science* 43.5 (2002): 1588-1594.
13. Jee Taek Kim, *et al.* "Analysis of the Optic Nerve Head and RNFL Thickness Using Optical Coherence Tomography in Diabetes". *Journal of the Korean Ophthalmological Society* 49.6 (2008): 935-941.
14. Schuman JS, *et al.* "Quantification of nerve fiber layer thickness in normal and glaucomatous eyes using optical coherence tomography: a pilot study". *Archives of Ophthalmology* 113.5 (1995): 586-596.

Volume 9 Issue 5 May 2018

©All rights reserved by Nagla Hassan Ali, *et al.*