

An Unusual Case of Phthiriasis Palpebrarum Infestation

Ozge Güngör Akkus* and Meral Türk

Department of Ophthalmology, Private Tekden Hospital, Turkey

*Corresponding Author: Ozge Güngör Akkus, Department of Ophthalmology, Private Tekden Hospital, Turkey.

Received: October 22, 2017; Published: December 23, 2017

Abstract

Phthiriasis palpebrarum is an ectoparasite infestation of eyelashes caused by *Phthirus pubis*. Generally it observed in poor hygienic condition as overcrowded or underdeveloped countries and sexually active population in developed countries. We report a case of a 3 years old girl. She is unusual case because it is not similar to the socioeconomic level of the cases reported in the literature until now.

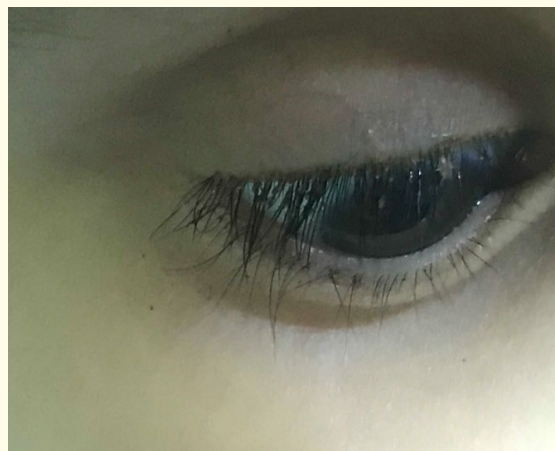
Keywords: Infestation; Lice; Eyelash; Petroleum Jelly

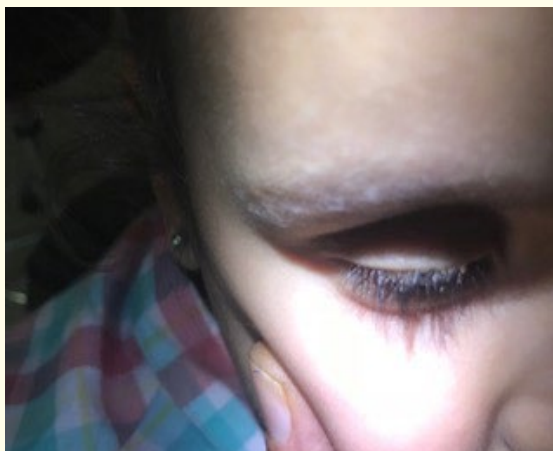
Introduction

Phthiriasis palpebrarum is a rare infestation caused by *Phthirus pubis*. Although its major habitat is inguinal region, it seldom effects eyelashes. Pubic lice infestation contributes 1 - 2% of total human population worldwide [1]. Generally it observed in poor hygienic condition as overcrowded or underdeveloped countries and sexually active population in developed countries. We want to present a case that is atypical for the person who is seen.

Case Report

A 3-year-old girl is brought to the hospital because of itching and burning at her eyes for two weeks. The family said they noticed things that moved in her lashes. Slit lamp examination there were numerous small translucent oval nits and adult lice coating her eyelashes (Figure 1,2). There was no hyperemia or discharge present in the conjunctiva and the cornea. On the first examination little girl was very agitated so we couldn't take sample. We told to her family the treatment options including cutting off her lashes and other medications. They did not allow their daughter's lashes to be cut off. We prescribed vaseline ointment four times a day and eye shampoo including Tea Tree Oil. After taking medication for three days, we convinced them to cut off her lashes and take sample eventually. The samples were taken from her eyelashes as much as possible and sent for parasitological examination, which confirmed the diagnosis. We went on the same medicine. We gave information about transmission types of this infestation. They said that there were many chickens in their neighborhood and asked if her illness could be transmitted in this way. Her mother noticed nits in her head. We recommended shampoos containing permethrin to get rid of these head lice. After two weeks we succeed to eradicate the lice. Her parents strongly refused any history of sexually contact or venereal disease. The socioeconomic status of the family was good and they were very interested in their children. Her mother stated that she couldn't worked anywhere because of daughter's sensitive personality structure. The child had eczematous skin rash when her parents left her alone.





Discussion

Phthiriasis palpebrarum is a member of hematophagous ectoparasites [2,3]. *Pediculus humanus corporis*, the human body louse, *Pediculus humanus capitis*, the head louse, *Phthirus Pubis*, crab louse. The first two are biological variants of the same species and have elongated body and narrow anterior mouthparts and they can be intermingle. But *P. pubis* is entirely different species with a distinctive morphology and habitat. Adult pubic louse is 1 - 2 mm in size with a broad oval, and flat translucent body. Due to this translucent view it can be difficult to see. It can be visualized when freshly injected blood meal. The body is divided into three divisions: head, thorax and abdomen. It has three pairs of short, stout legs and powerful claws which help to grasp tightly to hair shafts and remaining more localised. Life span passes in three stages: Nits to Nymph to Adult and about 1 month. Nits are operculated and oval, white or dark and remain attached to the base of hair near the skin where they find right temperature to incubate. It is difficult to remove. After 5 - 10 days, a nymph emerges and grows into adult in 7 - 10 days. It cannot live more than 48 hours outside human body. But nits can live up to 1 month sticking to the body of the head. Rarely the head louse found on the lashes, named as pediculosis palpebrarum. Sometimes the crab louse whose habitat is pubic and inguinal area, found lashes as an infective agent, named as phthiriasis palpebrarum. Transmission from genital area to eyes via hands or via beddings, towels contaminated with louse eggs. *P. pubis* predilection both eyelashes and pubic hairs is hypothesized arise from the observation that the average space between adjacent hair follicles in both region is equal to the grasping span of the louse's hind claws [3]. Due to the way of transmission, pediatric phthiriasis palpebrarum can represent child abuse, and the origins of this infection should be carefully investigated.

The removal of the crab lice and its nits from eyelashes mechanically has always been the basis of treatment [2-7]. When it is tedious and impossible because of all lashes coated by numerous ectoparasites and incompatibility of the patient especially in children like our case. Since we cannot mechanically clean the child's eyelashes, we cutted them off. Then we used petrolatum jelly four times a day as reported in the literature. Some drugs reported in the literature are not commercially available in our country like physostigmine eye ointment. We added the treatment an eye shampoo to provide lid hygiene and prevent secondary infection. Petrolatum jelly (Vaseline) is made of waxy petroleum material. Although the mechanism of action is not completely known, it is thought to close the ways of breathing so it prevents lice respiration or moving [5]. It has also ovicidal impact. The various treatment methods have been reported in the literature [1-7]. % 1 gamma benzene hexachloride cream and shampoo, %20 fluorescein, permethrin ointment and shampoo, phenothrin shampoo, % 0.25 physostigmine eye ointment, %1 lindane, 1% yellow mercuric oxide ointment, 1%, malathion drops, 1 % malathion shampoo (pediculocidal+ovicidal), pilocarpine gel, oral ivermectin, argon laser therapy or cryotherapy. Although a single dose gamma benzene hexachloride cream is effective, it has serious side effects as ocular irritation and epithelial toxicity [6]. Couch., *et al.* stated that they

treated a patient whose head skin was also affected similar to our patient with gamma benzene hexachloride shampoo [6]. In addition Ikeda, *et al.* reported that they treated the scalp hair with phenothrin shampoo [4]. We used Permethrin shampoo to treat the scalp hair. It is effective on both live lice and hatched lice (eggs), but not unhatched eggs. Because of its lack of percutaneous absorption, toxicity is not observed. It has almost 100% pediculicide and 20 to 70% ovicide activity. Anticholinesterase agents are reported to be as effective as other medicines. Not only they don't effect the nits but also they have undesirable ocular symptoms. Cryotherapy can be provide fast cure but this treatment may be very uncomfortable and potentially dangerous for the young uncooperative patient. Argon laser phototherapy has the same advantage of being a quick and effective method of treatment that can be done in one sitting. Its disadvantages are about damage to eyelash stems carrying the nits. But it seems rarely and well-tolerated. The lashes regain their normal length within a few days. In the same way as cryotherapy, this method cannot be used to treat young children owing to poor patient cooperation. The side effects of yellow oxide ointment are damage to the eyelid, conjunctiva, and Descemet's membrane. But it has been reported to be a reliable treatment method that can be used in children. Ivermectin is effective in killing these parasites by affecting the muscular and nervous system as it has a high affinity to glutamate-gated chloride channels [7].

It is important to examine areas with body hair and close contacts and treat with pediculicide shampoo to prevent a recurrence. Re-infestation can be prevent by sterilising clothing, linen, brushes and combs at a temperature of 5°C for 30 minutes [1]. The clinic findings of this Ectoparasitic infestation are commonly confused with bacterial, viral or allergic conjunctivitis, blepharitis, seborrheic dermatitis and even rarely keratitis [8-10]. Persistent pruritus caused by dermal hypersensitivity to louse saliva leads to scratching, inflammation, eczema, and seconder bacterial infection. In our case As mentioned above, sometimes lice can be difficult to identify due to their semi-transparent appearance and deep burrowing within lid margin. In our patient, the clinical presentation was so obvious that we were not forced to make a diagnosis.

Conclusion

Taking anamnesis properly and careful examination provide the correct diagnosis and appropriate treatment.

Bibliography

1. Kiran B, *et al.* "Case of Phthiriasis palpebrarum with blepheroconjunctivitis". *Indian Journal of Medical Microbiology* 30.3 (2012): 354-356.
2. Padhi TR, *et al.* "Ocular Parasitoses: A Comprehensive Review". *Survey of Ophthalmology* 62.2 (2016): 161-189.
3. Ryan FM. "Phthiriasis Palpebrarum Infection: A concern for child abuse". *Journal of Emergency Medicine* 46.6 (2014): 159-162.
4. Ikeda N, *et al.* "Phthirus Pubis Infestation of Eyelashes and Scalp Hairs in a girl". *Pediatric Dermatology* 20.4 (2003): 356-357.
5. Burns DA. "The treatment of Pthirus pubis infestation of the eyelashes". *British Journal of Dermatology* 117.6 (1987): 741-743.
6. Couch JM, *et al.* "Diagnosing and Treating Phthirus Pubis Palpebrarum". *Survey of Ophthalmology* 26.4 (1982): 219-225.
7. Bukhart CN and Bukhart CG. "Oral Ivermectin therapy for phthiriasis palpaebrium". *Archives of Ophthalmology* 118.1 (2000): 134-135.
8. Turgut B, *et al.* "Phthriasis palpebrarum mimicking lid eczema and blepharitis". *Journal of Ophthalmology* (2009): 803951.
9. Turow VD. "Phthiriasis palpebrarum: an unusual cause of blepharitis". *Archives of Pediatrics and Adolescent Medicine* 149.6 (1995): 704-705.

10. Manjunatha NP, *et al.* "Pediculosis pubis: presentation to ophthalmologist as pthriasis palpebrarum associated with corneal epithelial keratitis". *International Journal of STD and AIDS* 17.6 (2006): 424-426.

Volume 8 Issue 5 December 2017

© All rights reserved by Ozge Güngör Akkus and Meral Türk.