

Eye Traumas

Ibrahim Ali*

Private Clinic, Bekaa Hospital, Joub Jannine-Bekaa, Lebanon

***Corresponding Author:** Ibrahim Ali, Private Clinic, Bekaa Hospital, Joub Jannine-Bekaa, Lebanon.

Received: August 18, 2017; **Published:** November 30, 2017

Abstract

Ocular traumas represent one of the most devastating causes of worldwide irreversible loss of vision. Managing this type of injuries needs nonstandard multidisciplinary approaches. The trauma may affect not only the eye, but the surrounding soft tissues and bone structures.

In this article, we represent five cases of severe ocular traumas three of them caused by blast explosion, one car accident and one home accident, with optimal whether visual or cosmetic and subsequently psychological results.

Keywords: *Ocular Traumas; Sympathetic Ophthalmia (SO); Enucleation*

Introduction

Ocular traumas represent a difficult field in ophthalmology in both peace and war time.

There is no standard approach. The surgeon must be a plastic, cataract, glaucoma and other disciplines master at the same time. Even though, he might not be a retinal surgeon but the primary surgical intervention is very important and may determine the destiny of subsequent retinal surgery. Choosing the enucleation option may be the easiest approach, but one has to remember always that our mission as an eye doctor is to save the sight no matter how impossible and severe the case looked, at least to keep the eye as a cosmetic organ.

Light perception even incerta is a contra-indication of enucleation; Some traumas need several months even years, many steps, patience and attention to be managed but an unlimited satisfaction for the surgeon and the patient.

During my 30 years career, I had conducted about ten enucleations only.

I always have believed that my mission as an ophthalmologist, is to care about the eye and to fight for the organ of vision until the last breath; even in the most extreme situations.

The risk of sympathetic Ophthalmia (SO) in the era of steroids is exaggerated, and I had done only one case of typical fibrinoplastic SO in 1986.

Here I represent some cases of severe ocular traumas of Lebanese and Syrian casualties.

Case 1 – April 2014

Bader KM., Syrian refugee, 30 y/o male, blast war trauma: his left eye was enucleated and his right eye had undergone vitrectomy AC IOL. 20/12/14, was his first visit to my office; LE vis = 0

RE vis = 1/plc blue but not red vision, corneal ulcer, keratomalacia, hypopyon; panophthalmitis absence of the anterior chamber. IOL in contact with the cornea;

Scan B no RD CT SCAN no IOFB;

I began a treatment with Vancomycin intravitreal (IV) sub-conjunctival (S/C) injections of Gentamicin and Dexamethasone (G and D). Eye drops; Vancomycin 2.5% Vigamox, Pred Forte in total three Vancomycin IV injections, five S/C injections of Vancomycin, ten para bulbar and S/C injections of G and D.

10/02/15 vis RE, hand motions no hypopyon corneal vascularisation

18/02/15 IOL extraction

No finance for keratoplasty

08/07/15 PKP

10/07/15 finger counter

20/07/15 visus OD = 0.02

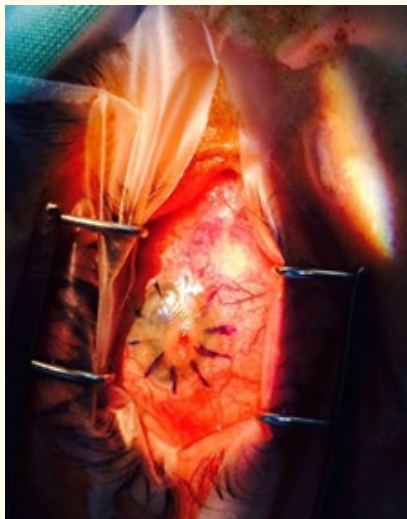
29/07/15 visus OD = 0.08

07/09/15 BCVA with sph + 4.0 cyl 4.0 ax 170 = 0.1 - 0.2

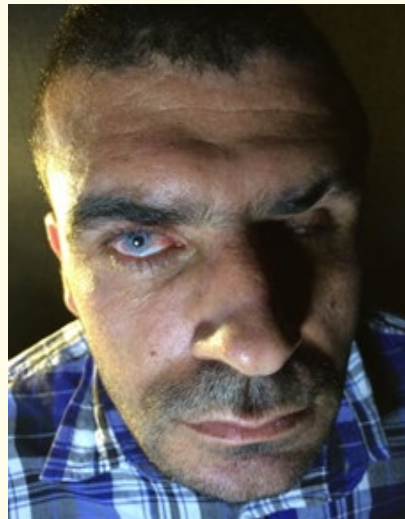20/03/16 BCVA = 0.3

22/10/15 sutures released

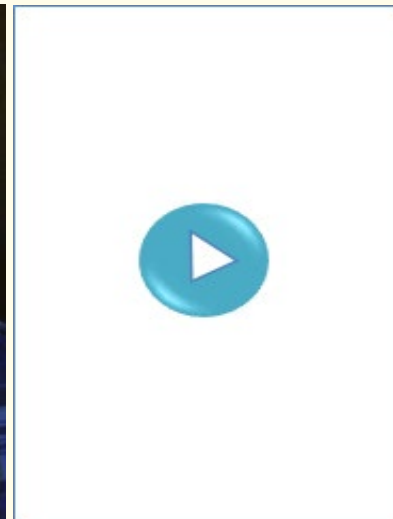
BCVA = 0.3



Pre-op (case 1)



Post-op (case 1)



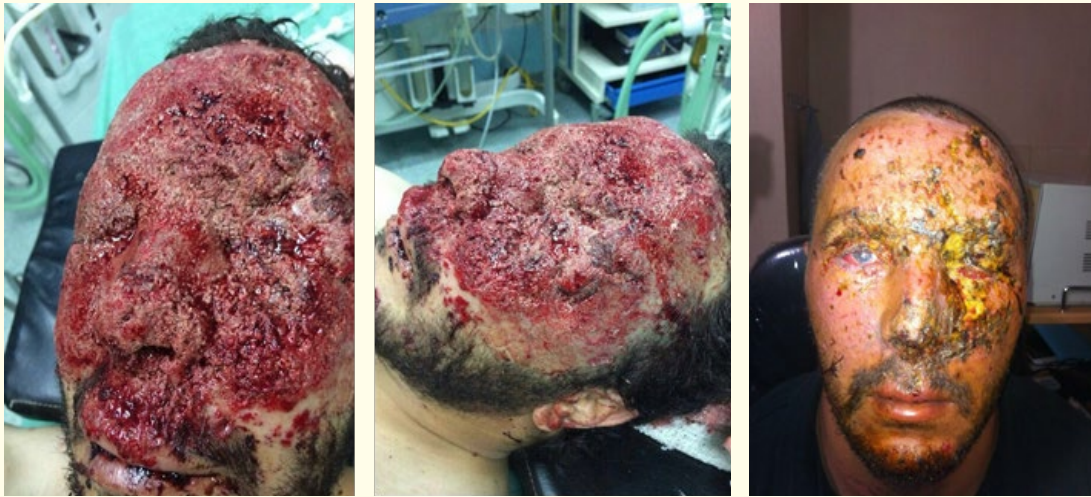Video 1

Case 2 – 28/4/2014

Mohamad AWH, 29 y/o male, explosion eyes polytraumas in Quarry Stones; LE: disintegration of the eye ball, posterior and superior orbital wall fractures, CNF leak. RE multiple perforating and non-perforating intra and extra ocular injuries non-countable intra and extra ocular foreign bodies RE vis = plc

Meticulous FB removal, injuries repair, neurosurgical intervention. One week post-op visual acuity was FC. ocular hypotony. Corneal edema.

I advised to postpone the next intervention for stabilizing IOP and corneal edema but the patient was operated somewhere two times in one week and had been lost for three months and appeared with ocular sub atrophy and vitreous fibrosis.



Pre-op (case 2)

One-week post-op (case 2)

Case 3 - 06/07/2017

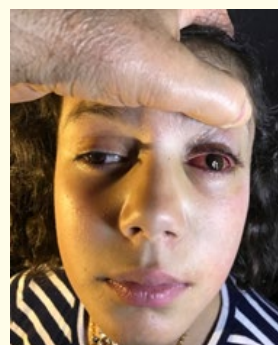
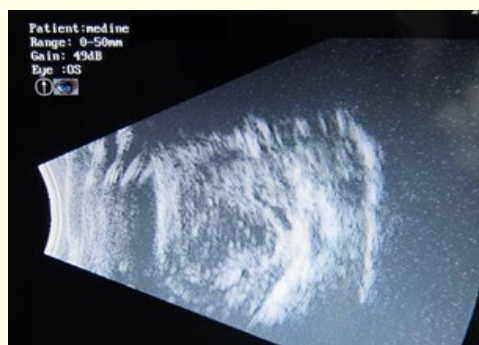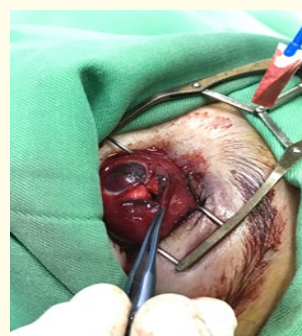
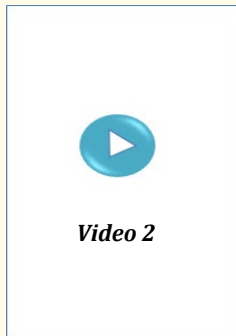
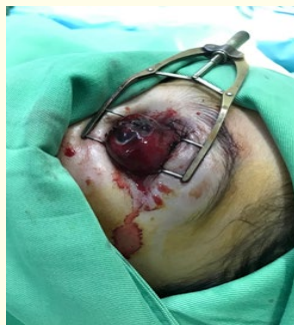Medina GF, 12 y/o female, was hit by an iron tube at home on her left eye.

RE vis = 1.0

LE vis = 0 zero

Rupture of the globe extending to the posterior pole with huge expulsive haemorrhage; the patient was under strong anticoagulant therapy related to congenital cardiac anomalies, and previous cardiac surgeries.

Meticulous repair of the injuries Zymarid, Pred Forte, Klacid, 5 parabular injections of G and D. On 14/07/2017 scan B total funnel retinal detachment and huge choroidal haemorrhage pre-op video post-op two weeks post-op.



Total funnel retinal detachment with huge choroidal hemorrhage Two weeks post-op (case 3)

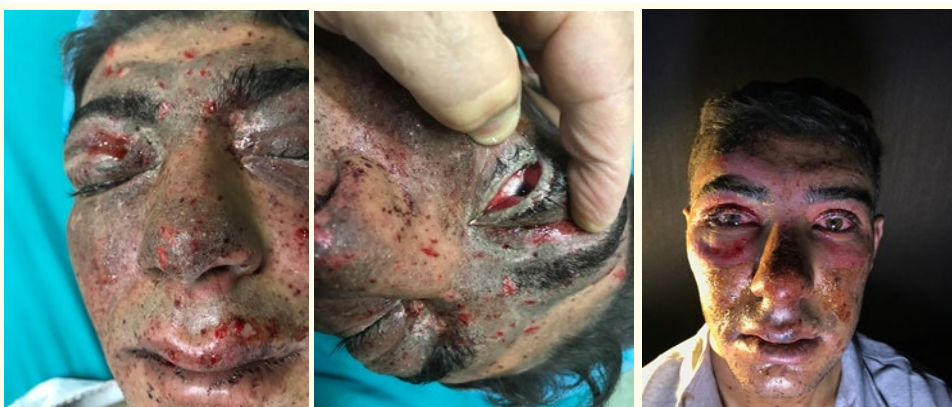Case 4 – 26/07/2017

Ahmad MH., 23 y/o male, had undergone an explosion eyes polytraumas in Quarry Stones.

RE non-countable extra and intraocular foreign bodies corneal perforation.

LE non-countable extraocular FB.

The surgery consisted of removing the intra and extra ocular FB suturing of corneal injury Tobradex, Klacid, parabolbar injections of G and D pre-op post-op 2 days vis OU = 0.4



Pre-op (case 4)

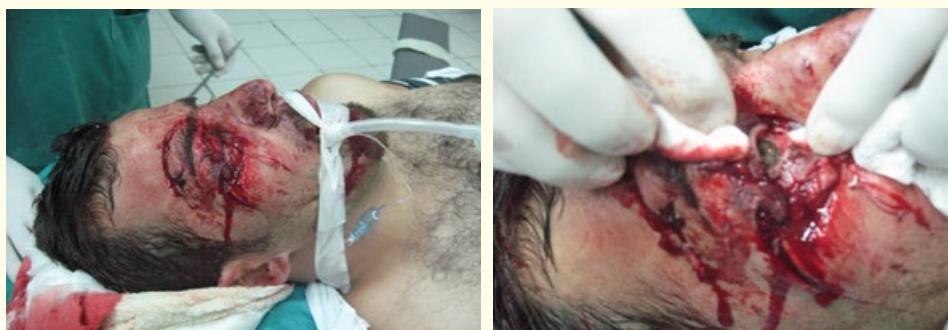Two days post-op (case 4)

Case 5 – 22/05/2012

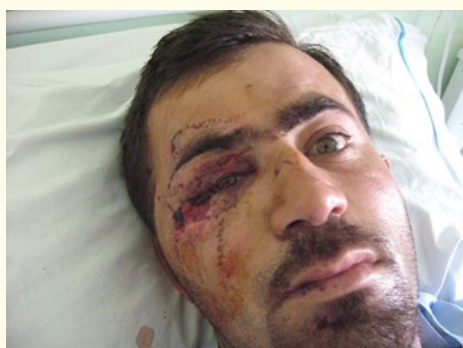H. M. T., 25 y/o male

The patient had a car accident, that lead to multiple perforations of right eyelids and surrounding tissues.

The eye remains intact vis OU = 1.0 pre-op post-op.



Pre-op (case 5)



Two days post-op (case 5)

Discussion

We presented five cases of severe ocular traumas.

Three patients preserve good or excellent visual acuity, while the other two only got cosmetic results, despite their disfiguring injuries.

Conclusion

Ocular traumas represent a difficult non-standard field in ophthalmology, but with patience and attention, you can get more than you expect, if only you do the best that you can.

Volume 8 Issue 4 November 2017

© All rights reserved by Ibrahim Ali.