

Benign Paralysis of Abducens in Children: Post -Viral Trigger or Vascular Component Undiagnosed?

Maíra L Acioli*, Luciano de B Mendes, Luis Felipe da S A Carneiro, Rafael S Costa and André de C Petti

Ophthalmology Department, Santa Casa de Misericórdia de Belo Horizonte-MG, Brazil

***Corresponding Author:** Maíra L Acioli, Ophthalmology Department, Santa Casa de Misericórdia de Belo Horizonte-MG, Brazil.

Received: September 14, 2017; **Published:** October 25, 2017

Abstract

Male patient, three years, admitted in emergency ophthalmologic sector of Santa Casa, Belo Horizonte, Brazil with left abducens paralysis started 24 hours ago, without any other comorbidities, trauma, aches or use of drugs and vaccines. In previous history, there was a similar esotropia episode reported at the age of 1 year and 6 months, with spontaneous improvement. The magnetic resonance of encephalous from the first event time which showed an upper displacement of the abducens nerves near to its emergence in Medullopontine sulcus with superior path to Anterior Inferior Cerebellar Artery which can lead to neurovascular conflict. The encephalo Magnetic Resonance Angiography showed near contact of Anterior Inferior Cerebellar Arteries with the cisternal portion of both Abducens Nerves predisposing neurovascular conflict. After thirty days from esotropia started the double sight vanished and both Abducens Nerves palsy and vicious head position decreased. The condition self improved after two months.

Keywords: *Esotropia; Abducent; Benign Recurrent; Abducens Palsy; Childhood*

Abbreviations

AICA: Anterior Inferior Cerebellar Artery; PBNA: Benign Paralysis of Abducens; MRI: Magnetic Resonance; AN: Abducens Nerve; NC: Neurovascular Conflict; MRA: Magnetic Resonance Angiography; BAANP: Benign Acquired Isolated Abducens Nerve Palsy; NMR: Nuclear Magnetic Resonance

Introduction

Benign paralysis of abducens is a common condition in the elderly, but rare in childhood. Most large studies date back to the 50 and 60 before the advent of modern neuroimaging techniques [1]. Recent studies may have different etiologies which were previously classified as idiopathic [1]. In this paper we will present a case study of a child presenting isolated benign palsy of abducens nerve secondary to vascular conflict with anterior inferior cerebellar artery.

Objectives

To report a benign paralysis of abducens (PBNA) in the left eye case a recurring condition in a healthy child. Discuss the etiology and the conditions that can function as trigger to this case.

Guide the minimum required workup to exclude major causes of sixth nerve palsy in children.

Case Report

Male patient, three years, brown skin without comorbidities, admitted in ophthalmologic sector of Santa Casa Belo Horizonte (State of Minas Gerais, Brazil) with left abducens paralysis started 24 hours ago. The companion denies any other comorbidities, trauma, aches

or use of drugs and vaccines. The mother made reference to upper respiratory tract infection symptoms fifteen days before the onset of esotropia with spontaneous improvement.

In previous history, there was a similar esotropia episode at the age of 1 year and 6 months, with spontaneous improvement. The magnetic resonance (MRI) of encephalous from the first event time showed an upper displacement of the abducens nerve (AN) near to its emergence in Medullopontine sulcus with superior path to Anterior Inferior Cerebellar Artery (AICA) which can lead to neurovascular conflict (NC).

At examination, the patient presented: head position tilted to the left and binocular fixation preference for the right eye. The Krinski test showed incomitant esotropia increased with the left eye focus. The gap increased in $\Delta 30$ in that gaze position with marked limitation of abduction of the left eye (-4/4). Pseudoptosis was absent in all gaze positions (Figure 1).

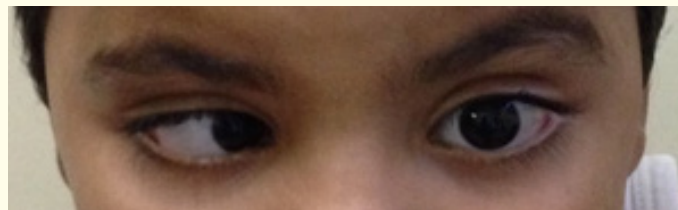

Figure 1: Levoversion limitation and abduction of the left eye (-4/4).

Visual acuity was 20/30 in both eyes and pupillary reflexes were preserved. The biomicroscopy and fundi were normal.

The encephalo Magnetic Resonance Angiography (MRA) showed near contact of AICAs with the cisternal portion of both ANs predisposing NCs (Figure 2 and 3).

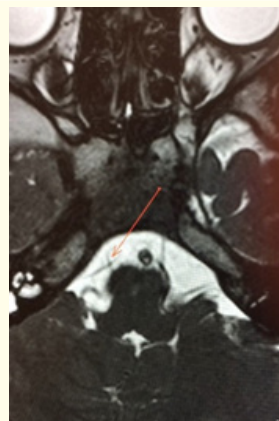


Figure 2: CISS-3D sequence the image shows the close relationship of AICA with the abducent nerve on the right side (arrow).

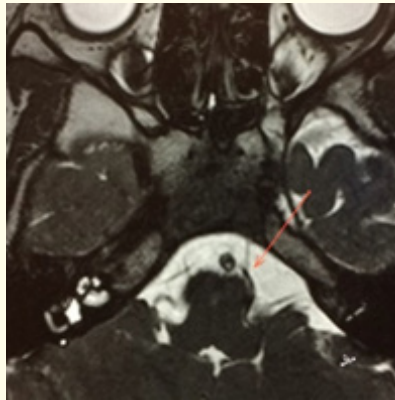


Figure 3: CISS-3D sequence The image shows the close relationship of AICA with the abducent nerve on the left side (arrow).

After thirty days from esotropia started the double sight vanished and both NA palsy and vicious head position decreased. The condition self improved after two months (Figure 4).

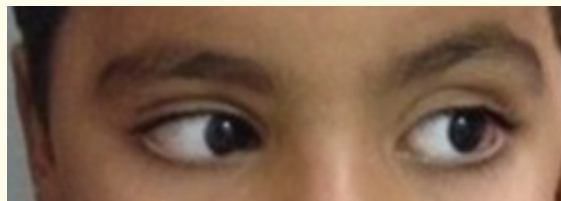

Figure 4: After two months: Levoversion and abduction limitation vanished.

Discussion

The AN palsy is a common clinical entity in the urgency unities that affects elderly patients with numerous comorbidities, but is a rare condition in infancy and childhood [2].

This inervacional defect origin varies being chronic diseases like diabetes and hypertension (the leading causes in adults and the elderly). However, in children the etiology is different. Tumors, bleeding, trauma, meningitis, sinusitis, petrositis, are all factors associated with this disease. Moreover, VI nerve palsy may occur rarely as a complication of ophthalmoplegic migraine [3].

When an isolate cause to AN palsy in children is not found it gains the name Benign Acquired Isolated Abducens Nerve Palsy (BAANP). It is rare clinical entity characterized by paralysis of AN undefined etiological cause and resolved spontaneously within six months. The diagnosis is determined retrospectively, after exclusion of the main VI pair paralysis conditions in childhood, cited above [4].

BAANP demands huge concern from parents and doctors once its differential diagnostics are diseases with high morbidity and mortality rate. Many studies suggests infectious diseases have a preponderant part as triggers, treating it as viral/post-viral neuritis. Lots of bacterial and viral agents described in literature were chronologically correlated with isolated AN palsy. Particularly, some works were described reporting BAANP after immunization against measles, mumps, rubella, diphtheria, tetanus, pertussis and infections as Epstein-Barr, varicella zoster, herpes zoster ophthalmic, mycoplasma, chlamydia, cytomegalovirus [4-6]. However these studies do not show histological nerve involvement evidences nor radiologic signs of contrast leakage in AN counting only with chronologic evidences of nerval palsy and positive serology to described entities.

Vascular Conflict is a widely described condition in literature in which cerebral arteries have contact with nervous structures causing symptoms clinically significant. One of the most common examples is the trigeminal neuralgia. However, this find is not easily diagnosed once it demands Nuclear Magnetic Resonance (NMR) of the encephalous with contrast and/or Magnetic Resonance Angiography of encephalous with emphasis to vascular conflicts [7].

The majority of studies in literature did not specify imagery examination methods and many have used Encephalous Magnetic Resonance only as standard test. Although, to view different segments of nerves I to XII is used in specific phases encephalous NMR [8,9]. This suggests that many BAANP may have NC undiagnosed due to lack of proper workup.

In case above, the anatomic relation between AICA and AN was diagnosed with FIESTA phase NMR and ANGIO NMR. By analyzing these data we infer that the neurovascular conflict is likely underdiagnosed entity, since childrens examination workup not always includes neuroimaging directed to evaluation of nerves and vessels.

Regarding symptoms improvement without chirurgical interventions, it is understood that as children are in development phase, positional changes occur in these structures many times causing the symptoms extinction, what goes towards BAANP characteristics, that, by definition shows spontaneous resolution.

The case related in this paper corroborates this hypothesis. In BAANP first episode at 1 year and 6 months, AICA and AN relation occurred in emergence in medullopontine area. In second episode, the structural contact occurred adjacent to cisternal area. These NMR findings showed the NC temporary character at that age due to inherent growth anatomical changes. This fact explain the symptom improvement without surgery.

BAANP in rare cases is recurrent [10]. In current case the recurrence can be explained by two neurovascular conflicts in distinct anatomic places.

Conclusion

The children abducent nerve palsies is a potential severe entity caused by high morbid/mortality rate diseases. When it occurs isolated receives the name Benign Abducent Nerve Palsy, which is a diagnosis by exclusion. In this form it is necessary a systemical and neuroimaging workup by NMR to exclude infectious etiology and neurovascular conflicts.

By this paper we propose a new workup and etiologic approach to explain BAANP through neural vascular conflicts.

Bibliography

1. Teksam O, *et al.* "Acute Abducens Nerve Paralysis in the Pediatric Emergency Department: Analysis of 14 Patients". *Pediatric Emergency Care* 32.5 (2016): 307-311.
2. Curi RLN, *et al.* "Paralisia do VI nervo (abducente)". *Revista Brasileira de Oftalmologia* 72.1 (2013): 59-69.
3. Cheng DR, *et al.* "Recurrent 6th nerve palsy in a child following different live attenuated vaccines: case report". *BMC Infectious Diseases* 12 (2012): 105.
4. Ozdemir M and Garipardiç M. "Benign Isolated Abducens Nerve Palsy". *European Journal of General Medicine* 7.2 (2010): 220-222.
5. Esmer AF, *et al.* "Neurovascular relationship between abducens nerve and anterior inferior cerebellar artery". *Folia Morphologica* 69.4 (2010): 201-203.

6. Taniguchi A., *et al.* "Bilateral abducens nerve palsy by compression from bilateral anterior inferior cerebellar artery". *Journal of Neurology* 258.12 (2011): 2271-2273.
7. Casselman J., *et al.* "MRI of the Cranial Nerves-More than Meets the Eye: Technical Considerations and Advanced Anatomy". *Neuroimaging Clinics of North America* 18.2 (2008): 197-231.
8. Hatipoglu HG., *et al.* "Comparison of FSE T2W and 3D FIESTA sequences in the evaluation of posterior fossa cranial nerves with MR cisternography". *Diagnostic and Interventional Radiology* 13.2 (2007): 56-60.
9. Mahoney NR and Liu GT. "Benign recurrent sixth (abducens) nerve palsies in children". *Archives of Disease in Childhood* 94.5 (2009): 394-396.
10. Lee MS., *et al.* "Sixth nerve palsies in children". *Pediatric Neurology* 20.1 (1999): 49-52.

Volume 8 Issue 3 October 2017

© All rights reserved by Maíra L Acioli., *et al.*