

Under Eye Filler Practices as Under Eye Hollows and Dark Circles' Treatments

Seyda Atabay*

Ophthalmologist, Private Practice, Izmir, Turkey

*Corresponding Author: Seyda Atabay, Ophthalmologist, Private Practice, Izmir, Turkey.

Received: May 10, 2017; Published: May 12, 2017

Abstract

Purpose: To evaluate the results of patients with complaint of under eye hollowness and dark circles and application of under eye hyaluronic acid filler, comparison of the cannula and injection techniques.

Method: Under eye hyaluronic acid filler was applied to the patients who consult to the clinic with complaint of hollows and dark circles under eye between March 2014 and December 2016. Application method was evaluated according to the success of results, satisfaction and complications.

Findings: 356 eyes of 178 patients were included to the research. There were 148 (83%) female and 30 (17%) male patients. Average age was 33 (age range 19 - 60). It was defined that the most frequently complaint was under eye hollowness with 84% and followed by dark circles with 74%. It is seen that in over 40 year old patients, the most common complaint was dark circles with 80%. The filler was applied to 140 patients with cannula and to 38 patients with injection. The hyaluronic acid filler was implemented 0,83ml (0,4 - 1,25ml) total for each eye approximately. Patients were followed averagely 14 month (1 - 32 month). While the most frequent complication was ecchymosis in 14 patients (8%), the second one was edema which lasts over two weeks in 8 patients. Emboli was not seen in any patient. When the cannula and injection techniques were compared, a distinct difference was seen in terms of ecchymosis risk. The risk of ecchymosis was 3% with usage of cannula, whereas with needle, it was 26%. Besides, while ecchymosis caused by injection was seen in more extensive area, the area caused by cannula was more limited. As satisfaction evaluation, 93% patients graded the filler application as good. 5% patients thought that it was average and 2% of them scored it as bad. 4 patients who evaluated the application bad were the ones that their filler was applied with injection and occurred ecchymosis in their under eye.

Result: The procedure of hyaluronic acid filler is an alternative treatment in the patients who have dark circles and hollows under eye. The procedure with cannula technique is safer for the patient satisfaction and risks of application, but this technique should be used with experienced doctor.

Keywords: Filler; Under Eye; Dark Circles; Hyaluronic Acid; Cannula

Introduction

Under eye dark circles may occur genetically or structurally. This situation may depend upon pigmentation increase in the skin of under eyelid. It may occur slowdown of venous circulation around the eye because of insomnia, irregular lifestyle, alcohol, smoking. Also, atopic and some other eczemas lead deep dark circles under eye. Iron deficiency anemia, some eye diseases, sinus, some liver and kidney illnesses may be the reason of it [1].

The dermis layer of our skin is 0,3 - 0,4 mm thick, but the thickness of the skin under eye get thinner to 0,1 - 0,2 mm depending on external and internal factor. The thinner skin of under eyelid causes vessels to become more visible by becoming transparent. These vessels bring out blue-purple circles under eye.

Generally, depending on genetic and structural features or environmental conditions effects, also it may occur as a result of localised atrophic patches which caused by weight loss and increasing age. Even if the dark circles are closed with cosmetic concealers, patients may complain about hideless under eye hollows.

Periorbital is the most frequently-used area in contact in our social lives, especially bilateral relations. It reflects our tiredness and calmness. The changes in our frame with age, metabolism, environment and nutrition are seen in this area at the most. Eye and periorbital shows the age, health and mental state of a person clearly.

If it is caused by systematic distortion, these disorders should be treated at first. However, even if apparent illness can be fixed, generally the problem may not be solved because of chronic disturbance.

To treat the dark circles and hollows, cold application, mesotherapy, PRP, externally balm applications and filler practices (HA) are used [2].

I would like to talk about under eye filler practices. The reason of this article is to evaluate the under eye filler applications overall.

Material and Method

Under eye hyaluronic acid filler was applied to the patients who consult to the clinic with complaint of hollows and dark circles under eye between March 2014 and December 2016. Patients were followed averagely 1-32 month. Patients who had intensive skin pigmentation in their under eye were not attach to the study. Application age border was accepted 19. It was practiced while the patient lies with 60 degree angle since in this angle, under eye tissues are more visible. Firstly, under eye area was deodorized with antiseptic in a sterile way in all patients. After orbital margin was palpated, hyaluronic acid filler was injected over the periost with deep application. With the attempt of the needle, it was arrived to area with two or three separate entrance. In the usage of cannula, the filler was performed by applying only one skin entrance. Before every application, it was showed extra attention by withdrawing the injector in order to avoid intravascular treatment. Filler was slowly injected over the area with retrograde technique (Figure 1 and 2). After that, by massaging softly the area, it was provided the filler to spread. Patients were kept informed and control appointments for 15 days later were given. In the control, patients who need more filler were touched up. Patients evaluated according to sex, existence of comorbidities, the reason of complaint, the volume of filler application, need of add-on-therapy and satisfaction [3].

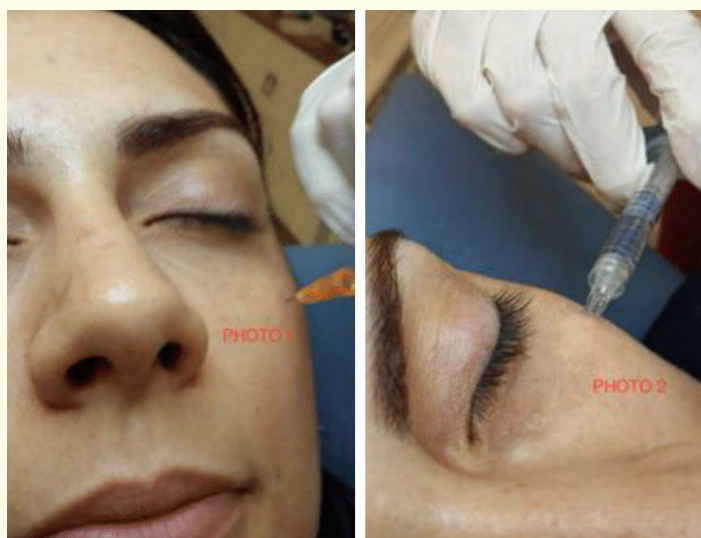

Figure 1 and 2: Application of Under Eye Filler with cannula.

Findings

There were 148 (83%) female and 30 (17%) male patients. Average age was 33 (age range 19 - 60). When it is asked additional

medicine usage, 28 patients (16%) mentioned their allergic frame and usage of anti-allergic medicine occasionally taken. Lidocaine and hyaluronic acid allergy were not encountered in any patient. 16 patients (9%) stated the usage of antidepressant. Patients particularly were not questioned about antidepressant usage. 4 patients had goiter history (Figure 3).

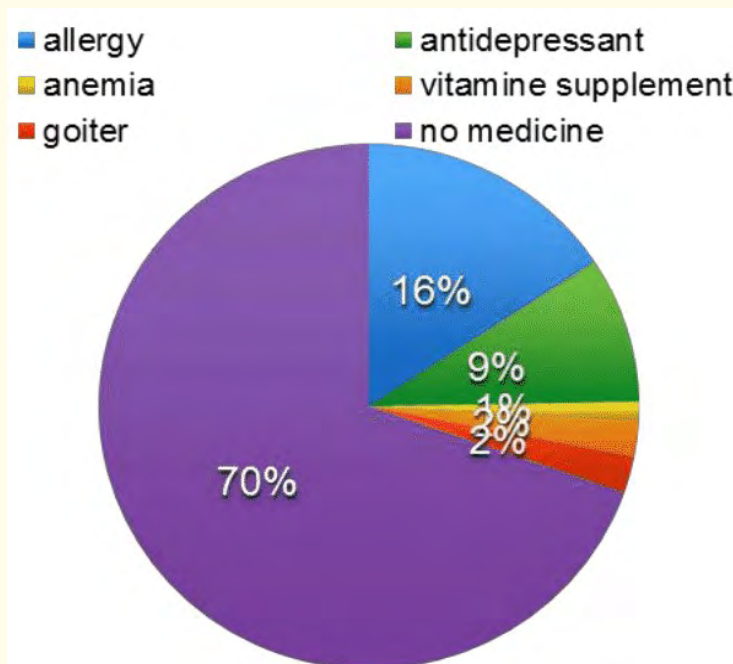


Figure 3: Additional medicine usage.

It was defined that the most frequently complaint was under eye hollowness with 84%. Second reason was dark circles with 74%. It is seen that in over 40 year old patients, the most common complaint was dark circles with 80% (Figure 4).

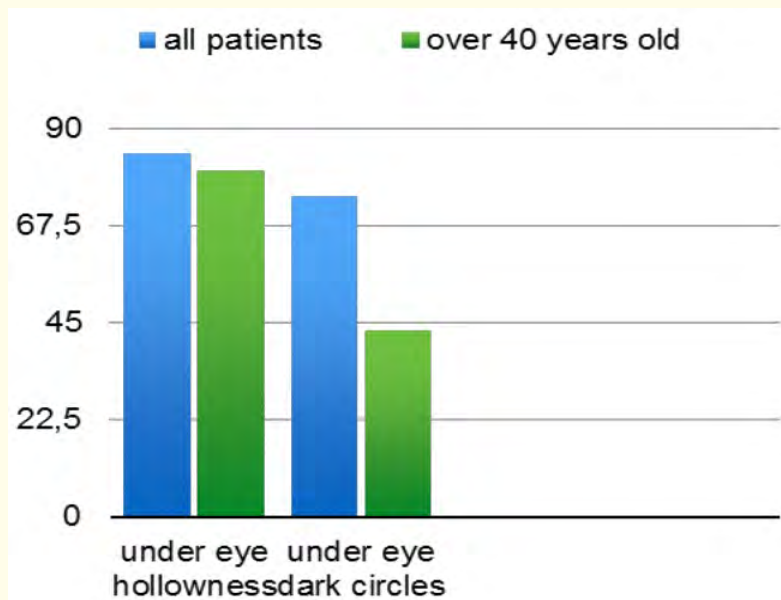


Figure 4: The comparison of patients' complaints according to age.

By examining their present situation, only under eye filler was applied to 85% patients. Additionally, cheek filler was applied to 12 patients (7%) since the present hollowness was extensive (Figure 5).

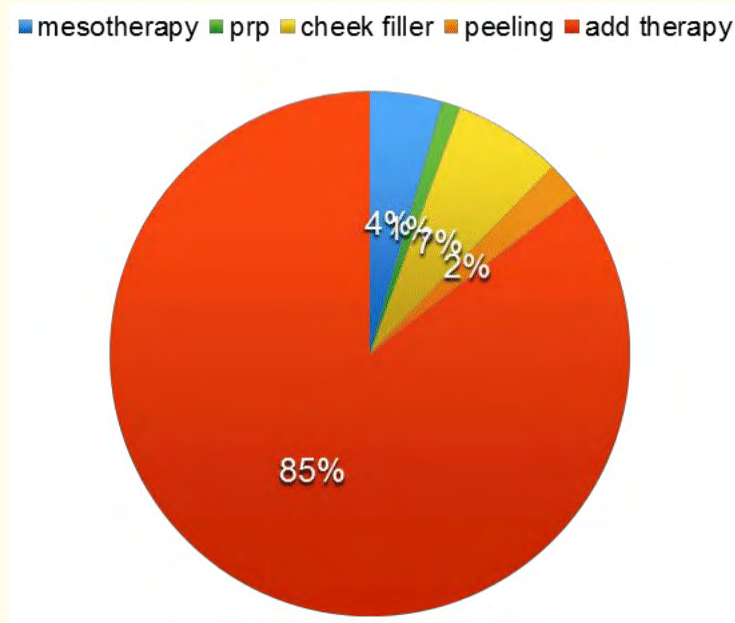


Figure 5: Additional treatments besides under eye filler application.

To treat the skin tissue in under eye area, mesotherapy was applied to 8 patients (4%).

Before application, local anaesthetic cream was applied to the patients. After waiting 20 minutes and deodorizing the application area, practice was performed. In the first application session, 0,67 ml was applied in average. After 15 days, patients who need more filler were touched up in control session. Totally, 0,83 ml practice was enough in all patients. It was observed that 0,82 ml filler was enough for women patients, whereas 0,85 ml was needed in men. The least application was 0,4 ml and the max one was 1,25 ml which was applied to a man patient (Figure 6).

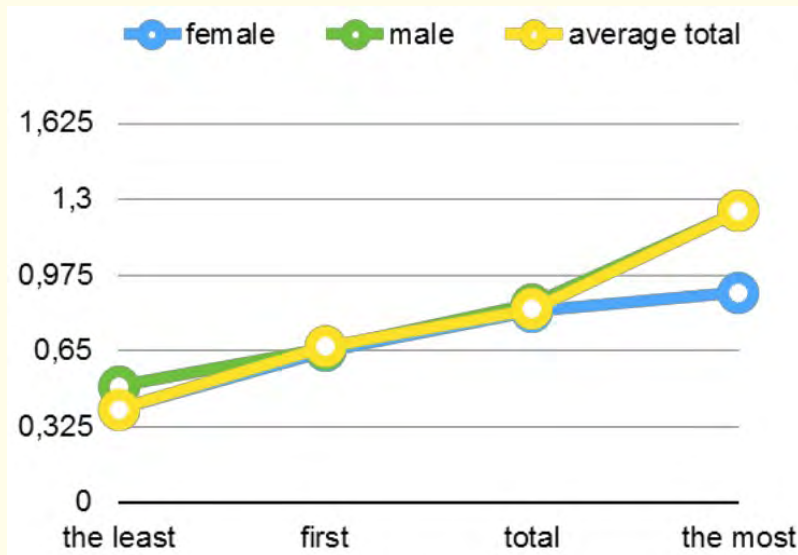


Figure 6: The doses of under eye application according to sexes.

Cannula technique was used 140 of 178 patients and injection was performed only to 38 patients (21%). As complication, bruise in application area was seen 14 patients. In the 10% patients with injection application, ecchymose occurred. Their ecchymoses showed more expansion. Ecchymoses which occur with cannula remain limited and regress in a jiff (Table 1).

	Person	Eye	Ecchymose	Ecchymose	ml
Injection	38	72	4	%76	0,76
Cannula	140	280	10	%98	0,85
Total	178	356	14	%93	0,83

Table 1: Comparison of injection and cannula technique.

In 8 patients (5%), edeme which lasts over 2 weeks was observed. After some time, it retreated. Hyaluronidase enzyme application was needed because of lingering swelling and edeme only to one patient. Emboli and transposition were not seen in any patient.

It was requested from patients to grade their satisfaction to the application as good, average and bad. 93% patients were satisfied with the result and graded it as good (Figure 7).

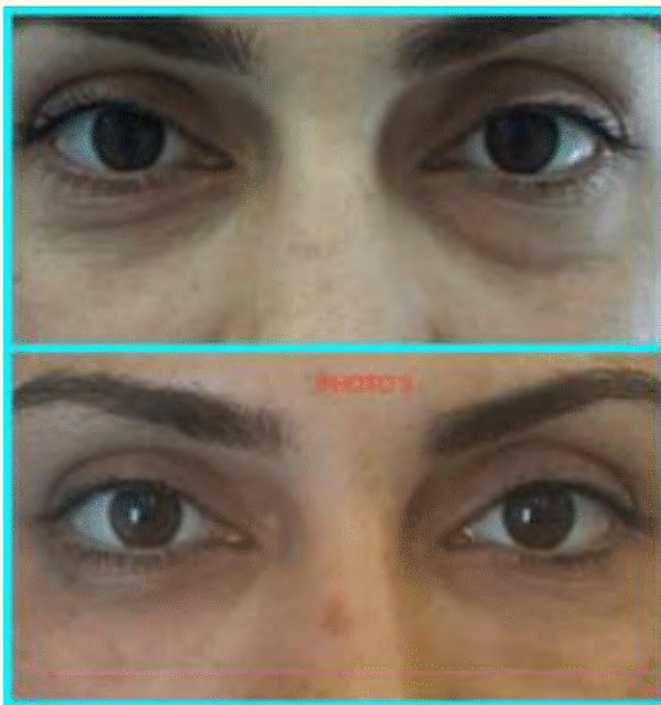

Figure 7: Upper side of the image shows pre-treatment. Lower side is post-treatment.

In the patient with injection application, satisfaction rate was 76%. In total, 4 patients was evaluated the application as bad. These patients were the ones that filler was applied with injection and developed ecchymoses (Figure 8).

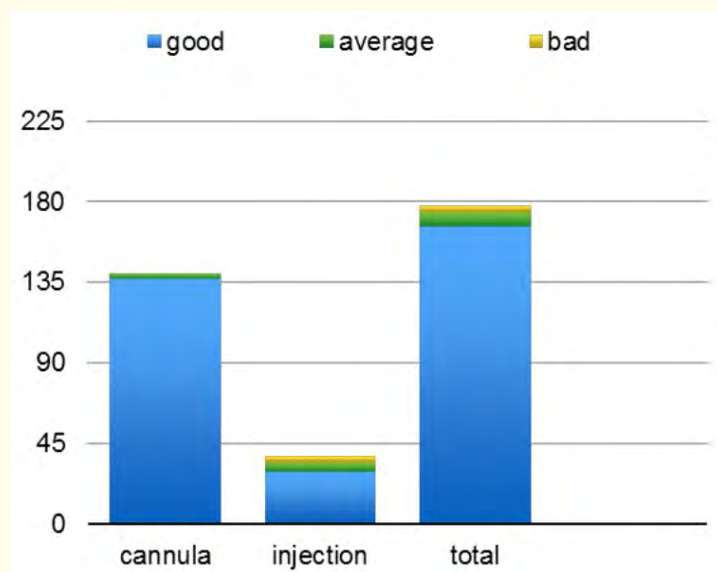


Figure 8: Satisfaction rate of patients.

Result

The procedure of hyaluronic acid filler is an alternative treatment in the patients who have dark circles and hollows under eye. The procedure with cannula technique is safer for the patient satisfaction and risks of application, but this technique should be used with experienced doctor [4,5]. When it is carried out with proper patient choice and accurate technique conclusions will be satisfactory for patient and doctor.

Discussion

Under eye hollowness and dark circles is a frequently encountered esthetics ailment. In the treatments of this disease, hyaluronic acid filler application is applied too often [6]. Hyaluronic acid is a polysaccharide that is found in human body and much more living being naturally. Fifty percent of hyaluronic acid created by the body occurs in epidermis. Hyaluronic acid is a half cross link filler. It consists of lots of amino acids and vitamin. It is the most favourite filler substance since it has homogeneous distribution, removal from the body entirely and few side effects. Hyaluronic acid in under eye is a type of filler which was developed for especially that area to reduce and remove the problems. Also, it shows many differences from normal fillers with its context. Beside having cross link and half cross-link context, this filler has 8 amino acids, 3 antioxidant, a zinc, a copper and vitamin B6 so it eases the application by providing skin reconstruction and anaesthesia to the area and it gives comfort to the patient. The area of the filler applied is the tear trough place.

Injection or cannula practices are common in this treatment [7]. Filler was injected over the periost. Ceptum should not be passed definitely. If it is passed, inferior oblique muscle dysfunction and many reactional problems can be observed [8,9-11]. The other important

issue is extensive arterio-venous anastomoses' in the area. There is a chance of emboli especially in angular vein embolisation, ophthalmic artery and central retinal artery. Bruising and swelling may rarely occur like can happen in every injection. These side effects can fade away in 3 or 5 days. Under eye filler lasts one or one and half year. Period can show an alteration according to the age, gender, living conditions and genetic factors of the patient. Reapplications help to increase the permanence of the filler. As soon as procedure is done, patient sees the result. However, the definitive effect is visible after 15 days. Complete procedure takes nearly 20 - 30 minutes. The filler is applied with a specially designed soft cannula of which is not spiked in order to keep the side effects minimum or thin pin injection. Patients can return their social life immediately after. As contraindications, in the case of patients having a known hypersensitivity to hyaluronic acid, a lidocaine allergy, an auto-immune disease, an infection or skin disease in injection area, and frequent infections or different fillers can be range.

Translated and Edited by Senay Saydir.

Bibliography

1. Vrcek I, *et al.* "Infraorbital Dark Circles: A Review of the Pathogenesis, Evaluation and Treatment". *Journal of Cutaneous and Aesthetic Surgery* 9.2 (2016): 65-72.
2. Friedmann DP and Goldman MP. "Dark circles: etiology and management options". *Clinics in Plastic Surgery* 42.1 (2015): 33-50.
3. Hill RH, *et al.* "Evolving Minimally Invasive Techniques for Tear Trough Enhancement". *Ophthalmic Plastic and Reconstructive Surgery* 31.4 (2015): 306-309.
4. Yang C., *et al.* "Tear trough and palpebromalar groove in young versus elderly adults: a sectional anatomy study". *Plastic and Reconstructive Surgery* 132.4 (2013): 796-808.
5. Hamman MS. "Comparison of two techniques using hyaluronic acid to correct the tear trough deformity". *Journal of Drugs in Dermatology* 11.12 (2012): e80-e84.
6. De Pasquale A and Russa G. "Hyaluronic acid filler injections for tear-trough deformity: injection technique and high-frequency ultrasound follow-up evaluation". *Aesthetic Plastic Surgery* 37.3 (2013): 587-591.
7. Sharad J. "Dermal Fillers for the Treatment of Tear Trough Deformity: A Review of Anatomy, Treatment Techniques, and their Outcomes". *Journal of Cutaneous and Aesthetic Surgery* 5.4 (2012): 229-238.
8. Kashkouli MB. "Diplopia after hyaluronic acid gel injection for correction of facial tear trough deformity". *Orbit* 31.5 (2012): 330-331.
9. Teo AA and Mokhtarzadeh A. "Late Presentation of Enlarging Lower Eyelid Mass and Muscle Degeneration Secondary to Hyaluronic Acid Filler". *Ophthalmic Plastic and Reconstructive Surgery* (2015).
10. Stutman RL and Codner MA. "Tear trough deformity: review of anatomy and treatment options". *Aesthetic Surgery Journal* 32.4 (2012): 426-440.
11. Viana GA and Osaki MH. "Treatment of tear trough deformity with hyaluronic acid gel filler". *Arquivos Brasileiros de Oftalmologia* 74.1 (2011): 44-47.

Volume 6 Issue 5 May 2017

© All rights reserved by Seyda Atabay.