

## Sunalp YAG Laser Lens, A Novel Method for Marking the Axis of Astigmatism Before Cataract Surgery and Toric Lens Implantation

Nino Sorgente, PhD., Myhidin Shehu, MD, MBA., Dana Sunalp, MBA and Murad A Sunalp, MD, MBA, FACS\*

*Sunalp Laser Vision, Tulare, California, United States*

\*Corresponding Author: Murad A Sunalp, MD, MBA, FACS., Sunalp Laser Vision, Tulare, California, United States.

Received: March 08, 2017; Published: March 31, 2017

### Abstract

**Purpose:** Comparison of astigmatic correction and visual acuity outcomes in patients implanted with toric intraocular lenses following cataract surgery reference marked pre-operatively manually with a pen or with YAG laser, in conjunction with the Sunalp YAG Laser Lens.

**Methods:** 16 eyes from 16 patients were divided into two groups of 8 patients each. Pre-operatively, the eye of one group was reference marked manually with a pen and the eyes of the second group were marked by generating a "disruption" spot on the cornea with YAG laser, in conjunction with the Sunalp YAG Laser Lens. All surgeries were performed by the same surgeon. Visual acuity and astigmatism were compared before and after surgery.

**Results:** Statistically there was no significant difference between the two groups before or after surgery and lens implantation. However, the data for astigmatism shows a better correction approaching statistical significance. A study with a larger cohort of patients would likely show a statistical superior outcome for astigmatic correction using the Yag laser marking method.

**Conclusion:** YAG laser marking of the cornea with the Sunalp YAG Laser Lens, provides superior results of toric lens placement and astigmatic correction.

**Keywords:** YAG Laser; Astigmatism; Cataract Surgery; Toric Lens Implantation

### Introduction

In Austria, a recent survey of 6900 eyes, showed that 75% of patients scheduled for cataract surgery had greater than 0.5 diopter (D) of astigmatism, 38.3 % had greater than 1 D and 39.1 % had astigmatism of 1.5 D or greater [1]. In the United States, it has been estimated that approximately 50% of the population aged over 60 years has  $\leq 1.00$ D of astigmatism [2]. Since a cylindrical defect of about 0.50 diopter (D) to 1.00D may be considered clinically significant, and may influence visual acuity it is important that it be treated.

The efficacy and safety of toric IOL implantation for correcting pre-existing corneal astigmatism in patients undergoing cataract surgery has been demonstrated in several studies. In patients with cataract and corneal astigmatism, bilateral toric IOL implantation compared to non-toric IOL results in greater spectacle independence, better uncorrected distance visual acuity with no significant difference in contrast sensitivity, and lower amounts of residual astigmatism than non-toric IOLs. Even low-power toric IOL used for correction of less than 1.25 D of corneal cylinder provide consistent, accurate refractive and astigmatic correction [3-5].

Alignment of the toric IOL on the steep corneal axis is critical to achieve optimal visual acuity. Pre-surgical accurate reference eye marking is essential for precise alignment of toric IOL. Reference eye marking is necessary to allow for the change in the orientation of the eye from the sitting to the horizontal position (cyclorotation) of the patient during lens implantation. Since cyclorotation averages 3 degrees and since for each degree of cyclorotation the patient loses 3.3% of astigmatism correction, the average loss in astigmatism correction would be about 10%; however, in the considerable number of patients in which cyclorotation is 5% or greater [6] misalignment of the lens would have a significant negative effect on astigmatism correction.

Four procedures are commonly used to mark the axis of astigmatism to align the toric IOL correctly. The oldest, the least expensive, but the also the least accurate uses ink to preoperatively mark the axis of astigmatism at 0°, 90 and 180° meridians. However, the ink marking procedure is problematic because it is subject to a number of sources of error, including the wide ink mark is wide, ink diffusion and even ink disappearance.

Another method of marking the axis of astigmatism uses cautery to leave a mark. A small probe has been devised and marketed (Wet-Field® Osher ThermoDot™ Marker) specifically for the purpose of marking the meridian of the eye. Using a cautery mark can be accurate, but requires the special equipment and the cautery may cause pain.

A digital method for marking the eye pre-operatively captures a high resolution image of the eye. A computer with special software detects scleral vessel, iris, pupil and limbus features, measures keratometry and pupillometry and other necessary parameters, and superimposes the image to the patient's eye image with a tracking overlay so that pre-operative features are paired to the patient's eye, thus enabling the surgeon to see markings in real time. This procedure eliminates the need for manual marking, automatically accounts for cyclorotation, and assists in the precise centering and alignment of the toric IOL. This method is accurate and simple but it requires specialized equipment (e.g., Verion Guidance System by Alcon), which is not available to most ophthalmologists. In fact, over 80% of ophthalmologists use manual marking for toric IOL alignment [7].

Intraoperative wavefront aberrometry is the most accurate means of achieving near-perfect vision after cataract surgery. This technology allows on-demand measurements of lens power, sphere, cylinder and axis allowing the surgeon at any time during the procedure to assess the quality of vision, to evaluate refractive findings, refine IOL power, cylinder power, and IOL alignment in real time. In addition, wavefront aberrometry accounts for both anterior and posterior corneal astigmatism and reduces incidence of unintended residual post-op astigmatism. Studies using the ORA aberrometer (Alcon Laboratories) have shown that the number of patients who fall outside the intended astigmatic target by are reduced by 54% compared to preoperative calculation of cylinder power and axis [8]. Aberrometers are precise, simple and offer results superior to other methods of marking the eye; however, the instrumentation required is not available to the majority of ophthalmologists, especially those in a small practice.

Here we report on a novel procedure for pre-operatively accurate reference eye marking that is available to all ophthalmologists at minimal cost using the Yag laser. In addition, the Yag laser could be used for reference marking in patients in remote areas served by visiting ophthalmologists, since in these areas the Yag laser already serves as a slit lamp and for capsulotomies [9].

### Material and Methods

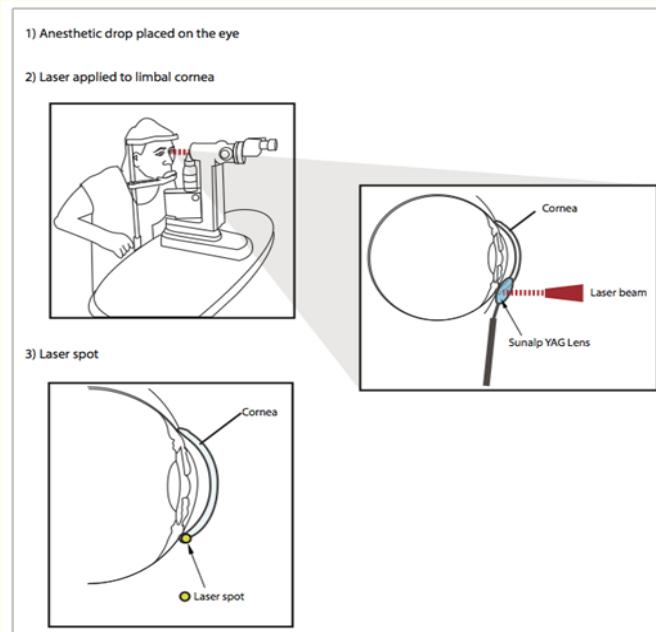
**Patients:** The study included 16 eyes of 16 patients (males = x; females = X) scheduled for cataract surgery and toric lens implantation. Patients were divided into 2 groups of 8 eyes each; the eyes in the first group were reference marked with a pen manually and the second group were marked with the YAG laser.

All patients underwent a complete initial ophthalmic examination one week before surgery, and post-operative at 1 day, 1 week, 1 month, 3 months and one year after surgery. Patients were excluded if at initial ophthalmic examination were found to have active intraocular inflammation, glaucoma, wet age-related macular degeneration, intraocular surgery or intravitreal drug injections within the previous 6 months.

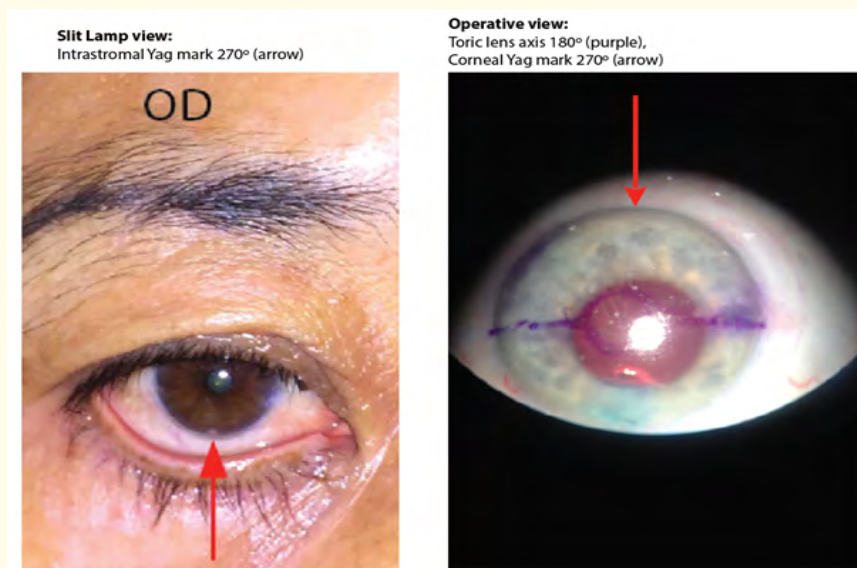
**Reference Eye Marking:** For manual marking with a pen, Medline STD tip was used to mark at the limbus at 0°, 180° 270°, while the patient was fixating with this eye at a distance target, after a local anesthetic drop on the eye (proparacaine hydrochloride ophthalmic solution 0.5% Akorn).

For marking with the YAG laser, a drop of local anesthetic (proparacaine hydrochloride ophthalmic solution 0.5% Akorn) is placed on the eye, and the patient is asked to place the chin on the chin-rest of the Yag laser. The "Sunalp Yag laser lens", manufactured by Volk (Mentor, OH, USA), with a drop of Goniovisc (Hypromellose Ophthalmic solution USP 2.5%) is placed on the concave corneal end (Figure

1) on the cornea with 90° lens at 90° patient cornea; with the level integrated in the lens, the Yag laser is focused at the mid cornea at 270° paralimbal and with the laser preset at 0 microns, a single laser pulse of 5 mjoules is aimed at 270° with 1 to 3 pulses in line 0.5 mm apart. If necessary, the laser pulses can be aimed at toric IOL axis 180° apart. The laser pulse marks the cornea with a small disruption and blanching of the stroma that remains visible for 48 hours or longer (Figure 2). The long-lasting mark produced by the YAG laser is important for those rare cases in which revisional surgery for lens re-alignment becomes necessary during the few days following lens implantation. The YAG laser lens (patent pending) is a 1 cm, 12 diopters acrylic lens.



**Figure 1:** The sunalp Yag laser lens procedure.



**Surgery:** All cataract surgeries were performed under topical and peribulbar anesthesia by the same surgeon. A clear corneal incision was made using a 2.40 mm metal keratome (Beaver, double bevel slit ) at 90° incision technique. The anterior chamber was filled with an ophthalmic viscoelastic device (Helon GV) and a 1.5 mm side incision was made with a 20 G MVR sideport blade at 45°. A 6-mm diameter continuous curvilinear capsulorhexis (CCC) was completed with a cystatome and Utrata forceps. After phacoemulsification of the nucleus and epinucleus and aspiration of cortical material the anterior chamber was refilled with the same viscoelastic device and the toric lens axis was marked on the cornea with a corneal marker and a 360° template. The foldable hydrophilic toric lens (Alcon IQ toric intraocular lens) was injected into the capsular bag, using D cartridge and oriented with a Sinsky hook along the corneal astigmatic axis using the Alcon Toric Calculator results.

As routine, viscoelastic was removed including behind the IOL, after Intravitreal (Impriss) 0.2 cc Tri-Moxi-Vanco antibiotic steroid injection, making sure no axis shift has occurred.

Miostat placed in the AC, wound hydrated with BSS, Sunalp Cautery technique and Resure sealant was also used. Wound was checked for leakage before patching the eye, 3 hours. Postoperatively patients were treated with NSAID daily drops (Ilevro, nepafenac ophthalmic suspension, 0.3%).

A student t test was used to compare significance between groups. A p value below 0.05 was regarded as statistically significant.

**Results**

This study included 16 eyes from 16 patients. As shown in Table 1 uncorrected visual acuity and astigmatism prior to cataract extraction was not statistically different between the two groups. After cataract extraction and toric lens implantation no statistical difference between the two groups was observed (Table 2); statistically uncorrected visual acuity is essentially the same between the two groups (p = 0.6575); however, it is evident from Table 2 that even though not statistically different (p = 0.1023) astigmatism correction was better in the group marked with the Yag laser than in the group marked with the pen. Note also that after toric lens implantation astigmatism variation among patients is much less in patients marked with the Yag laser (average 0.59 ± 0.35) than with the pen (average 1.19 ± 0.88) even though pre-operatively there was only a small between the two groups (average: 1.78 ± 1.41 vs. 2.56 ± 2.07) suggesting more accurate reference marking.

Reference Marking Method Visual Acuity				Reference Marking Method Astigmatism			
	Pen		YAG		Pen		YAG
Patient		Patient		Patient		Patient	
1	20/200	1	20/40	1	+3.00	1	+5.00
2	20/100	2	20/50	2	+1.50	2	+1.50
3	20/100	3	20/60	3	+4.25	3	+1.25
4	20/200	4	20/60	4	+0.50	4	+1.25
5	20/200	5	20/60	5	+0.25	5	+1.25
6	20/80	6	20/200	6	+1.25	6	+0.25
7	20/150	7	20/80	7	+6.25	7	+2.25
8	20/200	8	20/60	8	+3.50	8	+1.50
Mean	153.75 ± 53.17	Mean	76.25 ± 51.25	Mean	2.56 ± 2.07	Mean	1.78 ± 1.41
P=0.0102				P=0.3925			

**Table 1:** Pre-operative visual acuity and astigmatism of 6 patients manually marked with a pen and 6 patients marked with the YAG laser.

	Reference Marking Method Uncorrected Visual Acuity			Reference Marking Method Astigmatism			
	Pen		YAG		Pen		YAG
Patient		Patient		Patient		Patient	
1	20/30	1	20/20	1	+1.50	1	+1.00
2	20/20	2	20/20	2	+0.50	2	+0.75
3	20/20	3	20/20	3	0.00	3	+0.75
4	20/30	4	20/20	4	+1.50	4	+0.50
5	20/20	5	20/25	5	+2.00	5	0.00
6	20/20	6	20/20	6	0.00	6	+0.25
7	20/20	**7	20/50	7	+2.00	7	+0.50
*8	20/80	8	20/30	8	+2.00	8	+1.00
Mean	30.00 ± 20.70	Mean	25.63 ± 10.50	Mean	1.19 ± 0.88	Mean	0.59 ± 0.35
P=0.6023				P=0.0993			

**Table 2:** Visual acuity and astigmatism of the 6 patients manually marked with a pen and the 6 patients marked with the YAG laser after cataract surgery and toric lens implantation.

\*Eye later treated with PRK to further correct post-op visual acuity

\*\*Maximum visual acuity achievable due to Dry Macular Degeneration

## Discussion

Uncorrected astigmatism is a significant obstacle to good vision not only because it causes blurred vision, ocular discomfort and image distortion but also because it may engender headaches, squinting and difficulty with night vision, a problem that is exacerbated with advancing age. Numerous investigations have reported the prevalence of astigmatism at different ages in various populations. A study in a clinic in Austria has reported that in a survey of patients admitted to the clinic for cataract surgery 38.3% or 2641 eyes had an astigmatism greater than 1D [1]. A study in India showed that over 40 % of the Indian patients undergoing cataract surgery have more than 1.0 D of corneal astigmatism [10] and a Chinese study found that in the general population 39.25% of subjects had CA values greater than 2 D [11].

Previously astigmatism was managed with glasses or contact lenses, more recently refractive surgery has become the norm for correction of astigmatism and in the last few years the implantation of multifocal toric lenses has gained acceptance and published data have shown good outcomes [4,5,12-14]. Visual outcomes after toric lens implantation is highly dependent on the positioning of the lens, whereby the lens axis should be aligned as closely as possible with the axis of steep curvature of the cornea. Because of cyclorotation of the eye when the patient is supine it is critical to have a point of reference on the eye. Accurate reference eye marking can be done using specialized and very costly equipment; however, such equipment is not available to most ophthalmologists use manual marking of the eye [7] usually with a specialized pen. Marking with a pen has a number of shortcomings including fading and spreading of the ink. Here we have described a procedure to mark the eye with a Yag laser, which is available to every ophthalmic surgeon. There are several advantages of marking with the Yag laser, specifically the mark will not fade or spread, it is simple, it is safe, it is painless, and it lasts several days in case it becomes necessary to have to explant and re-implant the lens. The only requirement is a lens, which can be acquired at a reasonable cost and which will serve for many years. The result of this study does not show a statistically significant difference in outcomes; however, astigmatic correction is better and approaches statistical significance, which a study with a larger cohort would be necessary to show.

### **Financial Interest**

Murad Sunalp has a financial interest in the Yag Laser Lens.

### **Bibliography**

1. Michelitsch M., *et al.* "Prevalence and age-related changes of corneal astigmatism in patients before cataract surgery". *Ophthalmology* 114.3 (2016): 247-251.
2. Vitale S., *et al.* "Prevalence of refractive error in the United States, 1999–2004". *Archives of Ophthalmology* 126.8 (2008): 1111-1119.
3. Levitz L., *et al.* "Evaluation of Toric Intraocular Lenses in Patients with Low Degrees of Astigmatism". *Asia-Pacific Journal of Ophthalmology* 4.5 (2015): 245-249.
4. Visser N., *et al.* "Toric vs aspherical control intraocular lenses in patients with cataract and corneal astigmatism: a randomized clinical trial". *JAMA Ophthalmology* 132.12 (2014): 1462-1468.
5. Kessel L., *et al.* "Toric Intraocular Lenses in the Correction of Astigmatism During Cataract Surgery: A Systematic Review and Meta-analysis". *Ophthalmology* 123.2 (2016): 275-286.
6. Fea AM., *et al.* "Cyclotorsional eye movements during a simulated PRK procedure". *Eye* 20.7 (2006): 764-768.
7. American Society of Cataract and Refractive Surgery. Clinical Survey (2015).
8. Ianchulev T., *et al.* "Intraoperative refractive biometry for predicting intraocular lens power calculation after prior myopic refractive surgery". *Ophthalmology* 121.1 (2014): 57-60.
9. Kirthi Kumar Naidu., *et al.* "Atauro Eye Study: Outreach Cataract Surgery Outcomes in East Timor". *Asia-Pacific Journal of Ophthalmology* (Phila).
10. Prasher P and Sandhu JS. "Prevalence of corneal astigmatism before cataract surgery in Indian population". *International Ophthalmology* (2016).
11. Lin D., *et al.* "Prevalence of Corneal Astigmatism and Anterior Segmental Biometry Characteristics Before Surgery in Chinese Congenital Cataract Patients". *Scientific Reports* 6 (2016): 22092.
12. Hashemi H., *et al.* "Evaluation of the Results of Using Toric IOL in the Cataract Surgery of Keratoconus Patients". *Eye Contact Lens* 41.6 (2015): 354-358.
13. Lockington D., *et al.* "Effectiveness of cataract phacoemulsification with toric intraocular lenses in addressing astigmatism after keratoplasty". *Journal of Cataract and Refractive Surgery* 40.12 (2014): 2044-2049.
14. Debois A., *et al.* "Refractive precision and objective quality of vision after toric lens implantation in cataract surgery". *Journal Francais D'Ophthalmologie* 35.8 (2012): 580-586.

### **Volume 6 Issue 1 March 2017**

© All rights reserved by Murad A Sunalp, MD, MBA, FACS., *et al.*