

## Congenital abnormality of bilateral inferior rectus muscle with congenital vertical torsional nystagmus with DVD: A Case report

Feng Xueliang<sup>1\*</sup>, Yading JIA<sup>1</sup>, Xinxin ZHANG<sup>1</sup> and Nan JIA<sup>1</sup>

<sup>1</sup>Department of Ophthalmology, Shanxi Medical University, China

\*Corresponding Author: Feng Xueliang, Department of Ophthalmology, Shanxi Medical University Shanxi Eye Hospital 100 Fudong Street Taiyuan, China.

Received: September 14, 2015; Published: October 02, 2015

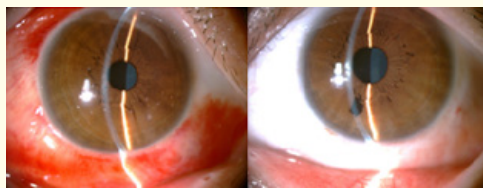
### Abstract

Unilateral or bilateral absence of the inferior rectus muscles is uncommon but not rare. Whereas congenital abnormality of bilateral inferior rectus muscles with congenital vertical torsional nystagmus with DVD is a rare condition. We will present an interesting case of congenital bilateral inferior rectus hypoplasia with vertical torsional nystagmus. It is a case of 26 years old female, with absence of the inferior rectus muscle in the right eye, while thin and narrow inferior rectus muscle was seen in the left eye. A unilateral inferior oblique muscle anterior transposition was performed to correct hypertropia in primary position in the right eye.

**Keywords:** *Inferior rectus; DVD; Nystagmus; Absence; Transposition*

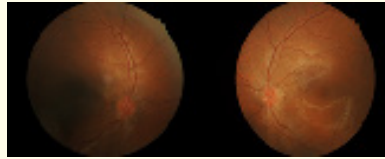
### Case Report

A 26-year-old female presented to our clinic in 2014 with right hypertropia in the primary position. Best-corrected visual acuity was 0.15 × + 1.25 DS/-2.50 DC × 45° in the right eye, 0.5 × -0.75 DS/+1.75 DC × 60° in the left eye. A pigmented nevus was found in the left eye (Figure 1). Fundi were intorsional (Figure 2). When the left eye fixated, it showed RHT30PD. Krimsky reflex showed RHT15°. Dissociated vertical deviation (DVD) was also found in her right eye. She had a chin down posture (Figure 3). Ocular versions are shown in (Figure 4). There is a down gaze limitation in both eyes in the fields of bilateral inferior rectus. It is more severe in the right eye than in the left eye (as shown). The nystagmus with upbeat and extorsion appeared in the right eye and nystagmus with intorsion could be seen in the left eye. She had 200 seconds of arc of stereopsis examined by Titmus.



Right eye (after surgery)      Left eye

**Figure 1:** A pigmented nevus was found in left eye.



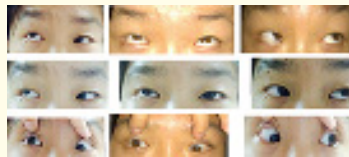Right eye

Left eye

**Figure 2:** Fundus photograph preoperation: bilateral intorsion.



**Figure 3:** Chin down head posture (Preoperation).



**Figure 4:** Ocular versions showed that RHT in primary gaze. Elevation of right eye was seen in abduction of right eye and elevation of left eye in abduction of left eye. (Preoperation).

Her parents denied swelling or bleeding in the orbits at birth. She had no family history of eye disease. No dental or facial anomalies were noted. Because of financial problem, she didn't have a CT scan or MRI. We diagnosed inferior rectus muscle palsy or aplasia bilateral preoperation? Or vertical Duane's syndrome.

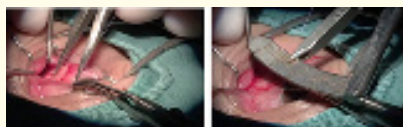On topical anesthesia, a forced duction test showed that the superior rectus is not very tight. Surgical exploration of the right eye revealed absence of inferior rectus completely. The medial rectus was normal. The left eye was then explored also. The width of inferior rectus in the insertion was 1/3 width of normal in the left eye. The patient's main complaint is hypertropia in the right eye. So inferior oblique muscle was transposed anteriorly and fixed on the sclera where the temporal insertion of inferior rectus should be, about 6 mm inferior from limbus. Follow-up at post-operation of two weeks and two months.

## Results

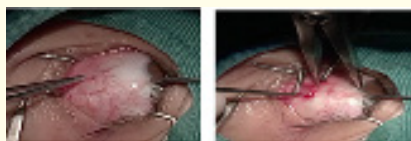
1. Vision: Vision of the right eye is the same as pre-operation. But the patient said she see clearer than before.
2. Hypertropia: 10PD RHT
3. Versions: There is still limitation in the field of inferior rectus. It looks a little better.
4. Nystagmus The patient felt much better.

**Discussion**

Congenital absence of the inferior rectus muscle could combine with an absence of other extraocular muscles [1]. Embryologically, the inferior rectus and inferior oblique muscles and inferior portions of the lateral rectus muscles originate from inferior mesodermal complex, whereas the superior muscle develops from a superior mesodermal complex at an early stage. Any factors that affect the development of the mesodermal complex might lead to abnormalities of extraocular muscle [2]. They included absence and hypoplasia. In this case, the patient with right hypertropia due to unilateral absence of the inferior rectus muscle and the hypoplasia of the inferior rectus muscle in the left eye (Figure 5,6). This was found during surgery. She was misdiagnosed as inferior paresis in both eyes. Obviously, CT, Magnetic resonance imaging (MRI) of orbits can assist in the diagnosis [3]. Previous study reported that an accessory muscle which may be an atavistic extraocular muscle appeared to cause paradoxical constriction in their cases [4,5]. Bhatte., *et al.* found that unilateral inferior rectus muscle hypoplasia was accompanied by Axenfeld-Rieger syndrome [6]. But in this case we did not find any signs related to Axenfeld-Rieger syndrome.



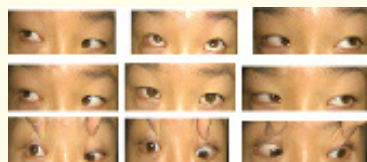**Figure 5:** Absence of inferior rectus muscles in right eye.



**Figure 6:** The Hypoplastic inferior rectus muscle in left eye.

Faeeqah Almahmoudi [7]. Reported a case is similar as our case. His case is aplasia of bilateral inferior rectus with hypertropia in the left eye. Torsional and upbeat nystagmus could be seen. Inferior scleral exposure may be related to the abnormal connection between lower lid and inferior rectus as Faeeqah said. This is one of causes. It may also be due to down gaze limitation of inferior rectus. The chin down posture of our case could confirm it.

Superior rectus recession, medial-lateral rectus infra-transposition [8]. And inferior oblique muscle anterior transposition [7]. Are the most common surgical procedures in patients with inferior rectus muscle palsy or aplasia? We performed the procedure of inferior oblique muscle transposition anteriorly in this case to correct her hypertropia in the right eye. It corrected hypertropia 20PD (Figure 7).



**Figure 7:** Ocular versions after operation of two weeks.

To our surprise, when the patient visited us one week after surgery she felt her vision and nystagmus much better than before. She said “visual acuity was not improved after surgery, but I felt I see clearly”. It seems that the Foveal Recognition Time (FRT) is shorter than before?

We did not say a word about her vision and nystagmus before operation. Nystagmus is defined as an involuntary rhythmic oscillation of the eyes, which leads to reduced visual acuity due to the excessive motion of images on the retina [9]. Although horizontal nystagmus is very common, vertical with torsional nystagmus (seesaw nystagmus, SSN) can also be seen in a few patients. SSN refers to an uncommon form of nystagmus with elevation and intorsion of one eye simultaneous with depression and extorsion of the other eye which is often accompanied by progressive severe vision problems, including blurriness [10]. The most common cause of SSN is septo-optic dysplasia and parasellar lesions such as pituitary tumors [2].

This case highlights the importance of imaging, forced duction testing, and surgical exploration in order to prevent misdiagnosis. Inferior oblique muscle anterior transposition can partially corrected hypertropia due to inferior rectus muscle aplasia. If it can take effect in nystagmus should be studied more comprehensively. Because inferior rectus muscle hypoplasia can present as vertical torsional nystagmus, patients with this finding should undergo a comprehensive work up prior to an attempt at surgical correction.

### **Bibliography**

1. Pei-Yu Lin and May-Yung Yen. “Congenital absence of bilateral inferior rectus muscles: a case report”. *Journal of pediatric ophthalmology and strabismus* 34.6 (1997): 382-384.
2. SB Ozkan., *et al.* “Hypoplastic inferior rectus muscle in association with accessory extraocular muscle and globe retraction”. *Journal of AAPOS* 11.5 (2007): 488-490.
3. Michelle Munoz. “Congenital absence of the inferior rectus muscles”. *American Journal of ophthalmology* 121.3 (1996): 327-329.
4. F Man., *et al.* “Unilateral vertical syndrome with orbital band”. *Journal of AAPOS* 13.4 (2009): 419-421.
5. SB Ozkan., *et al.* “Hypoplastic inferior rectus muscle in association with accessory extraocular muscle and globe retraction”. *Journal of AAPOS* 11.5 (2007): 488-490.
6. M Bhate., *et al.* “Unilateral inferior rectus hypoplasia in a child with Axenfeld-Rieger syndrome”. *Journal of AAPOS* 16.3 (2012): 304-306.
7. F Almahmoudi and Arif O Khan. “Inferior oblique anterior transposition for the unilateral hypertropia associated with bilateral inferior rectus muscle aplasia”. *Journal of AAPOS* 18.3 (2014): 301-303.
8. Astle WF., *et al.* “Congenital absence of the inferior rectus muscle diagnosis and management”. *Journal of AAPOS* 7.5 (2003): 339-344.
9. May EF and Truxal AR. “Loss of vision alone may result in seesaw nystagmus”. *Journal of Neuro Ophthalmology* 17.2 (1997): 84-85.
10. Mark L and Moster. “Nystagmus”. *Ophthalmology clinics of North America* 14.1 (2001): 205-215.

**Volume 2 Issue 3 September 2015**

**© All rights are reserved by Feng Xueliang., et al.**