

## **A Case Report on The Use Of MRI as an Important Diagnostic Tool for Posterior Scleritis**

**Ortega-Molina José María<sup>1\*</sup>, Solans Perez- de Larraya Ana<sup>1</sup>, Salgado-Miranda Andrés<sup>1</sup>, Ortego-Centeno Norberto<sup>2</sup> and García-Serrano José Luis<sup>1</sup>**

<sup>1</sup>Department of Ophthalmology, Hospital Universitario San Cecilio, Spain

<sup>2</sup>Department of Internal Medicine, Hospital Universitario San Cecilio, Spain

**\*Corresponding Author:** Ortega-Molina José María, Department of Ophthalmology, Hospital Universitario San Cecilio, Av Dr. Oloriz 16, Granada, 18012, Spain.

**Received:** August 29, 2015; **Published:** September 08, 2015

### **Abstract**

We report a case of a 15 year old woman patient who was presented with a history of ocular pain and headache since three months. The anterior segment examination was within normal limits. Funduscopy revealed bilateral papillitis and folds in inner retina. The results of B-scan ultrasonography (BSU) and Computed Tomography (CT) were unspecific. The patient received empirical treatment with systemic steroids, with the remission of the symptoms. Four months later, the patient presented again with similar symptoms. An orbital magnetic resonance imaging (MRI) was suggested. MRI showed enhancement of the sclera and optic nerve inflammation, providing the diagnosis for posterior scleritis. Posterior scleritis is often a misdiagnosed disease; it is a potential cause of blindness due to its associate complications. MRI is an important adjuvant tool for posterior scleritis diagnosis in cases where symptoms and BSU did not confirm the diagnosis.

**Keywords:** *Posterior Scleritis; MRI; Ocular inflammation*

### **Introduction**

Posterior scleritis is defined as an inflammation of the sclera posterior to the ora serrata. It represents 2-12% of all cases of scleritis, although its incidence can be higher, because it is believed that it can go undetected in cases where there is an involvement of the anterior pole. It can be uni or bilateral and is more common in middle-aged women. Posterior scleritis is isolated, but sometimes is associated with anterior scleritis and episcleritis. It can be classified as nodular or diffuse [1,2].

Twenty to thirty percent of the cases of posterior scleritis are associated with a systemic disease especially with rheumatoid arthritis and granulomatosis with polyangitis. More than a half of the cases are idiopathic. Posterior scleritis is also associated with infectious diseases and tumors [3].

Diagnosis is usually based on clinical manifestations which include severe visual lost, ocular pain, papilledema and/or posterior uveitis. BSU is not always an accurate diagnostic tool. In such cases, MRI can be decisive for clarifying the diagnosis of posterior scleritis [4-6].

The main purpose of this report is to highlight the usefulness of MRI as a complementary diagnostic test in cases where posterior scleritis is suspected and BSU is not conclusive.

### **Clinical Case**

A 26 year old woman with a *previous* diagnosis at her origin country of bilateral idiopathic orbital inflammatory disease, was admitted to the hospital after three months of intermittent eye pain and headache. The ophthalmological examination revealed a best corrected

visual acuity (BCVA) of 1 in both eyes (OU), the slit lamp examination was normal and the IOP was 14.00 mmHg in OU. The posterior pole examination revealed a bilateral papillitis and folds in inner retina in right eye (OD). (Figure 1a, 1b).

The BSU and CT were normal and in laboratory analysis *rheumatoid* factor and anti-neutrophilic cytoplasmic antibodies (ANCA) were negative. Further more, the diagnose of listeria, hepatitis, sífilis, human immunodeficiency virus, Citomegalovirus, mycoplasma, varicela virus, herpes simplex virus, brucellosis, bartonella, toxoplasma, Epstein-Barr virus, mediterranean spotted fever were ruled out through *serological testing*.

The patient was initially treated with systemic steroids therapy (prednisone 40 mg with slow tapering) with complete remission of the symptoms after a month.

Four months later the patient presented again with similar symptoms and a *neurosensory retinal detachment of the macula* adjacent of the optic nerve in the OD (figure 2a, 2b). MRI was performed and showed scleral thickening, optic nerve inflammation consistent with the diagnosis of posterior scleritis (figure 3). She was treated with systemic immunosuppressants (methotrexate 10 mg) and corticosteroids (prednisone 40 mg). The treatment was slowly tapered off with a total duration of 3 months with good response and no new recurrences.

## Discussion

Posterior scleritis is an under diagnosed disease because of the location and its nonspecific clinical symptoms and signs associated. It can be mistaken for other diseases such as idiopathic optic neuritis, choroidal metastases, choroidal lymphoma, orbital tuberculosis and idiopathic orbital inflammatory disease.

Diagnosis is based on clinical manifestation in addition to indirect signs observed on the BSU, such as the *T-sign*, which reveal the presence of fluid in the subtenon space. However it is only present on 25% of cases of posterior scleritis. Also the ultrasound findings do not correlate with clinical response to treatment and could persist after clinical resolution [3,4,7].

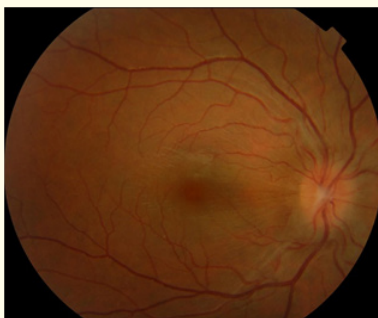
In our case, the patient was first diagnosed of idiopathic optic neuritis, but based on the results of the MRI, the diagnosis of posterior scleritis was made.

There are several reported cases which highlights the diagnostic value for MRI in posterior scleritis [4-6,8], it is mentioned that the gadolinium MRI and the fat suppression technique show the presence of scleral thickening and enhancement of the posterior sclera and optic nerve. MRI is also useful as a marker of activity and response to treatment in posterior scleritis, which cannot be measured with the BSU.

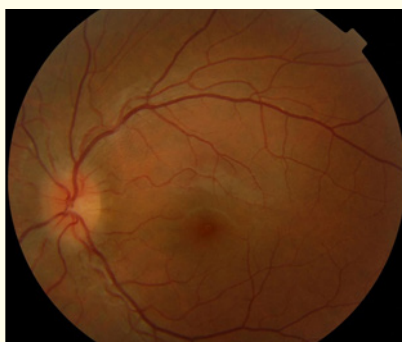
## Conclusions

The use of MRI was essential to reach the posterior scleritis diagnosis, while the BSU and CT were nonspecific. When posterior scleritis is suspected, laboratory test should be requested to discard an associated systemic and infectious disease. It is important to establish an early diagnosis to prevent secondary complications, which may compromise the visual acuity.

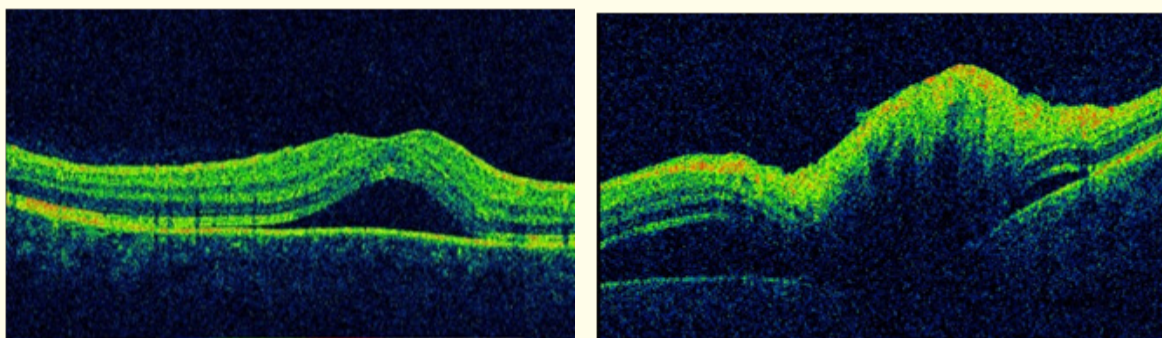
Currently, ocular BSU represents the gold standard in the diagnosis of posterior scleritis. However, orbital MRI may be an important diagnostic test for confirming posterior scleritis when the other tests are inconclusive.



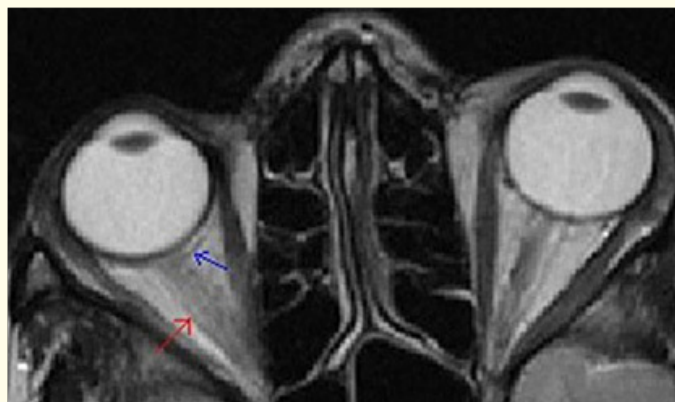**Figure 1a:** Papillitis and folds in inner retina in OD.



**Figure 1b:** Papillitis in OS.



**Figure 2a and 2b:** Neurosensory retinal detachment of the macula adjacent of the optic nerve in OD.



**Figure 3:** Axial postcontrast T1-weighted MRI of the orbits show scleral thickening enhancement of the uveoscleral margin (blue arrow) and optic nerve inflammation (red arrow).

### Bibliography

1. Cheung CM and Chee SP. "Posterior scleritis in children: clinical features and treatment". *Ophthalmology* 119.1 (2012): 59-65.
2. Benson WE. "Posterior scleritis". *Survey of Ophthalmology* 32.5 (1988): 297-316.
3. McCluskey PJ., et al. "Posterior scleritis: clinical features, systemic associations, and outcome in a large series of patients". *Ophthalmology* 106.2: 2380-2386.
4. Cordero-Coma M., et al. "Adjunctive globe magnetic resonance imaging in the diagnosis of posterior scleritis". *Canadian Journal of Ophthalmology* 46(4): 329-332.
5. Ohtsuka K., et al. "Posterior scleritis with optic perineuritis and internal ophthalmoplegia". *British Journal of Ophthalmology* 81.6 (1997): 513.
6. Salehihad H., et al. "Utility of MRI as an Imaging Modality in Posterior Scleritis". *Investigative ophthalmology & visual science* 49 (2008): 3901.
7. Iglesias Martín J and Díaz Rodríguez E. "Usefulness of optical coherence tomography in the treatment and monitoring of posterior scleritis: report of a case". *Archivos de la Sociedad Española de Oftalmología* 87.5 (2012): 145-148.
8. Chaques VJ., et al. "Computed tomography and magnetic resonance imaging in the diagnosis of posterior scleritis". *Annals of Ophthalmology* 25.3 (1993): 89-94.

Volume 2 Issue 2 September 2015

© All rights are reserved by Ortega-Molina José María., et al.