

## Experience in Prevention of Toxic Anterior Segment Syndrome / Endophthalmitis



René Hernán Parada Vásquez  
Montemorelos University  
Mexico

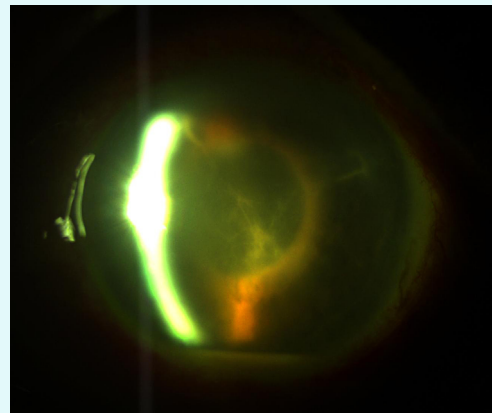
### COLUMN ARTICLE

Every ophthalmologist who operates cataracts, has had major complications of this surgery: Toxic anterior segment syndrome and endophthalmitis.

Endophthalmitis is an inflammation of the internal layers of the eye resulting from bacterial, fungal, parasitic or viral invasion and manifesting with an exudation of purulent materials into the vitreous cavity [1]. It can present in the immediate postoperative period, usually within 72 hours of surgery [2].

Toxic anterior segment syndrome (TASS) is a sterile postoperative inflammatory reaction most likely caused by a noninfectious agent that gains entry into the anterior segment at the time of surgery and results in toxic damage to intraocular lenses. This typically presents 12 to 48 hours after anterior segment surgery [2].

It is important to recognize that in TASS, the patient has no pain, episcleral hyperemia, sometimes presents hypopyon, increased intraocular pressure, classically with limbus-to-limbus diffuse corneal edema and cell deposition [2]; While in endophthalmitis there may be pain and marked hyperemia, corneal edema is late, product of elevated intraocular pressure as a result of plugging trabecular by inflammatory membranes (Figure 1).



**Figure 1:** Bacterial endophthalmitis. Inflammatory membranes and hypopyon, 3 days after phacoemulsification.

According to the literature to be studied, there are multiple potential causes of TASS including toxic effects from intraocular fluids, medications, lenses, instruments, endotoxins, and sterilization techniques [3].

It is worth mentioning that several methods have been used across multiple studies, which have been successful to prevent possible complications; among them, proper cleansing of the eyelashes that is necessary before surgery, as the most common microorganisms of blepharitis (*Streptococcus*, *Staphylococcus*, *Pseudomonas*, *Moraxella* and *Actinomyces*) they may have a mode of entry into the anterior chamber [2]. On the other hand, before each surgery, a

thorough cleaning of the eyelids, eyebrows and cheeks, is performed with 5% povidone iodine and ocular surface on cornea, conjunctiva and fornix with a dilution of 3 ml of balanced saline solution (BSS) and 2 ml of 5% povidone iodine.

I routinely use intracameral cefuroxime at the end of the surgical procedure, after aspirating the viscoelastic, this is prepared from a vial of 750 mg diluted in 7.5 ml of sodium chloride 0.9%, of which 1 ml is removed, to add to a 10 ml syringe with 9 ml of saline solution, and then 0.1 ml equivalent to 1 mg of cefuroxime is given in the anterior chamber.

If it has been complicated surgery, where the iris has been manipulated excessively or anterior vitrectomy has been performed, I place a dose of 4 mg periorbital injection of dexamethasone.

Being a good anterior segment surgeon does not mean achieved 20/20 in all cases, but rather, one who can successfully resolve their complications when these arise.

#### ACKNOWLEDGMENTS

The author has no financial disclosures. Figures belong to the author's own.

#### BIBLIOGRAPHY

1. Subhendu Kumar Boral and Suber S Huang. "A Practical Guide to Theory, Practice and Management". *New Delhi: Jaypee Brother* (2016): 140.
2. Krachmer JH., et al. "Cornea (3<sup>rd</sup> Edition)". *Philadelphia: Elsevier/Mosby* (2011): 1660-1661
3. Mamalis N., et al. "Toxic anterior segment syndrome". *Journal of Cataract and Refractive Surgery* 32.2 (2006): 324-333.

©All rights reserved by René Hernán Parada Vásquez.

**Citation:** René Hernán Parada Vásquez. "Experience in Prevention of Toxic Anterior Segment Syndrome / Endophthalmitis". *EC Ophthalmology* ECO.01 (2016): 09-10.