

Epidemiology of Echinococcosis in the Northern Region of Russia

EO Utenkova^{1*}, SV Baramzina¹ and LV Oparina²

¹"Kirov State Medical University" of the Ministry of Healthcare of the Russian Federation, Russia

²The Office of the Federal Service for Supervision of Consumer Rights Protection and Human Wellbeing in Kirov Region, Russia

***Corresponding Author:** EO Utenkova, "Kirov State Medical University" of the Ministry of Healthcare of the Russian Federation, Russia.

Received: February 04, 2021; **Published:** July 29, 2021

Abstract

Introduction: The Kirov region is the natural center of an echinococcosis. In recent years body height of incidence of this infection is noted. A research objective was studying of an echinococcosis epidemiological features in the region.

Materials and Methods: Data of cards of epidemiological inspection of the patients undergoing treatment for an echinococcosis from 2007 to 2015 are used in work. Women there were 22 persons, men - 14. The diagnosis at all was confirmed serological, the ultrasonography, MRT, KT methods.

Results and Discussions: More than 50% of patients were more senior than 50 years. Infection occurred when gathering wild berries more often. Equally often workers, employees, pensioners and the unemployed were ill.

Most often patients showed complaints to weight and pains in a liver. At 20% of patients at inspection the chance negative result was received. The final diagnosis was, as a rule, exposed after carrying out MRT and CT. Most of patients received surgical treatment and a chemotherapy. The lethal outcome for the last time was registered in 2002. The extract from a case history, the patient who died from an echinococcosis is given in article.

Conclusion: The Kirov region is the natural center of an echinococcosis where body height of incidence of this infection is noted in recent years. Features of epidemiology of an echinococcosis in the territory of the area are: lack of incidence among the children's population, a dominance among sick women, is more senior than 50 years, the greatest risk of infection with an echinococcosis when gathering wild berries. The most common form of echinococcosis was Liver alveococcosis in Kirov region.

Keywords: Helminthiases; Kirov Region; Liver; Epidemiology; Echinococcosis

Introduction

Echinococcosis (E) is a severe, chronic parasitic disease caused by tapeworms of the genus *Echinococcus*. The disease occurs in South America, Asia, Eastern Europe, Russia [1-4].

The registration of this helminthiasis was started in the USSR in 1983. There are four forms of E.: cystic echinococcosis, caused by *Echinococcus granulosus*, alveolar echinococcosis, caused by *E. multilocularis*, polycystic echinococcosis, caused by *E. vogeli* infection and monocystic echinococcosis, caused by *E. oligarthrus*.

For people, cystic and alveolar E. are of primary importance. The latter is the most difficult. But its separate registration in the country was introduced only in 2013.

In 2015, 437 cases of cystic E. and 54 cases of alveococcosis were registered in the country (A). Although slightly lower than in 2014, annual deaths are a concern. So, in 2014, 4 people died from the disease, and in 2015 - 3. The highest incidence is recorded in the regions where the population is engaged in hunting and animal husbandry.

At meat processing plants, more than 30 thousand cases of E. are detected in farm animals every year. Among the infected animals, the first (48%) and second places (32%) are occupied by cattle and small ruminants, respectively. Pigs make up 19%, horses - 1% [5].

The Kirov region is located in the north of the Volga Federal District. The region is not distinguished by developed animal husbandry, and biohelminthiasis occupy only the 3rd place in prevalence, after contagious helminthiasis and geohelminthiasis. However, cases of cystic E. and A. are registered in the region every year.

Aim of the Study

The aim of this study was to study the features of the epidemiology of E. in the territory of the Kirov region, one of the northern regions of Russia.

Materials and Methods

The work used maps of the epidemiological survey of the FBUZ "Center for Hygiene and Epidemiology in the Kirov region" of patients, residents of the Kirov region, who were treated for E. from 2007 to 2015. There were 22 women (61.1%), and 14 men (38.9%). The patients were distributed by age as follows: 18 - 30 years - 4 (11.1%), 31 - 40 years - 3 (8.3%), 41 - 50 years - 7 (19.4%), 51 - 60 years - 15 (41.6%), over 60 years old - 7 (19.4%). The patients were examined by ELISA (*Echinococcus*-IgG-ELISA-BEST, Vector-best, Russia) or by the RNGA method (Echinococcal erythrocytic dry diagnosticum, Vector GNTs VB, Russia). Diagnostic titer 1/100. The final diagnosis was made after examination by ultrasound, MRI and CT.

After surgical treatment, a pathologist was performed - a histological examination of the removed material. The information is used confidentially. Statistical processing of the results was carried out on a personal computer using licensed Microsoft Excel software. The mean values (p), the error of the mean (mp) were calculated, the reliability of differences in qualitative indicators was assessed using the Pearson χ^2 test for four-field tables with Yates correction for sample continuity (with an expected frequency of < 10); differences were considered significant at $p < 0.05$.

Results

The incidence of E in the Kirov region tends to increase and in recent years exceeds the national average (Figure 1).

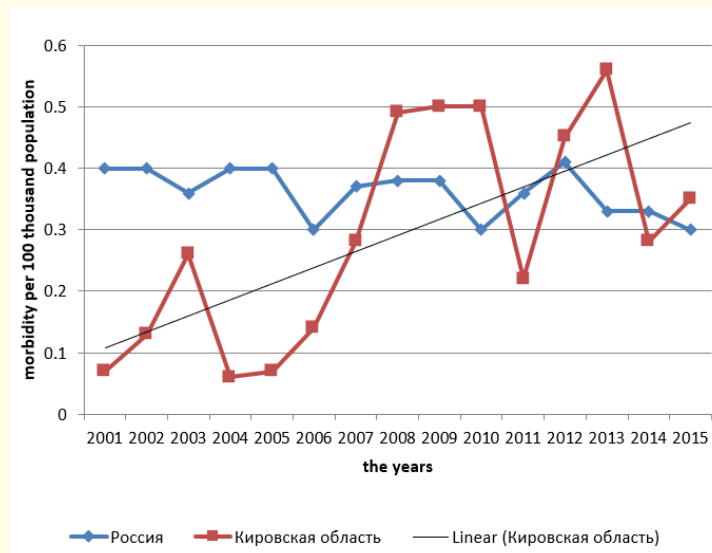


Figure 1: The incidence of E in the Russian Federation and the Kirov region from 2001 to 2015.

Total for the period 2007 - 2015 in the region, 36 cases of E were identified, of which cystic E was 38.9%, and A - 61.1%. All patients, except one, were residents of the Kirov region. Among patients with cystic E, persons over 50 years old accounted for 50%, among patients with A - 68.2%. When collecting anamnesis, it was not possible to find out exactly the route of infection. However, in the cystic E group, the majority of patients (71.4%) reported regularly picking wild berries, 50% kept dogs, and 14.2% looked after farm animals. Among patients with cystic E, townspeople accounted for 78.5%.

Among patients A, 90.9% of patients indicated picking of wild berries, 68.1% of patients indicated contact with dogs, and 36.4% of farm animals. In addition, 22.7% of the sick hunted regularly, 18.1% took part in the processing of the skins of wild animals. In this group, rural residents absolutely predominated (86.3%).

Speaking about the social structure of patients, it should be noted that workers, office workers, pensioners and the unemployed met almost with the same frequency. The only difference is that agricultural workers were sick only A. Cystic E was not registered among them.

It should be noted that in patients with E in the Kirov region, liver damage predominates. Among patients with cystic E it was 92.9%, among patients A - 100%. In the Kirov region, during the study period, with cystic E, only 2 patients were found to have lung damage and one of the spleen. Among patients A, there were lesions of the lungs, diaphragm, adrenal glands, pancreas and lymph nodes. But all these were liver metastases.

Diagnosis of E is often difficult. Despite the fact that the doctors of the region are no longer too familiar with nosology, making a diagnosis often causes difficulties and requires numerous examinations. Thus, in case of cystic E, the preliminary diagnosis of "Echinococcosis" was made only in 57.1% of patients. For the rest, the diagnosis sounded like "liver cyst". In case A, the patients were exposed to various preliminary diagnoses: hepatic mass formation, liver rupture, obstructive jaundice, liver cyst, hemangioma, liver abscess, hepatitis. Various diagnoses are probably associated with non-specific complaints presented by patients (Table 1).

Complaints	Cystic echinococcosis (N = 14)	Alveococcosis (N = 22)
Heaviness in the right hypochondrium	41,6 ± 14,2	63,6 ± 10,2
Pain in the right hypochondrium	75 ± 12,5	68,1 ± 9,9
Rash	8,3 ± 7,9	-
Epigastric pain	8,3 ± 7,9	9,0 ± 6,1
Weakness	41,6 ± 14,2	31,8 ± 9,9
Nausea	16,6 ± 10,8	-
vomiting	8,3 ± 7,9	4,5 ± 4,4
Dark urine	8,3 ± 7,9	-
Bitterness in the mouth	8,3 ± 7,9	9,0 ± 6,1
Decreased appetite	16,6 ± 10,8	4,5 ± 4,4
Slimming	16,6 ± 10,8	4,5 ± 4,4
Diarrhea	8,3 ± 7,9	4,5 ± 4,4
Jaundice	-	13,6 ± 7,3
Fever	-	9,0 ± 6,1
Heartburn	-	4,5 ± 4,4
Chills	-	4,5 ± 4,4
Itchy skin	-	9,0 ± 6,1
No complaints	16,6 ± 10,8	4,5 ± 4,4

Table 1: Complaints presented by patients with cystic E and A.

The most common complaints were of heaviness and pain in the right hypochondrium. Most of the complaints coincided with cystic E and A. But only patients with A complained of jaundice, fever, heartburn, chills and itching of the skin.

In all patients, the examination was started with ultrasound. Subsequently, serological examinations, MRI and CT were used. On serological examination, 20% of patients gave a false negative result. The final diagnosis was usually made after MRI and CT.

Currently, the main method of treatment for E is surgery, which is further supplemented by chemotherapy [6]. In the Kirov region, surgical treatment of such patients is carried out in the Kirov regional clinical hospital by the staff of the department of hospital surgery under the guidance of Professor V.A. Bakhtin.

From 2007 to 2015, all patients with cystic E were successfully operated on and 72% of them subsequently received specific therapy. The postoperative period was smooth. Only one patient developed a complication: pleurisy. Among patients with A, only 72.7% received surgical treatment for various reasons, and 81.8% received chemotherapy. In one patient, the postoperative period was complicated by the development of acute liver failure. There were no fatalities. The death was last recorded in 2002.

Here is an extract from the medical history: Patient D, 46 years old, a resident of one of the districts of the region. 11/25/99 turned to the local therapist with complaints of: chills, fever up to 39.5°C within a week, headaches, pain on palpation of the spine. I took aspirin, analgin without effect.

Anamnesis of life. Suffers from chronic gastritis, pancreatitis, osteochondrosis of the cervical and thoracic spine. In 1997, she was diagnosed with duodenal ulcer.

Examination revealed pain on palpation of the lumbar spine, as well as the abdomen in the mesogastric region, S. Pasternatsky (+). Preliminary diagnosis: Lumbar osteochondrosis, exacerbation; O pyelonephritis?

In the general analysis of blood and urine from 26.11.1999 without pathology. Abdominal ultrasound: hepatosplenomegaly, purulent lesion of the left kidney? Acute pyelonephritis on the right?

Consulted by a neurologist. Diagnosis: Lumbosacral plexalgia, bilateral, vertebrogenic.

The radiograph of the lumbar spine in 2 projections shows the initial signs of spondylosis, minor scoliosis.

The prescribed treatment (NVPS, aminophylline, baralgin, lasix) had no significant effect. In the general analysis of blood, an increase in ESR (from 21 to 27 mm / h) and eosinophilia (from 1 to 5%) were noted.

For further examination and treatment, she was sent to the Kirov Regional Clinical Hospital, where she was from 10.12.99 to 7.02.00. After additional examination at the KOKB, the diagnosis was made: Alveococcosis of the right half of the liver SVI-SVII with decay and metastases in the retroperitoneal space, peri-intestinal lymph nodes, m. iliopsoas dextra with decay.

December 23, 1999 - right-sided lateral lobectomy of the SVI-SVII liver was performed. Were removed parasitic nodes from the retroperitoneal space, made skeletonization of the aorta, inferior vena cava, celiac trunk, right renal artery. The patient was discharged in a satisfactory condition, the observation of a surgeon was recommended, monitoring of ALT, AST, ultrasound - monitoring of the abdominal organs after 6 months.

Over the next 6 months, the patient was on sick leave, regularly observed by a surgeon: worried about weakness, malaise, dull pain in the right hypochondrium. In the KLA from 17.04.00 and 6.05.00, hypochromic anemia (Hb 102.0 -105.8 g/l), leukopenia (L - 3-4 * 10⁹/l), no eosinophilia.

At the beginning of June 2000, throbbing pains in the sacrum region with irradiation to the right groin area began to disturb. Complaints are regarded as a manifestation of lumbodynia, vertebral etiology. Since the treatment did not help, on 26.06.2000 she was consulted by an abdominal surgeon at the KOKB. Control ultrasound of the abdominal cavity was performed on 26.06.00. Revealed minor splenomegaly. There is no other pathology. Ultrasound control is recommended after 6 months.

Despite the ongoing treatment at the place of residence, the pain increased. 08/30/2000 after MRI of the lumbar spine, diagnosed with alveococcosis of the right half of the SVI-SVII liver with metastatic lesions of the spine (L2-L3) of the vertebrae, compression of the L3 root on the left. On 05.09.00 the operation was performed: removal of the alveococcus from the spinal canal. The postoperative period was uneventful, the intensity of pain decreased, the patient was discharged in a satisfactory condition, wearing a corset was recommended, observation of a neurologist.

In the postoperative period from 5.10.00, there was an increase in pain in the lumbar spine with irradiation to the lower extremities, decreased sensitivity in the legs, and the appearance of a tumor-like formation in the lumbar region. The patient, due to intense pain and weakness in the legs, did not get out of bed for 1.5 years. Sent to KEC where the 1st group of disability was determined. For relief of pain syndrome, narcotic analgesics were prescribed for 1.5 years. On 28.05.02 the patient died at home.

Clinical diagnosis: Alveococcosis of the right half of the liver SVI-SVII with disintegration and metastases in the retroperitoneal space, peri-intestinal lymph nodes, m. iliopsoas dextra with decay, metastatic lesion of the spine (L2-L3 vertebrae), compression of the L3 root on the left.

Autopsy was not performed.

Discussion

E is a widespread disease [3,4]. Cystic E is common everywhere except Iceland and Greenland. And it is more typical for the northern hemisphere [3,4], although now they write more and more often that, perhaps, the area of its distribution is much wider.

The Kirov region belongs to the northern regions of Russia, so it is not surprising that A is found here more often than cystic E.

The epidemiological features of the disease are largely determined by the climate, social conditions, traditions in the area and the level of culture. The Kirov region is covered with forests. In the summer season, picking mushrooms and berries is one of the main occupations of the rural and urban population. This also determines the predominant route of infection. Meanwhile, infection through contact with dogs cannot be ruled out. In other countries, this route of infection prevails [7-9].

Among the cases of E in the Kirov region, women over 50 prevail, which is consistent with the data of the Baltic scientists [10]. Meanwhile, in the world of E, children often get sick, and the main morbidity occurs in people under 50 years old [9,11-13]. It is known that E develops slowly, and patients may not present any complaints for many years. The detection of numerous cases of E among children and young people may indicate either a more severe course of the disease, or a good diagnosis of E in a given region.

A clinical feature of E in the Kirov region can be called a predominant liver damage. When analyzing the literature data, it seems that liver damage is more typical for the northern countries [4,10]. But in the southern countries numerous lesions of other organs are described: lungs, brain, bones [11,13,14].

Currently, there are all the possibilities for the timely diagnosis of E. It should be recognized that serology at the present stage has only an auxiliary value [15]. Instrumental examinations play the main role. It is very important that doctors conducting such studies are aware of the epidemiological situation in the region and be able to correctly interpret the results obtained.

The given clinical case clearly demonstrates the prospects of patients A in the absence of chemotherapy. Exophytic growth of alveococcus with invasion into the spine in a patient has long been regarded as a course of lumbar osteochondrosis. X-ray the lumbar spine turned out to be uninformative and did not allow the correct diagnosis to be made. Only with MRI of the lumbar spine was it possible to prove the role of alveococcus as a cause of metastatic lesions of the spine (L2-L3) of the vertebrae with the development of compression syndrome. After surgical treatment in 1999 with the maximum possible removal of parasitic nodes from the retroperitoneal space and the region of the aorta, inferior vena cava, celiac trunk without chemotherapy, further progression of the disease was observed, which led to a lethal outcome. Unfortunately, the possibility of chemotherapy appeared in Russia only in 2008, when the drug Nemozol was registered.

Statistics in the region show that even today not all patients receive chemotherapy. Unfortunately, in some cases this is due to the ignorance of physicians in terms of treatment methods for nosology.

Conclusion

Summarizing all of the above, we can draw the following conclusion:

- Kirov region is a natural focus of E, where in recent years there has been an increase in the incidence of this infection.
- The specific features of the epidemiology of E on the territory of the region are: the absence of morbidity among the child population, the predominance of sick women over 50 years of age, the greatest risk of E contamination when picking forest berries.
- Among the forms of E in the region, A prevails with predominant liver damage.

Bibliography

1. Nelson I., et al. "Cystic Echinococcosis". *Journal of Clinical Microbiology* 54.3 (2016): 518-523.
2. Pakala T., et al. "Hepatic Echinococcal Cysts: A Review". *Journal of Clinical and Translational Hepatology* 4 (2016): 39-46.
3. Atanasov G., et al. "Alveolar echinococcosis-spreading disease challenging clinicians: A case report and literature review". *World Journal of Gastroenterology* 19.26 (2013): 4257-4261.
4. Torgerson PR. "Helminth-Cestode: *Echinococcus granulosus* and *Echinococcus multilocularis*". In: Motarjemi, Y. *Encyclopedia of Food Safety*. Waltham, MA: Elsevier (2014): 63-69.
5. Pismo federalnoj sluzhby po nadzoru v sfere zashhity prav potrebitelej i blagopoluchija cheloveka ot 20 ijunja 2016 goda N 01/7782-16-27". O zabolevaemosti jehinokokkozom i alveokokkozom v Rossijskoj Federacii (2016).
6. Bronshtejn AM., et al. "Echinococcosis (gidatidozny and alveolar) - a boundary problem of medical parasitology and surgery (the review and characteristic observations)". *Rossijskij Medicinskij Zhurnal* 3 (2012): 50-53.
7. Velieva TA. "Problems of diagnostics and treatment of an echinococcosis". *Scientific Journal* 4.10 (2015): 8-11.
8. Ermakova LA., et al. "Epidemiological aspects of a gidatidozny echinococcosis in the south of Russia". *Teorija i Praktika Parazitarnyh Boleznej Zhivotnyh* 16 (2016): 149-151.
9. Gawor J. "Alveolar Echinococcosis in Europe and Poland -threat to humans". *Przeglad Epidemiologiczny* 70.2 (2016): 281-288.
10. Marcinkute A., et al. "Echinococcus infections in the Baltic region". *Veterinary Parasitology* 213 (2015): 121-131.

11. Omorov TM. "Brain echinococcosis at children". *Nejrohirurgija i Nevrologija Kazahstana* 25.4 (2011): 18-20.
12. Trishin MV, *et al.* "Epidemiology and diagnostics of an echinococcosis among the children's population of the Orenburg region for 1994-2012". *Bjulleten' Orenburgskogo Nauchnogo Centra UrO RAN* 1 (2014): 1-4.
13. Çakır M., *et al.* "Management of Extra-Hepatopulmonary Hydatid Cysts (157 cases)". *Türkiye Parazitoloji Dergisi* 40 (2016): 72-76.
14. Bykov VP, *et al.* "Echinococcosis as natural and focal pathology". *Jekologija Cheloveka* 4 (2006): 3-5.
15. Kozlov SS, *et al.* "Diagnostics of parasitic diseases. Myths of the present". *Journal Infectology* 3.1 (2011): 64-68.

Volume 16 Issue 8 August 2021

©All rights reserved by EO Utenkova., *et al.*