

Using Valproic Acid in Patients with Brain Tumor During Adjuvant Radiotherapy

Aleksandr S Shershever^{1,2*}, Dmitry L Benzion¹, Svetlana A Lavrova¹, Yuliya A Mironova¹ and Gleb V Cherkasov¹

¹Sverdlovsk Regional Oncological Dispensary, Sverdlovsk Region, Russia

²Urals State Medical University, Yekaterinburg, Sverdlovsk Region, Russia

***Corresponding Author:** Aleksandr S Shershever, Professor at the Department of Nervous Diseases, Neurosurgery and Medical Genetics, Ural State Medical University, Yekaterinburg, Sverdlovsk Region, Russia.

Received: November 11, 2019; **Published:** December 04, 2019

Abstract

Objective: Epileptic seizures (ES) are quite common in patients with brain tumors. The frequency of ES depends on the location of the tumor, size, histology and type of treatment. We evaluated the efficacy of intravenous valproic acid in patients with seizures associated with a brain tumor (BT) in the postoperative period during adjuvant course of radiotherapy/chemoradiotherapy (RT/CRT).

Materials and Methods: The prospective study included 879 patients aged 18-78 with brain tumors who received adjuvant course of RT/CRT after brain surgery in 2014-2018. All patients for the duration of the course of RT/CRT were monitored in the radiotherapy department. According to the standard of examination and treatment, all patients were evaluated for clinical and neurological status, electroencephalogram (EEG), brain MRI with intravenous contrast. During the RT procedure the patient should be stay in non-moving position for 10-30 min. To prevent the development ES (focal and generalized) in patient during RT it was used Valproic acid administered via the intravenous route. The efficacy and safety of Valproic acid was evaluated.

Results: ES was detected in 147 patients (16.7%) out of 879 study participants. An increase of ES (even under basic AED therapy) was noted on days 14-21 after the start of RT course (i.e. between the 7 and 11th RT session) in 65 of 147 patients (44.2%). The administration of Valproic acid IV allowed all 65 patients to complete the course of RT/CRT. No adverse events (AE) associated with the use of Valproic acid were reported.

Conclusion: The study showed the high efficiency and safety of intravenous valproic acid in patients with ES (local and generalized) associated with a brain tumor during adjuvant radiotherapy/chemoradiotherapy (RT/CRT). The treatment should be accompanied by clinical, neurological and EEG monitoring.

Keywords: Valproic Acid; Valproate; Antiepileptic Drug; AED; Glial brain tumor; Epileptic Seizures; Status Epilepticus; Radiation Therapy

Introduction

Brain tumor is the most common form of central nervous system neoplasm. The standard treatment for the brain tumor includes maximal surgical resection within safe limits, radiation therapy (RT) and chemotherapy (CT) in case of aggressive tumor types (WHO gr. III-IV).

Epileptic seizures (ES) are one of the common symptoms in patients with the brain tumor. The appearance, frequency of seizures,

their serial and status course are often observed after surgery during RT and CT courses [1,2]. Valproic acid is used as an antiepileptic drug (AED) in patients with brain tumor, since it has a low toxicity profile and high efficiency [3,4]. Several in vivo and in vitro studies have shown that Valproic acid has a radio sensitizing effect in gliomas, and the radioprotective effect for the normal brain tissue and hippocampal neurons [5]. The results of some retrospective studies have also shown the potential advantage of Valproic acid to increase the survival of patients with brain tumor [5]

Currently, the literature does not have sufficient recommendations for RT in patients with brain tumors with an increase ES. We studied the use of valproic acid for intravenous administration in patients with tumors after surgical treatment with an increase in ES and the appearance of epileptiform activity (EA) during the course of radiotherapy and chemotherapy.

Purpose of the Study

The study was based on determining the effectiveness, toxicity of valproic acid and the effect on treatment tolerance in patients with cerebral gliomas after surgical treatment and a significant increase in ES during the administration of AEDs and courses of RT or CRT.

Materials and Methods

The prospective study included 879 patients aged 18-78 with brain tumors who received adjuvant course of RT/CRT after brain surgery. The study was conducted in the period from 2014-2018 in the Sverdlovsk Regional Oncology Center. All patients included in the study had a morphologically confirmed diagnosis of a brain tumor. At the first, all patients underwent surgical treatment in the form of complete or partial removal of a brain tumor. The next step was course of RT/CRT, depending on the histological grade of the tumor.

All patients for the duration of the course of RT/CRT were monitored in the radiotherapy department. According to the standard of examination and treatment, all patients were evaluated for clinical and neurological status, electroencephalogram (EEG), brain MRI.

All manipulations in this work were performed with the informed consent of the patients and were in accordance with the ethical standards of the Helsinki Declaration (2000).

Clinical and neurological examination

Clinical and neurological examination included a detailed collection of medical history, an exhaustive description of the structure of ES, the dynamics of the development of the disease, starting with the history of the first paroxysms in accordance with the Classification of the International Antiepileptic League [6].

Attention was drawn to identifying the features of the main clinical manifestations of ES after surgical treatment and removal of a brain tumor. Their frequency and periodicity were also evaluated. Epileptic seizures were divided into:

- 1) Frequent - More than two attacks of delay;
- 2) Daily - From three to five seizures, for it is in vain.

The aim of neurological survey was the identification of focal neurological disorders, evidence of cerebral dysfunction. The severity and dynamics of focal signs of central nervous system damage were studied in detail.

Electroencephalography

At the beginning of course of RT, EEG was performed for all patients. Record was made from the surface cup electrodes (Fp1; Fp2; F5; F6; F7; F8; C3; C4; P3; P4; O1; O2) established by standard, bipolar methods in the international system "10 × 20", which was multifunctional neurophysiological complex Nicolet, Bravo program (Nicolet Biomedical, USA). Then it was repeated every three days.

With increasing frequency of ES or before their occurrence, as well as with the detection of EA, EEG was performed every other day, throughout the entire subsequent course of RT. In order to increase the efficiency of the neurophysiological examination, standard or

special functional tests (single or rhythmic photo stimulation, 3-5-minute hyperventilation). The analysis of EEG activity between ES (interictal EEG) and the time of attack (ictal EEG) was carried out to prove the true focus of bioelectric brain dysfunction. The localization of the epileptic focus and its lateralization was determined.

The analysis of the amplitude-frequency characteristics of the biopotentials of the brain, the state of its excitability, the parameters of the main alpha and beta rhythms, as well as the features of pathological forms of activity was carried out. Convulsive forms of activity (acute waves, "acute-slow wave", "peak-wave" complexes), slow-wave activity was distinguished. Taking into account the incompleteness of the processes of formation of normal rhythms, the main attention was paid to features of EA, changes in brain excitability, structure and spatial distribution of slow-wave activity taking into account the patient's age. In the general assessment of EEG, classification was used [7].

Treatment

Radiation therapy (3-D conformal RT, VMAT) was carried out on a linear medical accelerator ELEKTA Synergy S in the position of the patient lying on the treatment table with fixation of the head with a thermoplastic mask. RT sessions were carried out daily for 5-6 weeks. A single dose was 1.8–2.0 Gy, the total dose was 45–60 Gy, depending on the histological grade of the tumor. Patients with tumors grade III-IV received concurrent CRT. According to the fact that RT during the serial course of ES is impossible, since the patient should be stay in non-moving position for 10-30 min. To prevent the development ES (focal and generalized) in patient during RT it was used Valproic acid administered via the intravenous route.

The administration of Valproic acid for IV is safely and well tolerated at an infusion rate of up to 10 mg/kg/min. doses up to 30 mg/kg [8-11]. Transient local irritation due to the rapid administration of undiluted shock doses can cause transient, lacking clinical significance, changes in blood pressure in some patients. The absence of serious side effects from the side of the cardiovascular, nervous systems, liver, side effects and the rapid achievement of therapeutic concentration justify the use of Valproic acid for intravenous administration in emergency situations.

Statistical analysis

Statistical studies of this work were carried out on the basis of standard methods of boots. It was used parametric (Student t) and nonparametric (Kolmogorov-Smirnov, Pearson) information analysis criteria. It was used methods for assessing the reliability of differences in indicators of average values, and correlation analysis. The results were considered reliable at $p < 0.05$. For statistical processing, was used the Excel editor (Microsoft, USA), a statistical analysis software package Statistical 5.0 for Windows (Stat Soft, Inc, USA).

Results and Discussion

RT/CRT is an important stage in the standard classical treatment of patients with brain tumors of most histological types. Traditional course of RT takes 5 - 6 weeks. It should be noted that the increased frequency of ES or their appearance, even in the context of the use of basic AEDs, was noted on the 10 - 21st day from the beginning of RT (between 7 - 11 sessions of radiation therapy). On admission, patients received benzodiazepines, valproates, carbamazepine, seizer, topiramate and perampanelum. Anticonvulsants in the post-operative period were prescribed systematically to patients with ES or signs of EA on EEG [12].

ESs were noted in 147 (16.7%) of 879 (100%) patients with a brain tumor who underwent surgery and received RT during the period 2014 - 2018. Of the 147 (100%) patients in 65 (63.1%), due to the rapid increase ES, it was impossible to perform RT, since ES could develop during the RT session. To prevent ESs at the beginning or during the RT session, Valproic acid was administered.

To reduce perifocal edema and improved nervous system function, dexamethasone 8 - 20 mg/daily were prescribed, since it has low mineralocorticoid activity and is actively used in RT. On admission, patients received benzodiazepines, valproate, carbamazepine, seizer, topiramate, perampanelum. The aim was to enable the patient to undergo a course of RT in the background of a sharp increase in ES.

For this purpose, Valproic acid for IV was used. To reduce perifocal edema and improved nervous system function, defamed zones from 8 - 20 mg/day were prescribed, since it has low mineralocorticoid activity and is actively used in RT. On admission, patients received benzodiazepines, valproate, carbamazepine, seizer, topiramate, paraspinal. Our task was to enable the patient to undergo a course of radiation therapy in the background of a sharp increase in EP. For this purpose, valproic acid for injection was used.

Clinical example

Patient A, 36 y.o. She considers herself to be a sick person since May 2017, when an epileptic aura appeared - a short focal sensory epileptic seizure, proceeding with a preserved consciousness and accompanied by subjective sensations - numbness, tingling, weakness and twitching of the left limbs, 2 - 3 times per day. The patient lives far from the hospital.

In October 2017 the frequency of seizures reached 4-5 times a week, there was a “contusion” of speech with secondary generalization and the subsequent development of Todd's paralysis. When contacting a medical physician, the place of residence was assigned Valproic acid 500 mg + lamotrigine 200 mg - there was no effect. After 30 days, state changes were not noted. Therapy was corrected: Valproic acid 1000 mg + lamotrigine 200 mg, seizure frequency 3 - 4. After five months of treatment, the patient was consulted by a neurologist to clarify the diagnosis.

The patient's EEG is shown in figure 1.

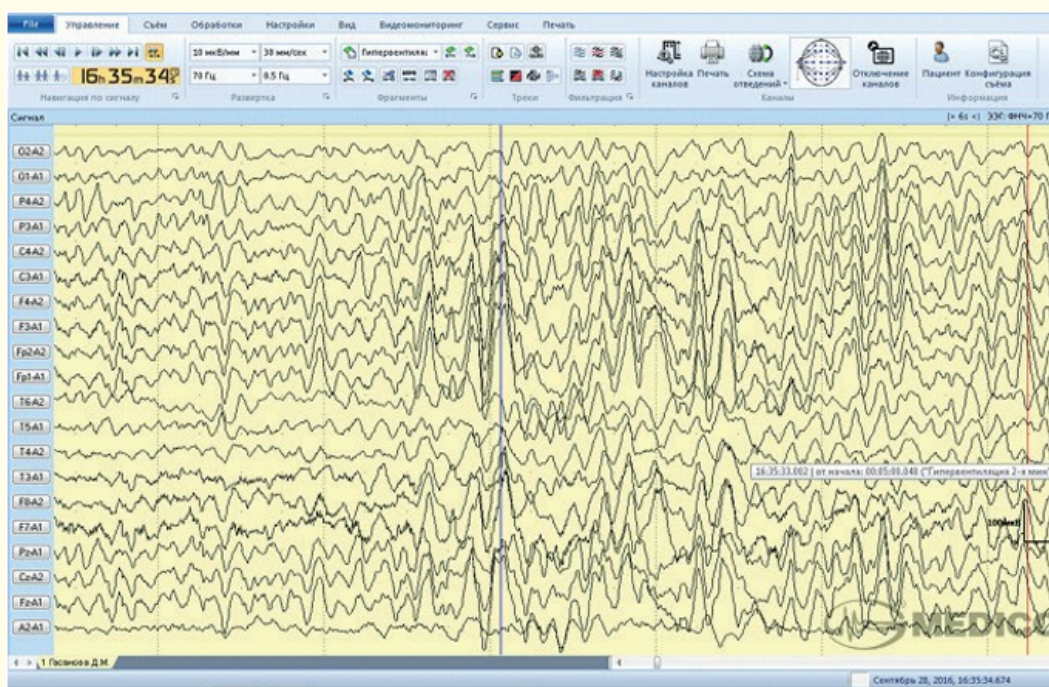


Figure 1: EEG record of patient A., 36 years old. Tumour in the posterior parts of the right frontal lobe; Symptomatic epilepsy. Slow activity of the theta range $5\ \mu\text{V}$ with an amplitude of 50 - 70 μV is dominating, bilaterally synchronous bursts with an amplitude higher than 200 μV are recorded throughout the frontal-central-parietal regions without distinct lateralization.

Brain MRI of the patient is presented in figure 2.

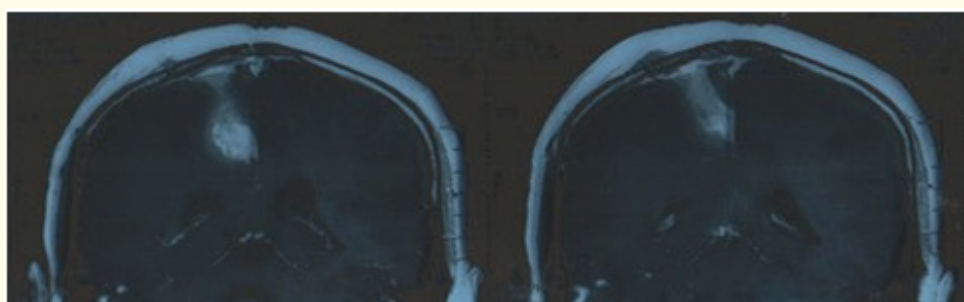

Figure 2: MRI scan of patient A, 36 years old. Tumour in the posterior parts of the right frontal lobe.

On September 24, 2017, an operation was performed to remove a tumor of the right frontal lobe. Histological examination revealed anaplastic oligodendroglioma, WHO gr.III. Anaplastic oligodendroglioma are characterized by rapid growth, their cells are significantly different from abnormal cells. Upon admission, isolation of the patient's RT revealed a moderately pronounced left-sided hemiparesis, ESS generalized by the Stood paresis, up to 4 times to the introducer. Considering that the administration of RT during EP is impossible, since the patient must be within 30 min "immobile" to complete a RT session (Figure 3 and 4).

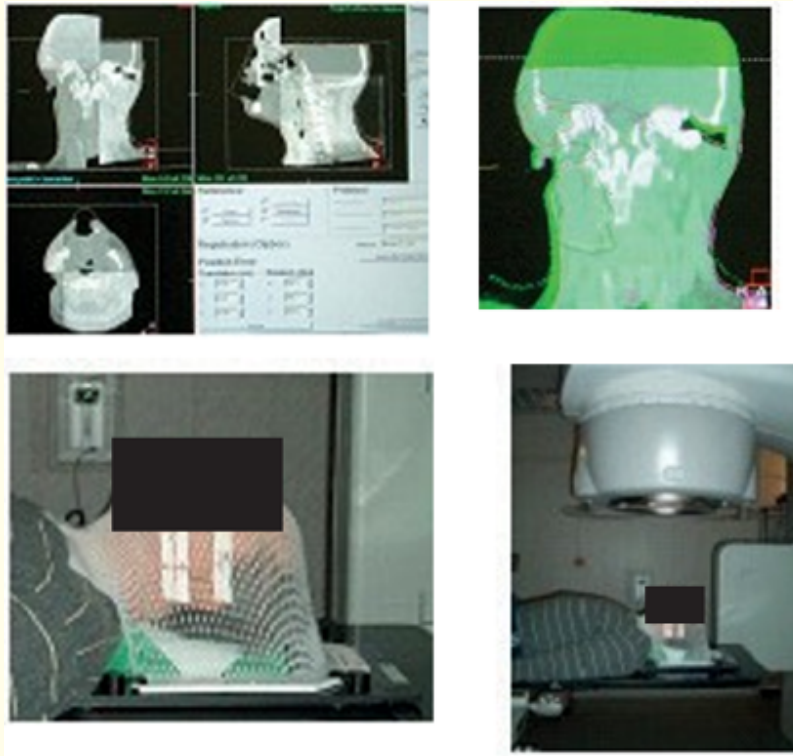


Figure 3: Position of a patient during a radiation therapy session.

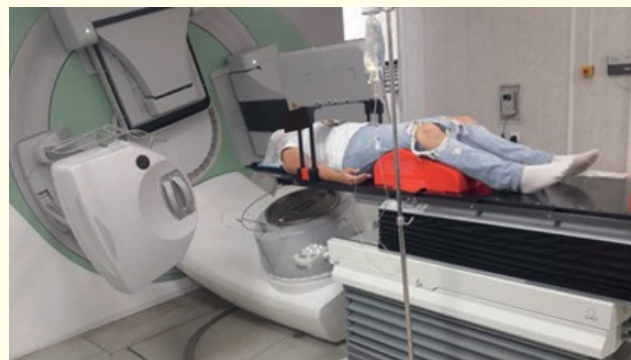

Figure 4: Patient A, 36 years old. Intravenous administration of valproic acid during a radiation therapy session.

In urgent convulsive conditions, Valproic acid was used for IV administration in shock doses-1500-3000 mg, 30-60 minutes before the start of RT or during RT for the purpose of relief or prevention of ES. Significant changes in blood pressure, respiratory disorders, electrocardiogram were not observed. After completing the RT course, patients were recommended to continue taking Valproic acid 2500 mg per day.

Currently, the evidence base for the effectiveness and safety of AEDs, that submitted by large-scale controlled studies of patients with focal ES associated with brain tumors, is limited [9]. Symptomatic treatment, for example, is the same as for focal seizures, taking into account the assumption that the cause is focal brain damage. AED treatment can be started after the first attack. There is no convincing evidence of the effectiveness of preventive treatment.

When treating ES associated with tumors, some important points need to be considered, including the following:

- High relapse rate after the first seizure.
- Hypersensitivity to undesirable effects of AED;
- Disease progression and associated changes in the clinical response;
- Possible interactions between AEDs and anticancer drugs.

As a rule, complete control of ES is rarely possible. There is no evidence of the effectiveness and safety of the AED for a given category of patients, submitted by large controlled studies.

According to scientific sources, the use of Valproic acid for IV administration seems to be a highly effective and safe method of treating many emergency situations of patients with brain tumors [10-12]. In our study, the use of Valproic acid for IV administration allowed in 2014-2018 to complete the course of RT for all 65 patients who had increased ES.

Conclusion

The survey in the conditions of real clinical practice allows us to recommend Valproic acid for the treatment of patients with brain glioma and epileptic seizures (focal and generalized) during of adjuvant RT under the control of clinical and neurological examination and EEG.

Conflict of Interests

The authors declare about the absence of conflict of interest with respect to this publication.

All authors contributed equally to this article.

Bibliography

1. Rudà R., *et al.* "Epilepsy and brain tumors". *Current Opinion in Oncology* 22.6 (2010): 611-620.
2. Ochiai S., *et al.* "Roles of Valproic Acid in Improving Radiation Therapy for Glioblastoma: a Review of Literature Focusing on Clinical Evidence". *Asian Pacific Journal of Cancer Prevention* 17.2 (2016): 463-466.
3. Karlov VA and Andreeva OV. "The use of injectable depakine in the treatment of status epilepticus". *Rus Med Zhurn* 20 (2001): 889-893.
4. Kholin AA., *et al.* "Efficacy and safety of intravenous valproate administration". *Zhurn NeVrologii i psikiatrii im S S Korsakova* 3 (2010): 55-59.
5. Happold GCT., *et al.* "Does valproic acid or levetiracetam improve survival in glioblastoma? A pooled analysis of prospective clinical trials in newly diagnosed glioblastoma". *Journal of Clinical Oncology* 34.7 (2016): 731-739.

6. Avakyan GN., *et al.* "ILAE classification of the epilepsies: the 2017 revision and update. *Epilepsia i paroksizmal'nye sostoania*". *Epilepsy and Paroxysmal Conditions* 9.1 (2017): 6-25.
7. Zhirmunskaya EA. "Clinical electroencephalography". Moscow (1991): 216.
8. Shershever AS., *et al.* "Injection of valproic acid in patients with serial epileptic seizures and status epilepticus at the prehospital stage and in the hospital". *Method. Recommendations* Ed. A.S. Shersever. Yekaterinburg. (2018): 88.
9. Shershever AS., *et al.* "Modern antiepileptic drugs in the treatment of symptomatic epilepsy associated with brain tumors: a combined approach". *Polenovskiy readings. Materials of the XI All-Russian Scientific and Practical Conference*. St. Petersburg (2017): 28.
10. Shershever AS., *et al.* "The use of antiepileptic drugs in the treatment of patients with glial brain tumors and epileptic seizures after surgical treatment during radiation therapy. *Actual issues of modern epileptology*". *Ural Conference on Epileptology. Conference proceedings*. Yekaterinburg (2014): 38-40.
11. Shershever AS., *et al.* "Tactics of management of patients with glial tumors and epileptic seizures after surgical treatment during radiation therapy". *Polenovskiy readings. Materials of the XI All-Russian Scientific and Practical Conference*. St. Petersburg (2012): 77.
12. Konovalov AN., *et al.* "Standards, recommendations and options in the treatment of glial brain tumors in adults". Moscow (2015): 29.

Volume 12 Issue 1 January 2020

©All rights reserved by Aleksandr S Shershever., *et al.*