ECRONICON OPEN ACCESS

EC NEUROLOGY
Review Article

Clinical Approach in Recognizing and Differentiating between Atypical Parkinsonian Disorders and their Treatment: A Short Review

George Christophides* and Ioannis Patrikios

School of Medicine, European University Cyprus, Engomi, Cyprus

***Corresponding Author:** George Christophides, School of Medicine, European University Cyprus, Engomi, Cyprus.

Received: July 23, 2019; **Published:** November 18, 2019

Abstract

Atypical Parkinsonism involves four distinct disease phenotypes which are the Progressive Supranuclear Palsy (PSP), Multiple Systems Atrophy (MSA), Dementia with Lewy Body (LBD) and Corticobasal degeneration (CBD). Although these are four distinctive separate diseases with distinct pathological background they share similar histopathological characteristics and consequently their symptoms often overlap making the diagnosis for neurologists challenging. Due to the failure of the presence of disease specific biomarkers and the low sensitivity or specificity of imaging techniques in distinguishing between MSA, PSP, CBD, LBD makes the differential diagnosis even more challenging; and based primarily upon the neurological clinical examination subsequently followed and supplemented by imaging techniques. These disorders not only do not respond to the conventional treatment applied to Parkinson's Disease but the use of some agents in the setting of misdiagnosis might outweigh the benefit to risk ratio. In this review we outline some major distinct disease clinical characteristics along with the most suitable investigation procedures and treatment plans for each atypical form of Parkinsonism.

Keywords: *Parkinson's' Atypical Parkinsonism; Supranuclear Palsy; Multiple Systems Atrophy; Dementia with Lewy Body; Corticobasal Degeneration*

Abbreviations

AD: Alzheimer Disease; CBD: Corticobasal Degeneration; CBS: Corticobasal Syndrome; CSF: Cerebrospinal Fluid; DAT-SPECT: Dopamine Transporter Single-Photon Emission Computed Tomography; DLB: Dementia with Lewy Bodies; DTI: Diffusion-tensor Imaging; FDG-PET: ^{18}F-Fluorodeoxyglucose Positron Emission Tomography; FTD: Frontotemporal Dementia; MRI: Magnetic Resonance Imaging; MSA: Multiple System Atrophy; MSA-C Multiple System Atrophy-Cerebellar Type; MSA-P: Multiple System Atrophy-Parkinsonian Type; PD: Parkinson Disease; PET: Positron Emission Tomography; PLS: Primary Lateral Sclerosis; PSP: Progressive Supranuclear Palsy; PSP-C: Progressive Supranuclear Palsy-Cerebellar Ataxia; PSP-CBS: Progressive Supranuclear Palsy-Corticobasal Syndrome; PSP-P: Progressive Supranuclear Palsy-Parkinsonism; PSP-PAGF: Progressive Supranuclear Palsy-Pure Akinesia Gait Freezing; REM: Rapid Eye Movement; SNRI: Serotonin Norepinephrine Reuptake Inhibitor; SPECT: Single-Photon Emission Computed Tomography; SSRI: Selective Serotonin Reuptake Inhibitor

Introduction

The general term of Parkinsonism or parkinsonian syndrome refers to a pathological state of hypokinesia or dyskinesia and it is commonly symptomatologically defined by resting tremor, bradykinesia, rigidity, general akinesia or difficulties in initiating movements and postural instability [64]. Although Parkinson's disease is the major neurodegenerative disease accompanied by the symptoms described above, there are a number of secondary or atypical Parkinsonian disease entities that share an overlap of the standard symptomatologic features of PD, making the diagnosis of PD or atypical Parkinsonism more challenging. Despite the fact that patients with atypical parkin-

sonism are considerably low in numbers in relation to the patients with typical PD this number of atypical cases is significant enough to produce difficulties in the diagnosis and differential diagnosis of Parkinsonian syndromes. The patients presented with atypical parkinsonism initially have the symptomatological features of PD, tend to develop some extra multisystemic brain clinical features involving more than just the dopaminergic pathway commonly seen in PD such as dementia, ocular motility difficulties, early and frequent falls, movement ataxia or autonomic failure features. These group of disease in which they are encompassed within the atypical parkinsonian spectrum include the Dementia with Lewy bodies, Corticobasal Degeneration and Multiple systems atrophy. The major clinical significance in the early differential diagnosis of atypical Parkinsonism against PD is that the progression of such disease is often aggressively rapid than in typical PD making the early diagnosis a crucial part in extending the lifespan and preserving the quality of life of these patients as best possible [63].

In these syndromes the treatment strategy is often more complex in relation to PD due to the fact that there is resistance in response to common treatments available and it is mostly based on the symptomatologic presentation of the patient. However, the foremost challenges in treating such diseases is that most of the treatments lack in efficacy or produce several side effects with complications that neutralize the benefits. Therefore, due to the additional special care that these patients require a more multidisciplinary approach of treatment has to be followed [62].

Signs and symptoms comprising the atypical Parkinsonism often overlap between the diseases in this category and the typical parkinsonian syndrome. Unfortunately the clinical features of these diseases not only overlap between each other within the parkinsonian spectrum but can also interconnect and overlap with other neurodegenerative diseases and secondary parkinsonism causes; rendering the diagnosis even more perplexing (Figure 1) giving rise to common drawbacks within the clinical setting such as diagnostic delays, misdiagnosis and under-recognition of the current disease. However, during the recent years of extensive scientific and clinical study of such confounding diseases, there is a progression in understanding the underlying pathophysiological mechanism of atypical Parkinsonian syndromes making a big step forward in distinguishing the distinct features of each separate disease entity in order to help with the proper diagnosis and treatment. Moreover, the clinical terms currently being used to describe a pathological state of atypical Parkinsonism are highly increased in recent years due to diagnostic doubt, similarity and the interconnection of symptomatology that describes a distinct parkinsonian disease entity [61].

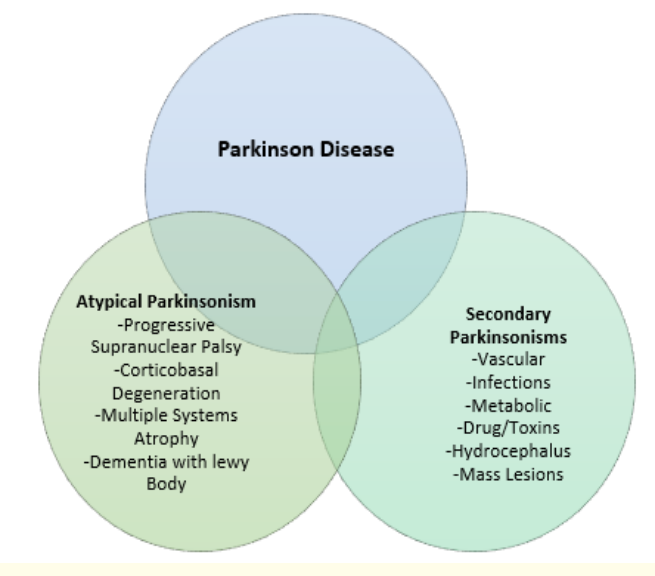

Figure 1: *The spectrum of conditions that cause parkinsonism either Secondary, Atypical, or Pure Parkinson's Disease.*

The most common pathophysiological finding inside the spectrum of neurodegenerative diseases is the deposition of abnormal proteins within the brain in areas that when pathologic are responsible of the specific clinical outcomes, describing a feature of the disease. This disease mechanism is known as proteinopathies and encompasses the major burden of neurodegenerative diseases. Protein examples resembling a specific proteinopathy (Table 1) are the a-synuclein commonly seen in Parkinsonian syndromes, ubiquitin, tau, prions and β-amyloid which is responsible for the pathological hallmarks of Alzheimer's disease [60]. Regardless of extensive research and diagnostic improvements towards understanding and diagnosing the atypical Parkinsonism diseases the major diagnostic millstone remains with clinical evaluation. There are other diagnostic tools which help and assist with proper diagnosis such as the brain imaging and by specific biomarkers.

Proteinopathies	Disease
Amyloid	Alzheimer's Disease
Ubiquitin	Parkinson's Disease with mutation of parkin
Synuclein	Parkinson's Disease, Multiple Systems Atrophy, Dementia with Lewy Body
Tau	Progressive Supranuclear Palsy, Corticobasal Degeneration, Alzheimer's Disease, Frontotemporal Dementia Parkinsonism
Polyglutamine expansion	Huntington's Disease, Cerebellar Ataxias
Prion	Creutzfeldt-Jakob Disease, Gestman-Straussler-Sheinker syndrome

Table 1: *The different categories of proteinopathies and the disease they cause.*

Nevertheless the main diagnostic evaluation weights mostly on the red flags derived from clinical evaluation and they will be described in this study; such as insidious disease onset and progression, autonomic system dysfunction, gait instability and early falls, tremor characteristics, reduced or absent response to levodopa therapy or other common treatment strategies, oculomotor abnormalities, ataxias indicating dysfunction on cerebellar tracts along with other cerebellar signs, dysautonomia, speech difficulties such as dysarthria or dysphonia and myoclonus and dementia [59].

The main goal of this study is to focus on atypical Parkinsonism and outline the different diagnostic approaches of each of the disease along with outlining the best possible treatment strategies that best suit in each modality.

Disease overview

Parkinson's disease overview

Parkinson's disease belongs to a group of pathological conditions affecting the central nervous system. While it usually affects older individuals it can manifest normally after the age of 50 years of age [1]. Parkinson's disease is characterized by a mark reduction of the quality of life of patients due to its distinct clinical features in which movements are exceedingly reduced and the mobility is certainly low, rendering normal daily activities difficult to perform [2]. Like most of the central nervous diseases; Parkinson's disease has a progressive neurodegenerative character meaning that the majority of cases will continue to get progressively worse. It is a crucial point for healthcare professionals to know that the patients with such a disease with no cure available will require at a point a continuous nursing care for the majority of their daily life [3].

The symptomatology of Parkinson's disease typically involves slow movements such as akinesia and bradykinesia in which movements take too long to be performed with a really slow pace such as slow small steps. It is worth to note that the initiation of movements is really difficult to be initiated for these patients. While a movement is initiated then it is difficult for the patient to terminate it. Another clinical hallmark is the stiffness that describes the cases with such a disease that makes the general movements difficult. This feature puts extra stress on the quality of life of the patients as stiffness not only interferes with daily movements but it is also associated with pain [4]. From the primary clinical features the most recognized characteristic clinical symptom is the tremor. Parkinsonian tremor is

a resting tremor meaning it can only manifest during rest and not during voluntary movements; and usually appears first on the upper extremities. As it progresses, it implicates other functions, sides/organs of the body such as bladder, digestion disorders, circulation problems, increased oil secretion on the skin, difficulties concentrating and depression [5].

Epidemiological studies show that the prevalence of Parkinson's disease is estimated to be 1 to 2 people per 1000 population while in older ages (over 60 years) the prevalence ascents to 18 people per 1000 population [6].

The searching for etiology of Parkinson's disease begun from very early during the 19th century and specifically in 1919 in which evidence suggested the loss of pigmentation of neurons in substantial nigra. Up-to-date studies indicated that the hallmark of pathological impact of this disease is the loss of neurons arising from the substantia nigra and pars compacta that mainly curry the neurotransmitter dopamine. Dopamine is the major modulatory neurotransmitter of the central nervous system associated with movement and motion control; hence this is the reason that explains the symptomatology of Parkinson's disease (PD), due to the loss of dopaminergic neurons through a mechanism allude to the deposition of a-synuclein proteins in the region of dopaminergic neurons. The exact pathophysiological mechanism will be discussed in detail later during this review article [7].

Diagnostic evaluation in patients with PD starts usually from history and then proceeds to clinical examination seeking for the major clinical features as mentioned above. Different movement disorder clinics imply the Unified Parkinson Disease Rating Scale in their diagnostic algorithm. This scale measures different clinical outcomes and feature of patients such as mentality, mood and behavior changes, daily activities and indubitably tremor with motor examination along with therapy complications as well. Additionally, a decisive part in establishing the diagnosis of PD through examination of clinical features is to exclude other causes that might be a reason of initiating the Parkinson's Disease symptomatology such as drugs which lead to extrapyramidal manifestations similar to PD [8]. Most neurologists establish a unique way of diagnosing Parkinsonian syndromes which include the diagnostics approach that involves the administration of the therapeutic agent the L-DOPA in order to observe whether the symptoms resolve, accompanied by rapid movements after the administration of the agent [9]. Likewise, there are several other diseases that need to be differentiated during the diagnosis that are similar to Parkinson Disease which share related characteristics and they are generally called 'atypical parkinsonism'. These "atypical" types will be discussed next in this review article.

Treatment strategy for Parkinson's disease may be reserved for the later stages of the disease progression usually due to the fact that the effects of the conventional therapy can be desensitized easily; but also due to fact that at the beginning PD is relatively mild. The common pharmacological therapy is the substitution of the lost dopamine levels by its precursor Levodopa which can be administered with Carbidopa to avoid the majority of side effects. The next management approach is by the use of dopamine agonists such as Pramipexole and Ropinirole. Anticholinergics and Amantadine are NMDA inhibitors (N-Methyl D- Aspartic acid receptor blockers antagonizing glutamine) and dopamine reuptake inhibitors (blocks dopamine re-uptake and increases dopamine release) and they can be used as another therapeutic approach aiming in controlling primarily the symptoms associated with tremor. However, PD is not simple and it needs a multidisciplinary approach to count all the possible disease features and symptoms therefore improving a patients balance, stability, overcome depression symptoms, sleeping difficulties, psychosis and hence maintain a normal quality of life as best as possible. The major point to be highlighted is that patients that receive pharmacological treatment over time get resistant to the drugs therefore other therapeutic approaches might be more sensible. These approaches include deep brain stimulation in which surgery is required in order to place electrodes in specific regions within the subthalamic nucleus and globus pallidus in order to balance out the excitatory stimulus that tend to be less controlled by the action of dopamine that is depleted [10].

Progressive supranuclear palsy

Progressive supranuclear palsy (PSP) belongs to a group of neurological disorders described as atypical Parkinsonism due to the fact that it shares similar characteristic features as Parkinson's disease. However, it is a very distinct clinical modality implicating different aspects than PD. PSP affects the gait, balance and movements in a similar manner as PD however there are some distinct features such as speech, swallowing, vision, eye movements, mood, behavior, and cognition disturbances. Unlike Parkinson's Disease pathophysiology, PSP is characterized by the deposition of a distinct protein rather than a - synuclein, the tau protein [11]. In 1964 three neurologists

Richardson, Olszewski and Steele succeeded in describing this syndrome of PSP as an uncommon assemblage of supranuclear gaze palsy accompanied by progressive axial rigidity, pseudobulbar palsy and dementia while nowadays is correctly described as an atypical parkinsonism or a Parkinson plus syndrome. According to Steele in 1972 PSP involved different nuclei within the brainstem and this explains the different variants in symptomatology of the disease. While the exact cause remains unclear up to date, advanced age, environmental factors and specific toxins contribute to the development of this Parkinson plus syndrome [12].

According to the epidemiological studies, the prevalence of PSP is around 5.5 to 6.8 per 100.000 while the incidence rate is 1.1 per 100000 and increases above the age of 50 to 1.7 per 100000 while above the age of 80 raises up to 14.7 per 100000. The mean age in which the disease manifests is at 65 years [13].

The main symptomatologic finding in patients with PSP is the loss of balance. The gait and posture of these patients while walking is stiff and broad based while the arms are abducted in contrast to "turn un bloc" feature of the Parkinson's disease, eventually leading to quick pivoting movements that increase the risk of falling down [14]. Furthermore, the hallmark of PSP involves the oculomotor system in which patients tend to acquire supranuclear ophthalmoplegia meaning that there is impairment to cope with vertical gaze examination. Other oculomotor findings include dysfunction of optokinetic nystagmus (especially during vertical gaze), convergence dysfunction, blepharospasm, and eyelid-opening apraxia. Moreover, the combination of decreased blinking, dystonic face and decreased and dysfunctional gaze leads to a distinct feature of face expression of long-lasting surprise or wonder. Vertical gaze dysfunction commonly gives rise to common problems such as reading, leaking food from mouth when eating, and negatively impacts to falls while walking [15].

Multiple systems atrophy overview

Multiple systems atrophy (MSA) is mainly a sporadic neurodegenerative disease which onset during adulthood and it is highly progressive, often fatal with no known cause or etiology. Contrasting to Parkinson's disease, MSA is characterized by a tendency to minimally respond or not respond at all to levodopa therapy or any other therapies and it is accompanied by autonomic system failure features along with ataxia of the cerebellar system or pyramidal signs [16].

On the other hand the similarities with Parkinson's disease are that they belong to the same group of a-synucleopathies, therefore as the grouping suggests the main histological and pathological feature is the deposition of a-synuclein. However, in contrast to the other synucleopathies in which the deposition is found in neurons and glial cells, in Multiple Systems Atrophy (MSA) the deposition is commonly seen in oligodendrocytes [17].

The main symptomatology of MSA is the autonomic dysfunction presenting mostly with symptoms of dysfunctional blood pressure, heart rate, bladder control and digestion. Secondly the other symptomatologic feature is the classical Parkinsonism signs and symptoms which include muscle rigidity, tremor and bradykinesia comprising of loss of or muscle control or limitations in movements, or decreased mobility and decreased muscle coordination. Next in the symptoms of MSA comes the cerebellar ataxia in which there is pathology affecting the cerebellar system such as difficulties in proper speech and gait, poor coordination of movements and daily tasks [18].

The names of MSA established in 1969 in order to incorporate and describe three distinct neurological disorders which are the nigrostriatal degenerative disease, olivopontocerebellar ataxia and Shy Dager syndrome which is the syndrome of autonomic dysfunction found in MSA [19]. Epidemiological studies implicating MSA denote a worldwide incidence rate of 0.6 per 100.000 and for adults over 50 years of age rises to 3 per 100.000 of population. Mean age of the first manifestation of symptoms is around 60 years of age with a mean survival rate of up to 9 years following the diagnosis of such a progressive neurodegenerative disease [20].

At last there is the clinicopathological classification of multiple systems atrophy according to the pathology and clinical features. Extrapyramidal clinical features that resemble Parkinson's disease such as motor abnormalities, bradykinesia, rigidity and postural instability are categorized as the parkinsonian type or MSA-P (P=Parkinsonism). Progressive ataxia symptoms decreased gait and arm coordination along with speech dysarthria is categorized to the olivopontocerebellar group or MSA-C (C=Cerebellar). Shy Dagger syndrome with autonomic failure such as dysfunctional blood pressure, heart rate, bladder control and digestion refer to the category of MSA-A (A=Autonomic) [21].

Dementia with lewy bodies overview

Dementia with Lewy Body (LBD) includes two distinct pathological features which are the dementia with Parkinson's Disease and Dementia with Lewy Bodies. LBD is characterized as a progressive neurodegenerative disease with a distinct prominent clinical feature which is the dementia. The predominant clinical features of Dementia with Lewy body as the name denotes is dementia along with psychosis and some clinical types of Parkinsonism. Moreover, there is great variation of symptoms among individuals with LBD rendering the diagnosis of this type of disease exclusively from clinical examination; sometimes there is an overlap of symptoms [22].

The general pathophysiological landmark of DLB is the deposition of Lewy bodies in specific areas of the brain with distinct cytoplasmic aggregates of a-synuclein and ubiquitin. More specifically and as a consequence of Lewy body deposition in specific regions of the brain the distinct presentation of the disease is the acetylcholine deficiency in both temporal and parietal lobes hence the outcome is dementia and psychosis with visual hallucinations. Moreover, there is upregulation of muscarinic acetylcholine receptors M1 type within the temporal lobe to compensate the acetylcholine loss and consequently diminish the dopamine levels [23].

There is no known cause or etiology of dementia with Lewy Body, however there is scientific evidence that a combination of genetic mutations, toxins from the environment, oxidative stress factors, mitochondrial dysfunction and aging are the contributing factors of the misfolding and aggregation of a-synuclein and ubiquitin consisting the Lewy bodies [24]. Epidemiological evidence suggests that this type of dementia consists of about 20 to 30 percent of all the major dementia causes usually appearing at the ages of 50 to 80 years old. While the incidence is difficult to be established due to the underdiagnosis or the misdiagnosis of the disease, there is evidence suggesting that the incidence is about 32 to 112 per 100.000 of population and the prevalence is 0.53% within age group of 65 years and above [25].

The main clinical features of LBD as mentioned above is the predominant dementia often accompanied by loss of attention, loss of memory (mainly at later stages of the disease), loss of executive function and decreased cognition. Other features include psychiatric disturbances such as hallucinations and psychosis and lastly LBD comes with a form of Parkinsonism which encompasses clinical features such as bradykinesia, tremors and rigidity [26].

Corticobasal degeneration overview

Corticobasal degeneration is a tauopathy and not synucleinopathy that belongs to the rare spectrum of progressive neurodegenerative diseases with asymmetric movement dysfunction. It is characterized by a combination of symptoms such as akinetic rigid syndrome, dystonia, apraxia, myoclonus and alien limb phenomena accompanied by an insidious onset of cognitive decline [54]. Moreover, through the years it is now widely accepted that corticobasal degeneration begins with cognition and behavior dysfunction and disturbances. In contrast to the rest of the parkinsonian syndromes the rest of the clinical features involving the motor system are non-specific for the disease but can occur within other pathological neurodegenerative diseases such as Progressive Supranuclear Palsy, Parkinson's Disease, Alzheimer's Disease and Frontotemporal dementia. Very rarely Cortical basal Degeneration can manifest on its own with the symptoms mentioned above. The diagnostic tools rely upon a good neurological assessment accompanied with advanced imaging techniques such as PET Scan. Levodopa treatment shows minimal effect and the only available treatment is the symptomatic [56].

Progressive supranuclear palsy

Physicians Richardson, Steele and Olzewski were the three doctors that discovered and studied about the Progressive Supranuclear Palsy back in 1963 and noticed that this disease manifests distinctively with supranuclear ophthalmoplegia, nuchal dystonia, pseudobulbar palsy and minor dementia. About 5% of the patients that initially show signs of Parkinsonism eventually develop PSP and therefore it is considered the most frequent form of atypical Parkinsonism. Epidemiological studies suggested that the prevalence of PSP rises to 5 per 100.000 of population while the incidence rate is about 0.005% whereas generally PSP commonly affects persons over 50 years of age and the expected lifespan reaches at 5 to 10 years [28].

The diagnostic hallmarks that describe the symptomatology of the disease and distinguish it from other types of parkinsonism is the postural instability during the early stages of the disease, the visual symptoms such as vertical gaze insufficiency, the unexpected falls

due to the instability and the progressive dementia. In addition, these classic symptoms of the disease are now termed as Richardson syndrome [29].

First of all gait instability that consequently leads to early falls is accompanied by fractures; which generally occur early in the disease progression, within the first 1 - 2 years, it is described as asymmetrical broad base, clumsy and stiff with the characteristic feature of abducted arms and extended knees and step asymmetry that reminds of a drunken person. In contrast to PD in which patients perform turn unbloc during turns, in PSP patients tend to pivot subsequently, prompting vulnerability to falls [30]. Besides, the major cause of falls is not only due to a single factor but rather to many contribution factors that influence the likelyhoodness of falls such as decreased sight of vision, deficient vestibular-visual system, freezing, decreased reflexes while standing, bradykinesia and axial rigidity. Nevertheless, the syndrome of pure akinesia with gaize freezing may be confused with Multiple Systems Atrophy that will be discussed next [13].

The second significant distinct feature of the disease is the visual impairment. Mostly visual impairment refers to signs and symptoms such as blurry vision, decreased vision, double vision, increased sensitivity to light and inability to cope with reading due to decreased convergence. Furthermore, it is the vertical gaze insufficiency that especially downward it is more prominent in this disease and it is the most important discernible factor and predictor of PSP while horizontal and upward gaze impairment can develop as well. Likewise, supranuclear palsy with gazing is generally projected through the reduced speed of vertical eye movements and decreased optokinetic nystagmus. Other non-specific signs of visual impairment in PSP involve Corneal dryness, blepharospasm, procerus sign (eyebrow contraction) and reduced eye blinking with face apraxia especially with the eyes consequently giving a general look of "Mona - Lisa". Furthermore, is triggered by additional symptoms that are commonly seen is PSP like personality changes along with emotional disturbances while combined with facial apraxia and dystonia as mentioned above, giving a worried look with constant anxiety [31].

Moving forward during the PSP progression other symptoms may be seen involving the Bulbar system including dysphagia with increased incidence of aspiration pneumonia, dysarthria, unexpected unintentional vocalizations, spastic and monotonous speech and phonation apraxia. As far as the neuropsychiatric aspects are concerned during Progressive Supranuclear Palsy there are symptoms of depression, apathy and general anxiety. Moreover, mood disturbance and mood swings are the predominant neuropsychiatric symptoms complemented with irritability, agitation, dysphoria and disinhibition. Likewise, the pseudobulbar effect might be seen which is described by interchangeable loughs and cries as the mood fluctuates, however the pseudobulbar effect can be found in other parkinsonian syndromes as well [31].

During the presentation of the distinct clinical features of the disease progressive dementia (frontal and subcortical dementia) can develop and it is described with cognitive decline, reduced task performance, slow processing of thoughts and speech and reduced verbalization or reduced usage of vocabulary. In PSP there is a tendency of retaining some clinical features that are seen in PD such as automatic behaviors that include the three clap test (applause sign) in which the patient fails to stop at three consequently hand claps and goes on despite the doctor's instruction to stop. Another exam is the Luria test while the patient cannot accomplish the hand-fist-palm test at least 6 times in a row [32].

PSP phenotypic variants and diagnostic criteria

The National Institute of Neurological Disorders and Stroke (NINDS) in collaboration with Progressive Supranuclear Palsy Society (SPSP) developed diagnostic criteria for PSP in order to distinguish the PSP from other PDs and to separate diagnostically the clinical variants of PSP.

First of all the major criteria for diagnosing PSP include the typical phenotype of Richardson syndrome along with a progressive course of the disease that typically begins to manifest after the age of 40. The minor criteria that support the likelihood of diagnosis of PSP are rigidity with unresponsiveness or low response to levodopa therapy in contrast to PD. A stressing factor is that the diagnosis can be excluded where there is evidence of encephalitis, meningitis, focal brain lesions, other neuropsychiatric signs such as hallucinations and delusions, autonomic nervous system impairment, alien limb syndrome and ataxia. Although ataxia and other cerebellar manifestation can lead to diagnosis of exclusion, recently there is a tendency of developing a PSP phenotype with cerebellar signs and symptoms [33].

Despite the fact that the diagnosis of PSP is pretty much straight forward if it manifests classically as the Richardson Syndrome, there are several other phenotypic clinical variants of the disease that will be discussed further (Table 2). First of all the most common clinical phenotype of PSP is termed as PSP-P (PSP-Parkinsonism) and as the term suggests it is the classical clinical phenotype of PSP with additional and intermixed features of PD including bradykinesia, axial rigidity, stiffness and resting tremor. Fortunately, PSP-P generally has a longer estimated survival rate than other forms of PSP. Prominently enough the oculomotor signs of the disease do not manifest at early stages, rather they develop slowly as the disease establishes. Moreover, this variant of PSP is the only phenotypic variant that shows response to levodopa therapy like in pure Parkinson's disease where the levodopa response is immediately and at early stages, however the overall levodopa response is limited [34]. Secondly another variant of PSP is the syndrome with pure akinesia and Gait freezing termed as PSP-PAGF (PSP-Pure Akinesia with Gait Freezing). PSP-PAGF is described with severe akinesia of gait (freezing) in which the speech is also involved; no tremor is present while the oculomotor dysfunction and dementia usually develop at late stages of the disease. Other features include micrographia and decreased facial expression. However, brain MRI reveals significant leukoaraiosis indicating that the disease shares imaging similarities with Binswanger disease [35].

Variant PSP	Clinical Features	Regional Pathology*
PSP-RS (Richardson Syndrome)	Early gait instability, falls, supranuclear gaze palsy, axial rigidity, dysarthria, dysphagia, progressive dementia	Dentate, globus pallidus, striatum, midbrain, and superior cerebellar (CBL) peduncle
PSP-Parkinsonism	Tremor, rigid-bradykinesia, Levodopa responsive** Late cognitive decline Longer life expectancy (9+ yrs)	Substantianigra, subthalamic nucleus
PSP-PAGF (Pure akinesia-gait failure)	Early gait difficulty, freezing of gait/motor block, micrographia, speech impairment, Hypophonia Disease duration (11-15 yr)	Motor cortex, pons, cerebellum
PSP-CBS	Dystonia, dyspraxia, cortical sensory loss, apraxia speech	Frontal and parietal cortex
PSP-PLS (primary lateral sclerosis)	Bulbar, limb weakness, upper motor neuron signs/ spasticity	Frontal predominant, corticospinal tract
PSP-cerebellar	Cerebellar ataxia	Deep cerebellar nuclei

Table 2: *The phenotypic variation of progressive supranuclear palsy.*

The third clinical alternate of PSP is the PSP-CBS (PSP- Corticobasal Syndrome). While Corticobasal degeneration (CBD) is another form of Parkinsonism that it is not covered extensively in this study, there is obvious and distinctive overlap between the symptomatology and pathophysiology of PSP and CBD. Merely the Richardson syndrome is frequently absent and not typical with this variant. However other features such as general dystonia, alien limb sign and apraxia manifest during the course of the progression of PSP. Normally the response to levodopa treatment for rigidity and bradykinesia that are also present within this variant is diminished. A rare form of PSP is the PSP-FTD (PSP- Frontal Temporal Dementia). During this rare form of Progressive Supranuclear Palsy the patients develop dementia from early stages accompanied by changes in behavior and cognitive decline. Although the predominant feature is the dementia, the classic Richardson syndrome can manifest at later stages of the disease while L-Dopa treatment shows no effect. Although the distinct clinical variants of PSP are those mentioned above there are some other extremely rare cases of PSP that show PSP with Primary lateral sclerosis variants and PSP with Cerebellar variants. Typically, Primary sclerosis displays nuclear (bulbar) symptoms such as gait and movement spasticity and difficulties in ocular movements; however supranuclear palsy is generally non evident. There are studies that suggest some evident cases presenting with cerebellar ataxia symptoms that overlap with PSP, however these cases were found almost exclusively in Asian population [36].

Investigations for PSP

Despite the fact that Progressive Supranuclear Palsy is mostly diagnosed through clinical examination, diagnostic modalities such as MRI and other imaging techniques may reveal pathological abnormalities that differentiate PSP from other parkinsonian syndromes.

To begin with MRI imaging in PSP reveals atrophy at the region of midbrain and superior cerebellar peduncle. Specifically, there is the appearance of the "humming bird sign" or the "morning glory flower sign" also called "the mickey mouse sign" (Figure 2) in the sagittal view of the brainstem, however the sensitivity and specificity of these signs stands low at about 50 percent sensitivity and 70 percent specificity. Another diagnostic modality based on MRI that measures the Brain atrophy at the pathologic region is the midbrain to pons ratio which is markedly decreased compared to other types of parkinsonism. Moreover, another diagnostic implement which can be applied to assess the pathology in PSP is the DTI (Diffuse Tensor Imaging) a type of diffuse MRI technique in which white matter tracts can be visualized. During DTI white matter tracts are significantly reduced or disrupted in the region of thalamic nuclei especially the anterior and medial [37]. Likewise PET scan (Positron Emission Tomography)starts to be used for the detection of abnormalities associated with PSP indicating decreased metabolic activity in the region of midbrain and the "Papez circuit" (Circuit of neurons in the regions of the Thalamus, Caudate Nucleus, Cingulate gyrus, Frontal and Prefrontal Cortex) using specific ligands such as ^{18}F-T807/8 and ^{18}F-THK523 [38]. IBZM SPECT (Single Photon Emission Tomography) which is a CT based diagnostic imaging tool used for the detection of defects in atypical parkinsonism using [^{123}I]Iodobenzamide radiolabeled ligand that binds to cerebral Dopamine transporters with high specificity within the basal ganglia, appears to be normal in Parkinson's Disease and abnormal in atypical parkinsonism, however from this diagnostic tool it is difficult to differentiate PSP from other types of atypical parkinsonism such as MSA or CBD [39].

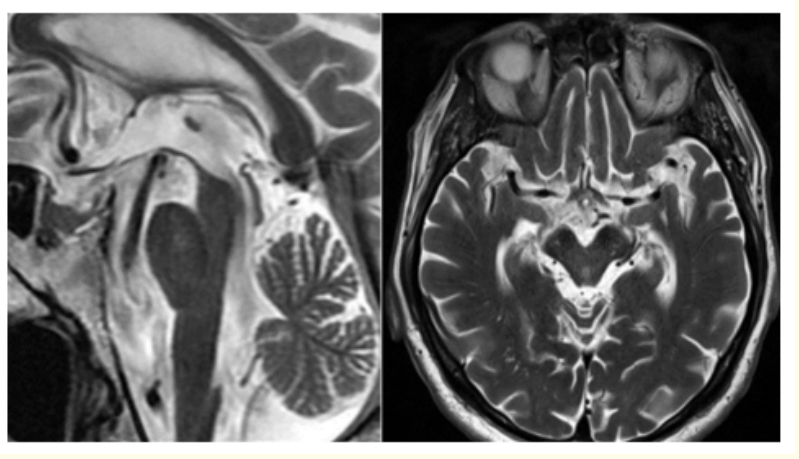

Figure 2: *On the left there is the hummingbird sign a pathognomonic feature of PSP showing pons atrophy and on the right there is the "Mickey Muse Sign" or the "Early Glory Flower Sign" indicating the Midbrain and ponsi atrophy at the region of the peduncles. From: https://radiopaedia.org.*

Treatment strategies for PSP

Up to date there are no known or effective treatment approaches available specifically for PSP therefore supportive treatment remains the only method for treating such patients. Levodopa with amantadine can be useful and neuroprotective; however there is limited or no response to the majority of the phenotypic variants of PSP especially in Richardson Syndrome. Botulinum toxin can be used to treat the painful and dystonic face and neck the blepharospasm and the eye apraxia during opening of the eyes. SSRIS (Selective Serotonin Reuptake Inhibitors) may be used for the treatment of depression, mood swings and anxiety however there is contradicting evidence showing that it may help or aggravate the apathy. Dementia and decreased cognition can be alleviated with acetylcholinesterase blockers such as rivastigmine nevertheless the benefit is only minimal. During recent studies concerning supplementing coenzyme Q10 for the protection of the neurons there is contradiction between the benefit and no benefit. Moreover, tideglusib a GSK3 inhibitor (glycogen synthase kinase 3) shows minimal benefit in reducing the brain atrophy. The main conclusion to be drawn regarding the treatment of PSP is that a more multidisciplinary approach needs to be applied in order to partially treat several clinical aspects such as physical therapy,

speech therapy, psychological support, psychiatry consultation and supervision, palliative care and other gastrointestinal procedures for the treatment of dysphagia [40].

Multiple systems atrophy

MSA is a progressive neurodegenerative disease pathologically involving different systems and regions of the brain that is characterized by features of Parkinsonism, pyramidal and cerebellar dysfunction and autonomic system failure. According to the system involved in the pathology of the disease MSA is categorized into three groups. While back in 1960 when it was first studied by researchers initially this disease was given different names according to the clinical outcome it presents such as Olivopontocerebellar atrophy with cerebellar and pyramidal signs, striatonigral degeneration with parkinsonian phenotypes and Shy Dragger Syndrome with autonomic failure signs. Moving forward it was later discovered that it is the same pathological entity that manifests at different regions of the brain henceforth the grouping and categorization [41]. The two distinct groups of Multiple Systems Atrophy are the MSA-P which manifests with Parkinsonian signs and symptoms and autonomic failure at presentation and MSA-C in which the cerebellar clinical features predominate [42]. On the epidemiological point of view MSA has a prevalence quite similar with the prevalence of PSP which is around 4 cases per 100.000 of population and normally the mean age of onset of the disease is around 50 years of age; while expression of such disease by people of less than 40 years of age is extremely uncommon. The mean survival time from the age of first presentation of symptoms is about 5 to 10 years and has a more insidious character than typical Parkinson's disease. In addition, MSA as an a-synucleinopathy was found to have a genetic component in some cases and that is the mutated COQ2 gene which is responsible for the metabolism and synthesis of Coenzyme Q10; however most of the cases are sporadic [43].

Clinical Features of MSA

MSA-P: MSA is characterized firstly with parkinsonian like symptoms such as hypokinetic rigidity; however there are some distinct clinical characteristics that can be used to separate these two disease entities. First of all the tremor in MSA is observed to be symmetric with increased frequency and decreased amplitude compared to PD, while a specific feature of the tremor is the jerky myoclonic movement that is initiated when stimulus is applied; therefore it is found to be caused by cortical dysfunction [44]. Likewise other Parkinsonian signs that come with MSA-P are the focal dystonia especially to the face and neck muscles that can be really painful, the speech dystonia causing dysarthria and phonation dysfunction, the dystonia of the trunk muscles giving the "Pisa sign" in which there is an obvious lateroflexion and the camptocormia in which there is anteroflexion of the torso. Severe dysphagia is also appears during the early stages of the disease and the dystonia and rigidity of neck and trunk muscles can cause laryngeal obstruction and hence stridor consequently leading to the need of a non-invasive mechanical ventilation apparatus [45].

MSA-C: The cerebellar type of Multiple systems atrophy, usually manifests parallel to the parkinsonian phenotype, however the gait ataxia prevails. Gait ataxia is accompanied by other symptoms such as decreased balance, wide gait, ataxia of the extremities, difficulties in speech with voice changes and oculomotor dysfunction involving nystagmus, jerky movements and irregular saccades [18].

Furthermore, along with the parkinsonian and cerebellar clinical aspects of MSA-P and MSA-C there are the autonomic features which make a crucial part for the diagnosis of MSA and originally described as the Shy Dragger Syndrome. The autonomic failure is generalized involving the cardiovascular, gastrointestinal, urogenital and respiratory systems. In almost half of the patients with MSA-P and MSA-C the autonomic features manifest earlier than the parkinsonian and cerebellar signs, making the clinical examination of the autonomic nervous system an essential predominant feature for the diagnosis of the disease. Most cases with autonomic dysfunction the urogenital symptoms appear first followed by the cardiovascular symptoms. Firstly, as an outcome of urogenital dysfunction is the impotence that affects both males with erectile dysfunction and females with decreased sexual arousal and function. Secondly bladder dysfunction may follow in the majority of cases with incomplete emptying, incontinence, decreased emptying and frequency with urgency. Thirdly the cardiovascular system comes into the symptomatology with orthostatic hypotension described by a fall of 30mmHg systolic pressure and 15mmhg diastolic pressure after 3 minutes of standing, syncope, and dizziness as a consequence of decreased perfusion within the brain. Notably the decreased perfusion to muscles causes "the coat hunger ache" which is the pain at the region of the neck and the shoulders. Other distinct features of the disease include sleep disturbances, apnea, pseudobulbar effect (described above in PSP section) and respiratory insufficiency [46]. The red flags of the disease are categorized in table 3.

MSA-P	MSA-C
Symmetrical onset	Cerebellar limb, gait ataxia
Rapid symptom progression	Early gait instability, falls
Jerky, myoclonic, postural/action tremor	Dysarthria (scanning, ataxic)
Contractures of hands and feet	Dysphagia
Anterocollis, axial dystonia (camptocormia ± lateral flexion, or Pisa syndrome)	Gaze impairment (hypo/hyperkinetic saccades)
Early gait difficulty, falls	Lower and upper motor neuron signs
Severe dysphonia, dysarthria	Emotionality, depression, anxiety
New/increased snoring, sleep apnea	Progressive dementia
Respiratory/laryngeal stridor	No family history of ataxia or parkinsonism
Hyperreflexia, Babinski's	
Pseudobulbar affect (emotional lability)	
Cold hands/feet	
Dysautonomia (69% vs 5% in PD)	
Poor/unsustained levodopa response (~30%)	
Orofacial dyskinesia/dystonia	

Table 3: *Distinct features and red flags of the Parkinsonian type MSA-P and the Cerebellar type MSA-C. McFarland NR. Diagnostic Approach to Atypical Parkinsonian Syndromes.*

Investigations

The most crucial diagnostic element is the cautious clinical examination of the patient. However, imaging techniques help in the diagnosing and differentiation of MSA form PD and other forms of atypical Parkinsonism. A distinctive feature in MRI imaging is the "hot cross bun sign", found in sagittal view of the brainstem that it is formed through the degeneration and atrophy of the pons and nearby regions such as the middle cerebellar peduncles and olivopontocerebellar degeneration (Figure 3). Additionally, the in T2 MRI imaging an obvious hypodense area is found within the basal ganglia especially the putamen with a hyperintense rim like region indicating atrophic erosion and iron deposits respectively (Figure 3) [47]. Functional MRI indicates atrophy within the striatum. Regarding other imaging modalities such as SPECT, PET and DAR scan, utilization of 125I-ioflupanea radiolabeled ligand with high affinity for presynaptic dopamine receptors and transporters, demonstrates defect metabolism within the basal ganglia. However, it is difficult to distinguish between the parkinsonian syndromes as they all show the defect of dopamine transportation [48]. A different diagnostic modality can be the scintigraphy using the ^{123}I-metaiodobenzylguanidine (MIBG) neurotransmitter which is a radiopharmacon and an analog of noradrenaline and adrenaline and can be up taken by the sympathetic neurons, while successively aids with the visualization of neurons in the heart. Subsequently it is a valuable technique that is used to distinguish Parkinson's disease from MSA whereas in Parkinson's disease there is marked reduction in the uptake of MIBG within the sympathetic neurons of the heart due to postganglionic denervation that is seen in PD patients. Dopamine is the second step in the process of biosynthesis of noradrenaline. Other tests that can be useful in assessing the orthostatic hypotension feature of MSA is the 24-hour ambulatory test of blood pressure. Urodynamic studies indicate urine bladder dysfunction and impotence test for sexual dysfunction in men. Likewise there are some cerebrospinal fluid? (CSF) markers that can be useful such as a-synuclein, Ab42 (amyloid marker) and Fit3 ligand (neurotropic factor) but their sensitivity and specificity remains controversial [48].

Treatment of MSA

Just like Progressive Supranuclear Palsy treatment for MSA needs a multidisciplinary approach aiding in rehabilitation and support. Consequently, there is not an effective treatment for MSA yet; making the use of supportive treatment measures the only solution.

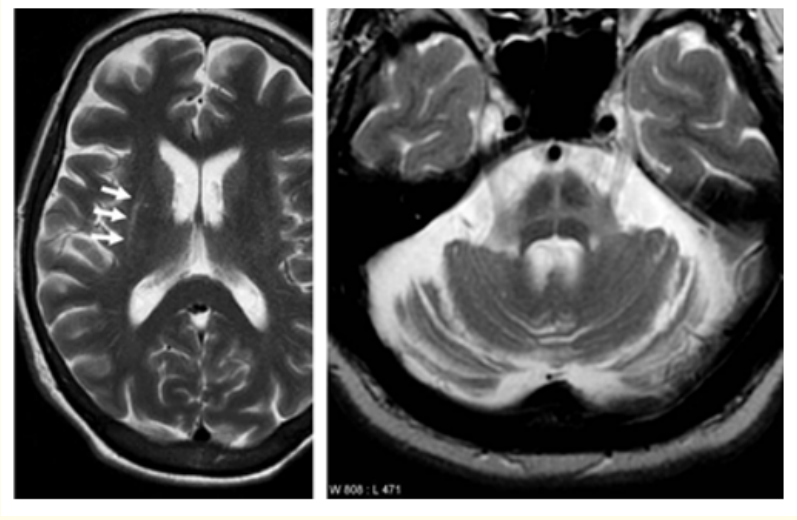

Figure 3: *On the left the rim like region is evident suggesting iron deposition paired with atrophy. On the right there is the hot cross bun sign which shows the degeneration and atrophy of the pons. From: https://radiopaedia.org.*

However up to one third of patients that predominantly express the parkinsonian feature administration of high dose of levodopa (1000 mg 3 times a day) can have a modest effect. Successively, the use of dopamine agonists might be of use in the parkinsonian type MSA, nevertheless their potency is much lower than levodopa [50]. There is no specific treatment for the orthostatic hypotension and only supporting measures can be used to alleviate the severity such hydration, increased salt intake, and compression aids such as stockings. Another smart way to counteract the decreased blood pressure is through the use of hydrocortisone (up to 3g per day) which increases the water retention and subsequently the blood volume. Other pharmacologic agents that can be used to treat hypotension including an a1 agonist of the blood vessels such as midodrine, pyridostigmine (acetylcholinesterase blocker) and droxidopa (noradrenaline precursor which crosses the Blood Brain Barrier). Antispasmodics such as oxybutynin reduces the symptoms of the defective or neurogenic bladder, however botulinum toxin is frequently used with success. Erectile dysfunction in men can be treated with sildenafil, however its use is contradictive due to the fact that it lowers the blood pressure ever further therefore other strategies such as intrapenile injections of alprostadil or implantation of penile expanders can have an effect [49].

Dementia with lewy body

Dementia with Lewy Bodies is characterized by progressive degeneration of nerves involved in memory and cognition. It is currently the second leading cause of dementia (first leading cause is the Alzheimer's Disease) and shares similar features with Parkinson's disease, however the dementia predominates. Usually symptoms start after the age of 50 and the progression of dementia is fast with an incidence of 0.1 to 0.2 percent each year and prevalence of 0.4% [27].

Clinical features of LBD

The symptomatology of the disease is described by first of all highly progressive dementia which is followed by some of the parkinsonian features such as akinetic rigid movements and tremor. Secondly there is a marked reduced in cognition that is fluctuating over the day with a general decline as the disease progresses and it is usually accompanied by decreased awareness and alertness. Thirdly a common clinical feature in patients with LBD is the visual hallucination of a periodic character. Some other clinical symptoms that can overlap with other forms of atypical Parkinsonism are the gait imbalance associated with falls which is commonly seen in PSP and orthostatic hypotension which is seen in MSA along with neuropsychiatric features such as delusive paranoia. Stressing enough is the fact that the use of neuroleptics can worsen the symptoms of MSA in half of the patients [27].

Investigations

Diagnosis of Dementia with Lewy Body has a strong clinical examination background however other investigation means can have a crucial part in the proper diagnosis. MRI imaging can show a general neurodegeneration and atrophy within the basal ganglia and at the region of the thalamus while the main distinction from Alzheimer's disease is that the atrophy remains diffusely within the caudate nucleus, putamen and thalamus while in AD the atrophy involves mostly the cortex and mainly the mesotemporal lobes while the occipital lobe is preserved. Other functional imaging techniques using ^{123}I-FP-CIT SPECT for the visualization of the dopamine transporters and ^{18}F-FDG PET for accessing the metabolism and uptake glucose within the brain parenchyma demonstrate a general dopaminergic deficit, hypo perfusion and areas of decreased metabolism especially within the occipital lobe and visual cortex making the differential diagnosis between Alzheimer's Disease and Dementia with Lewy Bodies. Notably there is also β-amyloid deposition in some areas which is the major pathognomonic feature of AD, however the amount of β-amyloid deposition is markedly lower than in AD. Other tests can be performed in the clinical setting involving drawing test which shows decreased visuospatial performance [51].

Therapeutic strategies

Unlike the other parkinsonian syndromes that show no to limited response to levodopa, in Dementia with Lewy Body administration of L-DOPA demonstrates good response, yet its use remains controversial due to the fact that it exacerbates neuropsychiatric aspects of the diseases such as psychosis, delusions and hallucinations. Therefore, during treatment all three aspects of the disease need to take up into consideration including the dementia with the cognitive decline, the Parkinsonism with the akinetic rigid syndrome and the psychosis with delusions and hallucinations [52]. The dopaminergic activating properties of dopamine agonists at the prefrontal cortex, the basal ganglia and the Limbic system negatively influences the psychotic aspects of the disease therefore the use of dopamine agonists or their non-dopaminergic counterparts such as monoamine oxidase inhibitors, Acetylcholine antagonists or amantadine which increase the potential of psychosis, cognitive decline, dementia and confusion need to be avoided [52]. Nevertheless, pharmacological management of the neuropsychiatric aspects of the disease once levodopa is administered for the control of the motor symptoms is firstly reduce the levodopa or any other dopamine activating agent. Then, atypical antipsychotics can be used such as quetiapine (Dopamine receptor antagonist, serotonin receptor agonist and minor antagonist, acetylcholine receptor antagonist). Moreover clozapine can be used for the treatment of psychosis and hallucinations which binds to serotonin receptors and dopamine receptors of the brain consequently increases their concentration. However, its use need to be quite monitored for adverse side effects such as agranulocytosis of blood and decreased blood pressure especially orthostatic hypotension [53].

Corticobasal degeneration

Corticobasal degeneration or corticobasal syndrome is a sporadic tauopathy and not a-synucleinopathy as the majority of parkinsonian disorder which usually presents on its own or as a consequence of other diseases such as Alzheimer's disease or Progressive Supranuclear Palsy (as mentioned above). Pure Corticobasal syndrome is a very rare disease which manifests as asymmetric parkinsonism (tremor, Bradykinesia, stiffness) which is levodopa resistant accompanied by dystonia, general apraxia, aphasia, decreased sensory inputs from cortex, alien limb, decreased language functionality with dysarthria and dysphagia, frontotemporal dementia and myoclonic phenomena [54]. The average prognosis from the first manifestation of symptoms is up to 8 years and usually affects people above the age of 60 with a prevalence of 5 to 7 people per 100.000 of population [55].

Clinical features of CBD

Clinically Corticobasal degeneration is described by asymmetric Parkinsonism like bradykinesia, dystonia and rigidity usually implicating only one limb and later progresses to other parts complemented by myoclonus [56]. The alien limb phenomenon is evident as it is slightly elevated and uncoordinated and it is explained by patients as it has its own mind and it acts autonomously from the rest of the body. Sometimes that affected limb can be described as useless or paralyzed. Ideomotor apraxia is another district clinical feature of the disease in which the patient finds hard time to initiate a controlled task involving planning skills, language organization, sensory inputs and motor outcome therefore the patient is incapable of following and mimicking some tasks or gestures such as showing signs with their hands. Moreover, frontotemporal dementia manifests later in the disease and majorly the episodic memory is unaffected during the early stages of dementia as opposed to the Alzheimer's disease. Impaired cortical sensation is often seen when the patient loses the ability of stereognosis or two point discrimination point [57].

Investigations

The best investigation tool for the diagnosis of CBD is the combination of a careful neurologic examination and imaging techniques. Likewise, the standard imaging modalities such as MRI or CT can reveal findings of general atrophy within the frontal and parietal lobes. Interestingly enough, other functional imaging modalities can be more specific to findings. PET scan using [F18]fluorodeoxyglucose indicates decreased usage and metabolism of the probe ([F18]fluorodeoxyglucose) by the cortical centers of the brain especially frontal, while PET scan using [^{18}F]dopa (dopamine probe) and ^{*123}I+β-CIT (dopamine transporter ligand) DAT scan show dopaminergic loss of neurons within the basal ganglia that follow an asymmetric manner [39].

Treatment

CBD although a disease that responds majorly to supportive measures, it shows some alleviation of symptoms with levodopa administration (1g per day). Other pharmacological agents that can be used to supportively control the symptoms of the disease especially the parkinsonian phenotype are the amantadine and valproate or levetiracetam for the control of myoclonic episodes. In addition, muscle relaxants such as baclofen and botulinum toxin can have good outcomes when the patient presents with marked rigidity and reduced functionality of movements due to stiffness [58]. However, supporting measures using a multidisciplinary approach need to be taken into consideration such as physical therapy, physical exercise, speech and language therapy and psychological support.

Conclusion

For many years atypical Parkinsonism remains a challenge between physicians and neurologists due to the diagnostic challenges that arise in distinguishing between the different clinical variations of the disease. While the majority of the diseases described as parkinsonian diseases have no specific markers either in blood or CSF and the imaging techniques have low specificity due to the common clinicopathological background that describe such clinical entities, puts the majority of stressing effort to the clinical diagnosis through careful neurological examination. Nevertheless, imaging techniques might assist to the diagnosis and differential diagnosis only if it is combined with the clinical examination.

Atypical parkinsonism as the name denotes includes all the diseases that share a common clinical feature which is the parkinsonian phenotype described by tremor, rigidity and bradykinesia along with some other complementary symptoms. Subsequently, they share similar pathological background within the brain and according to the region affected each disease separately develops distinct features. Furthermore, these distinct features between atypical Parkinsonism can be used as red flags in neurological examination in order for the proper diagnosis. Although clinical criteria have been proposed previously in order to separate and categorize each disease based on clinical phenotype, their application to practice is difficult because of the overlap of symptoms that the atypical parkinsonian diseases share. Likewise the common treatment strategies that apply to Parkinson's Disease although supportive show minimal response when applied to atypical parkinsonian syndromes or they even cause more harm than good (i.e. corticobasal degeneration) therefore it is highly crucial to establish a correct diagnosis first and then proceed with the disease treatment with a plan that only assists in the management of the specific disorder. Even though there is some disease biomarkers for example α-synuclein for the majority of parkinsonian syndromes and fit3 ligand for Multiple Systems Atrophy their use is often non-specific making the future directions for the differential diagnosis of atypical Parkinsonism to help in the development of diseases specific biomarkers.

Acknowledgments

Special thanks to my supervisor Professor Dr. Ioannis Patrikios Chairperson of the EUC School of Medicine who supported me through this research study. I would also like to thank my anatomy teacher and Dean of the EUC School of Medicine Professor Elizabeth Johnson that gave me all the necessary information about the anatomical perspective of the brain, Professor Dr. Kyriakides Theodoros for his guidance on material selection in relation to the neurological examination and treatment of the syndromes discussed in the current study and Professor Dr. Anastasios Stefanou as well as Professor Dr Xanthos Theodoros for their guidance during writing of this study.

Bibliography

1. Mirpour S., *et al*. "Impact of DAT-SPECT on Management of Patients Suspected of Parkinsonism". *Clinical Nuclear Medicine* 43.10 (2018): 710-714.

2. Odin P., *et al*. "Emergent Functional Network Effects in Parkinson Disease". *Cerebral Cortex* (2018).

3. Rogers G., *et al*. "Parkinson's disease: summary of updated NICE guidance". *BMJ* 27.358 (2017): j1951.

4. Jankovic J. "Parkinson's disease: clinical features and diagnosis". *Journal of Neurology,Neurosurgery and Psychiatry* 79.4 (2018): 368-376.

5. GBD Disease Injury Incidence Prevalence Collaborators. "Global, regional, and national incidence, prevalence, and years lived with disability for 310 diseases and injuries, 1990-2015: a systematic analysis for the Global Burden of Disease Study 2015". *Lancet* 388.10053 (2016): 1545-1602.

6. Chung SJ., *et al*. "The Pattern of Striatal Dopamine Depletion as a Prognostic Marker in De Novo Parkinson Disease". *Clinical Nuclear Medicine* 43.11 (2018): 787-792.

7. The National Collaborating Centre for Chronic Conditions. Diagnosing Parkinson's Disease. Parkinson's Disease. London: Royal College of Physicians (2006): 29-47.

8. Hornykiewicz O. "L-DOPA: from a biologically inactive amino acid to a successful therapeutic agent". *Amino Acids* 23.1-3 (2002): 65-70.

9. Rosenquist PB., *et al*. "When All Else Fails: The Use of Electroconvulsive Therapy for Conditions Other than Major Depressive Episode". *Psychiatric Clinics of North America* 41.3 (2018): 355-371.

10. Caparros-Lefebvre D., *et al*. "Guadeloupean parkinsonism: a cluster of progressive supranuclear palsy-like tauopathy". *Brain* 125 (2002): 801-811.

11. Golbe LI., *et al*. "Follow-up study of risk factors in progressive supranuclear palsy". *Neurology* 47.1 (1996): 148-154.

12. Respondek G., *et al*. "The phenotypic spectrum of progressive supranuclear palsy: a retrospective multicenter study of 100 definite cases". *Movement Disorders* 29.14 (2014): 1758-1766.

13. Dickson DW., *et al*. "Neuropathology of variants of progressive supranuclear palsy". *Current Opinion in Neurology* 23.4 (2010): 394-400.

14. Boeve BF. "Progressive supranuclear palsy". *Parkinsonism and Related Disorders* 18.1 (2012): S192-194.

15. Wenning GK., *et al*. "Multiple system atrophy: a review of 203 pathologically proven cases". *Movement Disorders* 12 (1997): 133-147.

16. Kisos H., *et al*. "Increased neuronal alpha-synuclein pathology associates with its accumulation in oligodendrocytes in mice modeling alpha-synucleinopathies". PLoS ONE 7.10 (2012): e46817.

17. Kollensperger M., *et al*. "Presentation, diagnosis, and management of multiple system atrophy in Europe: final analysis of the European multiple system atrophy registry". *Movement Disorders* 25 (2010): 2604-2612.

18. Papp MI., *et al*. "Glial cytoplasmic inclusions in the CNS of patients with multiple system atrophy (striatonigral degeneration, olivopontocerebellar atrophy and Shy-Drager syndrome)". *Journal of the Neurological Sciences* 94 (1989): 79-100.

19. Geser F., *et al*. "The European Multiple System Atrophy-Study Group (EMSA-SG)". *Journal of Neural Transmission* 112 (2005): 1677-1686.

20. Gilman S., *et al*. "Consensus statement on the diagnosis of multiple system atrophy. American Autonomic Society and American Academy of Neurology". *Clinical Autonomic Research* 8 (1998): 359-362.

21. Chin KS., *et al*. "Dementia with Lewy bodies: Challenges in the diagnosis and management". *Australian and New Zealand Journal of Psychiatry* Apr 53.4 (2019): 291-303.

22. Chen X., *et al*. "Parkinson's disease-linked D620N VPS35 knock in mice manifest tau neuropathology and dopaminergic neurodegeneration". *Proceedings of the National Academy of Sciences USA* 19 116.12 (2019): 5765-5577.

23. Brenowitz WD., *et al*. "Alzheimer's disease neuropathologic change, Lewy body disease, and vascular brain injury in clinic- and community-based samples". *Neurobiology of Aging* 53 (2017): 83-92.

24. Hogan DB., *et al*. "The prevalence and incidence of dementia with Lewy bodies: a systematic review". *Canadian Journal of Neurological Sciences* 43.Suppl 1 (2016): S83-95.

25. Hofmann W., *et al*. "Guideline-conform exact diagnosis and coding of dementia". *Zeitschrift für Gerontologie und Geriatrie* 52.2 (2019): 179-194.

26. McKeith IG., *et al*. "Consortium on DLB: Diagnosis and management of dementia with Lewy bodies: third report of the DLB Consortium". *Neurology* 65 (2005): 1863-1872.

27. Bower J., *et al*. "Incidence of progressive supranuclear palsy and multiple system atrophy in Olmsted County, Minnesota 1976 to 1990". *Neurology* 49 (1997): 1284-1288.

28. Josephs KA and Dickson DW. "Diagnostic accuracy of progressive supranuclear palsy in the Society for Progressive Supranuclear Palsy brain bank". *Movement Disorders* 18 (2003): 1018-1026.

29. Litvan I., *et al*. "Clinical research criteria for the diagnosis of progressive supranuclear palsy (Steele-Richardson- Olszewski syndrome): report of the NINDS-SPSP international workshop". *Neurology* 47 (1996): 1-9.

30. Batla A., *et al*. "Vertical wrinkling of the forehead or procerus sign in progressive supranuclear palsy". *Journal of the Neurological Sciences* 298.1-2 (2010): 148-149.

31. Strowd RE., *et al*. "Pseudobulbar affect: prevalence and quality of life impact in movement disorders". *Journal of Neurology* 257 (2010): 1382-1387.

32. Kanazawa M., *et al*. "Cerebellar involvement in progressive supranuclear palsy: a clinicopathological study". *Movement Disorders* 24.9 (2009): 1312-1318.

33. Williams DR and Lees AJ. "Progressive supranuclear palsy: clinicopathological concepts and diagnostic challenges". *Lancet Neurology* 8 (2009): 270-279.

34. Williams DR., *et al*. "Pure akinesia with gait freezing: a third clinical phenotype of progressive supranuclear palsy". *Movement Disorders* 22.15 (2007): 2235-2241.

35. Kertesz A and McMonagle P. "Behavior and cognition in corticobasal degeneration and progressive supranuclear palsy". *Journal of the Neurological Sciences* 15. 289 (2010): 138-143.

36. Kanazawa M., *et al*. "Cerebellar involvement in progressive supranuclear palsy: a clinicopathological study". *Movement Disorders* 24.9 (2009): 1312-1318.

37. Whitwell JL., *et al*. "Disrupted thalamocortical connectivity in PSP: a resting-state fMRI, DTI, and VBM study". *Parkinsonism & Related Disorders* 17.8 (2011): 599-605.

38. Beyer L., *et al*. "Clinical Routine FDG-PET Imaging of Suspected Progressive Supranuclear Palsy and Corticobasal Degeneration: A Gatekeeper for Subsequent Tau-PET Imaging?" *Frontiers in Neurology* 9 (2018): 483.

39. Hellwiga Sabine., *et al*. "*^{18}F+FDG-PET is superior to *^{123}I+IBZM-SPECT for the differential diagnosis of parkinsonism." *Neurology* 79.13 (2012): 1314-1322.

40. Stamelou M., *et al*. "Rational therapeutic approaches to progressive supranuclear palsy". *Brain* 133 (2010): 1578-1590.

41. Gilman S., *et al*. "Second consensus statement on the diagnosis of multiple system atrophy". *Neurology* 71 (2008): 670-676.

42. Ahmed Z., *et al*. "The neuropathology, pathophysiology and genetics of multiple system atrophy". *Neuropathology and Applied Neurobiology* 38 (2012): 4-24.

43. Multiple-System Atrophy Research Collaboration. "Mutations in COQ2 in familial and sporadic multiple-system atrophy". *New England Journal of Medicine* 369 (2013): 233-244.

44. Batla A., *et al*. "Markedly asymmetric presentation in multiple system atrophy". *Parkinsonism and Related Disorders* 19 (2013): 901-905.

45. Kollensperger M., *et al*. "Red flags for multiple system atrophy". *Movement Disorders* 23 (2008): 1093-1099.

46. Kimpinski K., *et al*. "The role of autonomic testing in the differentiation of Parkinson's disease from multiple system atrophy". *Journal of the Neurological Sciences* 317 (2012): 92-96.

47. Han YH., *et al*. "Topographical differences of brain iron deposition between progressive supranuclear palsy and parkinsonian variant multiple system atrophy". *Journal of the Neurological Sciences* 325 (2013): 29-35.

48. Bajaj N., *et al*. "Clinical utility of dopamine transporter single photon emission CT (DaT-SPECT) with (123I) ioflupane in diagnosis of parkinsonian syndromes". *Journal of Neurology, Neurosurgery, and Psychiatry* 84.11 (2013): 1288-1295.

49. Perez-Lloret S., *et al*. "Current Concepts in the Treatment of Multiple System Atrophy". *Movement Disorders Clinical Practice* 2.1 (2015): 6-16.

50. Constantinescu R., *et al*. "Levodopa responsiveness in disorders with parkinsonism: a review of the literature". *Movement Disorders* 22 (2007): 2141-2148.

51. Whitwell JL., *et al*. "Focal atrophy in dementia with Lewy bodies on MRI: a distinct pattern from Alzheimer's disease". *Brain* 130 (2007): 708-719.

52. Gomperts SN. "Lewy Body Dementias: Dementia With Lewy Bodies and Parkinson Disease Dementia". *Continuum (Minneap Minn)* 22.2 (2016): 435- 463.

53. Hack N., *et al*. "An eight-year clinic experience with clozapine use in a Parkinson's disease clinic setting". *PloS one* 9 (2014): e91545.

54. Wenning GK., *et al*. "Natural history and survival of 14 patients with corticobasal degeneration confirmed at postmortem examination". *Journal of Neurology, Neurosurgery, and Psychiatry* 64 (1998): 184-189.

55. Mahapatra., *et al*. "Corticobasal degeneration". *The Lancet Neurology* 3.12 (2004): 736-743.

56. Armstrong MJ., *et al*. "Criteria for the diagnosis of corticobasal degeneration". *Neurology* 80 (2013): 496-503.

57. Kouri N., *et al*. "Neuropathological features of corticobasal degeneration presenting as corticobasal syndrome or Richardson syndrome". *Brain* 134 (2011): 3264-3275.

58. Stamelou M and Hoeglinger GU. "Atypical parkinsonism: an update". *Current Opinion in Neurology* 26 (2013): 401-415.

59. Quinn N. "Multiple system atrophy—the nature of the beast". *Journal of Neurology, Neurosurgery, and Psychiatry* (1989): 78-89.

60. Bayer TA. "Proteinopathies, a core concept for understanding and ultimately treating degenerative disorders?". *European Neuropsychopharmacology* (2013).

61. Jankovic J and Lang AE. "Movement disorders: diagnosis and assessment". In: Bradley WG, Daroff RB, Fenichel GM, Jankovic J, editors. Neurology in clinical practice. 5th edition Philadelphia, PA: Saunders (2008).

62. Lippa CF., *et al*. "DLB and PDD boundary issues: diagnosis, treatment, molecular pathology, and biomarkers". *Neurology* 68.11 (2007): 812-819.

63. Williams DR and Litvan I. "Parkinsonian syndromes". *Continuum* 19 (2013): 1189-1212.

64. Dickson DW. "Parkinson's disease and parkinsonism: neuropathology". *Cold Spring Harbor Perspectives in Medicine* 2.8 (2012): a009258.

Volume 11 Issue 12 December 2019
©All rights reserved by George Christophides and Ioannis Patrikios.