

Corpus Callosum Lipoma with Extracranial Extension Associated with Seizure

Bipin Chaurasia^{1*}, Dhiman Chowdhury¹, Ranjit Kumar Chaurasiya¹, Kanak Kanti Barua¹, Raushan Kumar Chaurasia² and Ramesh Chaurasia²

¹Department of Neurosurgery, Bangabandhu Sheikh Mujib Medical University, Shahbag, Dhaka, Bangladesh

²Birgunj Health Care Hospital, Birgunj, Nepal

***Corresponding Author:** Bipin chaurasia, Department of Neurosurgery, Bangabandhu Sheikh Mujib Medical University, Shahbag, Dhaka, Bangladesh.

Received: April 24, 2019; **Published:** May 27, 2019

Abstract

Intracranial lipoma is a congenital anomaly usually found incidentally. Pericallosal lipoma with extension into extracranial tissue through interhemispheric structures are not common and when this occurs, it is usually accompanied by other intracranial malformations. We discuss this rare case having corpus callosal lipoma with subcutaneous lipoma, a tubulonodular type, manifesting as a seizure in adulthood. Due to extra morbidity after surgery, we planned to follow up the patient's with conservative management.

Keywords: Intracranial Lipoma; Extracranial Extension; Seizure

Introduction

Intracranial lipoma is a congenital benign lesion which constitute about 0.1% of all intracranial tumors. It is thought to arise either from lipid cells of pia mater or fatty transformation of connective tissue or from embryonal remnants or from dedifferentiation of the meninx primitive to lipomatous tissue. Most of them are associated with congenital malformations. It is very rarely associated with extracranial extension [1-3]. We report a case of 31 year-old male who was referred from remote village hospital with the complaint of occasional seizures. We diagnosed the case as corpus callosum lipoma with extension into subcutaneous tissue. We will highlight here brief description of the rare case, image findings and our management strategy.

Case Report

A 31 year-old male farmer came to our hospital with the complaint of slow growing scalp swelling and on and off headache since birth and the occasional seizure for 2 months. Headache used to be mild and controls with analgesics so he didn't consult the doctor before. During the last 2 months, he had tonic clonic seizure twice in a month. There was history of brief loss of consciousness associated with seizure. There was no history of congenital anomalies within the family. General physical examination of patient revealed a subcutaneous non mobile swelling of size 10 x 15 cm was present in the frontoparietal region it was in midline, rubbery and devoid of hairs. The swelling was also extended in the forehead. Neurological examination including funduscopic examination revealed normal findings. There was no sign of facial anomalies. Laboratory data were noncontributory.

We did MRI of brain which showed there was huge lesion in the callosal, pericallosal and supracallosal region extending into subgaleal region through a defect in the frontal bone. The lesion was hyperintense in both T1W and T2W images which was sufficient for diagnosis (Figure a-e). DWI showed no restriction of diffusion. Posterior part of body and splenium of corpus callosum were absent suggestive of agenesis of corpus callosum. Lateral ventricles were also invaded by the lesions.

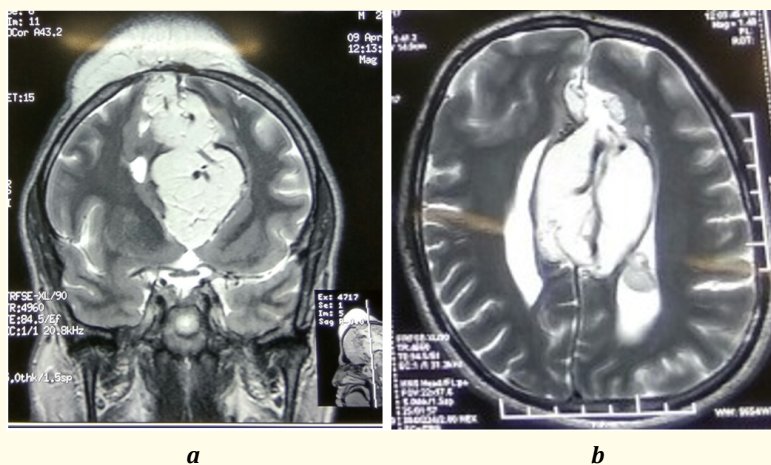


Figure a and b: T2WI image showing huge hyperintense lipoma with extracranial extension.

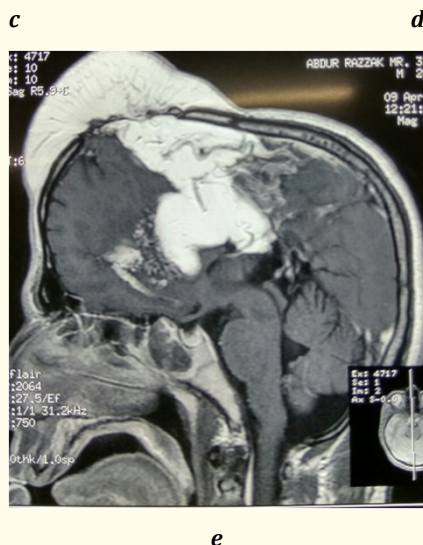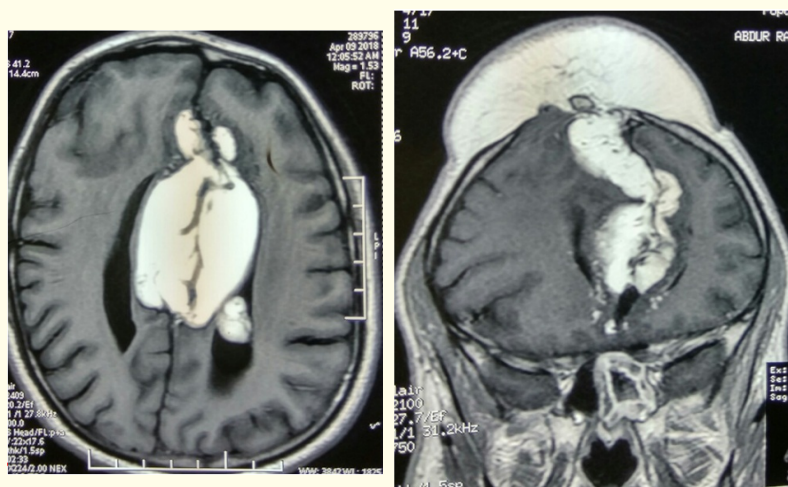


Figure c-e: Showing T1WI image which is hyperintense and absence of corpus callosum.

After our diagnosis was confirmed we called a meeting of all neurosurgeons in our hospital for individual views regarding the management. We concluded that the subcutaneous scalp swelling can be removed for cosmetic purposes. For intracranial part we decided not to touch as aggressive gross total removal may cause additional morbidity to patient and the seizure for which patient seek treatment may not subside seeing the location of lesion. So we decided to follow up the patient with anticonvulsants and occasional use of analgesics for headache. We clearly described the pros and cons of surgery to the patient. He didn't agree to go through surgical interventions. Ultimately, we prescribed anticonvulsants and analgesics.

Discussion

Intracranial lipoma constitutes about 0.06 - 0.46% of intracranial lesions which is usually discovered incidentally. It is thought to be a congenital malformation and are generally asymptomatic. The most common manifestations are headache, seizures and raised intracranial pressure [1,2,4-6]. The most common locations are interhemispheric fissure, corpus callosum, quadrigeminal- ambient cistern, infundibular chiasmatic region, cerebellopontine angle and sylvian fissure [1,2]. Pericallosal lipoma constitute about half of all intracranial lipoma and is usually associated with agenesis of corpus callosum similar to our case. It may extend to interhemispheric fissure connecting to extracranial tissue, may extend into ventricles or may be associated with frontonasal dysplasia [6,7].

Interhemispheric lipoma has 2 types. Tubulonodular type is anteriorly located, larger, occurs before closure of anterior neuropore and is associated with agenesis of corpus callosum, calcifications and frontal bone defect whereas curvilinear type occurs posteriorly and is thin and not associated with cerebral anomalies [7,8].

Pericallosal interhemispheric lipoma may have extracranial connection through fibrous-lipomatous stalk or direct connection through cranium bifidum or mayn't have connection between extracranial intracranial parts.it is thought that this connection may result from secondary dehiscence of cranium with invagination of small tuft to meninx primitive [5]. Some of the published cases having intracranial lipoma with extension into extracranial has been summarized in table 1.

Case	Age	Sex	Symptoms				
Kinal., <i>et al.</i> (1951)	3 months	M	Midfrontal tumor				
Cant., <i>et al.</i> (1952)	5 years	M	Frontal swelling, seizures				
Kuwabara., <i>et al.</i> (1963)	17 years	F	Ocular hypertelorism, forehead swelling				
Addlestone., <i>et al.</i> (1974)	4 months	M	Forehead swelling				
Kushnet., <i>et al.</i> (1978)	64 years	F	Convulsions, forehead swelling saddle nose deformity				
Hyashi., <i>et al.</i> (1980)	3 yrs	F	Ocular hypertelorism				
Kudoh., <i>et al.</i> (1983)	3 Months	F	Swelling in forehead, hypertelorism				
a.sari., <i>et al.</i> [9] (1998)	3 months	M	Swelling over anterior fontanelle				
Chen., <i>et al.</i> [6] (2004)	newborn	M	Swelling over vertex				
Given., <i>et al.</i> [2] (2005)	9 weeks	M	Anterior fontanelle mass				
Ahmetoglu., <i>et al.</i> [5] (2007)	5 months	F	Midline parietal mass				
Reddy., <i>et al.</i> [4] (2012)	13 yrs	M	Occipital swelling				
Karabag., <i>et al.</i> [8] (2014)	26 yrs	F	Vertex scalp swelling				
Rai., <i>et al.</i> [7] (2015)	40 yrs	M	Forehead swelling				
Aggrawal., <i>et al.</i> [10] ¹⁰ (2018)	22 yrs	F	<table border="1" style="display: inline-table; vertical-align: middle;"> <tr> <td style="width: 20px; height: 20px;"></td> <td style="width: 20px; height: 20px;"></td> <td style="width: 20px; height: 20px;"></td> <td style="width: 20px; height: 20px;"></td> </tr> </table> Scalp swelling				
Chaurasia., <i>et al.</i> 2019	31 yrs	M	seizure				
Current case							

Table 1: Several Cases of intracranial lipoma with extension into extracranial [3].

MRI is superior to all imaging modalities over diagnosis of intracranial lipoma having characteristics hyper intensity in both T1W and T2W image and defining relationship to the surrounding structures [9].

Treatment is usually not required as many patients are asymptomatic which can be followed with observation. Some have symptoms of raised intracranial pressure, seizures and cosmetic deformity which may necessitate interventions, surgical excision of scalp lesion may be achieved for cosmetic lesions but at that time the cranial gap should be obliterated with pericranium to avoid recurrence. Due to very dense adhesions of lipoma to surrounding structures intracranial parts should not be usually removed to minimize morbidity and mortality [4].

Conclusion

In conclusions seeing the nature of this huge lesion conservative management with anticonvulsants and analgesics are sufficient to satisfy the patient. It also avoids morbidity due to surgical damage to the intracranial vessels and surroundings vital structures which are tightly adhered to the lipoma. The rarity of this disease and the huge size (10 x 15 cm) compelled us to report this case for future learnings. None of the cases described in the literature report a larger size than our case.

Bibliography

1. Chaurasia BK, et al. "A rare case of quadrigeminal plate lipoma presenting with the sixth cranial nerve palsy". *Neuroimmunology and Neuroinflammation* 4 (2017): 232-235.
2. Given CA, et al. "Interhemispheric lipoma connected to subcutaneous lipoma via lipomatous stalk". *Pediatric Radiology* 35.11 (2005): 1110-1112.
3. Kudoh H, et al. "Lipomas in the corpus callosum and the forehead, associated with a frontal bone defect". *Surgical Neurology* 22.5 (1984): 503-508.
4. Reddy SR, et al. "Intracranial lipoma with subgaleal extension: An interesting case report with review of literature". *Neurology India* 60.4 (2012): 444-446.
5. Ahmetoğlu A, et al. "Intracranial and subcutaneous lipoma associated with sagittal sinus fenestration and falcine sinus". *American Journal of Neuroradiology* 28.6 (2007): 1034-1035.
6. Chen CF, et al. "Posterior pericallosal lipoma extending through the interhemispheric fissure into the scalp via the anterior fontanelle". *Neuroradiology* 46.8 (2004): 692-695.
7. Rai S, et al. "Corpus callosal lipoma with extracranial extension as a scalp swelling". *Neurology India* 63.5 (2015): 796-797.
8. Karabag H, et al. "Pericallosal lipoma associated with subcutaneous lipoma in an adult". *Journal of Neurosciences in Rural Practice* 15.1 (2014): 91-93.
9. Sari A, et al. "Interhemispheric lipoma associated with subcutaneous lipoma". *European Radiology* 8.4 (1998): 628-630.
10. Aggarwal N, et al. "Frontal subcutaneous lipoma associated with interhemispheric lipoma, lipomeningocele, and corpus callosal dysgenesis in a young adult: CT and MRI findings". *The Indian Journal of Radiology and Imaging* 28.1 (2018): 22-26.

Volume 11 Issue 6 June 2019

©All rights reserved by Bipin Chaurasia.