ECRONICON OPEN ACCESS

EC NEUROLOGY
Case Report

Atypical Case of Takotsubo Syndrome in an Elderly Woman

Mark B Detweiler[1,2,3]*, Jonna G Detweiler[3] and Geoffrey M Bader[1,3,4,5]

[1]*Staff Psychiatrist, Veterans Affairs Medical Center, Salem, Virginia, USA*

[2]*Department of Psychiatry, Edward Via College of Osteopathic Medicine, Blacksburg, Virginia, USA*

[3]*Geriatric Research Group, Department of Psychiatry, Veterans Affairs Medical Center, Salem, Virginia, USA*

[4]*Chief Consult Liaison Service, Department of Psychiatry, Veterans Affairs Medical Center, Salem, Virginia, USA*

[5]*Virginia Tech-Carilion Psychiatry Residency Program, Roanoke, Virginia, USA*

***Corresponding Author:** Mark B Detweiler, Staff Psychiatrist, Veterans Affairs Medical Center, Salem, Virginia, USA.

E- mail: mark.detweiler1@va.gov

Received: December 16, 2018; **Published:** February 27, 2019

Abstract

The case of a 69 year old female reporting to the mental health clinic with complaints of depression, anxiety, anhedonia, fatigue and bilateral lower leg swelling is presented. Her case is complicated by a multitude of comorbid chronic medical and psychosocial issues. The differential diagnosis is discussed as the case was resolved with the diagnosis of an atypical case of the Takotsubo syndrome (TTS). The literature is reviewed to help the clinician understand the multiple variables of the differential diagnosis when assessing probable depression in elderly women with comorbid cardiac signs and symptoms.

Keywords: *Takotsubo Syndrome (TTS); ST-elevation Myocardial Infarction (STEMI); Acute Coronary Syndrome (ACS)*

Introduction

Takotsubo cardiomyopathy or the Takotsubo syndrome (TTS) is a reversible cardiomyopathy first described by the Japanese in 1990 and in the United states in 1997. TTS involves abnormal left ventricular contraction in which the weakened ventricle manifests the pathognomonic shape having a narrow neck and a ballooned lowered portion resembling a ceramic pot (takotsubo, Figure 1) used by Japanese fishermen to trap octopus 2 [1]. It has also been referred to as the "broken heart syndrome" or the "stunned heart syndrome" [2,3] as it may result from a catecholamine shock to the heart following a severe emotional or physical stress [4-6]. It occurs principally in women between the ages of 58 and 75 (mean 67 - 70) years of age [7,8]. The male female ratio varies and has been estimated to be approximately 1:9 [9] with 1-3 percent of all persons with suspected ST-elevation myocardial infarction (STEMI) [10] and 5 - 6% of females presenting with suspected STEMI [11].

Studies suggest that five percent of women evaluated for possible myocardial infarction have TTS [6]. TTS involves a weakening of the left ventricle, frequently as the result of severe emotional or physical stress [2]. The left ventricle undergoes a modification in shape which may be temporary and shares characteristics with acute coronary syndrome (ACS) [12]. It is estimated that in 85 percent of cases, the stress that precipitates TTS precedes the event by minutes to hours [3]. Emotional stresses can include grief (family member, dear friend), fear (assault, public speaking), anger (significant other or coworker) and financial stressors (job loss, stock market loss, robbery). Physical stressors may include acute asthma attacks, surgical procedures and stroke. In the other 15 percent of TTS cases, the exact stressor eliciting the TTS cannot be identified [3]. It is reported that many subclinical TSS cases are undetected in centers without percutaneous intervention units [13]. Approximately 67 percent of TTS cases may be associated with emotional traumas, physical stressors, a combina-

tion of emotional and physical stressors, approximately 33 percent of patients present without the evidence of either emotional or physical stressors [8,14-16]. Women present more frequently with emotional stressors while men predominantly have physical stressors [8].

TTS involves abnormal left ventricular contraction in which the weakened ventricle manifests the pathognomonic shape having a narrow neck and a ballooned lowered portion resembling a takotsubo (Figure 1) [3]. The most common presenting symptoms are chest pain, dyspnea or syncope [8]. A subpopulation of TSS with emotional stressors have a higher prevalence of chest pain and palpitations [17]. Unlike myocardial infarctions, episodes of TTS may recover to the prior premorbid state without permanent heart pathology. Recovery time can vary from several weeks to a month [18]. Long-term permanent complications such as arrhythmias, coronary artery obstruction and ventricular wall rupture have been reported [19]. Approximately 5 percent of patients will suffer a second or third episode [3]. However, the syndrome may be fatal secondary to severe adrenergic stimulation accompanied by myocardial ischemia resulting in life-threatening ventricular arrhythmias and critical hemodynamic disorders. The in-hospital mortality rate from TTS varies from 2.5 to 20.0 percent due to complications such as cardiogenic shock, ventricular arrhythmias (e.g. torsade de pointes, ventricular fibrillation), left ventricle rupture, thrombotic and embolic events caused by left ventricle parietal clot, or multiorgan insufficiency [6,19]. Redfors., *et al.* assessed the short- and long-term mortality in patients with TTS versus patients with STEMI and non-ST-elevation myocardial infarction (NSTEMI). Findings showed that 14 percent of TTS patients also had significant coronary artery disease and developed cardiogenic shock more frequently than in patients with NSTEMI. The 30 day morality rate was approximately four percent, similar to patients with STEMI and NSTEMI. At a median follow up of 25 months, risk of dying from TTS was similar to dying from NSTEMI [11].

The precise etiology of TTS is evolving. Early reports posited that the hormonal response during an acute or prolonged stress triggers changes in heart muscle cells and/or coronary blood vessels that impede normal physiologic left ventricle contraction. Early studies suggested that older women are more vulnerable because of reduced levels of estrogen after menopause [20]. In a retrospective study of 18 women with TTS 16 were postmenopausal and none were taking estrogen replacement therapy (ERT). The authors concluded that ERT in the postmenopausal state may be prophylactic to TTS [20].

In a model proposed by Akashi., *et al.* an unexpected, severe emotional or medical distress activates estrogen receptors. This precipitates significant increases in sympathetic neuronal and adrenomedullary epinephrine (adrenal medulla) and norepinephrine (cardiac and extracardiac sympathetic nerves), hormones that bind with cardiac and coronary blood vessel adrenoceptors in the blood vessels and heart. Increased blood vessel contraction rapidly increases systemic blood pressure with increased end-diastolic pressure and cardiac afterload. High plasma brain natriuretic peptide (BNP) and catecholamine levels induce cardiomyocyte catecholamine toxicity with hypercontraction of the left ventricular wall causing increased mechanical wall stress in the left ventricular apex and increased end-diastolic pressure [5,6]. Consequently, contraction bands and myocardial cell rupture occurs in the left ventricle apex sections with the highest concentration of adrenoceptors [6]. For major anatomical types of TSS have been described: Apical ballooning; mid ventricular; basal; and focal wall motion patterns [21].

Presenting Signs

Most frequently, TTS signs of chest pain and dyspnea are similar to those of myocardial infarction (MI). There are also similarities on ECG examination: ST elevation in precordial leads; subsequent T-wave inversion and Q-wave formation [22] and mild creatinine kinase and troponin level increases [6]. Patients may also have high levels of serum catecholamines and BNP similar to MI patients [23]. Therefore, an echocardiogram or left ventriculography are often employed to resolve the differential diagnosis [12]. Recent studies have demonstrated that an echocardiogram can differentiate between TTS and acute MI with high specificity and positive predictive value [24]. The echocardiogram demonstrates ballooning of the left ventricle apex with contraction during systole. A myocardial biopsy may reveal: interstitial infiltrates consisting primarily of mononuclear lymphocytes; leukocytes; macrophages; myocardial fibrosis; and contraction

bands with or without overt myocyte necrosis. These inflammatory markers and contraction bands distinguish TTS from MI secondary to coronary artery occlusions that are characterized by coagulation necrosis without contraction bands [6]. Some findings suggest that disturbances in the coronary microcirculation are involved in the dynamic changes in the left ventricular wall [25]. For comprehensive description of TSS please refer to the International Expert Consensus Document on Takotsubo Syndrome (Part I): Clinical Characteristics, Diagnostic Criteria, and Pathophysiology published in June 2018 [12].

Case Report

A 68-year-old woman arrived in the mental health clinic in a wheelchair which she requested when she had her automobile parked by the hospital valet parking attendants. The hospital voluntary staff wheeled her to the mental health clinic. The patient appeared more frail than usual and appeared to have lost weight since her last clinic visit a year ago. Unlike her euthymic presentations for years, she was not reading a book.

Immediately upon entering the examination room she stated "I need something for my anxiety and a pill for the water on my legs. They feel like they weigh 20 pounds." In addition, she complained of increasing chronic depressive symptoms, fatigue, lack of initiative, anxiety and loss of interest in her favorite activities of gardening and reading occurring over a period of months. The patient had been complaining of worsening weakness and depressive symptoms following her discharge from the medical ward four months prior for small bowel obstruction associated with an acute exacerbation of Crohn's disease. Since that time the patient had three no-shows and multiple clinic appointment cancellations for the past 12 months which were out of character for her. The patient had a prolonged history of severe protein and calorie malnutrition. Although she repeatedly denied binging/purging or restrictive eating habits during each clinical visit for years, her weight had been gradually declining from a high of 114 pounds in 2006 to 73 pounds at clinic check-in.

The patient had been followed in the mental health clinic for two decades for the diagnoses of restricting type anorexia nervosa, borderline personality disorder resolved, PTSD, recurrent major depression in partial remission, agoraphobia and insomnia. In addition to her psychiatric diagnoses, the patient had a complicated medical history. Her medical problems included low BMI, benign essential hyper-

Expected Presentation [12]	Present (Y/N)	Case Presentation
Female > 57-78 years old [6,7]	Yes	Female 68 years old
Dyspnea [22]	No	No dyspnea
After collapse of left ventricle, low blood pressure	Yes	99/64
No bilateral lower extremity pitting edema	No	Bilateral lower extremity pitting edema
No basilar lung infiltrate	No	Basilar infiltrate left lung
< 60 minutes following surgical procedure	No	4 months following last surgical procedure
< 60 minutes following medical procedure	No	No recent medical procedures; Chronic protein and calorie malnutrition (↓ BMI 15.2)
Several weeks to months [18]	Yes	
Female > 55 - 60 years old	Yes	Female 68 years old
History of surgery	Yes	Multiple surgeries: Crohn's disease, ileocecal resections; perforated duodenal ulcer; (ERCP) with biliary and pancreatic sphincterotomy
< 60 minutes following surgical procedure	No	No recent medical procedure.
Cerebral bleeding, strike, aneurysm rupture, TIA, concussion, posterior reversible encephalopathy syndrome	No	No history of cerebral bleeding, TIA, concussion or encephalopathy
Crohn's Disease exacerbation, gastrointestinal bleeding	Yes	Recent hospitalization for Crohn's disease and GI obstruction
Pheochromcytoma, urosepsis	No	No history of pheochromcytoma or, urosepsis
Cancer	No	No history of cancer
Sudden drop in blood pressure	No	No sudden drop in blood pressure
Tobacco use disorder [26]	Yes	Severe chronic tobacco use disorder
Hyperlipidemia [9]	No	No hyperlipidemia
Severe pain [27]	Yes	Severe pain since 2004 (prescribed opioids)
Pneumonia, asthma attack, bronchitis, COPD exacerbation	No	No history of asthma; Severe COPD with home oxygen required
Alcohol abuse [28]	No	No history of alcohol abuse
Serious accident	No	No history of serious accident

Table 1: *Medical presentations of Takotsubo Syndrome symptoms.*

tension, history of acute duodenal ulcer with hemorrhage, diabetes mellitus type 2, chronic pancreatitis, chronic obstructive pulmonary disease, meningioma, and neoplasm of the adrenal gland (Table 1).

Records showed that she had no history of coronary artery disease or congestive heart failure. Medications included: cholecalciferol 1000 international units for vitamin D deficiency; diltiazem 120 mg daily for hypertension; a nutritional supplement "meal" twice a day; hydrochlorothiazide 12.5 mg daily for hypertension; methylphenidate SA 27 mg twice a day for treatment of resistant depression; mirtazapine 30 mg at bedtime for depression; ondansetron 4 mg every 6 hours as needed for nausea; oxycodone 5 mg 3 times a day as needed for pain; troponin 18 mcg inhaler/aerosol daily; and, glucosamine 2 capsules daily.

Mental status examination revealed a thin woman sitting in wheelchair with a knit cap and a blanket over her legs. Her attitude was demanding and frustrated with her functional limitations. Her speech was normal rate and tone with normal rhythm and prosody. She showed mild psychomotor retardation. Her impulse control was relatively intact. Her thought processes were logical and goal oriented. She was oriented to person, place, situation and date. Her eye contact was good, although her mood was depressed and anxious. Her affect was dysthymic with mild restriction. She denied any suicidal or homicidal ideations, plan or intent. There were no signs of paranoia or thought disorder. She had futuristic ideations of seeing her son who was living in her house and working to improve his health. Her insight was relatively good as she recognized that she was depressed and anxious. However, her judgment was poor as she had not come to her appointments for greater than one year and thus allowed her situation to deteriorate before she finally sought help. This was uncommon

Expected Presentations [12]	Present (Y/N)	Case Presentation
Recent (< 1 hr.) Severe Emotional Stress	No	No recent emotional stress
Depression, Anxiety disorders	Yes	Anxiety disorders present on admission
Suicide Attempt	No	No history of suicide attempts
Fear of Surgery/Hospitalization	Yes	Neoplasm of the adrenal gland, Fear of hospitalization for exacerbation of Crohn's Disease
Illness of close person	Yes	Ongoing for years
Divorce	Yes	Decades ago
Post-traumatic Stress Disorder	Yes	Onset decades go, stable
Relocation to another city	No	Same house for several decades
New job, job Loss, retirement	No	Retired for more than 2 decades
Financial stressors: Debt, large money loss	Yes	Fixed income with recent expenses due to storm damage to property, house
Death of family member, partner	Yes	Son's status post stroke; death of mother; death of mother-in-law; death of 13 year old dog
Fear	Yes	Fear of dying from adrenal gland neoplasm
Assault	Yes	History of sexual assault
Anger, argument with partner, family, community member	Yes	Medications stolen by son's girlfriend who was a guest in the home while son in prison
Domestic violence	Yes	History of domestic violence
National disaster	No	No history of a national disaster
Receiving bad news	Yes	Son with stroke and paralysis; another son in prison, violated parole and sent back to prison; mother's death; death of beloved mother-in-law; divorce; sister's death from diabetes; death of dog; patient's 3 children and other family members' moves from the state
Public speaking	No	No public speaking

Table 2: *Psychosocial presentations in atypical takotsubo syndrome.*

for her as she had been very diligent about attending her mental health clinic appointments for two decades.

The patient had been experiencing a plethora of medical (Table 1) and psychosocial stressors during the past twenty years (Table 2).

Among these psychosocial stressors were a divorce, a son sent to prison, years of visiting her son in prison, a sister with diabetes requiring dialysis followed by death, a second son having a stroke with hemiplegia and aphasia, the death of her mother-in-law who was the patient's surrogate mother and her own mother's death. Her most recent medical stressor was a surgical admission for small bowel obstruction associated with an acute exacerbation of Crohn's disease. She underwent a small bowel resection and an ERCP with biliary and pancreatic sphincterotomy. During this admission, her methylphenidate SA 27 mg twice a day for treatment resistant depression was stopped without tapering. Subsequently, starting her on bupropion extended release was attempted. However, her decision to not attend her mental health clinic appointments after her medical discharge made medication management difficult. She was contacted approximately every two months by her psychiatrist, who attempted medication management by telephone conversations. However, compliance was unclear as the symptoms worsened. Telephonically, the patient reported signs of worsening depression such as "I'm too tired to come into the hospital" and "I don't have enough strength to drive from my home to the hospital." She had an ongoing fear of future hospitalizations for exacerbation of her Crohn's disease and also a fear of death from an adrenal neoplasm (benign). When she finally came into the mental health clinic she presented with the above symptoms of weakness, anxiety, depression, and weight loss.

On examination, the patient had orthostatic bilateral pitting edema on two thirds of her lower legs. There were no skin thickenings, ulcerations or pigmentation. Vital signs were: temperature 99.1 F; pulse 124; respirations 22; blood pressure 99/64; pulse oximetry 99 percent. The patient did not have any shortness of breath, cough, phlegm production or chest pain. She was subsequently taken to the emergency room for evaluation. On arrival at the emergency department, an ECG revealed sinus tachycardia with ST elevation in the antero-septal leads (V1 - V4) (Figure 2).

Figure 1

Japanese Takotsubu pot with octopus tentacles protruding from the opening. The pot is lowered by a rope to the underwater surface of a salt water bay to await the entrance of an octopus. An increase in the weight of the pot identified by pulling on the rope indicates the probable entrance of an octopus.

Troponin I was elevated at 0.569 ng/ml (normal 0.04 - 0.39 ng/mL) and CK-MB was elevated at 8.0 ng/ml (normal 0.5 - 3.6 ng/ml). Chest x-ray revealed small left basal infiltrate. A STAT echocardiogram suggested TTS rather than an MI (Figure 2).

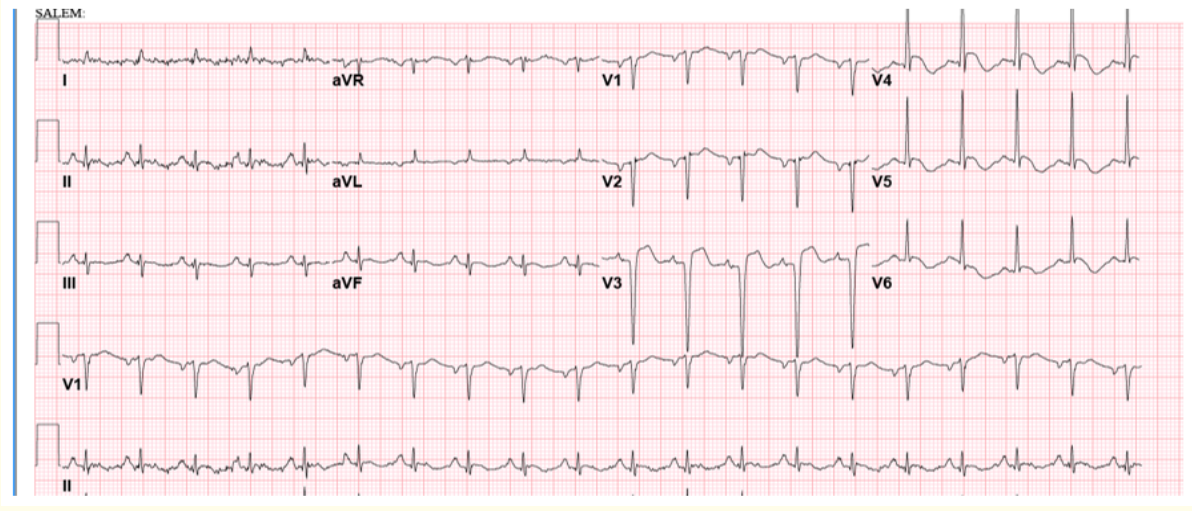

Figure 2A: *12 lead EKG demonstrating global ST/T changes on admission to acute medicine. The elderly patient had a mild Troponin elevation and a coronary angiogram was notable for no significant obstructive coronary artery disease. This information along with a pattern of wall motion abnormality on echocardiogram led to diagnosis of stress induced cardiomyopathy or Takotsubo Syndrome.*

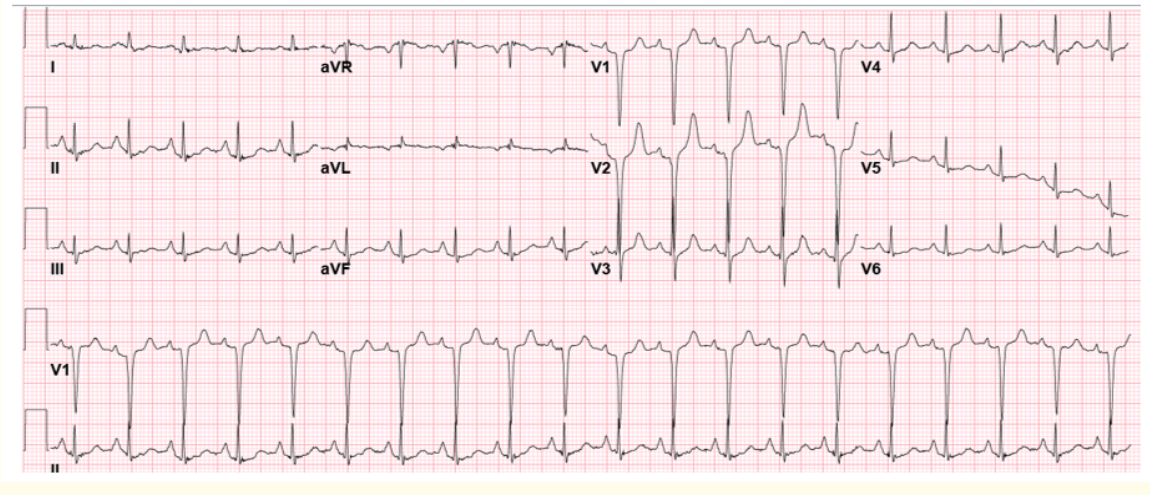

Figure 2B: *The 12 lead EKG a few months prior to the patient's admission to acute medicine for an episode of Takotsubo Syndrome.*

Figures 3A and 3B show echocardiogram images of the left ventricle captured in end systole demonstrating basal hypercontractility and mid to apical severe hypokinesis during an acute Takotsubo Syndrome episode.

The echocardiogram showed a low ejection fraction (30%), severely impaired left ventricular systolic function and wall motion abnormalities, severe left ventricular diastolic dysfunction, increased left atrial pressure, mild pulmonary hypertension, mild aortic insufficiency, severe mitral regurgitation, however, there was no evidence of a source for cardiac embolisms.

On the medical ward, the cardiologist recommended stopping the diltiazem, adding digoxin for cardiac stabilization and furosemide for several days to eliminate the lower extremity edema and left basilar infiltrate. The patient was started on hydrochlorothiazide for hypertension, continued on albuterol inhaler for COPD, started on a nicotine patch taper for her tobacco use disorder and she was continued on mirtazapine 30 mg for depression. The consult liaison service recommended that methylphenidate SA 27 mg twice a day should be discontinued as adrenergic activation of methylphenidate may have a negative impact on the autonomic regulation of patients with compromised cardiovascular function [29]. Tapering the methylphenidate was not recommended considering that the longer half-life of the SA formulation should in part self-taper. The patient was closely monitored for the risk of potential withdrawal symptoms. Future use of methylphenidate to help with depressive symptoms was not recommended.

Discussion

The symptom burden of medical illnesses and psychosocial stressors with age is an important factor in the clinical presentation of depression in the elderly [30-32]. Diagnosing mood disorders can be problematic in this population as there are no pathognomonic blood tests that are specific for mood and anxiety disorders. Depression in elderly women is more common than in elderly men. This difference is not only based on biological changes, but also on psychosocial stressors. Elderly women have a higher risk to live in poverty, be single parents and/or caregivers, work multiple jobs and suffer from physical, gender and sexual abuse. These variables contribute to low self-esteem and feelings of losing control of their lives [33].

The association between depressive disorders, psychological stress and cardiomyopathy was described as early as 1892 by Sir William Osler and this association is reported to be underappreciated in clinical practice [34,35]. These clinical variables are particularly important in elderly patients that may have been experiencing chronic mood disorder symptoms for many years. Decades of illness can be considered to be a dose-response symptom burden, or the ongoing accumulation of chronic affective symptomatology [36,37]. When an elderly patient arrives in clinic complaining of dysphoria with or without somatic symptoms, the differential diagnosis is broad and may include mood disorders, anxiety disorders, bipolar disorder, diabetes mellitus, hypothyroidism, chronic fatigue syndrome, thyroid instability, medications, alcohol use, drug abuse, bereavement from the death of the patient's family and friends, poverty issues and cardiomyopathy among others. In the present case, the patient arrived at clinic with depressive symptoms after a one year history of failure to come to clinic. She was also complaining of anxiety with weakness, decreased energy and anhedonia. She was at her lowest weight in 12 years and was suffering from marked protein and calorie malnutrition.

The medical literature reports multiple possible mechanisms underlying psychosocial stressors such as anxiety and mood disorders that may contribute to high catecholamine levels from the adrenal medulla, sympathetic nerves and exogenous medications leading to myocardial stunning causing the varying patterns of left ventricle regional ballooning in TTS [12]. Early studies suggested that high circulating concentrations of catecholamines from stress could directly damage the myocardium [38]. Acute or chronic medical and/or psychosocial stressors activate and destabilize the hypothalamic–pituitary–adrenal axis resulting in myocardial infarctions, dysrhythmias, left ventricular dysfunction and exacerbated atherosclerotic processes [39]. Early reports associated low estriol levels as a risk factor for TSS in women [20,40], however recent evidence suggests that altered sex hormone levels are not a risk factor for TTS [41]. There may be a genetic predisposition to TSS as the syndrome has been reported in mother-daughter pairs and sister pairs [42,43].

In the current case study, the patient had been followed in her most recent mental health clinic for approximately two decades for the diagnoses of borderline personality disorder, recurrent major depressive disorder, insomnia and the restricting type of anorexia nervosa in addition to several episodes of depressive disorder (bereavement) related to the deaths of family members. She had an established

history of chronic medical and psychosocial stressors which, based on the medical literature, which had possibly precipitated chronic activation and destabilization of her hypothalamic–pituitary–adrenal axis. As the patient had been treated for her medical and psychiatric problems in other clinics prior to reaching our hospital in the late 1990s, the HPA axis destabilization can be presumed to have been ongoing for more than 40 years.

Treatment

Presently there are no published randomized clinical trials regarding TTS treatment strategies. Therefore, most clinicians use standard medications for cardiomyopathies such as beta blockers, ACE inhibitors and diuretics for TTS treatment. In addition, concurrent treatment for the comorbid medical, psychiatric and social stressors that may have played a role in triggering TTS should be employed [18]. Until TTS is distinguished from ACS, patients should first be transferred to a cardiology unit with imaging capabilities and a cardiac catheterization laboratory to receive ACS guideline treatment (e.g. aspirin, heparin, possibly morphine and oxygen) until the differential diagnosis resolved. Patients with cardiogenic shock or post-cardiac arrest should be sent to the intensive care unit [21].

Based on the evidence that TTS is similar ACS, Ghadri., *et al.* developed an International Takotsubo Diagnostic Score (InterTAK Diagnostic Score) to estimate the probable presence of TTS and to distinguish TTS from ACS [21]. The InterTAK Diagnostic Score comprises seven parameters (female sex, emotional trigger, physical trigger, absence of ST-segment depression [except in lead aVR], psychiatric disorders, neurologic disorders, and QT prolongation) ranked by their diagnostic importance with a maximum attainable score of 100 points. Patients presenting with ST-segment elevation are recommended to undergo urgent coronary angiography with left ventriculography to exclude acute myocardial infarction. In patients with non–ST-segment elevation, the InterTAK Diagnostic Score can be considered. Patients with a low probability (InterTAK Score ≤ 70 points) should undergo coronary angiography with left ventriculography, while transthoracic echocardiography should be considered in patients with a high score (score ≥70) [21].

In the present case, the medical and psychosocial stressors had been aggressively treated during the patient's 20 years at our hospital. However, her large spectrum of ongoing chronic psychosocial and medical problems had gradually debilitated her with acceleration during the 12 months prior to her TTS episode as she refrained from seeking treatment. Studies are inconclusive regarding the graded value of benefit of biopsychosocial treatment s for chronic mood/anxiety disorders and medical disorders in mitigating the risk of TTs [35].

For the psychiatrist or mental health clinician, what can be discerned from this case in the effort to be better prepared for such a complicated differential diagnosis? The usual key elements in considering a diagnosis of TTS would be finding a woman over 60 years of age, presenting with anxiety and/or depression, with a recent (60 minutes or less) history of acute medical or psychosocial stressors. Classically this will be accompanied by complaints of chest pain, shortness of breath and a sudden drop in blood pressure. Also an extensive history of medical and psychiatric problems that have been ongoing for several decades increases the risk of cardiac damage which could lead to either a myocardial infarction or TTS diagnosis. What was uncommon in this case is that the patient did not have shortness of breath or chest pain. Moreover, she did not have any very recent medical or psychosocial events that could be identified as the precipitating stressor. She did have multiple chronic medical and surgical problems that had been ongoing for decades. The signs of leg edema with increasing fatigue suggested congestive heart failure were the clinical signs leading to suspicion of ACS. In the ED, ECG variables indicated the need for an echocardiogram which subsequently identified TTS. This case illustrates the need for physicians to include TTS in the differential diagnosis when older women present with signs of ACS accompanied by chronic stressors in addition to recent acute stressors, even in the absence of shortness of breath and/or chest pain.

Conclusion

Depression is not an uncommon phenomenon in elderly women 60 years and over, particularly when they are single and have multiple biopsychosocial stressors. Studies indicate that TTS is more prevalent than generally understood and principally manifested in the aging

population. Complicating the diagnosis is the fact that cardiomyopathy often presents differently in women than in men. When examining elderly women with chronic anxiety and/or mood disorders accompanied by signs and symptoms of heart disease, the differential diagnosis is broad and should include TTS. The present case illustrates an atypical presentation compared to the more classical presentations described in the medical literature. Awareness of variations in the presentation of TTS may decrease morbidity and mortality.

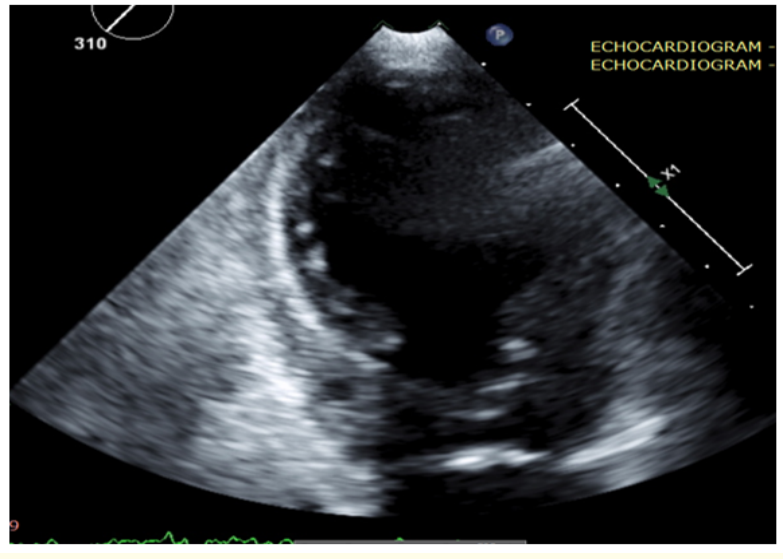

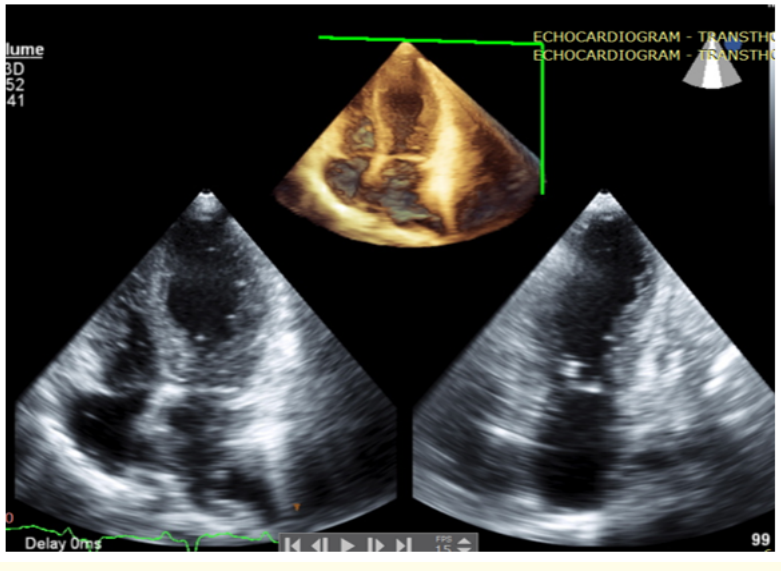

Figure 3A and 3B: *3A and 3B show echocardiogram images of the left ventricle captured in end systole demonstrating basal hypercontractility and mid to apical severe hypokinesis during an acute Takotsubo Syndrome episode*

Disclosure

The authors report no conflict of interest. The report findings do not represent the views of the Department of Veterans Affairs or the United States Government. This material is the result of work supported with resources and the use of facilities at the Salem, Veterans Affairs Medical Center, Virginia.

Bibliography

1. Pavin D., *et al*. "Human stress cardiomyopathy mimicking acute myocardial syndrome". *Heart* 78.5 (1997): 509-511.
2. Virani SS., *et al*. "Takotsubo Cardiomyopathy, or Broken-Heart Syndrome". *Texas Heart Institute Journal* 34.1 (2007): 76-79.
3. Sharkey SW., *et al*. "Takotsubo (Stress) Cardiomyopathy". *Circulation* 124.18 (2011): e460-e462.
4. Akashi YJ., *et al*. "Reversible left ventricular dysfunction "takotsubo" cardiomyopathy associated with pneumothorax". *Heart* 87.2 (2002): e1.
5. Akashi YJ., *et al*. "The clinical features of takotsubo cardiomyopathy". *QJM: An International Journal of Medicine* 96.8 (2003): 563-573.
6. Akashi YJ., *et al*. "Takotsubo cardiomyopathy: a new form of acute, reversible heart failure". *Circulation* 118.25 (2008): 2754-2762.
7. Seth PS., *et al*. "A syndrome of transient left ventricular apical wall motion abnormality in the absence of coronary disease: a perspective from the United States". *Cardiology* 100.2 (2003): 61-66.
8. Templin C., *et al*. "Clinical features and outcomes of takotsubo (stress) cardiomyopathy". *New England Journal of Medicine* 373 (2015): 929-938.
9. Deshmukh A., *et al*. "Prevalence of Takotsubo cardiomyopathy in the United States". *American Heart Journal* 164.1 (2012): 66-71.
10. Prasad A., *et al*. "Apical ballooning syndrome (Tako-Tsubo or stress cardiomyopathy): a mimic of acute myocardial infarction". *American Heart Journal* 155.3 (2008): 408-417.
11. Redfors B., *et al*. "Mortality in takotsubo syndrome is similar to mortality in myocardial infarction - A report from the SWEDEHEART". *International Journal of Cardiology* 185 (2015): 282-289.
12. Ghadri JR., *et al*. "International Expert Consensus Document on Takotsubo Syndrome (Part II): Diagnostic Workup, Outcome, and Management". *European Heart Journal* 39.22 (2018): 2047-2062.
13. Roshanzamir S and Showkathali R. "Takotsubo cardiomyopathy a short review". *Current Cardiology Reviews* 9.3 (2013): 191-196.
14. Sato H. "Tako-tsubo-like left ventricular dysfunction due to multivessel coronary spasm". In: Kodama K, Haze K, Hori M, eds. Clinical Aspect of Myocardial Injury: From Ischemia to Heart Failure. Tokyo: Kagakuhyoronsha Publishing Co (1990): 56-64.
15. Sharkey SW., *et al*. "Natural history and expansive clinical profile of stress (tako-tsubo) cardiomyopathy". *Journal of the American College of Cardiology* 55.4 (2010): 333-341.
16. Gianni M., *et al*. "Apical ballooning syndrome or takotsubo cardiomyopathy: a systematic review". *European Heart Journal* 27.13 (2006): 1523-1529.
17. Song BG., *et al*. "The impact of stressor patterns on clinical features in patients with tako-tsubo cardiomyopathy: experiences of two tertiary cardiovascular centers". *Clinical Cardiology* 35.11 (2012): E6-E13.

18. Takotsubo cardiomyopathy (broken-heart syndrome) - Harvard Health Publishing, Harvard medical School (2018).

19. Sosnowska-Pasiarska B., *et al*. "Sudden cardiac arrest in takotsubo cardiomyopathy - a case study". *Postępy w Kardiologii Interwencyjnej* 10.2 (2014): 110-113.

20. Kuo BT., *et al*. "Reduced estrogen in menopause may predispose women to takotsubo cardiomyopathy". *Gender Medicine* 7.1 (2010): 71-77.

21. Ghadri JR., *et al*. "A novel clinical score (InterTAK Diagnostic Score) to differentiate takotsubo syndrome from acute coronary syndrome: results from the International Takotsubo Registry". *European Journal of Heart Failure* 19.8 (2017): 1036-1042.

22. Bybee KA., *et al*. "Electrocardiography cannot reliably differentiate transient left ventricular apical ballooning syndrome from anterior ST-segment elevation myocardial infarction". *Journal of Electrocardiology* 40.1 (2007): 38.e1-38.e6.

23. Nef HM., *et al*. "Release pattern of cardiac biomarkers in left ventricular apical ballooning". *International Journal of Cardiology* 115.1 (2007): 128-129.

24. Frangieh AH., *et al*. "ECG Criteria to Differentiate Between Takotsubo (Stress) Cardiomyopathy and Myocardial Infarction". *Journal of the American Heart Association* 5.6 (2016): e003418.

25. Yoshida T., *et al*. "A pathophysiologic study of tako-tsubo cardiomyopathy with F-18 fluorodeoxyglucose positron emission tomography". *European Heart Journal* 28.21 (2007): 2598-2604.

26. Takagi A., *et al*. "Stress echocardiography causes stress cardiomyopathy: A very rare complication should be reminded". *Journal of Cardiology Cases* 6.3 (2012): e94-e95.

27. Ferguson AL. "Takotsubo cardiomyopathy: Healing a broken heart". *American Nurse Today* 10.6 (2015).

28. Stout BJ., *et al*. "Takotsubo Cardiomyopathy in the Setting of Acute Alcohol Withdrawal". *Hawai'i Journal of Medicine and Public Health* 71.7 (2012): 193-194.

29. Zukkoor S. "The Safety of Stimulant Medication Use in Cardiovascular and Arrhythmia Patients". Expert Analysis, American College of Cardiology (2015).

30. Cesar J and Chavoushi F. "Update on 2004 Background Paper, BP 6.15 Depression". World Health Organization, (2013).

31. Physiology and Psychology of Aging, Health and Place. Health and Places Initiative. Harvard Graduate School of Design. A Research Brief, Version 1.0 (2014).

32. Eckerblad J., *et al*. "Symptom burden in community-dwelling older people with multimorbidity: a cross-sectional study". *BMC Geriatrics* 15 (2015): 1.

33. Depression and women: Understanding the gender gap. Mayo Clinic staff. Mayo Clinic (2016).

34. Osler W. The principles and practice of medicine, Classics of Medicine Library, Division of Gryphon Editions, Ltd, Birmingham, AL (1892) (Reprinted 1978).

35. Fiedorowicz JG. "Depression and cardiovascular disease: an update on how course of illness may influence risk". *Current Psychiatry Reports* 16.10 (2014): 492.

36. Varghese FP and Brown ES. "The Hypothalamic-Pituitary-Adrenal Axis in Major Depressive Disorder: A Brief Primer for Primary Care Physicians". *Primary Care Companion to the Journal of Clinical Psychiatry* 3.4 (2001): 151-155.

37. Murri MB., *et al*. "HPA axis and aging in depression: Systematic review and meta-analysis". *Psychoneuroendocrinology* 41 (2014): 46-62.

38. Iga K., *et al*. "Reversible left ventricular wall motion impairment caused by pheochromocytoma: a case report". *Japanese Circulation Journal* 53.7 (1989): 813-818.

39. Brotman DJ., *et al*. "The cardiovascular toll of stress". *The Lancet* 370.9592 (2007): 1089-1100.

40. Pelliccia F., *et al*. "Pathophysiology of Takotsubo Syndrome". *Circulation* 135.24 (2017): 2426-2441.

41. Möller C., *et al*. "Comprehensive assessment of sex hormones in Takotsubo syndrome". *International Journal of Cardiology* 250 (2018): 11-15.

42. Cherian J., *et al*. "Can takotsubo cardiomyopathy be familial?" *International Journal of Cardiology* 121.1 (2007): 74-75.

43. Ikutomi M., *et al*. "Takotsubo cardiomyopathy in siblings". *Heart Vessels* 29 (2014): 119-122.

Volume 11 Issue 3 March 2019