

## A Case of Brain Hemangiopericytoma: Possible Long Survival

Ersan Al Zamel, Mohammed Salama, Nazim Ahmed and Ehab Hanafy\*

Prince Sultan Oncology Center, King Salman Armed Forces Hospital, Tabuk, KSA

\*Corresponding Author: Ehab Hanafy, Prince Sultan Oncology Center, King Salman Armed Forces Hospital, Tabuk, KSA.

Received: July 06, 2018; Published: July 31, 2018

### Abstract

Hemangiopericytoma is rare tumor constituting < 1% of all central nervous system tumors. Less than 100 cases have been reported in the literature. We herein present a case of Brain Hemangiopericytoma emphasizing that, despite the tumor's natural tendency to recur several times and the ability of intracranial Hemangiopericytoma to spread outside the CNS (central nervous system), it is possible to ensure a long survival time.

**Keywords:** Hemangiopericytoma; Brain Tumor; Radiotherapy

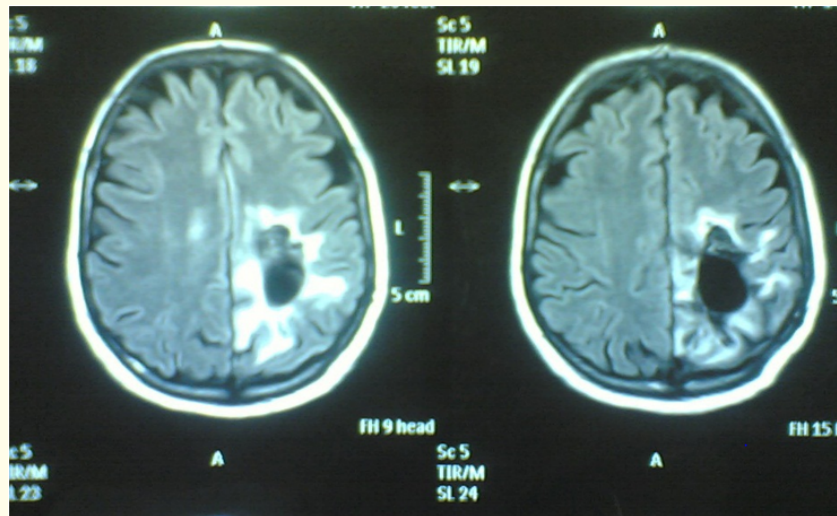
### Introduction

Hemangiopericytoma is a rare tumor that was first described by Schmidt in 1937 and named by Stout and co-workers in 1942. Hemangiopericytoma arises mainly where capillaries exist and occurs either from the precapillary cells or pericytes of Zimmerman. The most common site is in the lower extremities; however, it can occur in the retroperitoneal space or pelvis and in few cases was found to occur in the larynx, spleen, bone, meninges and thorax.

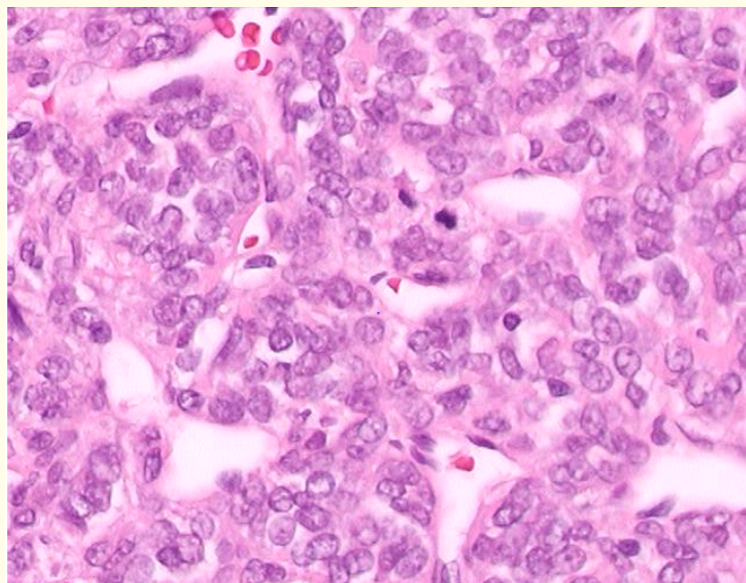
The peak incidence of Hemangiopericytoma is in the fourth and fifth decades of life. These tumors are characterized by a long natural history. For instant, it is a locally aggressive and potentially malignant tumor that has the potential to cause late recurrences and distant metastases, mainly to the bone, lung and liver. Its incidence of metastasis ranges from 12% to 57%. However, Guthrie., *et al.* demonstrated an increasing metastatic frequency up to 64% [1].

### Case Report

A 38-year-old, intubated, and mechanically ventilated woman was transferred to our hospital after loss of consciousness, headache, weakness and numbness in her right side of the body. Both brain CT and MRI showed space-occupying lesion in the left parietal parasagittal area with hemorrhage and mass effect. Craniotomy and Subtotal tumor resection was performed (Figure 1). Histology showed Hemangiopericytoma (Figure 2).



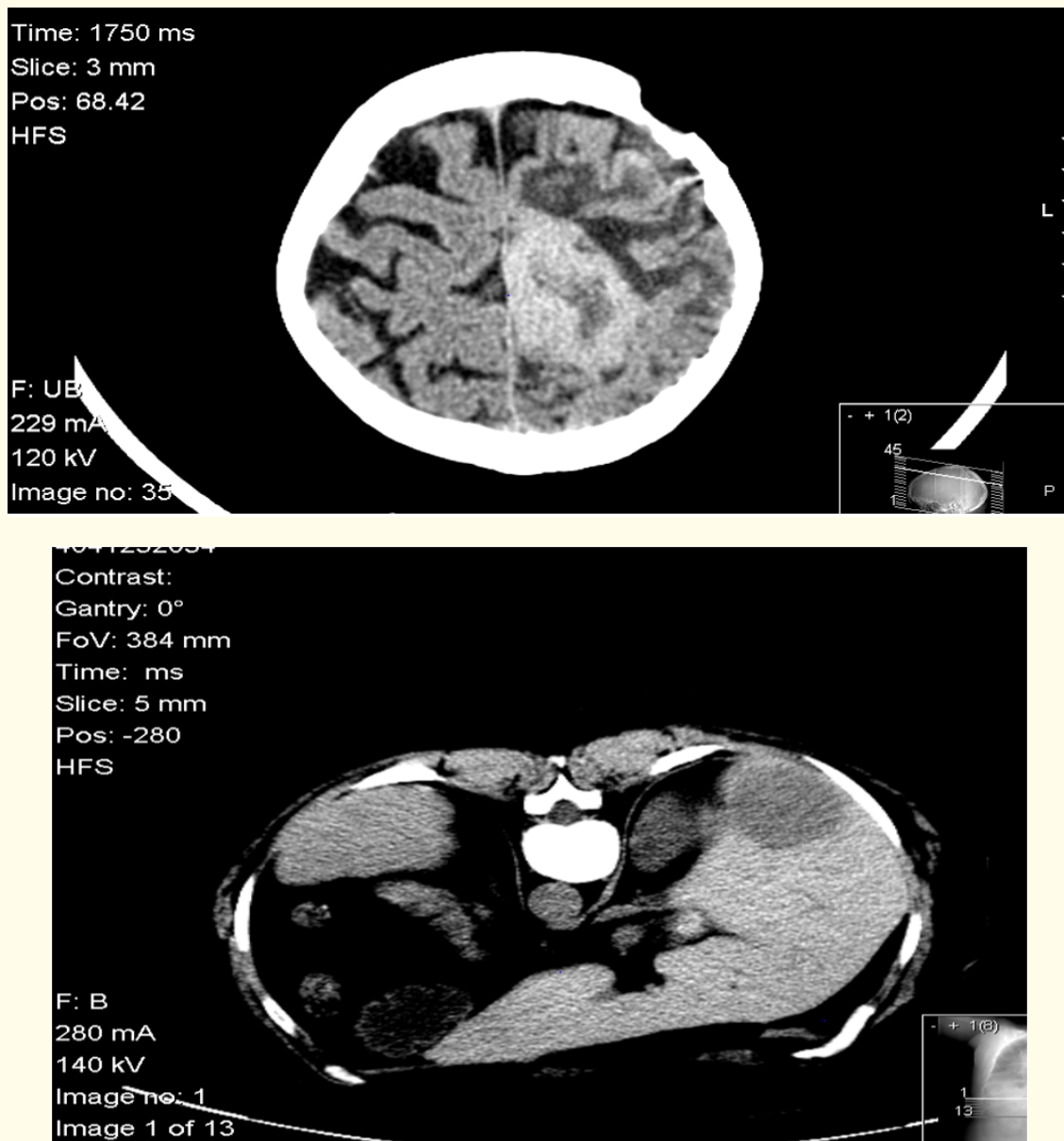
**Figure 1:** MRI shows residual tumor tissue at the left parietal area in parasagittal location surrounded by grade II perifocal edema.



**Figure 2:** The figure shows Hemangiopericytoma. Branching vessels show the typical "staghorn" appearance and vascular space is surrounded by proliferating spindle shaped pericytes.

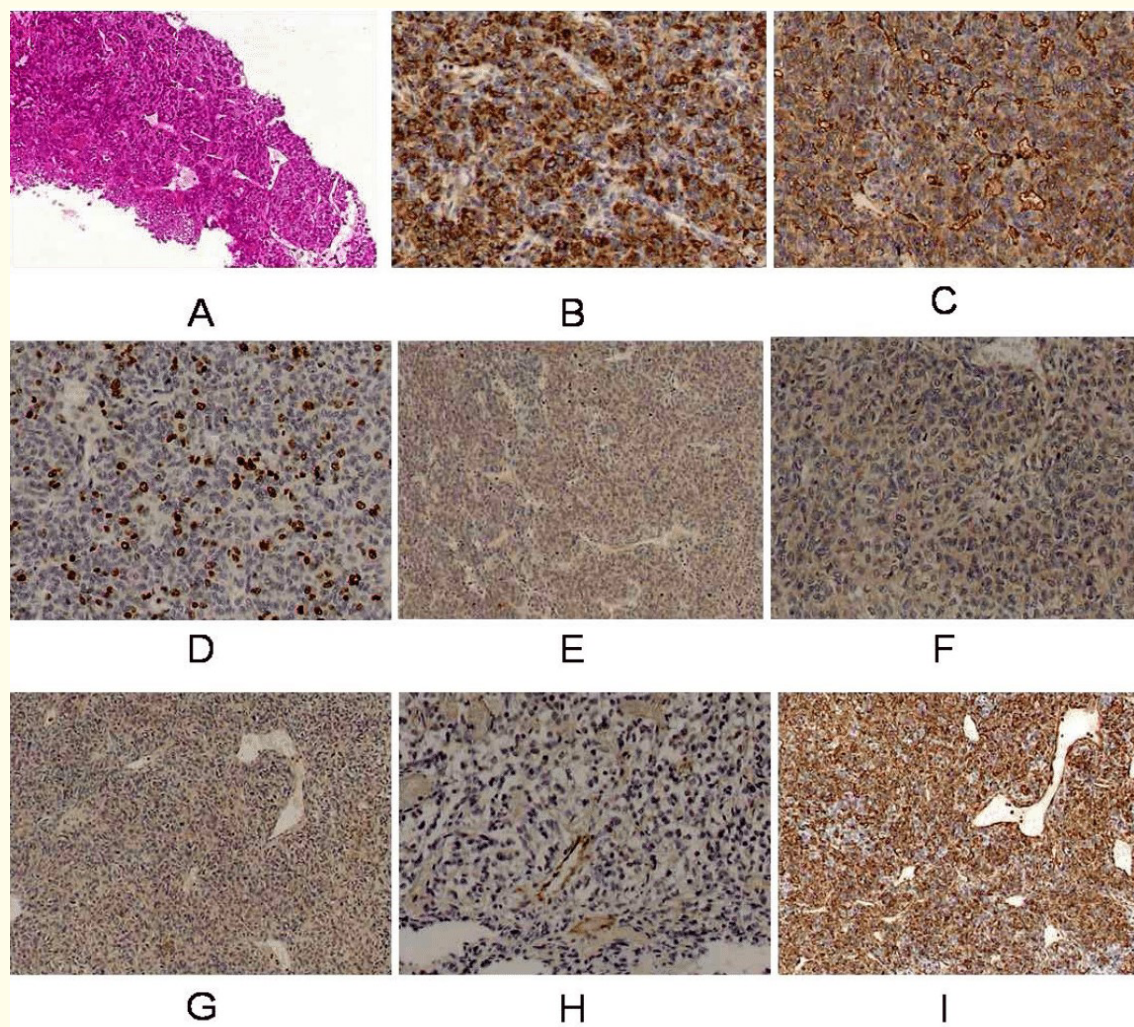
The patient experienced right sided hemiparesis postoperative and had received radical dose of post-operative radiation therapy.

3 years later, she presented with one-week history of fits when a brain CT scan was done and showed regrowth of the tumor on the same site and a second operation (subtotal resection) was performed. Furthermore, a work up staging CT scan showed residual left parietal area tumor as well as liver nodule (4 × 4 cm) (Figure 3).



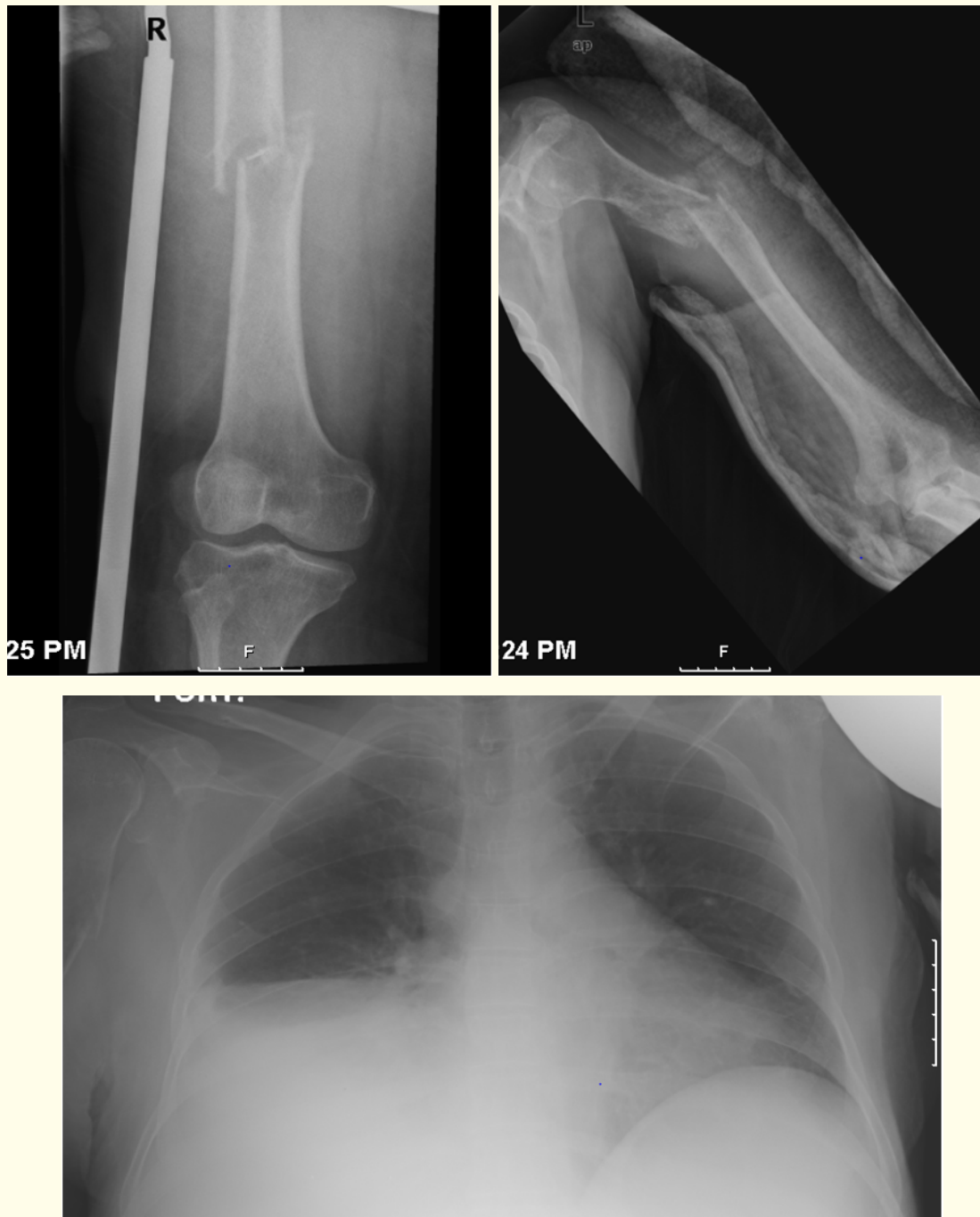**Figure 3:** CT Brain shows residual left parietal area swelling and CT of the abdomen shows a liver nodule 4X4 cm at the posterior-anterior segment of the right lobe (segment VI).

She had a CT-Guided True cut biopsy from the liver. The Histopathology suggested Hemangiopericytoma which was confirmed by IHC (CD57 (+), CD34 (focal +), Chromogranin (focal +), Synaptophysin (focal+), Vimentin (+), NSE (focal+), CD31 (+), S-100 (-), CK pan (-) (Figure 4).



**Figure 4:** The figure shows the histopathology of the liver biopsy and its related immunohistochemistry (CD57, CD34, Ki 67, CGA, CK pan, Synaptophysin, CD31, Vimentin) are represented in figure 4 from B to I respectively.

The patient was offered palliative chemotherapy but she refused and was kept on regular follow up in palliative care clinic. Later on, she had progressive disease which was manifested by huge hepatomegaly reaching till the umbilicus exhibiting multiple, ill-defined liver metastases, right-sided pleural effusion, and multiple long bones pathologic fractures (Figure 5).



**Figure 5:** The figure shows left mid-shaft humeral fracture, right mid-shaft femoral fracture and right moderate pleural effusion.

### Discussion

Hemangiopericytoma is a rare, potentially malignant cancer rises from pericytes in the small capillaries. Hemangiopericytoma does not follow uniform clinical or radiographic patterns, and usually affects older ages. These tumors are composed of closely-packed spindle cells and prominent vascular channels. For the histologic aspect the differential diagnosis includes mesenchymal tumors, such as solitary fibrous tumor and the synovial sarcoma. No single clinical or histological feature including histologic type or DNA ploidy allows prediction of the biologic aggressiveness of the tumor. Malignant Hemangiopericytoma is characterized by high mitotic rate, tumor size and multiple areas of hemorrhage and necrosis.

Immunohistochemically, Hemangiopericytoma shows a positive response to antibodies against Vimentin and type IV collagen and a negative response to VIII-related antigen, S-100 protein, neuron specific enolase, carcinoembryonic antigen, desmins, laminin and cyto-keratin.

The management of choice for Hemangiopericytoma is surgical radical excision. Hansen and colleagues stated the necessity to perform extended surgery considering all Hemangiopericytoma as malignant [2]. Chemotherapy and radiotherapy are not effective modes of management despite being recommended in some cases. On the other hand, Rusch., *et al.* reported that chemotherapy regimens containing Adriamycin were effective in metastatic cases [3]. The 5-year survival of Hemangiopericytoma 85% [4].

Maruya Jun., *et al.* reported that Meningeal Hemangiopericytoma is rare, and only seven cases have manifested as intracranial hemorrhage. They treated two patients with meningeal Hemangiopericytoma manifesting as life-threatening massive intracerebral hemorrhage [5].

Despite of the major role of surgery as a part of Hemangiopericytoma management, radiotherapy has a potential role in management especially when surgery is not feasible and also to decrease the incidence of local recurrence. Radiotherapy has been used preoperatively in high risk surgical cases. Whereas, post-operative radiotherapy showed an increased survival. Chemotherapy has been used in metastatic cases with a palliative intent role and does not show effective results in primary management of such tumors. Overall, with the current modalities of treatment, patients with Hemangiopericytoma have a long survival chance even in metastatic settings [6].

### Conclusion

We may conclude that, despite the tumor's natural tendency to recur several times and the ability of intracranial Hemangiopericytoma to spread outside the CNS (central nervous system), it is possible to ensure a long survival time [7].

### Conflict of Interest

None of the authors has a conflict of interest to declare.

### Bibliography

1. Masanori Someya., *et al.* "Four Cases of Meningeal Hemangiopericytoma Treated with Surgery and Radiotherapy". *Japanese Journal of Clinical Oncology* 31.11 (2001): 548-552.
2. Hansen CP., *et al.* "Primary hemangiopericytoma of the lung". *Scandinavian Journal of Thoracic and Cardiovascular Surgery* 24.1 (1990): 89-92.
3. Rusch VW., *et al.* "Massive pulmonary hemangiopericytoma. An innovative approach to evaluation and treatment". *Cancer* 64.9 (1989): 1928-1936.
4. A Chnaris., *et al.* "Primary mediastinal hemangiopericytoma". *World Journal of Surgical Oncology* 4 (2006): 23.

5. Maruya Jun., *et al.* "(Meningeal Hemangiopericytoma Manifesting as Massive Intracranial Hemorrhage-Two Case Reports)". *Neurologia Medico-Chirurgica* 46.2 (2006): 92-97.
6. Amit Bahl., *et al.* "Multifocal Intracranial Hemangiopericytoma". *Indian Journal of Medical and Paediatric Oncology* 28.1 (2007): 37-38.
7. Spatola C and Privitera G. "Recurrent intracranial hemangiopericytoma with extracranial and unusual multiple metastases: case report and review of the literature". *Tumori* 90.2 (2004): 265-268.

**Volume 10 Issue 8 August 2018**

**©All rights reserved by Ehab Hanafy., *et al.***